



# Grand Rounds from HSS

## Management of Complex Cases

Rheumatology

October 2019 | Volume 8 Issue 3

### HSS Authors

**Halide Ozge Basaran, MD**  
Visiting Research Fellow

**Anne R. Bass, MD**  
Attending Physician  
Professor of Clinical Medicine  
Weill Cornell Medicine

**David R. Fernandez, MD, PhD**  
Assistant Attending Physician  
Assistant Professor of Medicine  
Weill Cornell Medicine

**Nilasha Ghosh, MD**  
Rheumatology Fellow

**Jessica K. Gordon, MD, MS**  
Associate Attending Physician  
Associate Professor of Clinical Medicine  
Weill Cornell Medicine

**Pantelis P. Pavlakis, MD, PhD**  
Assistant Attending Neurologist

**Kimberly Showalter, MD**  
Rheumatology Fellow

**Sarah F. Taber, MD**  
Assistant Attending Physician  
Assistant Professor of Clinical Pediatrics  
Weill Cornell Medicine

**Samir K. Trehan, MD**  
Assistant Attending Orthopaedic Surgeon  
Assistant Professor of Orthopaedic Surgery  
Weill Cornell Medicine

**Guest Author**  
**Xiaoping Wu, MD, MS**  
Assistant Attending Physician  
New York-Presbyterian Hospital  
Instructor of Medicine  
Weill Cornell Medicine



## Diagnostic and Treatment Challenges in Rheumatology

Mary K. Crow, MD  
Editor

This issue features descriptions of several fascinating and challenging patients successfully managed by our Hospital for Special Surgery rheumatologists. The cases highlight examples of the diagnostic and treatment challenges that our physicians address every day.

Case 1, presented by **Halide Ozge Basaran, MD, Samir K. Trehan, MD,** and **Sarah F. Taber, MD,** highlights the diagnosis of a 15-year-old boy with pachydermodactyly, a rare form of fibromatosis that can result from minor mechanical trauma to the fingers.

In Case 2, **Nilasha Ghosh, MD,** and **Anne R. Bass, MD,** describe the successful treatment of an 83-year-old woman who had checkpoint inhibitor-associated myositis and myocarditis, the result of her prior immunotherapy with nivolumab.

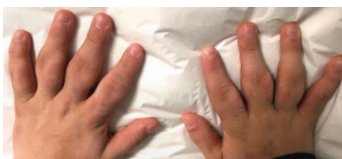In Case 3, **Pantelis P. Pavlakis, MD, PhD,** and **David R. Fernandez, MD, PhD,** discuss a 56-year-old man whose neuropathy associated with trisulfated heparin disaccharide responded well to IV immunoglobulin treatment.

Case 4, presented by **Kimberly Showalter, MD, Xiaoping Wu, MD, MS,** and **Jessica K. Gordon, MD, MS,** features a previously healthy 36-year-old man with progressive shortness of breath and dry cough ultimately diagnosed with antisynthetase syndrome responsive to monthly IV cyclophosphamide for 6 months.

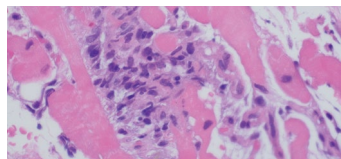
Find enlarged images and links to related articles for this and every issue of *Grand Rounds from HSS: Management of Complex Cases* at [hss.edu/complexcases](http://hss.edu/complexcases). We welcome your comments at [complexcases@hss.edu](mailto:complexcases@hss.edu).

**Mary K. Crow, MD**  
Physician-in-Chief  
Chair, Division of Rheumatology

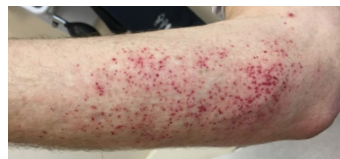## In This Issue



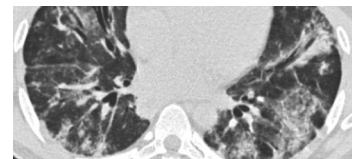
**Case 1**  
Pachydermodactyly, a Rare and Benign Digital Fibromatosis, Diagnosed in a 15-Year-Old Boy



**Case 2**  
Nivolumab-Associated Myositis and Myocarditis in an 83-Year-Old Woman



**Case 3**  
Neuropathy Associated with Trisulfated Heparin Disaccharide Antibodies Responsive to IV Immunoglobulin Treatment



**Case 4**  
Progressive Dyspnea and Cough in a Healthy, Young Man

# Case 1

Case presented by Halide Ozge Basaran, MD, Samir K. Trehan, MD, and Sarah F. Taber, MD

## Pachydermodactyly, a Rare and Benign Digital Fibromatosis, Diagnosed in a 15-Year-Old Boy

**Case Report** A 15-year-old boy presented with a 5-year history of bilateral swelling of the proximal interphalangeal (PIP) joints. The swelling had occurred gradually, until he had visible deformity of both hands. He denied pain or stiffness in his fingers and could write and play sports without limitation. He had no other symptoms, including pain or swelling in his other joints, morning stiffness, fever, or rash. He denied any activity causing repetitive trauma to his fingers, although he did admit to the habit of cracking his knuckles multiple times a day. He had no significant medical or family history. He had previously seen 3 hand surgeons and a pediatric rheumatologist, with no diagnosis.

Clinical examination revealed bilateral periarticular swelling of the PIP joints of the second through fifth digits, with no joint tenderness or decreased range of motion. He had areas of thickened skin on the fingers of both hands (Fig. 1). There were no other joint findings, and his physical examination was otherwise normal. Laboratory investigations, including complete blood count, C-reactive protein, erythrocyte sedimentation rate, antinuclear antibody testing, rheumatoid factor, anti-cyclic citrullinated peptide antibodies, and human leukocyte antigen B27 were all normal. X-ray showed soft-tissue swelling around the PIP joints, with normal joint spaces, articular surfaces, and bone morphology (Fig. 2). Magnetic resonance imaging showed soft-tissue prominence, including collateral ligament thickening with infiltration of subcutaneous fat, but no effusions or erosions. In the absence of clinical, laboratory, and radiological findings suggestive of an inflammatory arthropathy, a diagnosis of pachydermodactyly (PDD) was made. The patient and his family were educated on the nature of this disease, and he was encouraged to refrain from repetitive mechanical trauma to his fingers, including knuckle cracking.

**Discussion** PDD is a rare, benign, acquired digital fibromatosis marked by painless, progressive swelling of the periarticular soft tissues of the fingers, without joint involvement. Adolescent males are most commonly affected [1]. Although the precise etiology remains unknown, the disorder is thought to be related to repetitive minor mechanical trauma, including frequent cracking of the finger joints [2]. Patients present with progressive, painless swelling around the PIP joints, often with thickening of the overlying skin. PDD is diagnosed in patients with typical examination features and the absence of findings consistent with inflammatory arthropathy on imaging and laboratory tests. [1]. Although biopsy is not routinely necessary for diagnosis, histopathology shows hyperkeratosis, acanthosis, and dermal thickening, with increased collagen bundles and fibroblasts [3]. The prognosis is benign, and treatment is not required unless patients are disturbed by the appearance of the fingers. Intralesional corticosteroid injection and surgical excision have been used with benefit in some cases; avoidance of mechanical trauma is recommended [4].

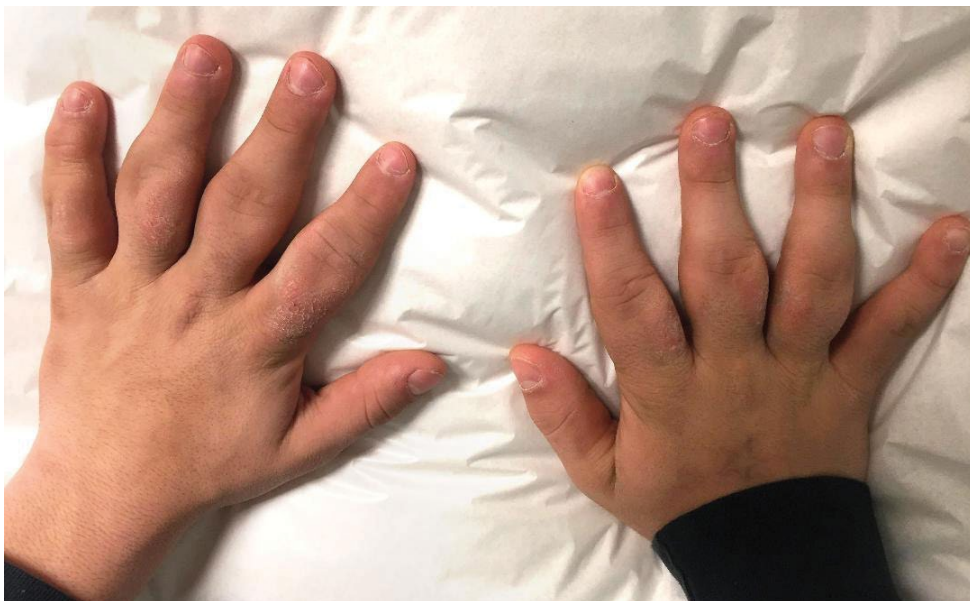PDD can mimic the appearance of an inflammatory arthropathy, such as psoriatic arthritis, rheumatoid arthritis, or juvenile idiopathic arthritis. Patients with PDD are often misdiagnosed, leading to unnecessary concern and treatments. Careful attention to the physical exam, history, and imaging is crucial in order to make the correct diagnosis. Awareness of this clinical entity allows physicians to provide reassurance to their patients and to avoid prescribing unwarranted antiinflammatory or immunosuppressive treatment. ■

### Case 1 References

1. Dallos T, Oppl B, Kovács L, Zwerina J. Pachydermodactyly: a review. *Curr Rheumatol Rep*. 2014;16(9):442.
2. Rancy SK, Granstein RD, Bansal M, Barley CL, Fields TR, Wolfe SW. Pachydermodactyly: a case report including histopathology. *J Hand Surg Am*. 2016;41(8):e243–246.
3. Naviglio S, Mazzolai M, Ventura A. Bilateral finger swelling in an adolescent. *J Pediatr*. 2017;1(188):299.
4. Jhu H, Song J, Kim do Y. Pachydermodactyly: a benign cutaneous condition that may be misdiagnosed as a joint disorder. *J Rheumatol*. 2016;43(8):1615–1616.

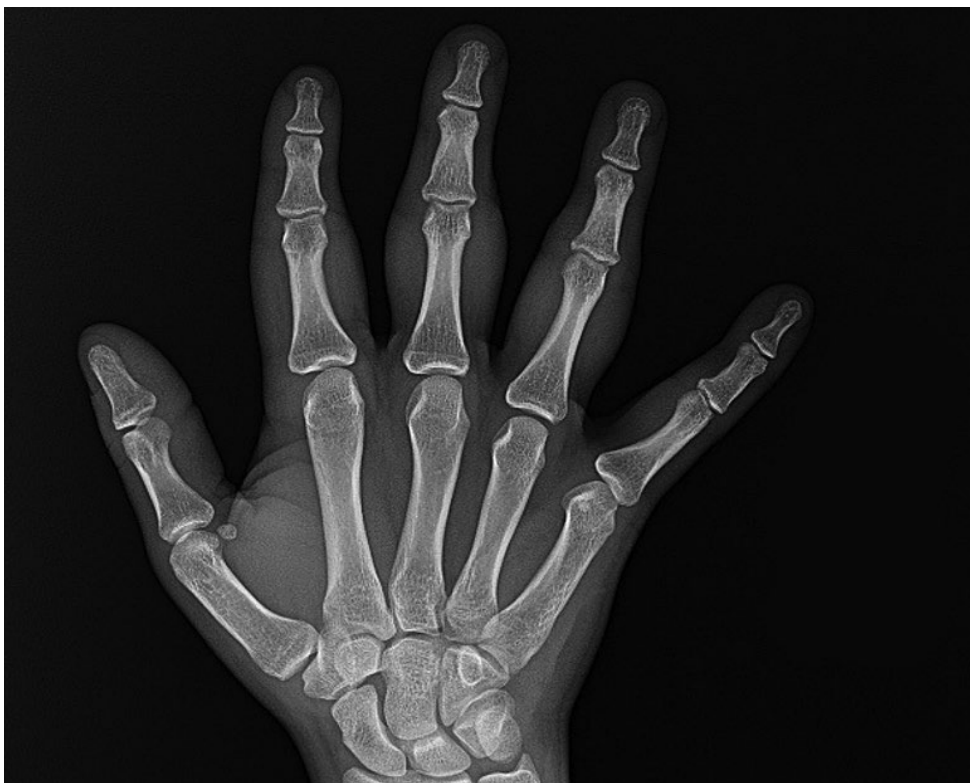[Images on the next page](#)

**Figure 1**



**Figure 1:** Bilateral swelling of the PIP joints, with thickening of the overlying skin.

**Figure 2**



**Figure 2:** X-ray showing soft-tissue swelling around the PIP joints, without joint space narrowing, erosions, or other bony abnormalities.

## Nivolumab-Associated Myositis and Myocarditis in an 83-Year-Old Woman

**Case Report** An 83-year-old woman with nasal cavity melanoma, previously treated with resection and radiation, received two doses of nivolumab, a checkpoint inhibitor (CI), and presented with progressive myalgia and weakness starting a few days after her second infusion.

Her examination was notable for ptosis of the right eye, diffuse tenderness to palpation of her upper arms and thighs, and weakness of her proximal quadriceps and psoas muscles. She required assistance for ambulation and thus was hospitalized. Her bloodwork was notable for creatine kinase (CK) levels above 5000 U/L, transaminase levels in the 300 to 400 U/L range, and a troponin level of 0.99 ng/mL. Electrocardiography (EKG) showed no acute changes, and echocardiography demonstrated a normal ejection fraction and no wall motion abnormalities.

Due to concern for nivolumab-induced myocarditis, she was immediately treated with methylprednisolone 1 g. Laboratory tests shortly thereafter showed a troponin level rising to 1.2 ng/mL; she was started on mycophenolate mofetil 1 g twice daily. Right and left heart catheterization demonstrated non-obstructive coronary artery disease, and biopsies of the right ventricle were taken. The troponin level continued to rise, despite treatment with pulse-dose steroids and mycophenolate. She was then given a single dose of infliximab 5 mg/kg IV, and the troponin level peaked at 1.67 ng/mL. She was transitioned to methylprednisolone 500 mg on hospital day 2 and 250 mg on day 3. Her myalgia and muscle weakness improved. Endomyocardial biopsy revealed a lymphohistiocytic myocarditis with interspersed CD8+ T cells and myocyte necrosis, characteristic of CI-associated myocarditis (Fig. 1). Steroids were titrated down as her troponin level improved, which eventually normalized by hospital day 19 on oral prednisone doses of less than 10 mg daily and continuing mycophenolate.

**Discussion** CIs such as nivolumab, a programmed cell death 1 (PD-1) antibody, enhance T-cell-mediated antitumor responses to treat a variety of advanced cancers. However, immune-related adverse events are seen in more than 80% of patients [1] and can affect almost every organ system. Here we discuss a case of CI-associated myocarditis and myositis.

CI-associated myocarditis usually occurs within the first 1 to 2 months of therapy initiation, and the incidence has been suggested to be around 1% [2]. Although it is a rare immune-related adverse event, it carries the highest case fatality rate [3]. Myocarditis often presents with abnormal cardiac muscle enzymes, along with changes in EKG, echocardiography, and/or magnetic resonance imaging, although these radiographic changes are not always present [4]. Characteristic biopsy findings include histiocytic and CD8+ T cell predominant infiltrate [2, 4, 5]. In select postmortem studies of patients who died of CI-induced myocarditis, similar clonal populations of CD8+ T cells were observed in both tumor and cardiac tissue samples, suggesting myocardial injury is due to cross-reactive T cells [5]. Patients with myocarditis may have skeletal muscle involvement, as well. CI-associated myositis can range from asymptomatic CK elevation to rapidly progressive, profound bulbar weakness and respiratory compromise. An accompanying myasthenia-like syndrome with ptosis and bulbar symptoms has also been reported [6].

Treatment of myocarditis and myositis begins with high-dose steroids, although some patients may require other therapies, such as mycophenolate mofetil, intravenous immunoglobulin, or even plasmapheresis [2, 4, 6]. Tumor necrosis factor inhibitors, such as infliximab, are also used, borrowing from their use in the treatment of CI-associated colitis. Myocarditis, if unrecognized, can rapidly lead to life-threatening arrhythmias

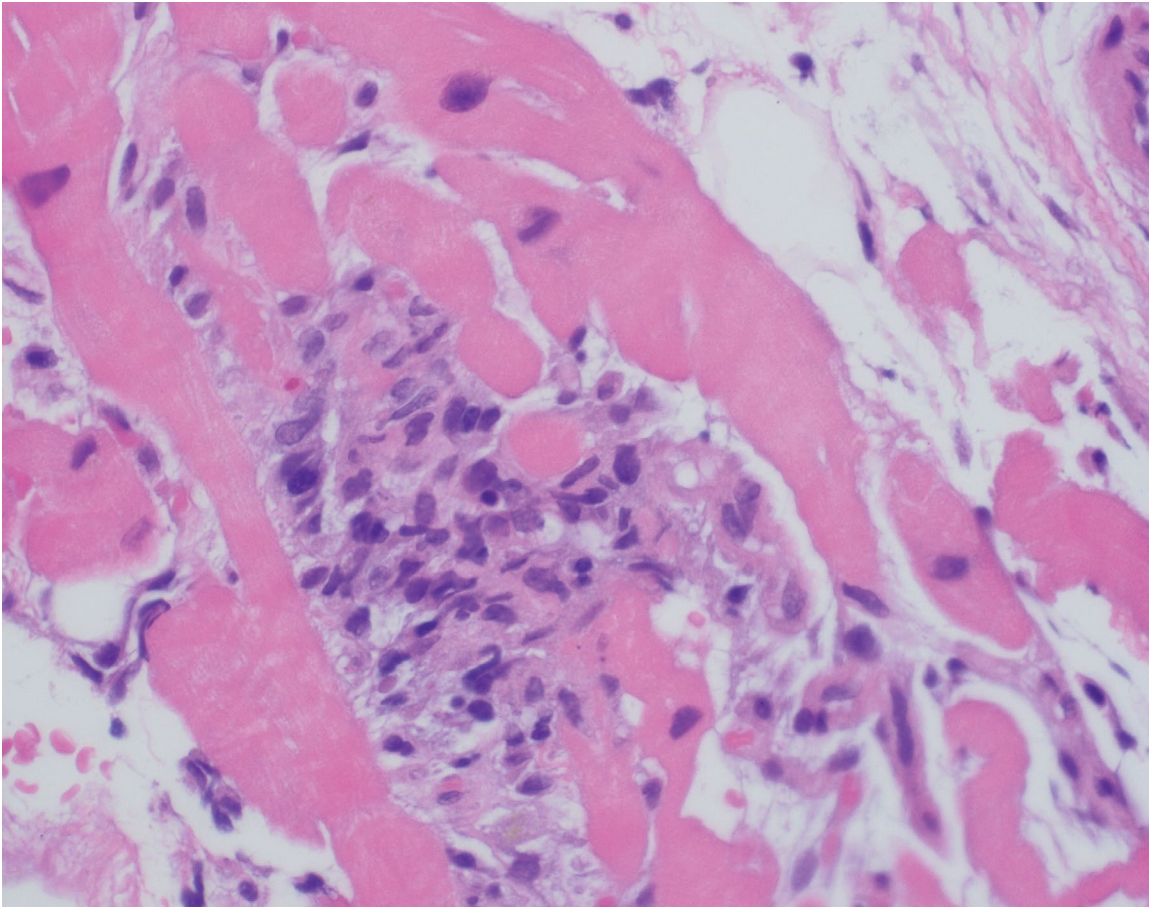
and/or cardiac failure and should be treated promptly and aggressively. However, the use of multiple immunosuppressive agents can be associated with infectious complications, and steroids should be tapered as soon as possible. ■

### Case 2 References

1. Larkin J, Chiarion-Sileni V, Gonzalez R, et al. Combined nivolumab and ipilimumab or monotherapy in untreated melanoma. *N Engl J Med*. 2015;373(1):23–34.
2. Mahmood SS, Fradley MG, Cohen JV, et al. Myocarditis in patients treated with immune checkpoint inhibitors. *J Am Coll Cardiol*. 2018;71(16):1755–1764.
3. Wang DY, Salem JE, Cohen JV, et al. Fatal toxic effects associated with immune checkpoint inhibitors: a systematic review and metaanalysis. *JAMA Oncol*. 2018;4(12):1721–1728.
4. Yang S, Asnani A. Cardiotoxicities associated with immune checkpoint inhibitors. *Curr Probl Cancer*. 2018;42(4):422–432.
5. Johnson DB, Balko JM, Compton ML, et al. Fulminant myocarditis with combination immune checkpoint blockade. *N Engl J Med*. 2016;375(18):1749–1755.
6. Touat M, Maisonobe T, Knauss S, et al. Immune checkpoint inhibitor-related myositis and myocarditis in patients with cancer. *Neurology*. 2018;91(10):e985–e994.

**Images on the next page**

**Figure 1**



**Figure 1:** Hematoxylin and eosin staining of right ventricle endomyocardial biopsy showing myocarditis with lymphohistiocytic infiltration.

## Neuropathy Associated with Trisulfated Heparin Disaccharide Antibodies Responsive to IV Immunoglobulin Treatment

**Case Report** A 56-year-old man with a history of gout and meralgia paresthetica presented with progressive, painful paresthesia since age 53, following a flu-like illness. The paresthesia initially affected his lower legs and then spread to his hands; he described the sensation as burning or crawling in nature. Initial assessment was consistent on nerve conduction studies with a sensorimotor polyneuropathy. Laboratory testing revealed a mildly positive rheumatoid factor and a 0.3g/dL serum immunoglobulin G-κ (IgG-κ) monoclonal gammopathy of undetermined significance (MGUS), though urine immunofixation, vitamin B1, vitamin B12, and thyroid studies were normal, while Lyme antibody testing and transthyretin deoxyribonucleic acid (DNA) testing were negative. An abdominal fat pad biopsy was negative for amyloid deposition. Symptomatic management was attempted with trials of nonsteroidal anti-inflammatory drugs, amitriptyline, gabapentin, pregabalin, and duloxetine, but these were unsuccessful, and he soon required large doses of long-acting and short-acting opioids for pain control.

On evaluation at Hospital for Special Surgery, he described ongoing painful paresthesia, associated with erythema and edema of his legs. These symptoms remained severe despite his intensive opioid regimen, with clear worsening upon heat exposure. He also experienced new-onset photosensitivity, associated with petechial rash (Fig. 1). Neurologic examination showed normal strength and reflexes, with decreased pain, temperature, and vibration sensation in the distal arms and legs. Electrodiagnostic studies showed normal motor and sensory-evoked responses in the arms and legs, except for mild median neuropathy at the left wrist, and no abnormal spontaneous activity on needle electromyography. Magnetic resonance imaging showed only mild lumbar spine degenerative changes and normal lumbosacral plexus. Skin biopsy

showed decreased intraepidermal nerve fiber density at the left calf (2.72 fibers/mm; normal, >3.3) and at the left distal forearm (2.79 fibers/mm; normal, >3). Laboratory testing for antinuclear antibodies, extractable nuclear antibodies, ganglioside, and paraneoplastic antibodies were negative. Immunoglobulin M (IgM) antibodies against IdoA2S-GlcNS-6S, a trisulfated heparin disaccharide (TS-HDS), were then tested and found to be positive (42,000; normal, <10,000).

Partial improvement in symptoms was seen with a trial of moderate-dose corticosteroid therapy. Given the evidence of immune-mediated neuropathy, this was followed by intravenous immune globulin (IVIG), 2g/kg over 4 days, followed by 0.4g/kg every 2 weeks. After starting IVIG therapy, the patient's symptoms rapidly improved, with less pain and less sensitivity to heat and light. Remarkably, within weeks he no longer required long-acting opioids and could steadily taper the short-acting opioids over 9 months.

**Discussion** We report a case of IVIG-responsive, predominantly small-fiber neuropathy associated with IgG-κ MGUS and TS-HDS antibodies. TS-HDS antibodies have previously been associated with immunoglobulin M-κ (IgMκ) MGUS and predominantly small fiber or sensory axonal neuropathy, both in adults [1, 2] and children [3]. As in prior studies, our patient had pure sensory, predominant small-fiber neuropathy. A majority of patients have IgM-κ MGUS; however, our patient had IgG-κ MGUS. Further, the degree of heat sensitivity and the appearance of a petechial rash with sun exposure has not been emphasized previously. Although this is an uncontrolled case study, our patient's marked decrease in opioid requirement after IVIG therapy began provides a marker of treatment response, along with the decreased rash and photosensitivity. This indicates that IVIG may be a valuable agent in the treatment of this rare condition. Larger-

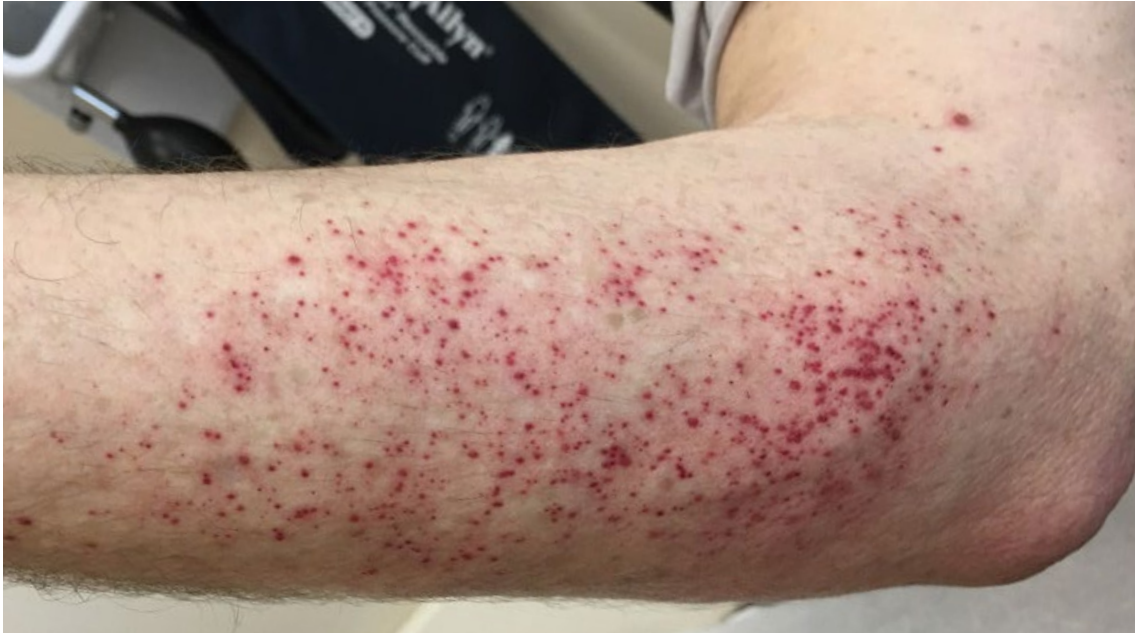scale, placebo-controlled studies are needed to further validate this observation in other patients. ■

### Case 3 References

1. Pestronk A. et al. Sensory neuropathy with monoclonal IgM binding to a trisulfated heparin disaccharide. *Muscle Nerve*. 2003 Feb;27(2):188-95.
2. Pestronk A. et al. Clinical and laboratory features of neuropathies with serum IgM binding to TS-HDS. *Muscle Nerve*. 2012 Jun;45(6):866-72.
3. Kafaie J. et al. Clinical and Laboratory Profiles of Idiopathic Small Fiber Neuropathy in Children: Case Series. *J Clin Neuromuscul Dis*. 2017 Sep;19(1):31-37.

[Images on the next page](#)

**Figure 1**



**Figure 1:** Patient's petechial rash, which emerged after sun exposure.

## Progressive Dyspnea and Cough in a Healthy, Young Man

**Case Report** A 36-year-old previously healthy man presented with progressive shortness of breath and dry cough for 3 months and intermittent fevers for 2 weeks. He had no Raynaud's phenomenon, joint pain, muscle weakness, or skin changes. A chest radiograph demonstrated bilateral basilar infiltrates. Computed tomography (CT) angiography showed bilateral basilar ground-glass opacities, traction bronchiectasis, and a dilated thickened esophagus without pulmonary embolism. He was treated with antibiotics without improvement. A bronchoscopy with biopsy was performed, and pathology from the small sample was read initially as organizing pneumonia. Prednisone 60 mg daily was started. His cough and fevers resolved; however, he subsequently experienced worsening dyspnea, 15-lb. weight loss, dysphagia, and proximal muscle weakness. On the 6-minute-walk-test (6MWT), he desaturated to 90%, with a Borg dyspnea score of 4 ("somewhat severe"). Repeat CT demonstrated worsening ground-glass opacification (Fig. 1).

The patient was readmitted for pulmonary disease progression despite high-dose steroids. Bacterial cultures and tests for respiratory viruses, aspergillus, *Pneumocystis jiroveci* pneumonia, HIV, and tuberculosis were negative. Antinuclear antibody titer was 1:80 (speckled). Other serologic tests were negative including rheumatoid factor and autoantibodies against cyclic citrullinated peptide, Ro (SSA), La (SSB), double-stranded DNA, ribonucleoprotein (RNP), myeloperoxidase, proteinase-3, Jo-1, Scl-70, anticentromere, RNA polymerase III, and anti-glomerular basement membrane. With steroid therapy, creatine phosphokinase level was normal, and aldolase level was mildly elevated (9.2 U/L; upper limit: 8.1). The patient had an isolated urinalysis with hematuria that resolved on repeat study. On re-evaluation of the small initial biopsy sample, there was concern for capillaritis. Repeat lung biopsy was pursued given

diagnostic uncertainty and showed mixed cellular and early fibrotic non-specific interstitial pneumonia (NSIP) (Fig. 2). Cyclophosphamide was given by IV, and eventually a myositis-specific serologic panel was positive for anti-PL-12 (alanyl-tRNA synthetase) antibody.

The patient was diagnosed with antisynthetase syndrome and received monthly IV cyclophosphamide for 6 months, with an excellent response, evidenced by clinically significant improvement in 6MWT distance (92 m) and Borg dyspnea score (2-unit improvement). Steroids were tapered, and mycophenolate was initiated for maintenance. Eight-month CT imaging improved significantly (Fig. 1). After 12 months of treatment, forced vital capacity was 94% predicted (from 89% 3 months post-treatment), and diffusing capacity for carbon monoxide was 62% predicted (from 57% 3 months post-treatment). Eighteen months after diagnosis, the patient had no pulmonary, musculoskeletal, or gastrointestinal symptoms.

**Discussion** Clinical features of antisynthetase syndrome include myositis, interstitial lung disease (ILD), arthritis, fever, and Raynaud's phenomenon [1]. The most common radiographic ILD patterns are NSIP and organizing pneumonia [1]. Autoantibodies in antisynthetase syndrome include anti-Jo-1 (most common), anti-PL-7, anti-PL-12, anti-EJ, anti-OJ, anti-KS, anti-Zo, anti-SC, anti-JS, and anti-YRS [1]. Differences in disease features by antisynthetase antibody have been observed. Specifically, anti-PL-12 positivity is associated with amyopathic dermatomyositis and isolated ILD [2], and patients with anti-PL-12 antibody (vs. anti-Jo-1 antibody) have more severe ILD and worse prognosis [1]. Accordingly, among 202 patients with antisynthetase syndrome, 5-year survival was better in patients with than those without anti-Jo-1 antibody (90% vs. 75%, respectively;  $p < 0.005$ ) [3].

Randomized controlled trials testing therapies in antisynthetase syndrome are lacking. Steroids are considered first-line treatment; however, steroid monotherapy is associated with frequent disease flares. Other immunosuppressive agents used off-label include azathioprine, mycophenolate, tacrolimus, rituximab, and cyclophosphamide [1]. In a systematic review, data was pooled from 12 nonrandomized studies that included 141 patients with idiopathic inflammatory myopathy-associated ILD treated with cyclophosphamide [4]. Cyclophosphamide was associated with forced vital capacity and diffusing capacity for carbon monoxide improvement in 58% and 64% of patients, respectively [4]. Our case illustrates symptomatic and radiographic improvement of antisynthetase syndrome treated with cyclophosphamide with durable response at 18 months on mycophenolate maintenance therapy. ■

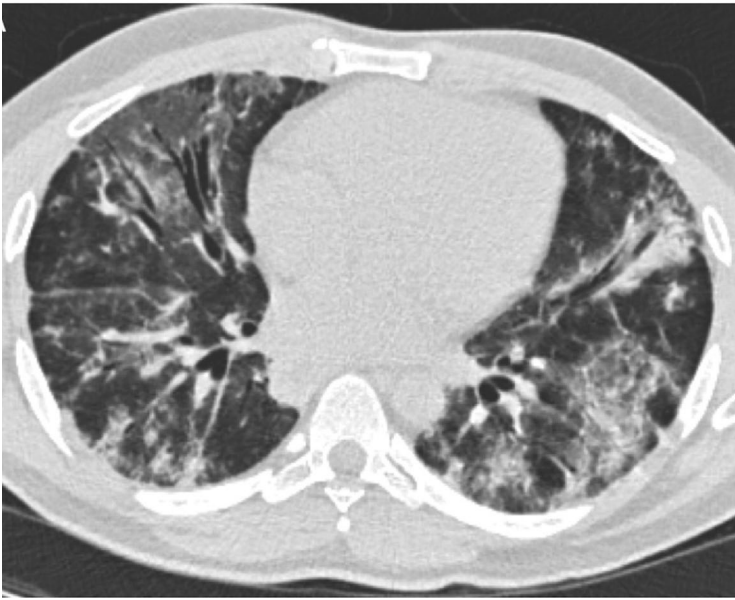### Case 4 References

1. Witt LJ, Curran JJ, Strek ME. The diagnosis and treatment of antisynthetase syndrome. *Clin Pulm Med*. 2016;23(5):218–226.
2. Hamaguchi Y, Fujimoto M, Matsushita T, et al. Common and distinct clinical features in adult patients with anti-aminoacyl-tRNA synthetase antibodies: heterogeneity within the syndrome. *PLoS One*. 2013;8(4):e60442.
3. Aggarwal R, Cassidy E, Fertig N, et al. Patients with non-Jo-1 anti-tRNA-synthetase autoantibodies have worse survival than Jo-1 positive patients. *Ann Rheum Dis*. 2014;73(1):227–232.
4. Ge Y, Peng Q, Zhang S, Zhou H, Lu X, Wang G. Cyclophosphamide treatment for idiopathic inflammatory myopathies and related interstitial lung disease: a systematic review. *Clin Rheumatol*. 2015;34(1):99–105.

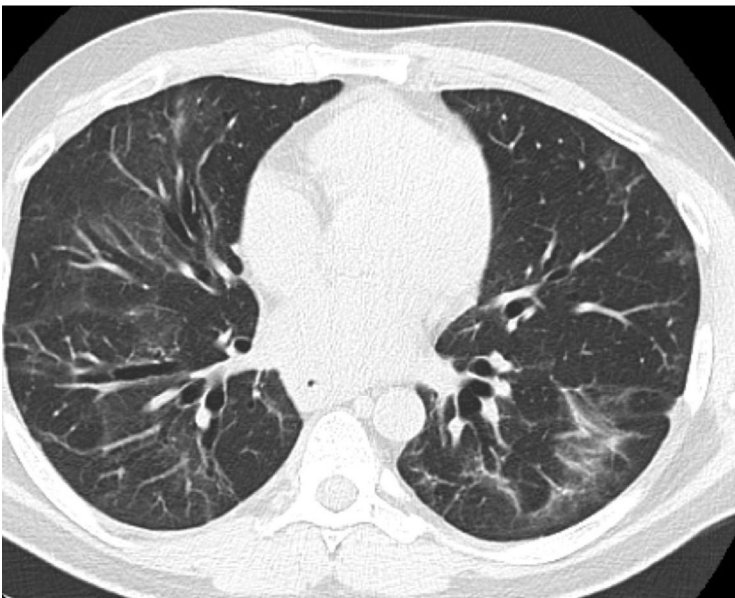
[Images on the next page](#)



**Figure 1A**

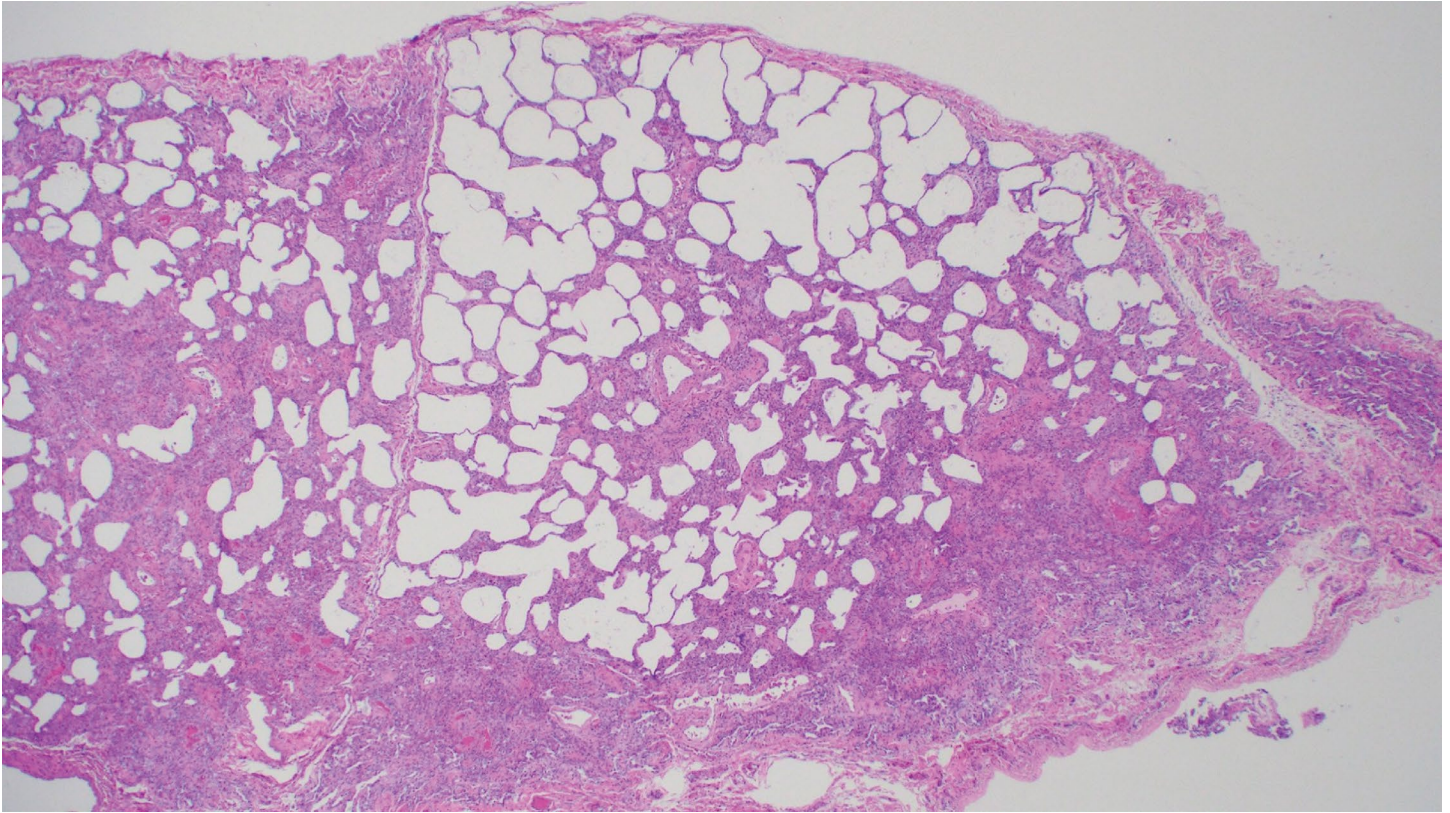


**Figure 1B**



**Figure 1:** (A) Initial CT scan of the lungs demonstrates bilateral ground-glass opacities and peribronchovascular consolidation. (B) Follow-up CT scan, 8 months later, demonstrates significant improvement in the areas of ground-glass and consolidation with persistent mid-to lower-lobe traction bronchiectasis consistent with fibrotic non-specific interstitial pneumonia without progression.

**Figure 2**



**Figure 2:** Right lower lobe lung biopsy demonstrates mixed cellular and early fibrotic non-specific interstitial pneumonia (image courtesy of Alain Borczuk, MD).

# Grand Rounds from HSS Management of Complex Cases

## HSS Editorial Board

### Editors

**Mary K. (Peggy) Crow, MD**

Physician-in-Chief  
Chair, Division of Rheumatology  
Professor of Medicine  
Weill Cornell Medicine

**Edward C. Jones, MD, MA**

Assistant Attending Orthopaedic Surgeon  
Assistant Professor of Orthopaedic Surgery  
Weill Cornell Medicine

### Consultants

**Theodore R. Fields, MD, FACP**

Attending Physician  
Professor of Clinical Medicine  
Weill Cornell Medicine

**Jessica Kovac**

Assistant Vice President  
Division of Rheumatology

### Board

**Dalit Ashany, MD**

Assistant Attending Physician  
Assistant Professor of Clinical Medicine  
Weill Cornell Medicine

**Anne R. Bass, MD**

Attending Physician  
Professor of Clinical Medicine  
Weill Cornell Medicine

**Bryan T. Kelly, MD, MBA**

Surgeon-in-Chief and Medical Director  
Chief Emeritus, Sports Medicine Institute  
Attending Orthopaedic Surgeon  
Co-Director, Center for Hip Preservation  
Professor of Orthopaedic Surgery  
Weill Cornell Medicine

**Laura Robbins, DSW**

Senior Vice President  
Education Institute & Global Partnerships  
Associate Professor  
Graduate School of Medical Sciences  
Clinical Epidemiology and  
Health Services Research  
Weill Cornell Medicine

**Joy Jacobson**

Managing Editor, *HSS Journal*  
HSS Education Institute

### Design/Production

**Marcia Ennis**

Senior Creative Director  
Education Marketing & Digital Communications  
HSS Education Institute

**Randy Hawke**

Associate Director  
Education Marketing & Digital Communications  
HSS Education Institute