

# Fixator-Assisted Plating of Limb Deformities

S. Robert Rozbruch, MD

Fixator-assisted plating of the distal femur and proximal tibia can be used for accurate and effective correction of acute deformity. The advantage of this hybrid technique is that one can use the best of both internal and external fixation. The external fixator is applied in a fashion that does not impede insertion of the plate. The neutral wedge osteotomy is then performed in a minimally invasive fashion. The fixator is used to incrementally correct the deformity over several minutes in a controlled and gradual fashion in the operating room. Complex deformity correction, including angulation and translation in the coronal, sagittal, and axial planes, can be gradually adjusted. The surgeon maintains control of the osteotomy, and the position can be checked with x-ray and/or computer navigation. The fixator may be further adjusted to tweak the position as needed. Once alignment is optimal, a locked plate is inserted through a minimal incision technique to maintain the position, allowing removal of the fixator.

Oper Tech Orthop 21:174-179 © 2011 Elsevier Inc. All rights reserved.

**KEYWORDS** osteotomy, deformity, external fixator, fixator assisted plating, Taylor spatial frame

Asymmetric joint wear, caused by malalignment and/or rotational deformity, skews the proper transmission of forces across a joint. In the knee, even moderate malalignment can advance or jump-start the progression of osteoarthritis.<sup>1,2</sup> The deformity can originate from the femur, tibia, joint line, or a combination of these locations. Our approach has been to perform osteotomy at the source of the deformity. We use the malalignment test<sup>3</sup> in which joint orientation angles are analyzed to determine the source of the deformity. Osteotomy of the femur<sup>4,5</sup> and tibia<sup>6,7</sup> have proven to be a reliable approaches for correcting malalignment and may even lead to cartilage regeneration. Accurate femoral and tibial deformity corrections depend on the combined correction of the mechanical axis deviation (MAD) and the joint orientation angles-lateral distal femoral angle (LDFA) and medial proximal tibial angle.<sup>8</sup> Achieving optimal overcorrection is a critical factor in achieving long-term success in the treatment of unicompartmental arthrosis.<sup>7</sup>

Acute correction of malalignment may be achieved with either closing or opening wedge osteotomy. Some of the limitations of these classic techniques include the need for large surgical exposure with soft-tissue stripping, and difficulty in executing a precise deformity correction in surgery. Optimal

correction is often not achieved, and the alignment cannot be adjusted further without additional surgery. Shortening results from the removal of large bone segments for a closing wedge osteotomy. These techniques become even more technically challenging when the deformity is in an oblique plane requiring a closing or opening trapezoidal wedge. Deformity correction of a large magnitude requires removal or creation of a big wedge which in turn can lead to shortening or difficulty with bone healing, respectively. Often the deformity correction necessitates translation of the bony fragments<sup>3,9</sup>; this is not possible with the opening wedge technique, which requires an intact cortex on the convexity of the deformity to maintain stability.

External fixation can be used to accurately correct deformity about the knee.<sup>9</sup> Fixators can be used for acute or gradual deformity correction. However, external fixation is uncomfortable for the patient, tethers the soft-tissue, and is often associated with pin site irritation and infection.<sup>9</sup>

Hybrid techniques have been implemented to use the strengths and benefits of both internal and external fixation techniques.<sup>10-13</sup> This approach has been used successfully in lengthening over a nail,<sup>14</sup> lengthening and then nailing,<sup>13</sup> and fixator-assisted nailing.<sup>10,15</sup> Fixator-assisted plating (FAP) shares many of the same principles but has particular benefit in periarticular deformity in which the osteotomy is performed close to the joint. External fixation can be used to control and stabilize the fragments while dialing in the desired correction. Internal fixation can then be applied to a

Limb Lengthening and Complex Reconstruction Service, Hospital for Special Surgery; Clinical Orthopaedic Surgery, Weill Cornell Medical College, New York, NY; Cornell University, New York, NY.

Address reprint requests to S. Robert Rozbruch, MD, 535 East 70th Street, New York, NY 10021. E-mail: RozbruchSR@hss.edu

stable fully corrected osteotomy, enabling the intraoperative removal of the fixator without loss of position.

External fixators designed specifically for deformity correction, such as the Taylor Spatial Frame (TSF; Smith & Nephew, Memphis, TN)<sup>9,12,13</sup> and the EBI/Biomet Mutiaxial Correction (MAC) Frame (Parsippany, NJ)<sup>11,16</sup> are best used for this purpose. They have hinges that enable incremental deformity correction in the sagittal, coronal, and axial planes. The external fixator is applied to match the deformity, and the pins are placed so that they will not impede the subsequent insertion of internal fixation.<sup>10,13,14,17</sup> The osteotomy is performed in a percutaneous fashion. The fixator is then used for controlled incremental deformity correction while in surgery. Typically a neutral wedge correction is used with some required translation and satisfactory bone contact. No bone graft is needed. Intraoperative assessment can be performed with fluoroscopy and/or computer navigation.<sup>11</sup> Additional correction may be implemented. The bony fragments are stable during the process. Once the position is deemed to be optimal, the internal fixation is inserted to maintain the position. Locked plating systems are ideally suited for this because translation can be maintained and the plate functions like an internal fixator.

## Operative Technique

### Fixator-Assisted Plating of the Distal Femur with Computer Navigation

In this technique, a combination of epidural and femoral block anesthesia is used. The patient is positioned supine on a radiolucent table. The MAC external fixator (EBI rail frame) is applied to the distal third of the femur (Fig. 1B). Two 6.0-mm Schanz screws are inserted from anterior to posterior in the diaphysis and 2 medial Schanz screws are inserted into the distal condyle under fluoroscopic control. The center of rotation of angulation<sup>3,8</sup> is defined on the basis of preoperative measurements and localized on the patient by the use of C-arm fluoroscopy. This is performed to accurately position the hinge of the fixator at the center of rotation of angulation.

Before further steps are taken, navigation is performed with dedicated osteotomy reconstruction software. The required reference markers are attached to the frame's proximal Schanz screws, and at the proximal tibial site 2 additional Schanz screws are used for fixation of the markers.

Image-free leg-alignment data acquisition includes registration of the hip and ankle centers and defined percutaneous landmarks of the femoral and tibial epicondyles. Passive flexion-extension motion sequence is further registered. The apex of the deformity is chosen to be the osteotomy site. The osteotomy is performed by the use of a percutaneous multiple drill hole and osteotomy technique under fluoroscopic guidance (Fig. 1C, D).

After navigated registration is complete, mechanical leg alignment correction is performed by the use of the main frame hinge for correction in the frontal plane. Stepwise corrections in 1° increments are preformed and are simultaneously measured by the navigation system (Fig. 1E).<sup>11</sup> The fixator adjustments of each degree do not always perfectly

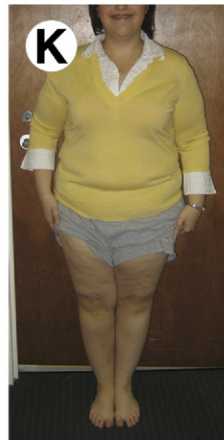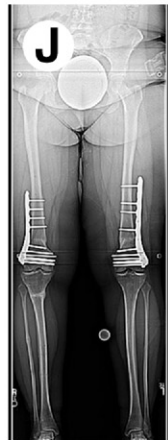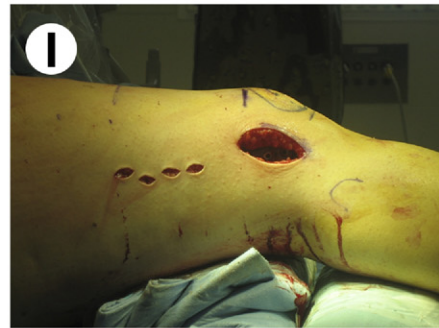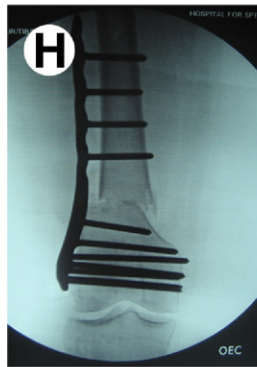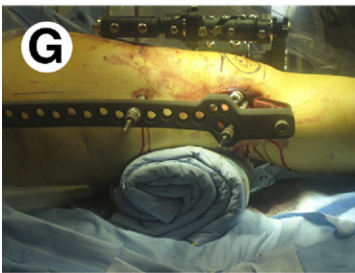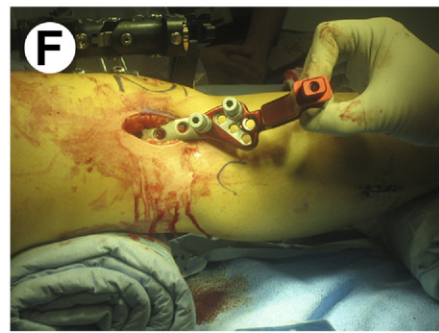
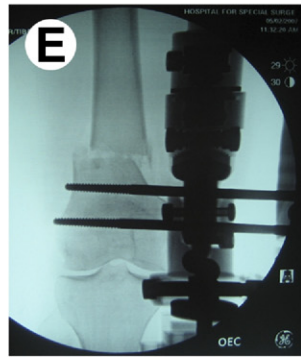
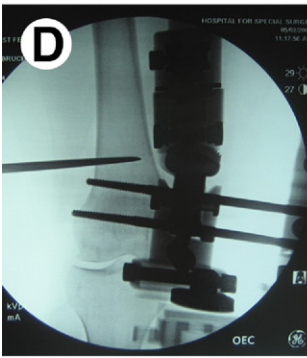
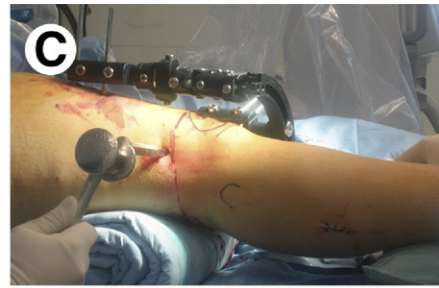
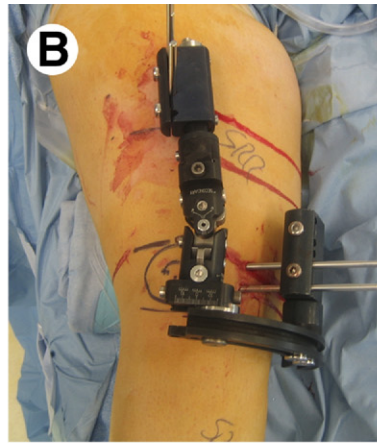
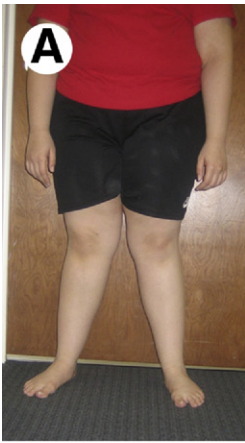correlate with the degree correction noted by the navigation or intraoperative x-ray. Soft-tissue tension can cause some compromise in the bone movement response to the fixator adjustment. Axial loading was again preformed and showed no further deformity. This finding supports the concept that the well aligned extremity is more resistant to deformity from ligamentous laxity. Before correction, axial loading will often increase the MAD when there is ligament laxity.<sup>11</sup>

Final position is secured with the frame, and the fixation is performed with a precontoured distal femoral locking plate in a minimally invasive technique. A 5-cm incision is made on the lateral aspect of the distal femur where there is no external fixation. The iliotibial band was incised in line with the incision and the dissection was carried to bone. A tunnel is made under the vastus lateralis muscle. A locked distal femoral plating system with a jig for percutaneous screw placement is used. The plate is inserted in a retrograde fashion along the lateral aspect of the distal femur (Fig. 1F). Biplanar fluoroscopy is helpful for optimal positioning of the plate. The plate targeting device is attached and used for screw insertion (Fig. 1G). The first screw is a nonlocking screw at the proximal plate to pull the plate to the bone, and all subsequent screws are locking screws. Care should be taken not to deform the plate. Often the distal plate is translated off the bone (Fig. 1H). Proximal plate screws are inserted through percutaneous stab wounds (Fig. 1I) by the use of the targeting device. The external fixator was then removed after the plate was secure. Computer navigation is not essential.

### Clinical Results of Fixator-Assisted Plating of the Femur

We evaluated the results of osteotomy of the femur with the use of FAP versus monolateral external fixation.<sup>18</sup> The primary goal was to assess the accuracy of correction, surgical time, and the recovery time of patients within the 2 groups. We evaluated 36 extremities in 27 patients. The EBI was used for deformity correction in 23 femurs and FAP was used in 13 femurs. The average age of all the patients was 33 years. The average follow-up period was 16 months, with the longest being 4.5 years.

The average preoperative MAD for patients using a rail frame with a varus and valgus deformity was 52 mm medial (range, 18-100 mm medial) and 34 mm lateral (range, 8-83 mm lateral), respectively. The average preoperative MAD for patients who underwent correction with a FAP for valgus deformity was 27 mm lateral (range, 3-55 mm lateral). Two patients underwent varus correction with a FAP had preoperative MAD 57-75 mm medial, respectively. We corrected an average of 48 mm on patients with a varus deformity and 37 mm with a valgus deformity by using the rail frame. We corrected an average of 28 mm in patients with a valgus deformity who underwent FAP (Fig. 1J, K). Two patients underwent correction for rotational deformities, and 2 had varus correction via the use of FAP. The average preoperative LDFA in frame group was 85 (range, 78-98) and with FAP was 84 (range, 72-103). The average postoperative LDFA was 90 (range, 83-95) for frame group and 91 (range, 85-95) for





FAP group. The average duration of surgery for application of a rail frame was 94 minutes and for correction with FAP was 122 minutes. Accuracy of correction was similar between the 2 groups.

We concluded that both the use of FAP and a rail frame for femoral deformity correction are safe and effective surgical techniques. Correction with a rail frame requires more time for recovery. The external frame can cause superficial pin tract infections. The FAP technique requires more or time and also increases the incidence of postoperative blood transfusion. It is associated with postoperative discomfort around the Iliotibial band, which requires removal of the hardware in some cases after 1 year.

### Fixator-Assisted Plating of the Proximal Tibia

Spinal anesthesia typically is used for this procedure. We perform a fibular osteotomy under tourniquet control. A 3-cm incision is made on the lateral aspect of the middle leg, and the fibula is approached in the interval between the lateral and posterior compartments. An oblique fibula osteotomy is then performed with a microsagittal saw while cooled with saline and then completed with an osteotome. The tourniquet is not used for the remainder of the surgery. A three-ring TSF is then applied with a rings-first method.<sup>9,19-21</sup> We use a 2/3 ring at the proximal tibia with the opening of the ring facing lateral. The pin fixation is placed from the medial side leaving the lateral approach undisturbed (Fig. 2A-D). With the use of a cannulated wire technique, the reference pin is placed from medial to lateral perpendicular to the proximal mechanical axis. The second pin is directed antero-medial to posterolateral and sets the ring in both the coronal and sagittal planes (Fig. 2B). The third pin is anteromedial to posterolateral and captures the fibula head. This is placed using a cannulated wire technique. First, the 1.8-mm wire is directed from the proximal fibula in an anteromedial direction. Then, a cube is placed on the ring at the location of the wire. A cannulated 4.8-mm drill is directed from anteromedial to posterolateral, ending in the fibula head, and then a 6-mm pin is then inserted. The distal ring is applied so the pin fixation will be distal to the future plating. At the plate insertion, it is desirable to place 3-4 locking screws into the distal fragment.

The proximal ring is the reference ring, and TSF mounting parameters are measured in relation to this ring. The ring

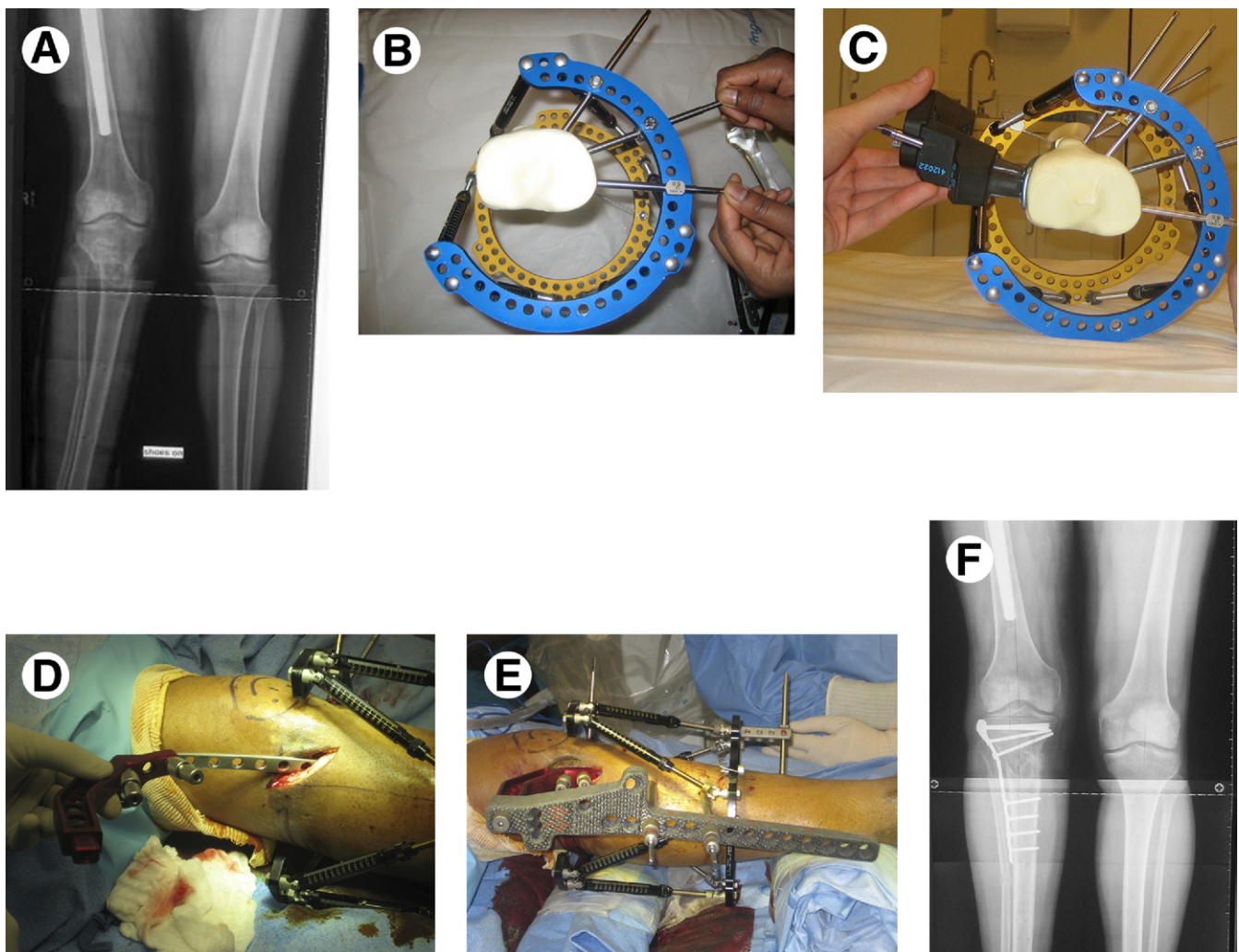
orientation requires the input of rotatory frame offset into the TSF program because the master tab of the reference ring is rotated (Fig. 2B).<sup>9,19-21</sup> The origin was placed at the level of deformity within the metaphysis. The origin was typically at the level of osteotomy 5 cm distal to the knee joint just beyond the tibial tubercle. The struts were then removed for the osteotomy. The osteotomy was performed through a 1 cm stab incision using a multiple drill hole technique.<sup>3,9</sup> The struts were then reapplied and the correction was done incrementally in the operating room. A TSF schedule was created and the correction was done stepwise by adjusting all 6 struts gradually over several minutes. The position was checked with intraoperative x-ray and/or computer navigation. Once the position was deemed to be optimal, the plate as inserted.

The plate was inserted with the TSF in place. A 5-cm incision was made at the proximal lateral tibia away from the external fixation pins. The iliotibial band insertion on Gerdy's tubercle was released and split in the anterior fascia was made as a portal for the plate. A locked plate was inserted along the lateral aspect of the tibia in an antegrade direction (Fig. 2D). Biplanar fluoroscopy was helpful for optimal positioning of the plate. The plate targeting device (Fig. 2E) was attached and was used for screw insertion. The first screw was a nonlocking screw at the proximal plate to pull the plate to the bone. All subsequent screws were locking screws. Care was taken not to deform the plate. Often the distal plate was translated off the bone. Typically, we inserted 4 screws in both the proximal and distal segments (Fig. 2F). The frame was then removed.

### Conclusions

FAP of the distal femur and tibia can be used for accurate and effective acute deformity correction. The advantage of this hybrid technique is that one can use the best of both internal and external fixation. Complex deformity correction, including angulation and translation in the coronal, sagittal, and axial planes, can be achieved while the surgeon maintains control of the osteotomy position. Once alignment is optimal, a locked plate is inserted allowing the removal of the fixator. This technique can be used as an alternative to external fixation and has the benefit of not requiring the patient to wear a frame for 3 months. FAP may also be used as an alternative to osteotomy with in-

← **Figure 1** (A) 24 year old woman with bilateral knee valgus deformities associated with lateral knee pain. Preoperative front view. (B) Front view of right thigh in operating room. Left side of photo is the lateral side of thigh. MAC frame is mounted with hinge over the distal femur. Proximal pins are anterior to posterior and distal pins are medial to lateral. (C) Percutaneous osteotomy is performed from lateral side. (D) Intraoperative fluoroscopy image showing pass of osteotome during the osteotomy. (E) After the frame has been used to reposition the osteotomy. (F) Insertion of locked plate through a 5-cm lateral incision in a retrograde fashion. (G) The plate has been positioned, and the targeting jig is being used to insert screws. (H) Fixation with the locked plate. Note the intentional translation that may be maintained with a locked plate. (I) Lateral view of the thigh after plate insertion showing the minimal incision technique. (J) One-year follow-up erect leg radiograph after bilateral distal femur FAP and right proximal tibial osteotomy with a TSF. (K) One-year follow-up front view. (Color version of figure is available online.)



**Figure 2** (A) Anteroposterior radiograph showing fracture and valgus deformation after frame removal following a proximal tibia lengthening. (B) Axial view of saw bone model from proximal to distal showing the TSF 2/3 ring mounted to proximal tibia. Opening of the ring is lateral. Pin fixation is medial. (C) Saw bone model with lateral plate and targeting jig in place. (D) After intraoperative correction of the deformity with the TSF, antegrade insertion of the locking plate through 5 cm incision at lateral proximal tibia. (E) Targeting jig in place for screw insertion. (F) Follow-up anteroposterior radiograph showing neutral alignment. (Color version of figure is available online.)

ternal fixation and has the benefit of minimal incision surgery and use of a temporary frame to incrementally correct deformity and maintain stability of the osteotomy before insertion of the plate.

## References

- Hochberg MC, Altman RD, Brandt KD, et al: Guidelines for the medical management of osteoarthritis. Part II. Osteoarthritis of the Knee: American College of Rheumatology. *Arthritis Rheum* 38:1541-1546, 1995
- Sharma L, Song J, Felson DT, et al: The role of knee alignment in disease progression and functional decline in knee osteoarthritis. *JAMA* 286:188-195, 2001
- Paley D: *Principles of Deformity Correction* (ed 1). Berlin, Springer-Verlag, 2005
- Terry GC, Cimino PM: Distal femoral osteotomy for valgus deformity of the knee. *Orthopedics* 15:1283-1289, 1992
- Wang JW, Hsu CC: Distal femoral varus osteotomy for osteoarthritis of the knee. Surgical technique. *J Bone Joint Surg Am* 88(Suppl 1):100-108, 2006
- Coventry MB: Proximal tibial varus osteotomy for osteoarthritis of the lateral compartment of the knee. *J Bone Joint Surg Am* 69:32-38, 1987
- Coventry MB, Ilstrup DM, Wallrichs SL: Proximal tibial osteotomy. A critical long-term study of eighty-seven cases. *J Bone Joint Surg Am* 75:196-201, 1993
- Paley D, Herzenberg JE, Tetsworth K, et al: Deformity planning for frontal and sagittal plane corrective osteotomies. *Orthop Clin North Am* 25:425-465, 1994
- Rozbruch SR, Segal K, Ilizarov S, et al: Does the Taylor Spatial Frame accurately correct tibial deformities? *Clin Orthop Relat Res* 468:1352-1361, 2009
- Gugenheim JJ Jr, Brinker MR: Bone realignment with use of temporary external fixation for distal femoral valgus and varus deformities. *J Bone Joint Surg Am* 85-A:1229-1237, 2003
- Kendoff DO, Fragomen AT, Pearle AD, et al: Computer navigation and fixator-assisted femoral osteotomy for correction of malunion after periprosthetic femur fracture. *J Arthroplasty* 25:333.e13-9, 2009
- Rogers MJ, McFadyen I, Livingstone JA, et al: Computer hexapod assisted orthopaedic surgery (CHAOS) in the correction of long bone fracture and deformity. *J Orthop Trauma* 21:337-342, 2007

13. Rozbruch SR, Kleinman D, Fragomen AT, et al: Limb lengthening and then insertion of an intramedullary nail: A case-matched comparison. *Clin Orthop Relat Res* 466:2923-2932, 2008
14. Paley D, Herzenberg JE, Paremian G, et al: Femoral lengthening over an intramedullary nail. A matched-case comparison with Ilizarov femoral lengthening. *J Bone Joint Surg Am* 79:1464-1480, 1997
15. Eralp L, Kocaoglu M, Cakmak M, et al: A correction of windswept deformity by fixator assisted nailing. A report of two cases. *J Bone Joint Surg Br* 86:1065-1068, 2004
16. Tellisi N, Ilizarov S, Fragomen AT, et al: Humeral lengthening and deformity correction in Ollier's disease: Distraction osteogenesis with a multi-axial correction frame. *J Pediatr Orthop B* 17:152-157, 2008
17. Kocaoglu M, Eralp L, Bilen FE, et al: Fixator-assisted acute femoral deformity correction and consecutive lengthening over an intramedullary nail. *J Bone Joint Surg Am* 91:152-159, 2009
18. Shafi R, Rozbruch SR, Fragomen AT, et al: A Matched Comparison of Fixation Techniques for Distal Femur Osteotomy: Fixator Assisted Plating vs. Monolateral Frame. Presented at the Limb Lengthening and Reconstruction Society Meeting, 2009. Louisville, KY, 2009
19. Rozbruch SR, Fragomen AT, Ilizarov S: Correction of tibial deformity with use of the Ilizarov-Taylor spatial frame. *J Bone Joint Surg Am* 88 suppl 4:156-174, 2006
20. Rozbruch SR, Pugsley JS, Fragomen AT, et al: Repair of tibial non-unions and bone defects with the Taylor Spatial Frame. *J Orthop Trauma* 22:88-95, 2008
21. Taylor JC, Taylor: Spatial Frame, in Rozbruch SR, Ilizarov S (eds): *Limb Lengthening and Reconstruction Surgery*. New York, Informa, 2007, pp 613-637