

# Charcot Reconstruction Using External Fixation

NY Podiatric Clinical Conference, January 26, 2013

## **S. Robert Rozbruch, MD**

Chief, Limb Lengthening & Complex Reconstruction Service  
Professor of Clinical Orthopedic Surgery

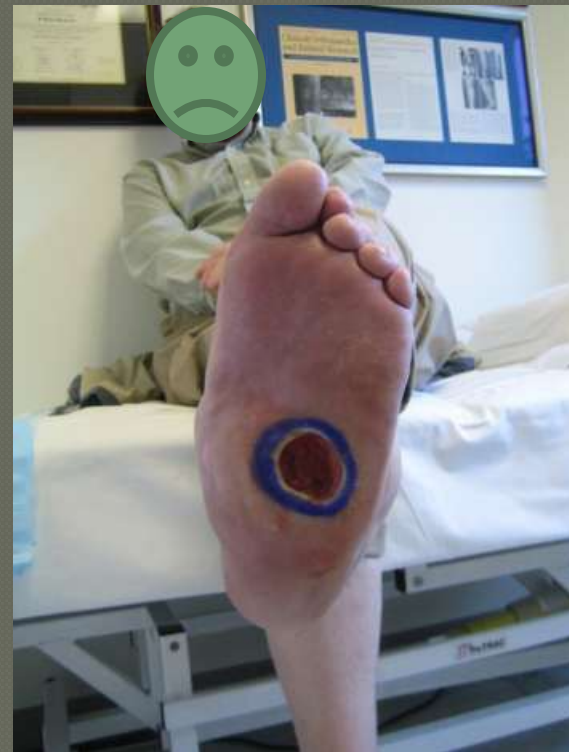

LIMB .COM

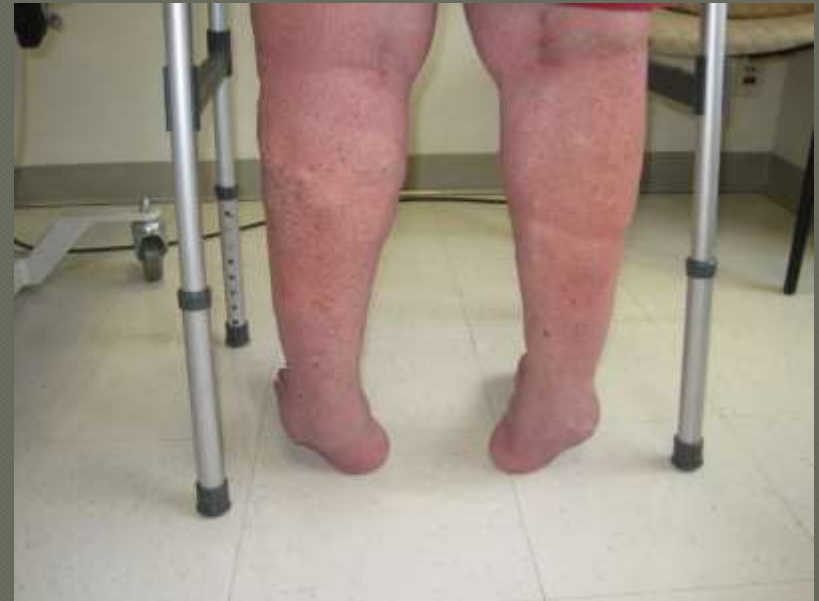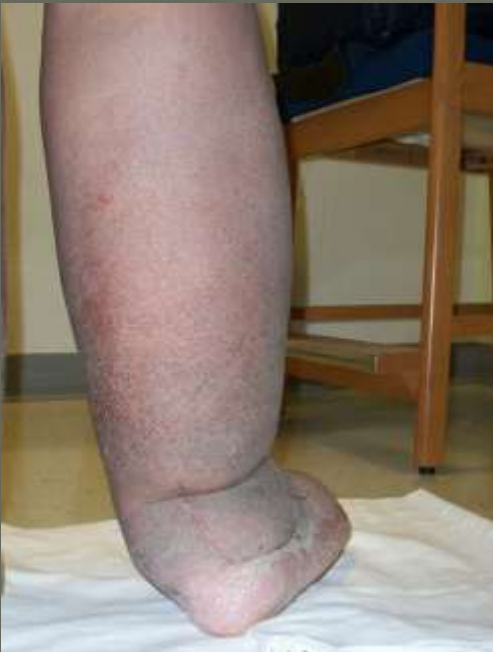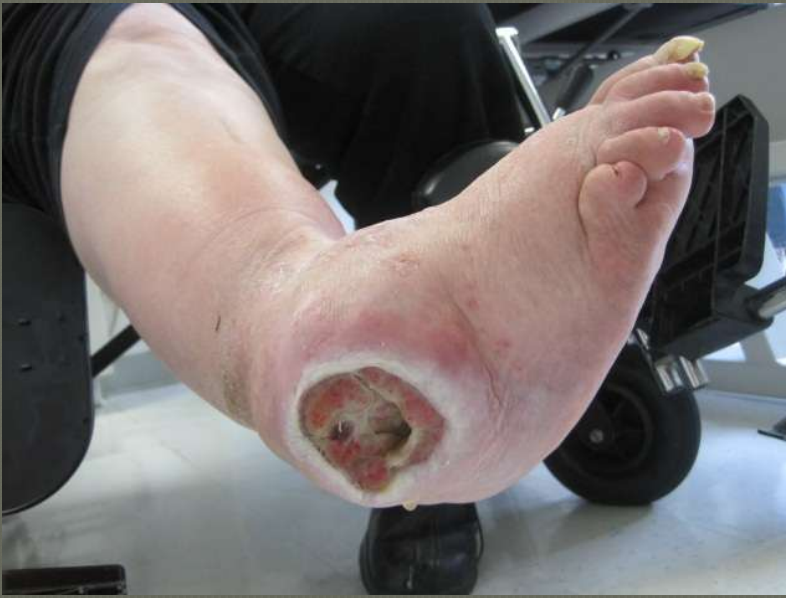The logo for Limb Lengthening.com features the word "LENGTHENING" in a blue, bold, sans-serif font, enclosed within a black rectangular frame that has tick marks on all four sides, resembling a technical drawing or a measurement tool. The word "LIMB" is to the left and ".COM" is to the right of this frame.

# Charcot

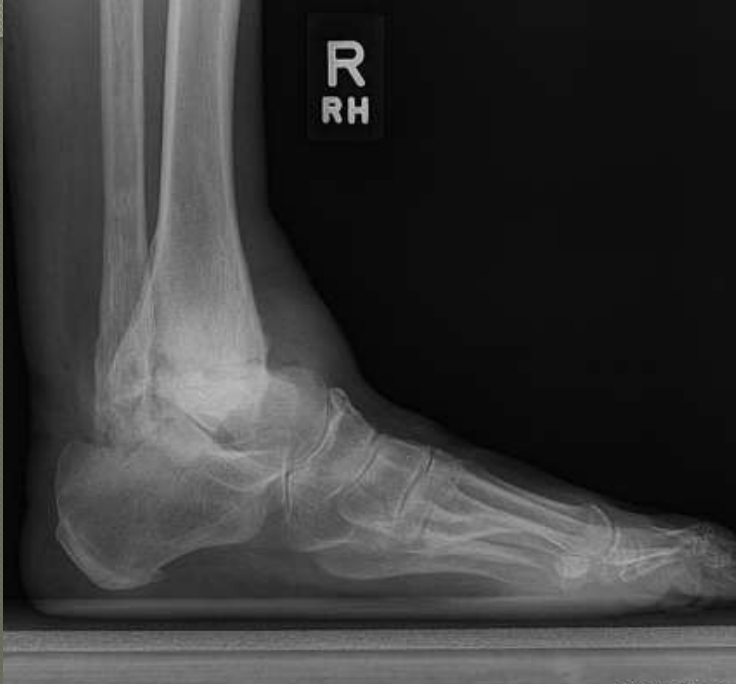- Ankle
- Hindfoot
- Midfoot
- Infection
- Ulcers
  
- Charcot-Marie-Tooth



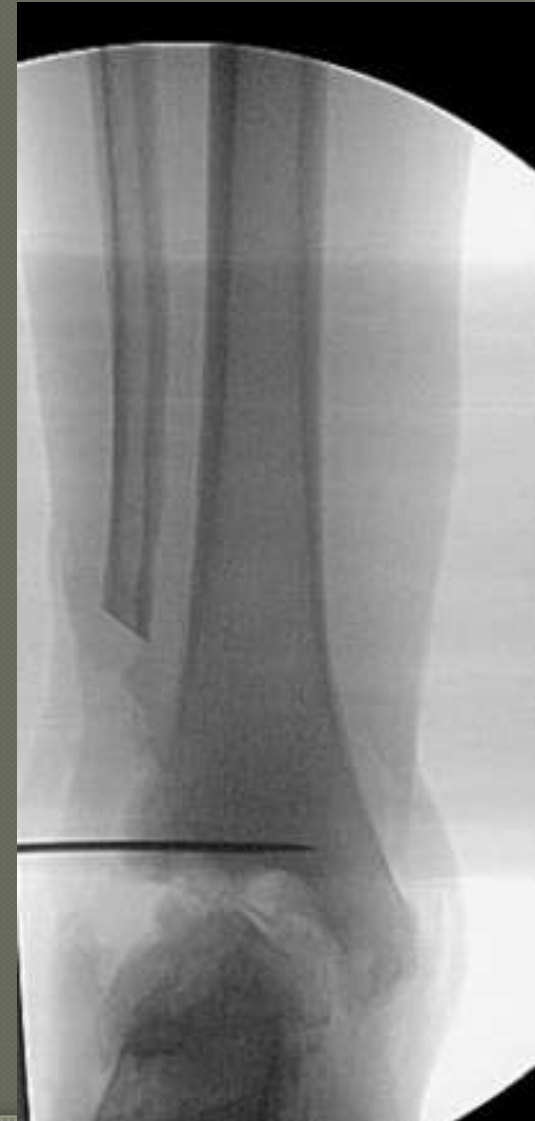Before:  
Charcot variety



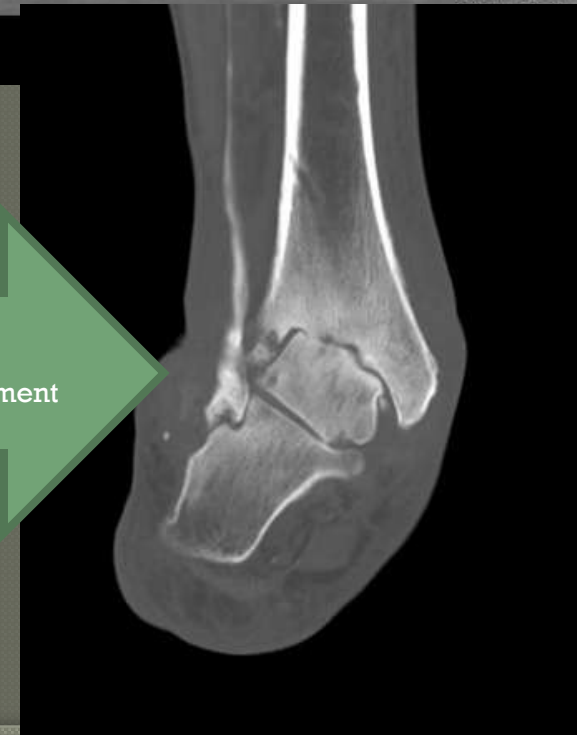R  
RH


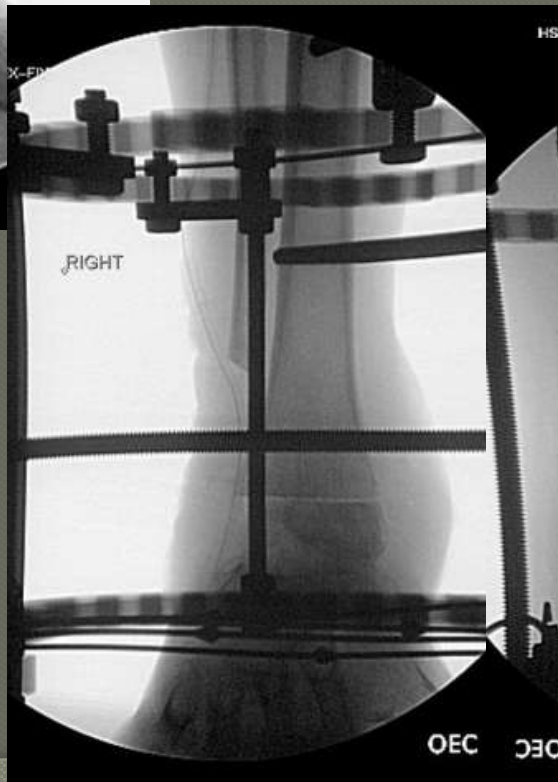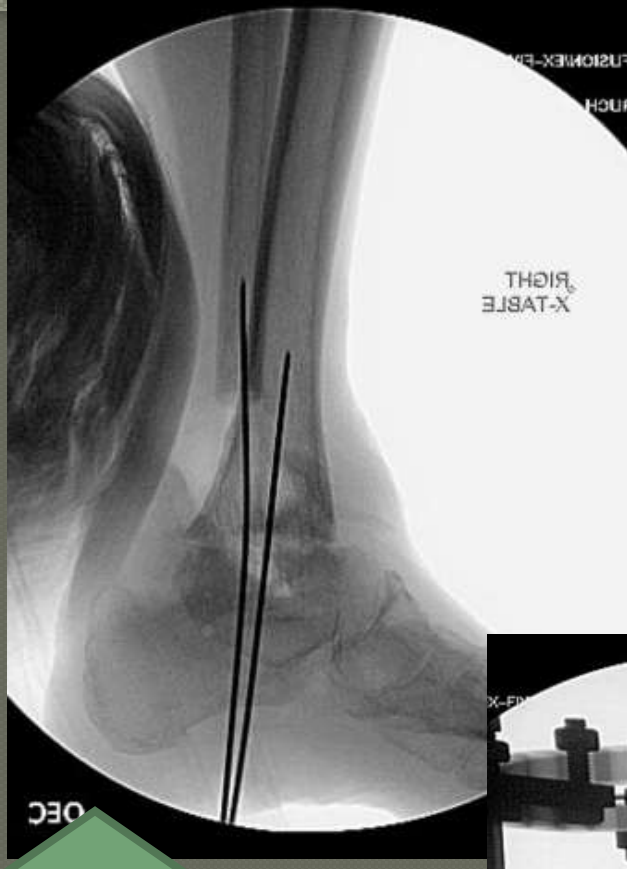
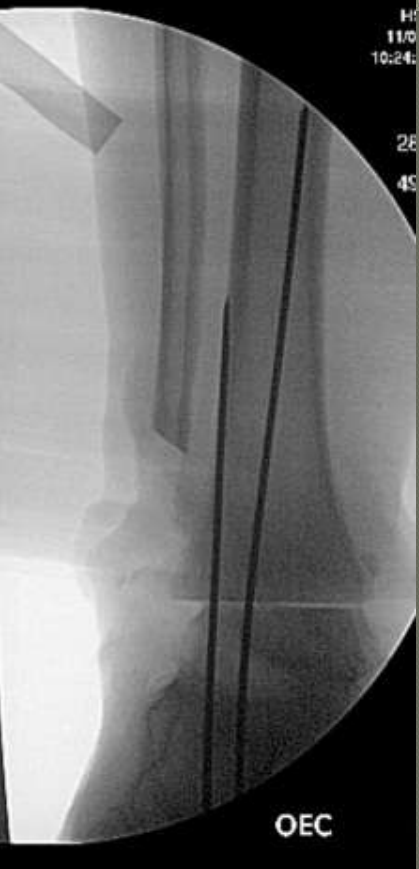

Before

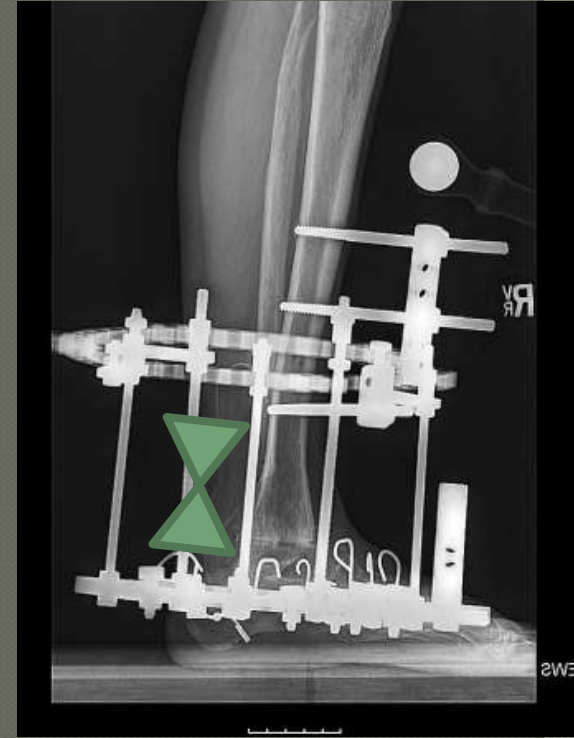
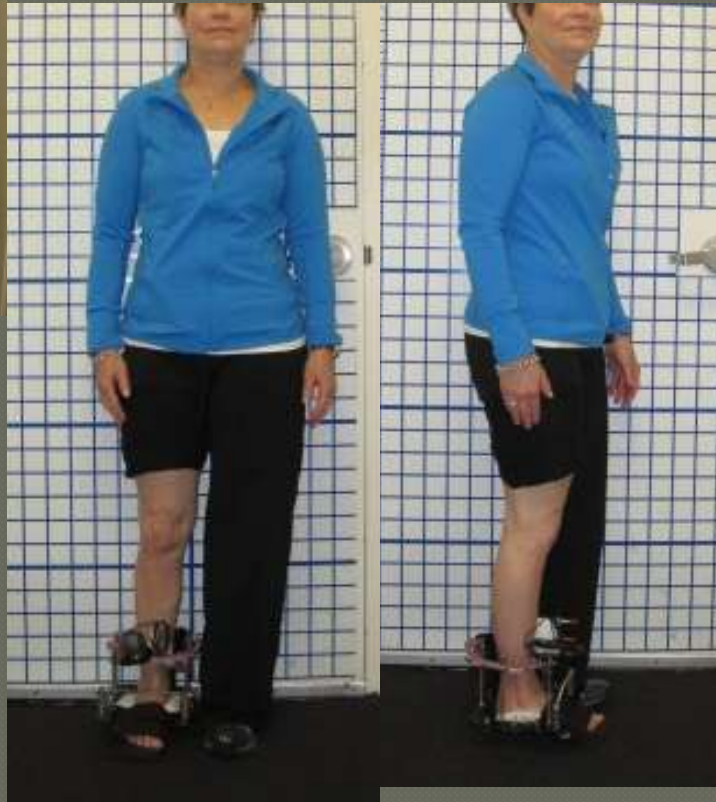
Valgus def.  
Fibular impingement

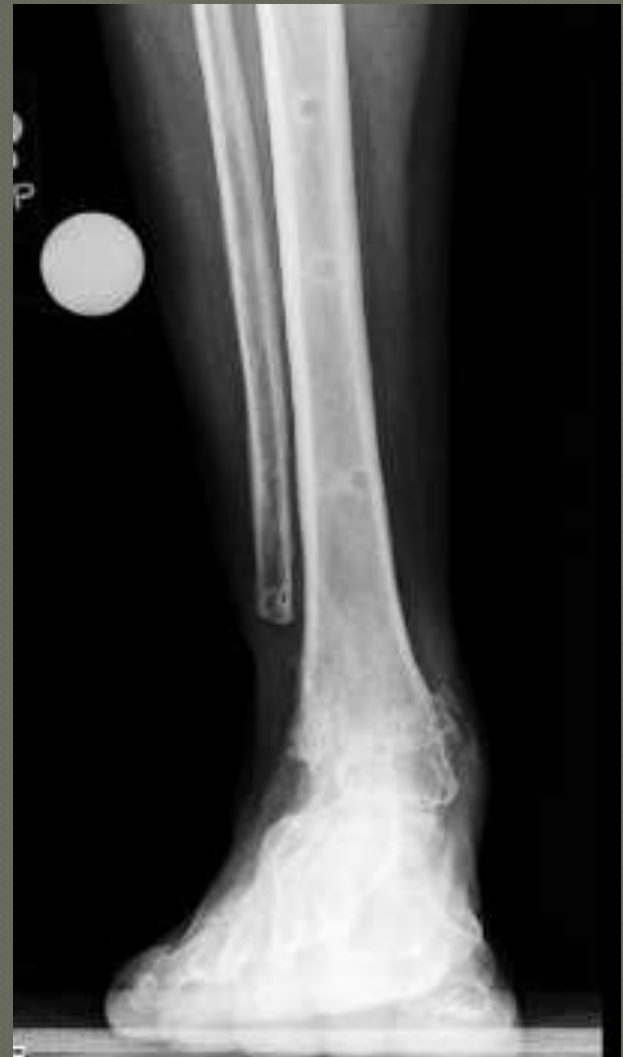
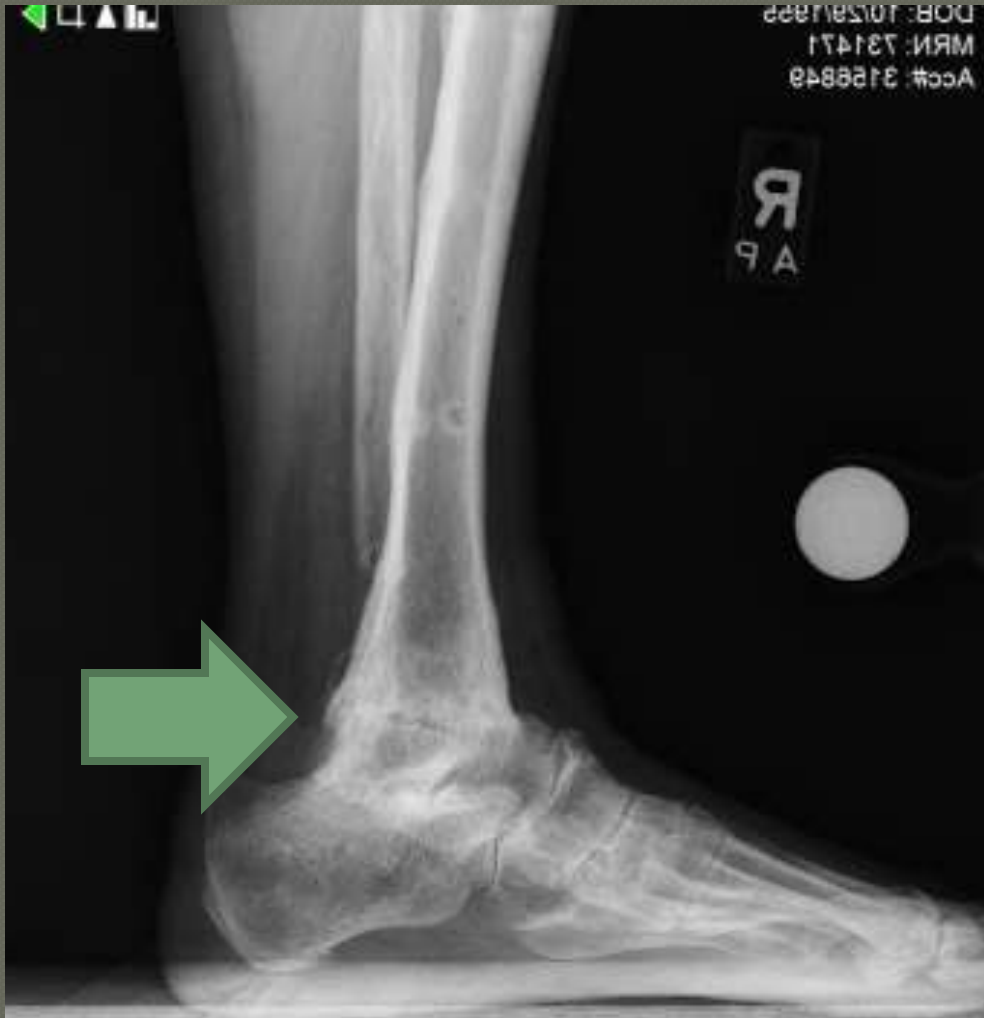


Temporary wires

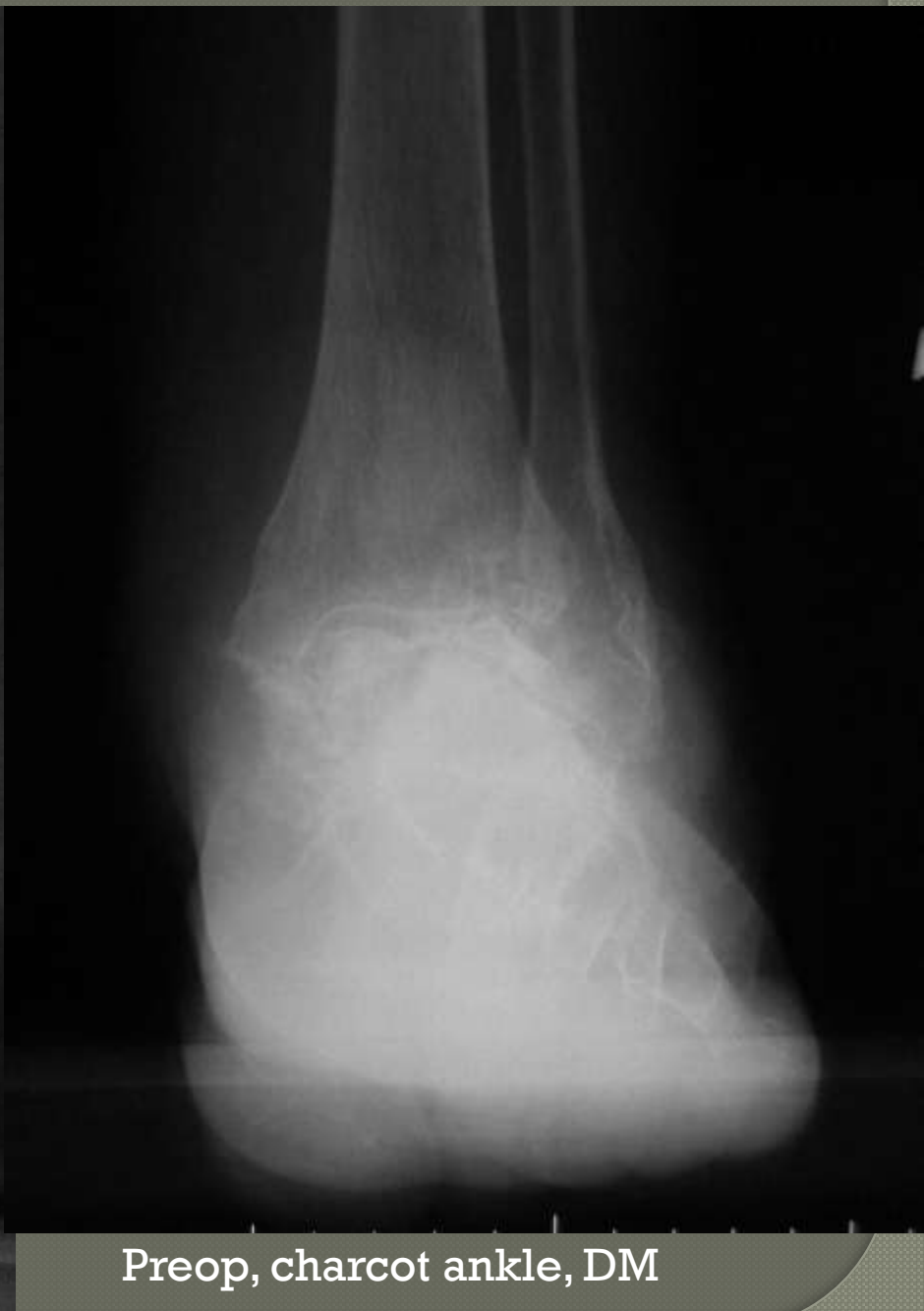
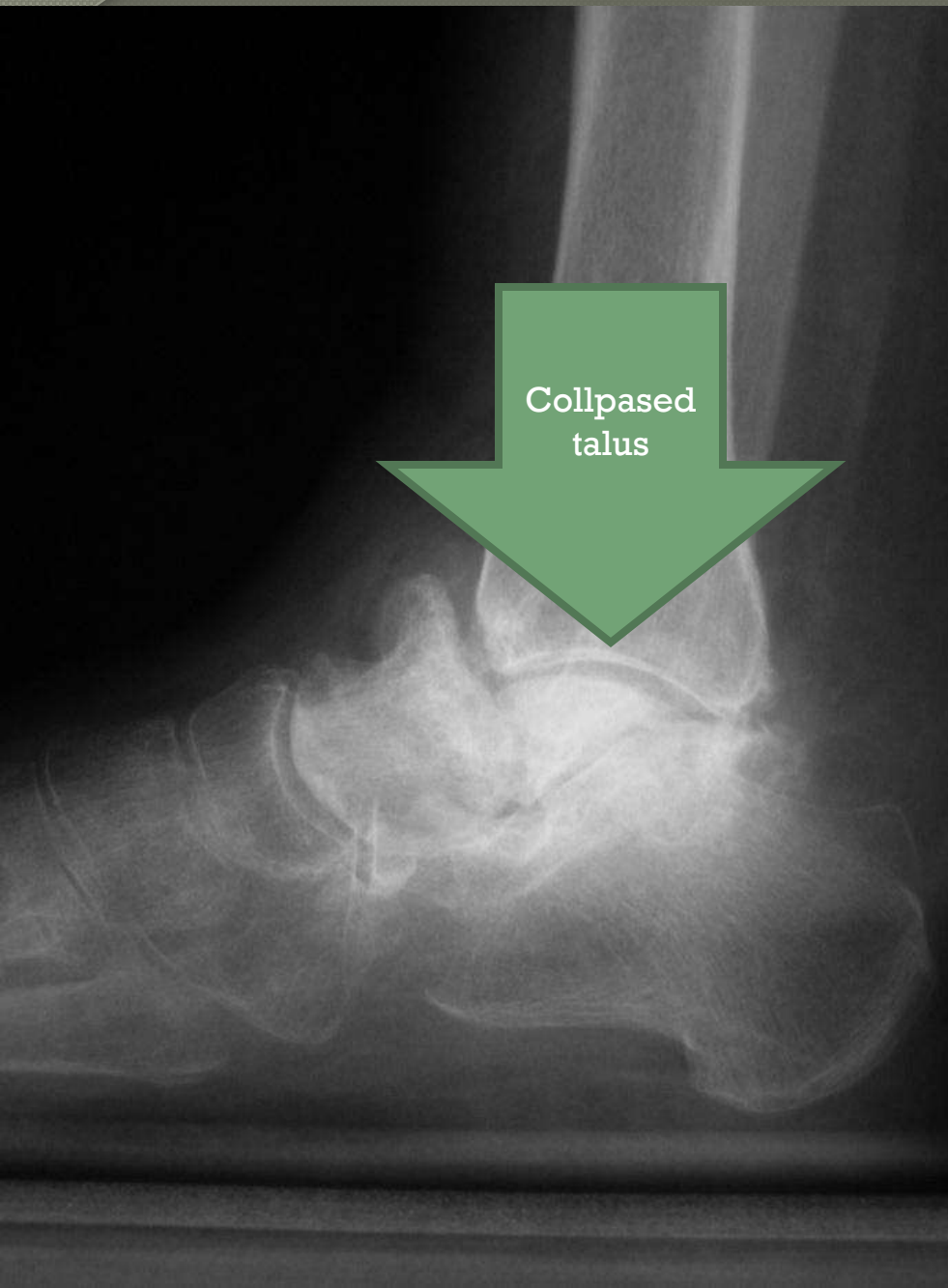
# After: Solid ankle/ST Fusion







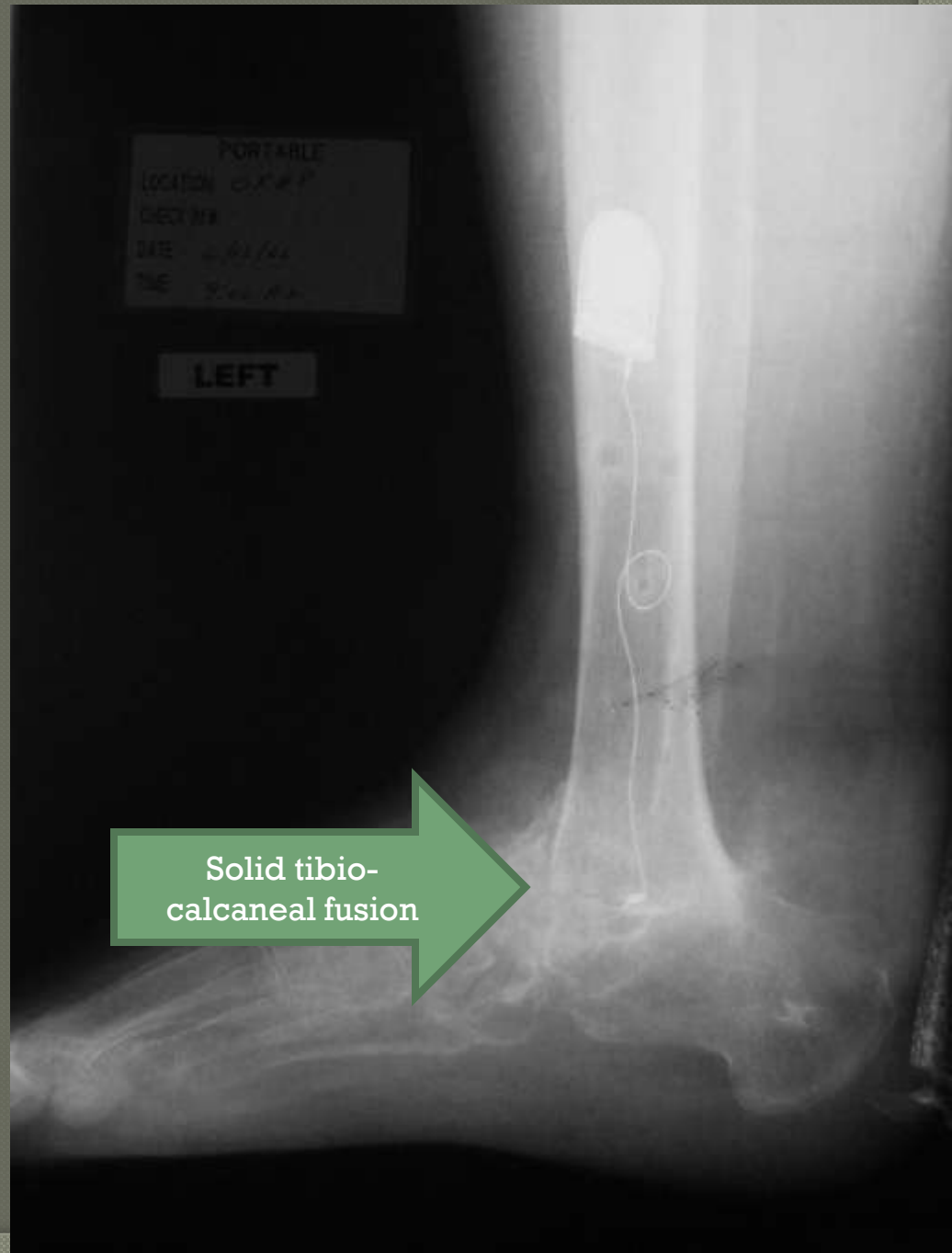
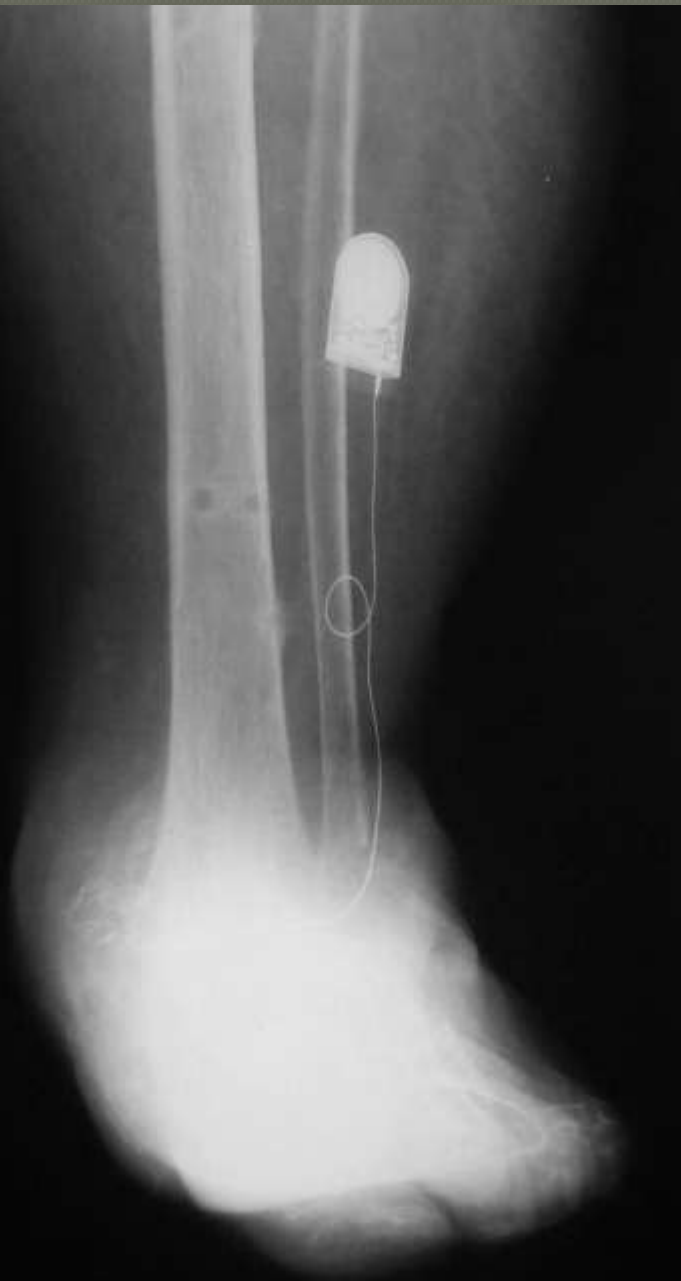


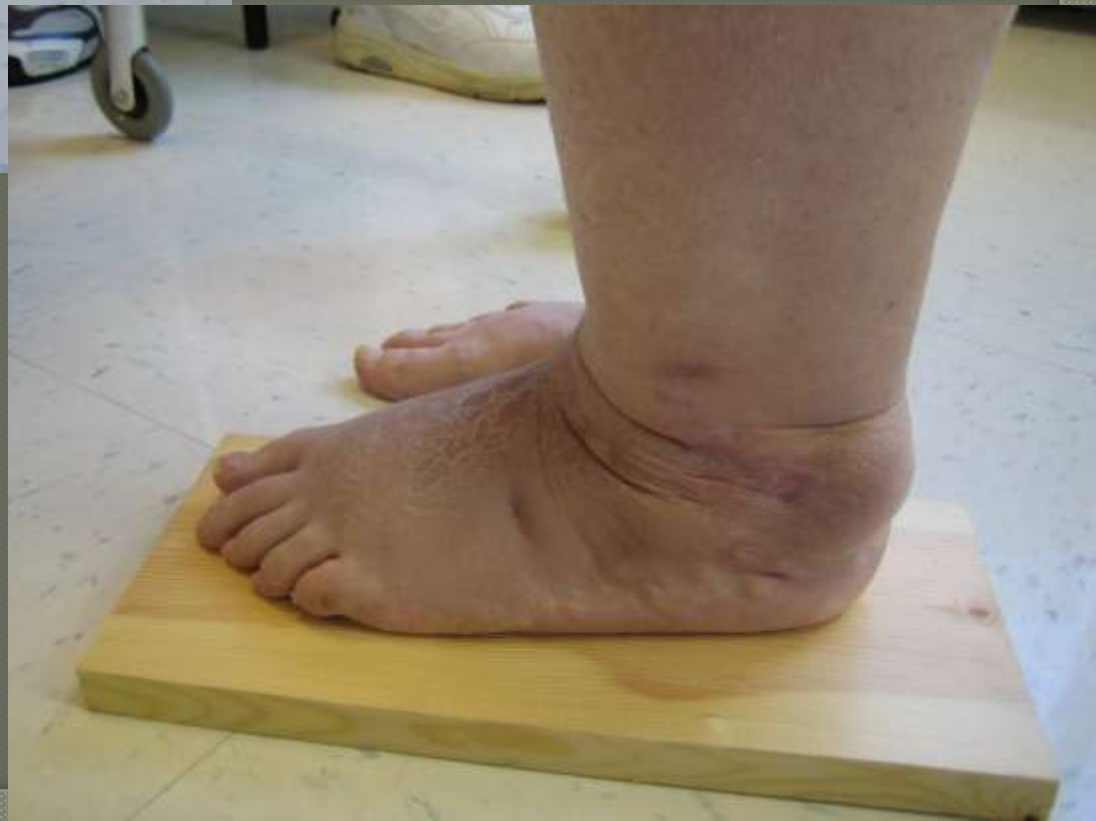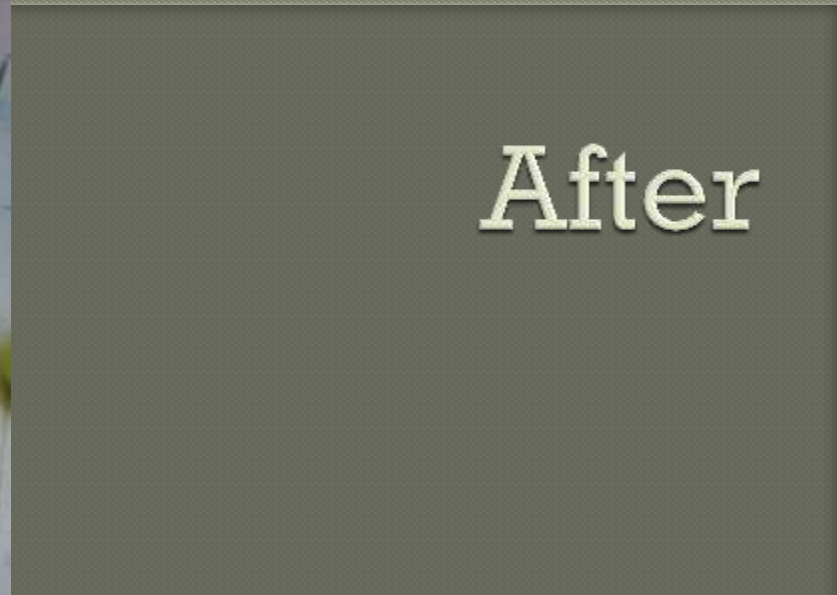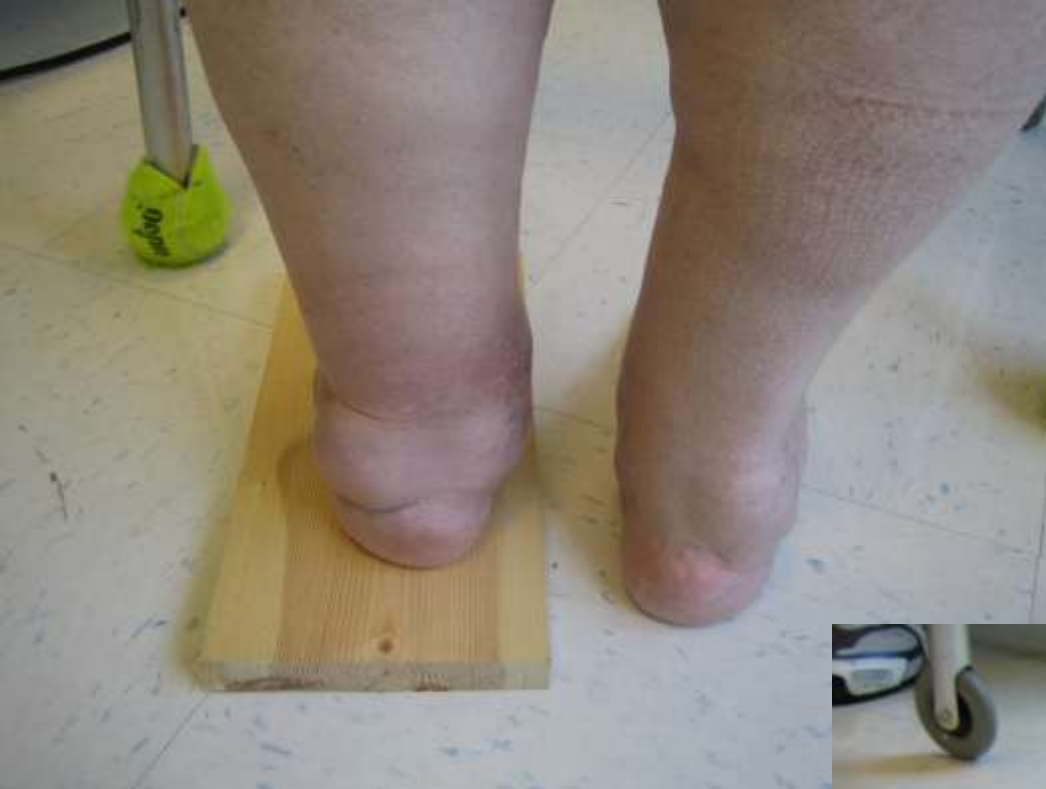Preop, charcot ankle, DM



Before frame removal

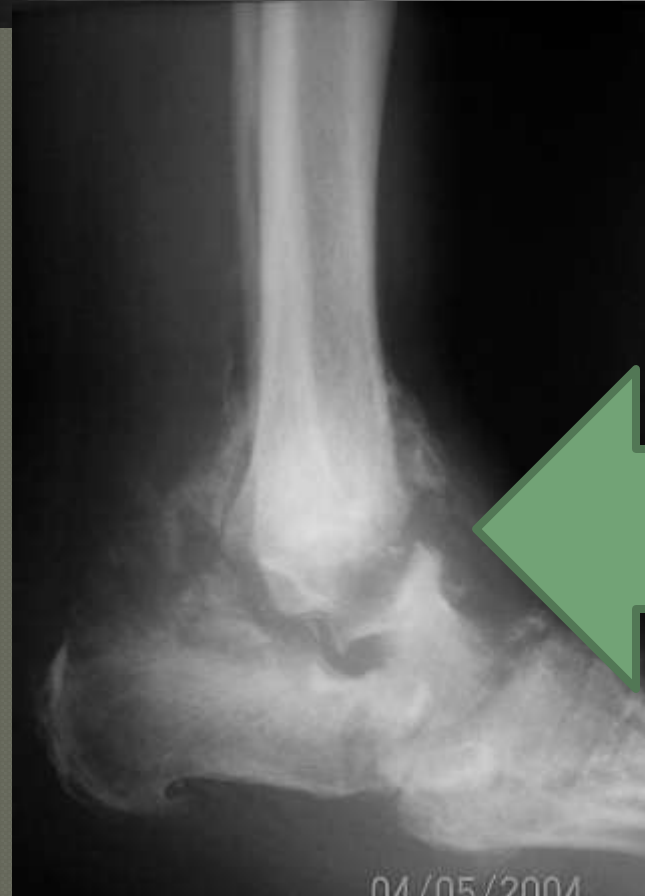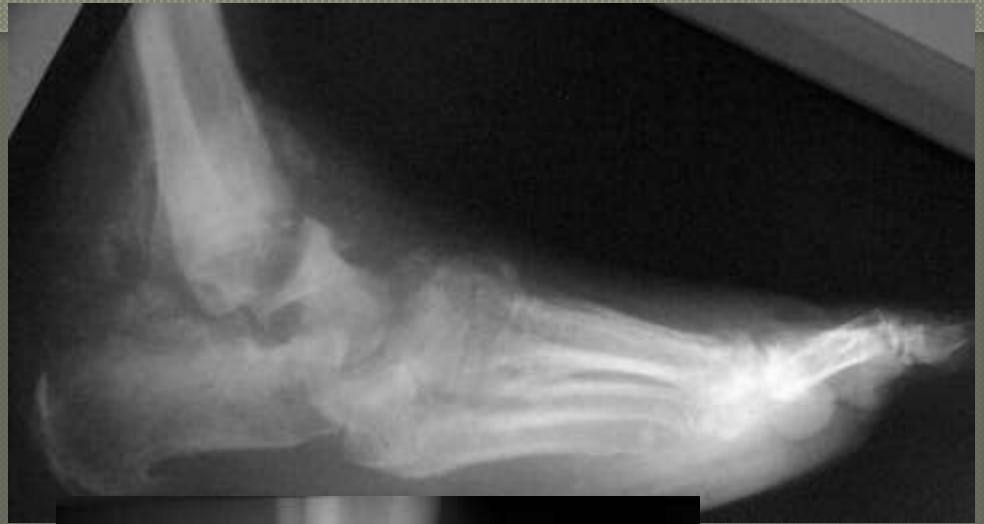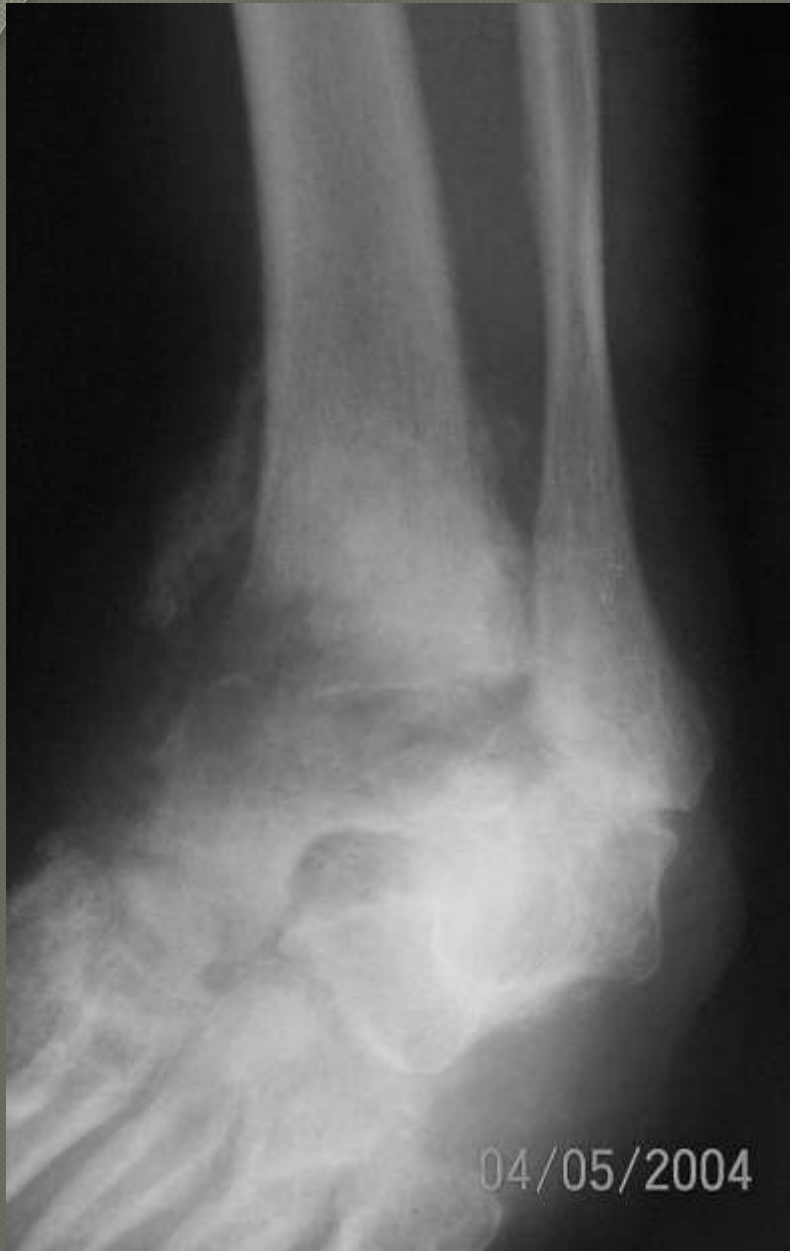AFTER



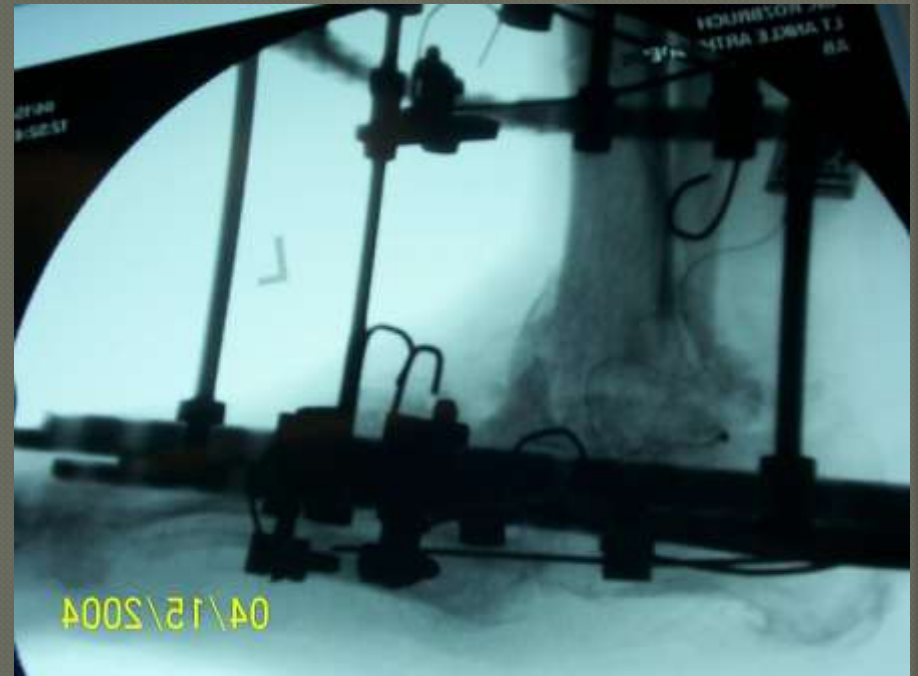
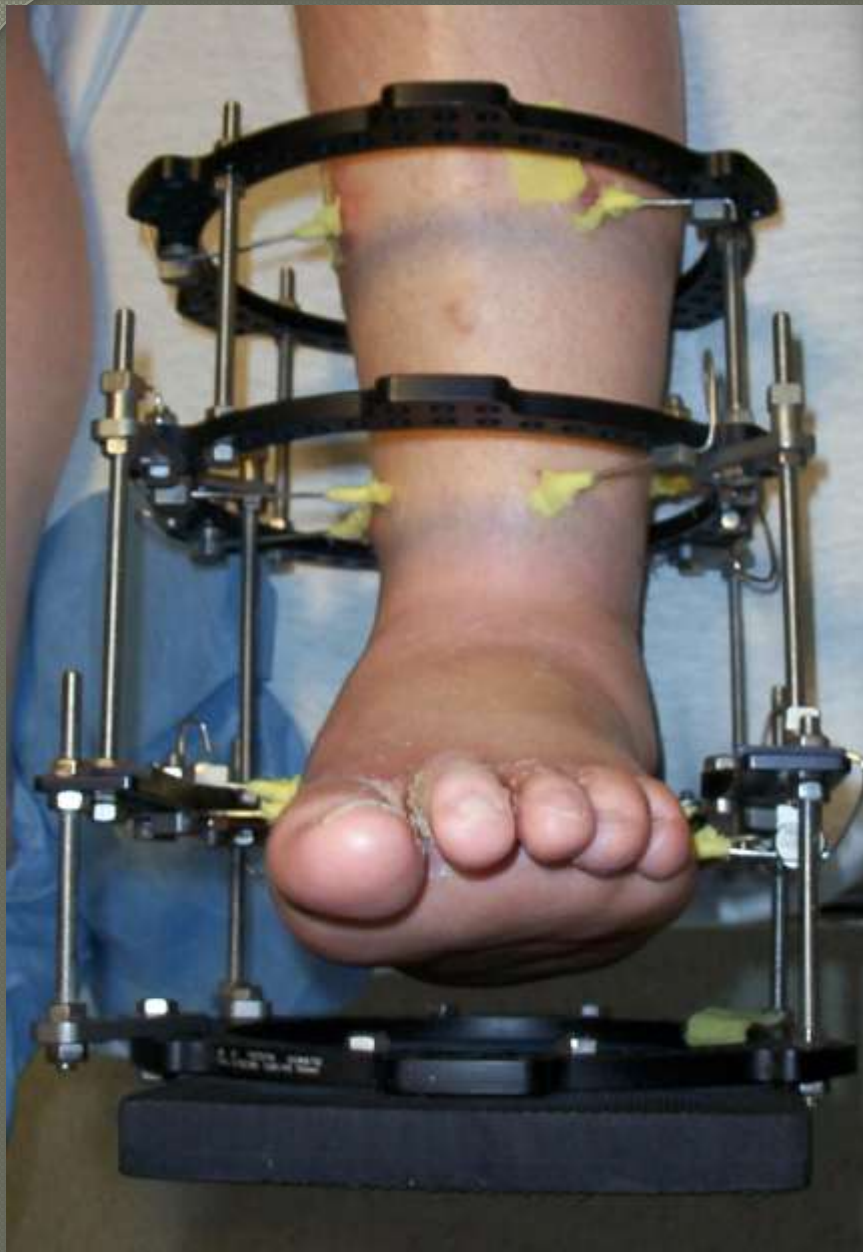
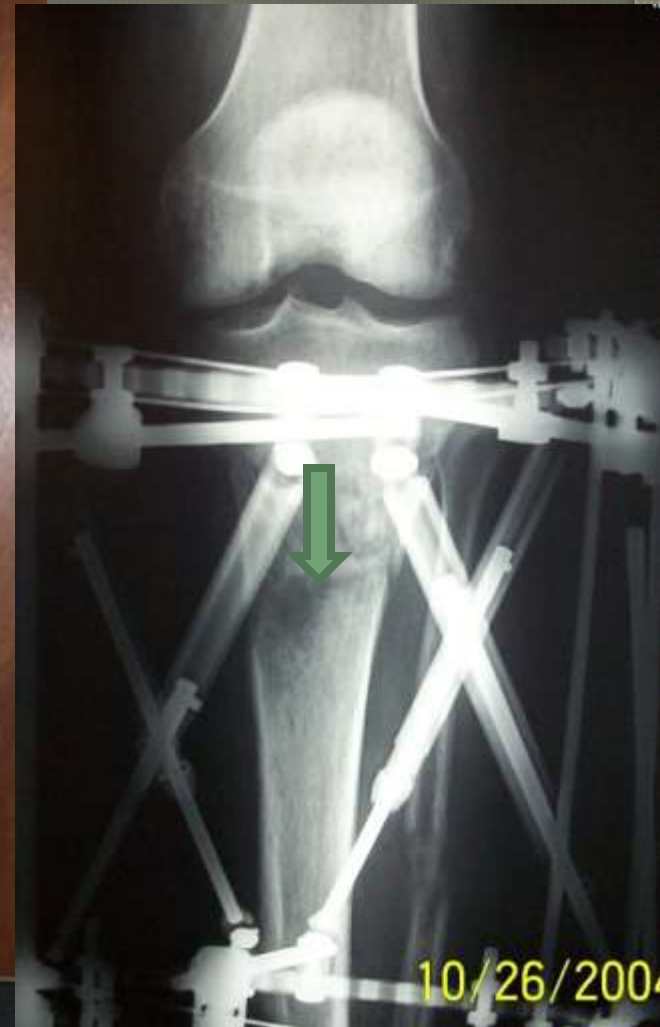Plantigrade foot  
LLD 3 cm (missing talus)





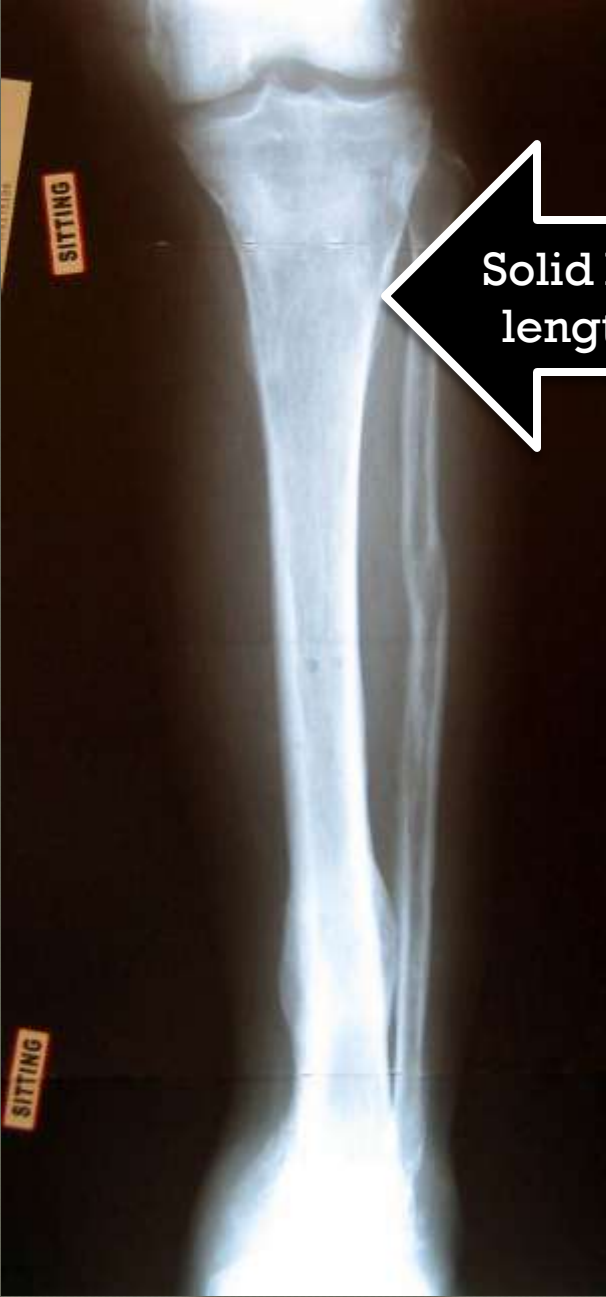← Before



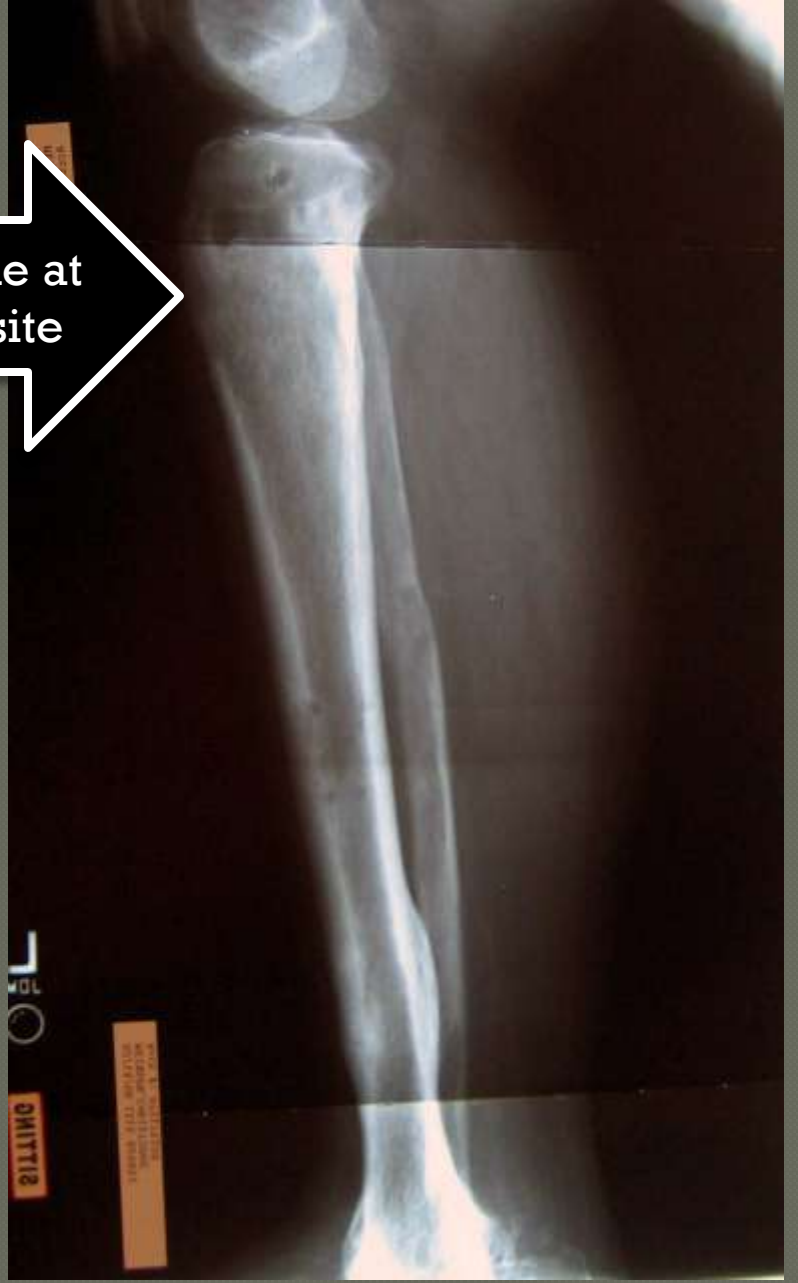






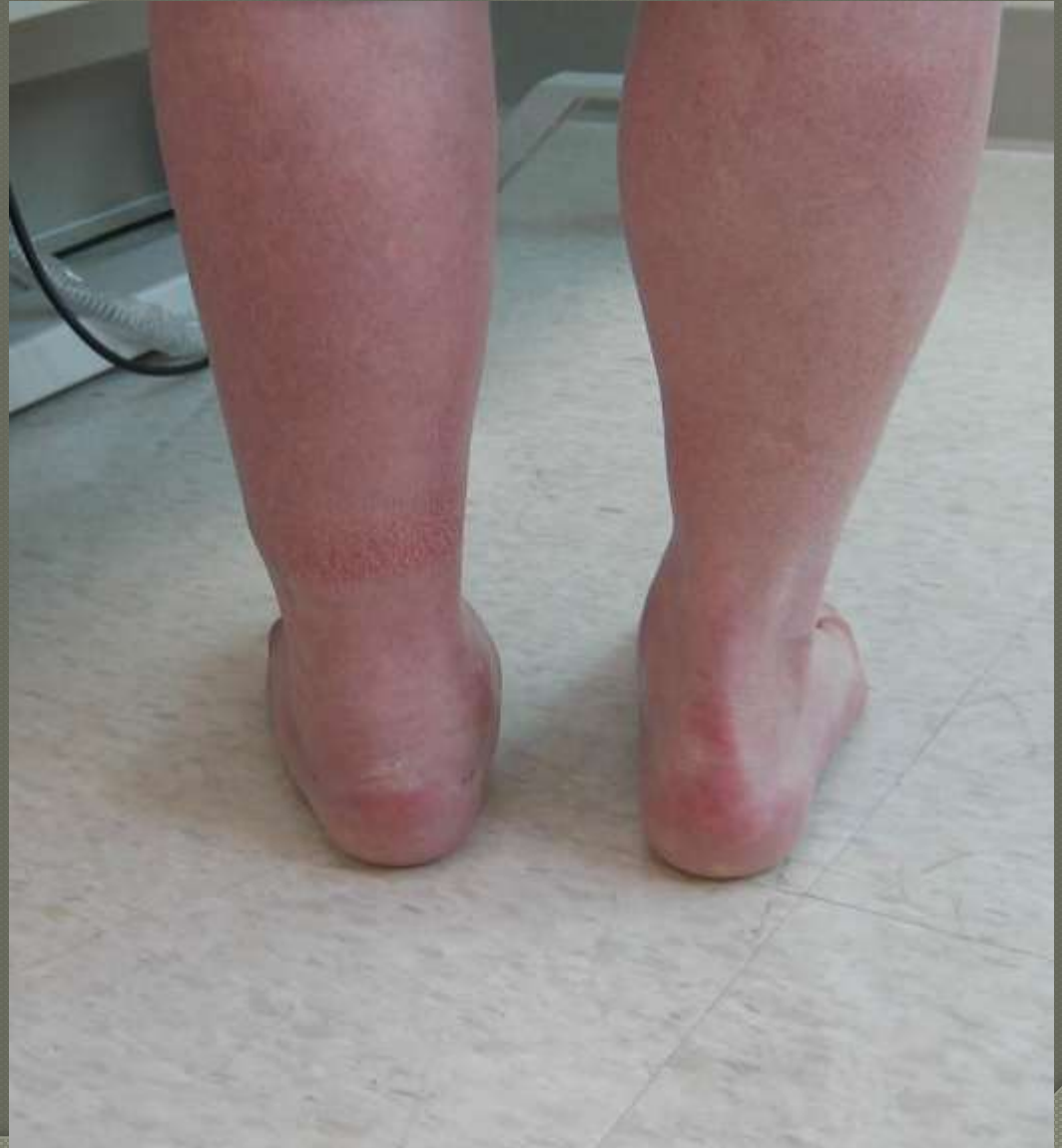
Solid New Bone at lengthening site

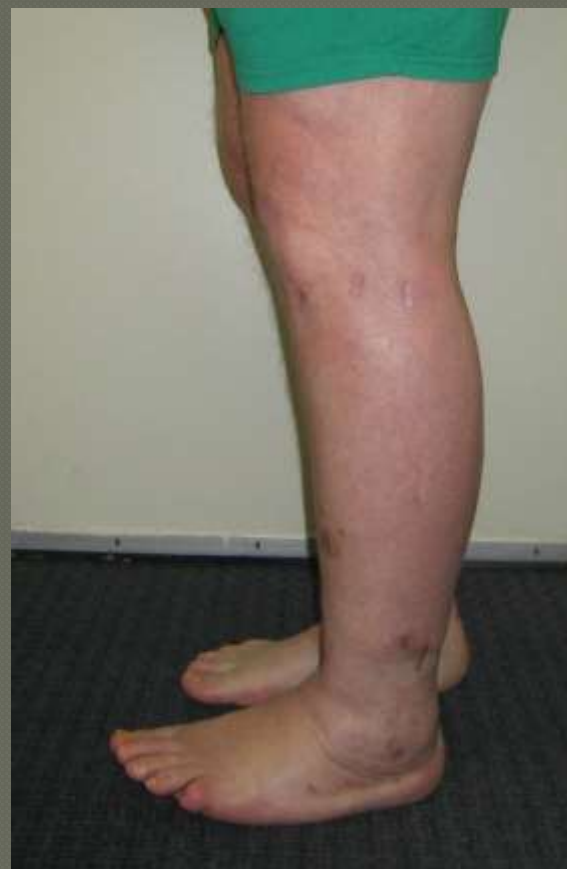
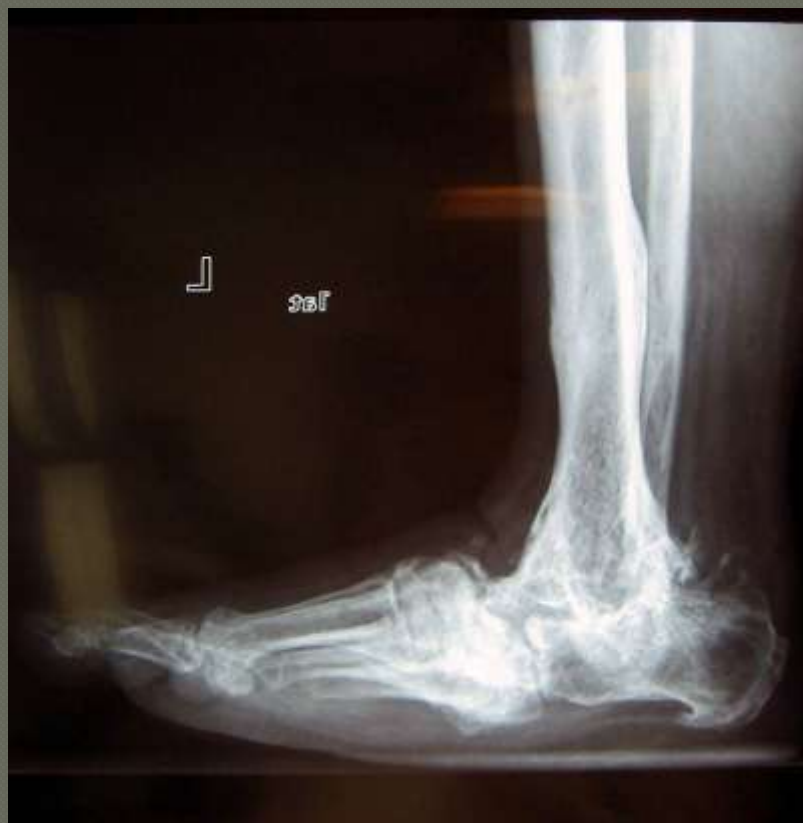


After: no LLD

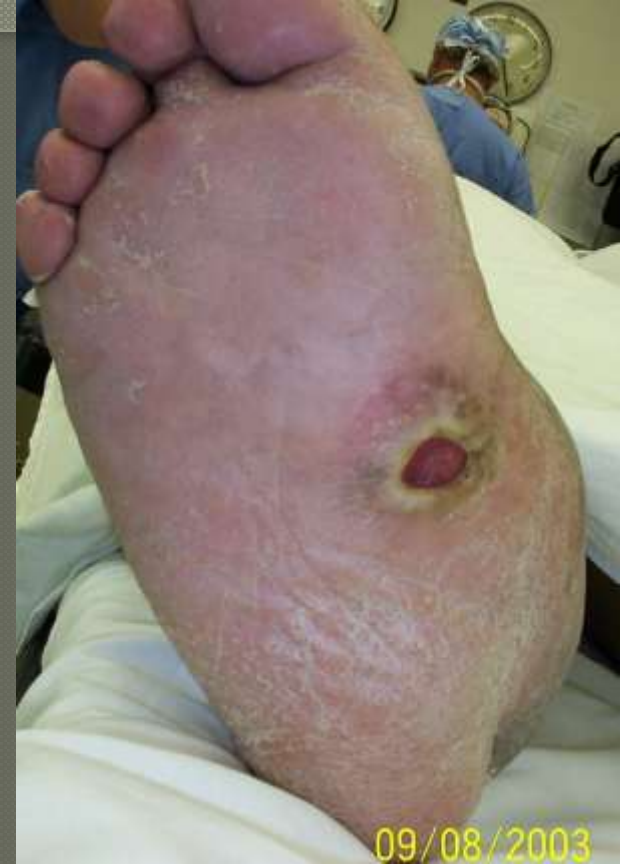
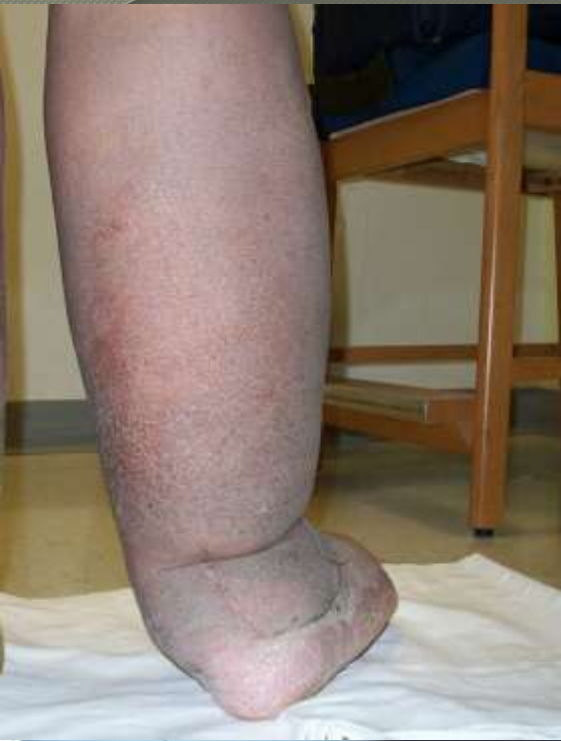
# After: Plantigrade foot

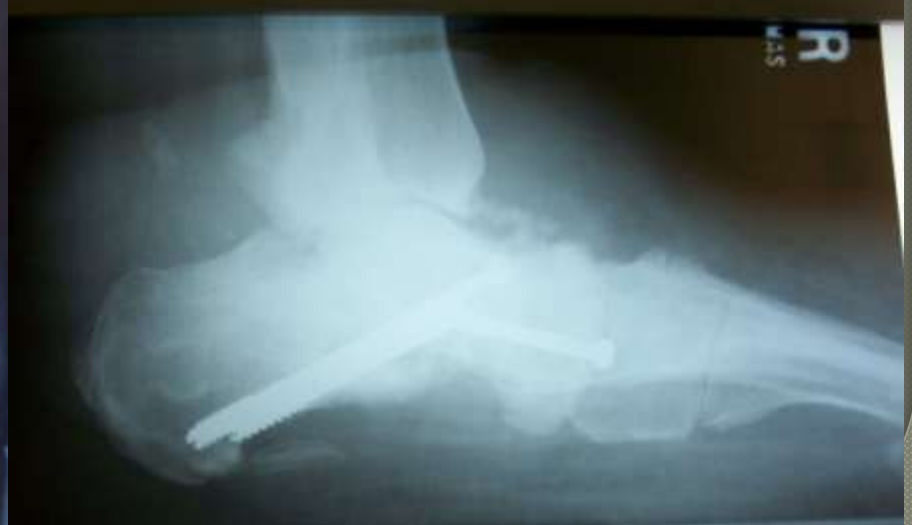
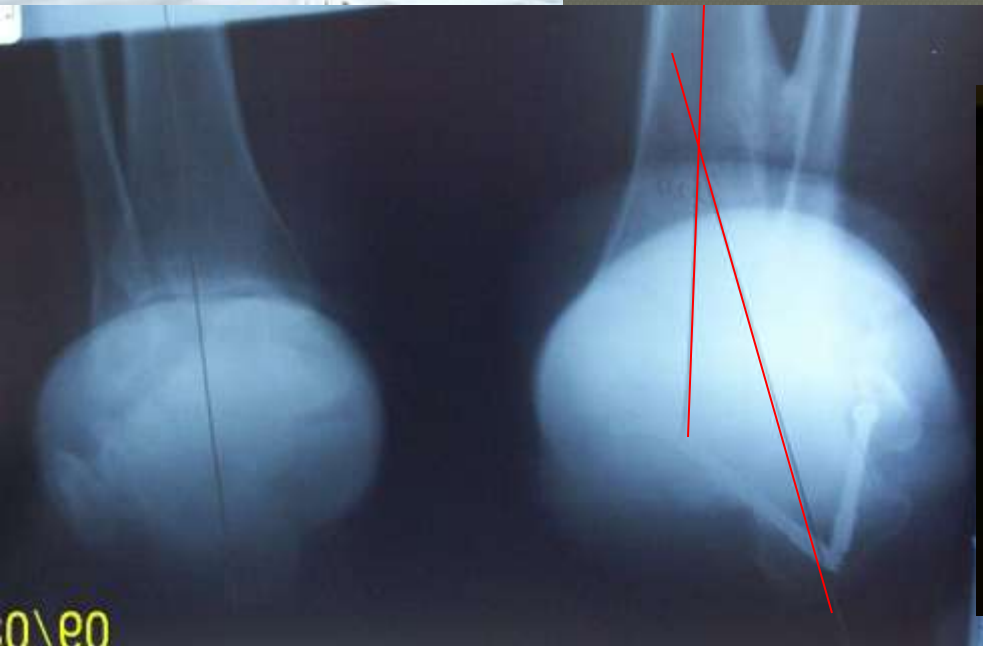
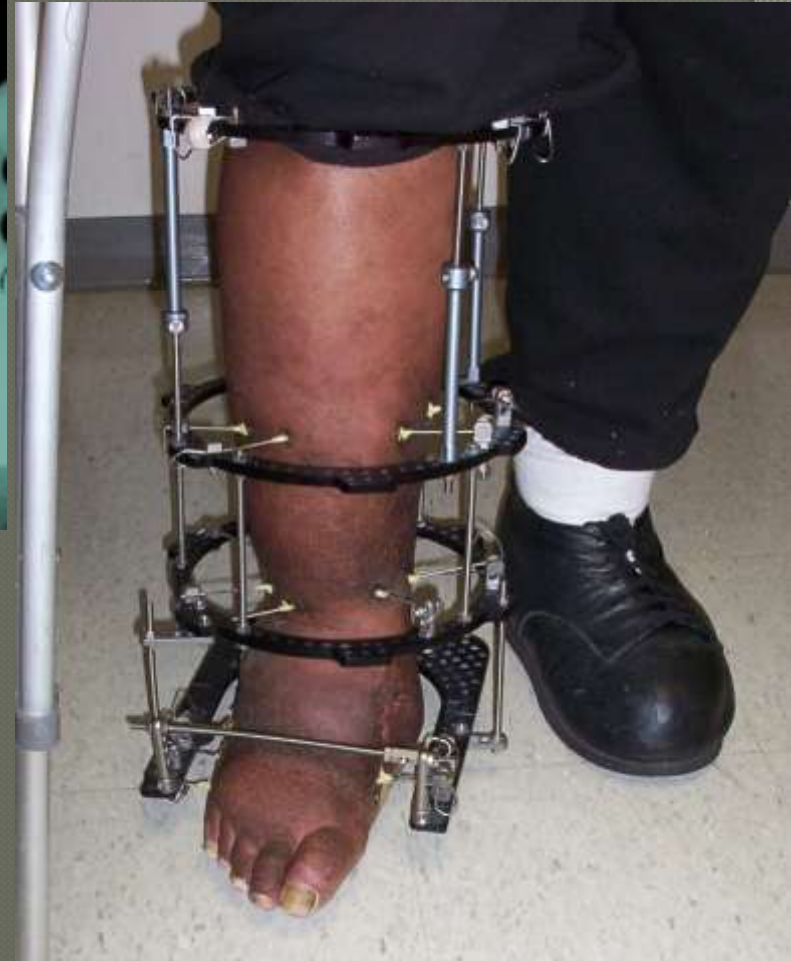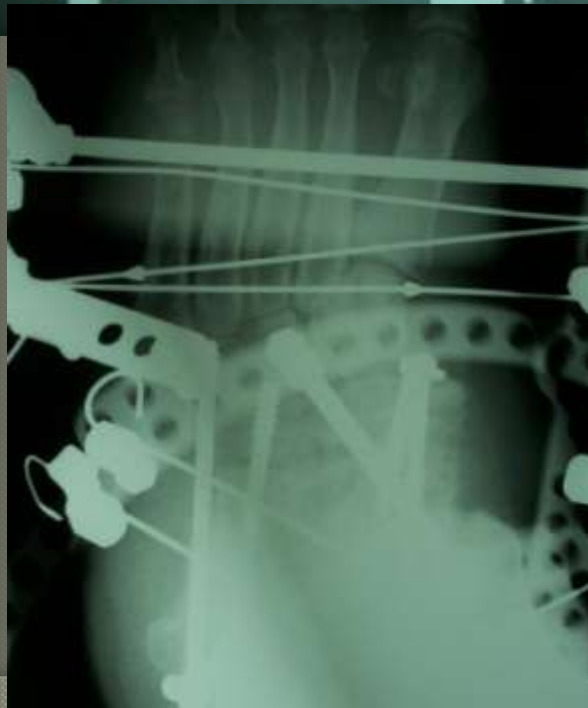



# Before Hindfoot valgus

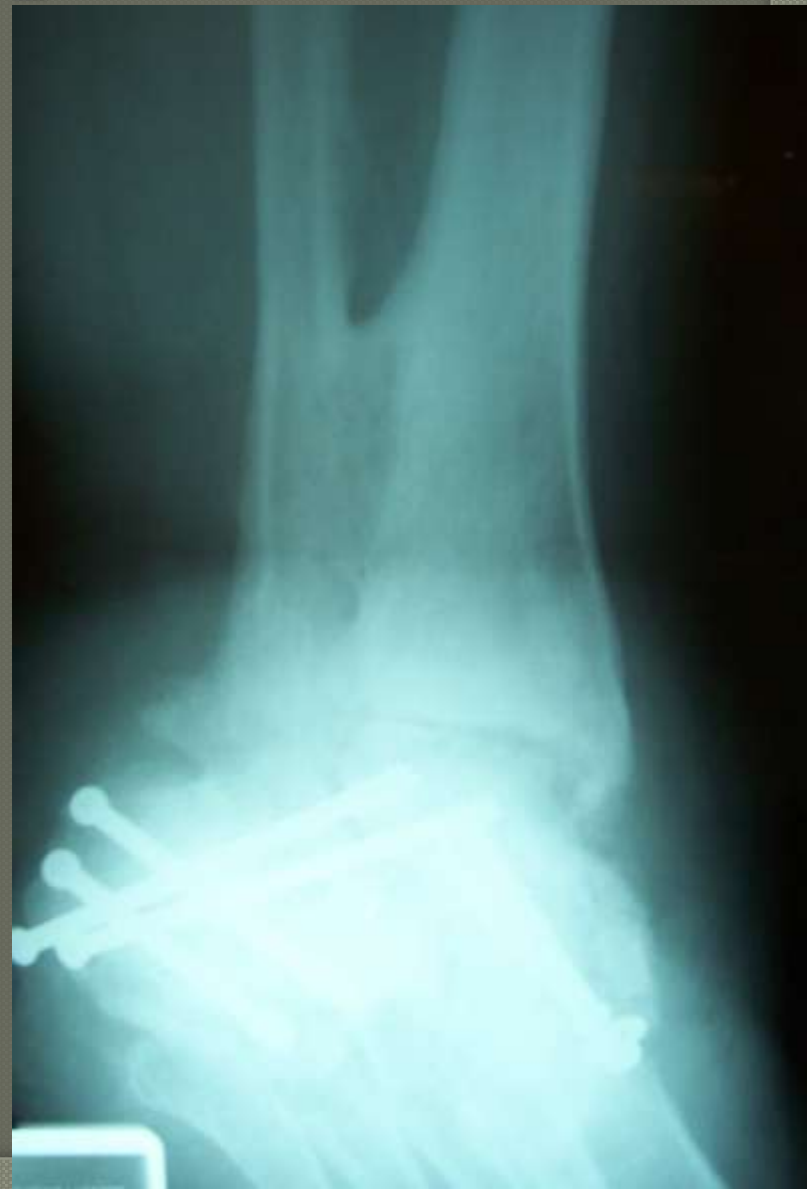
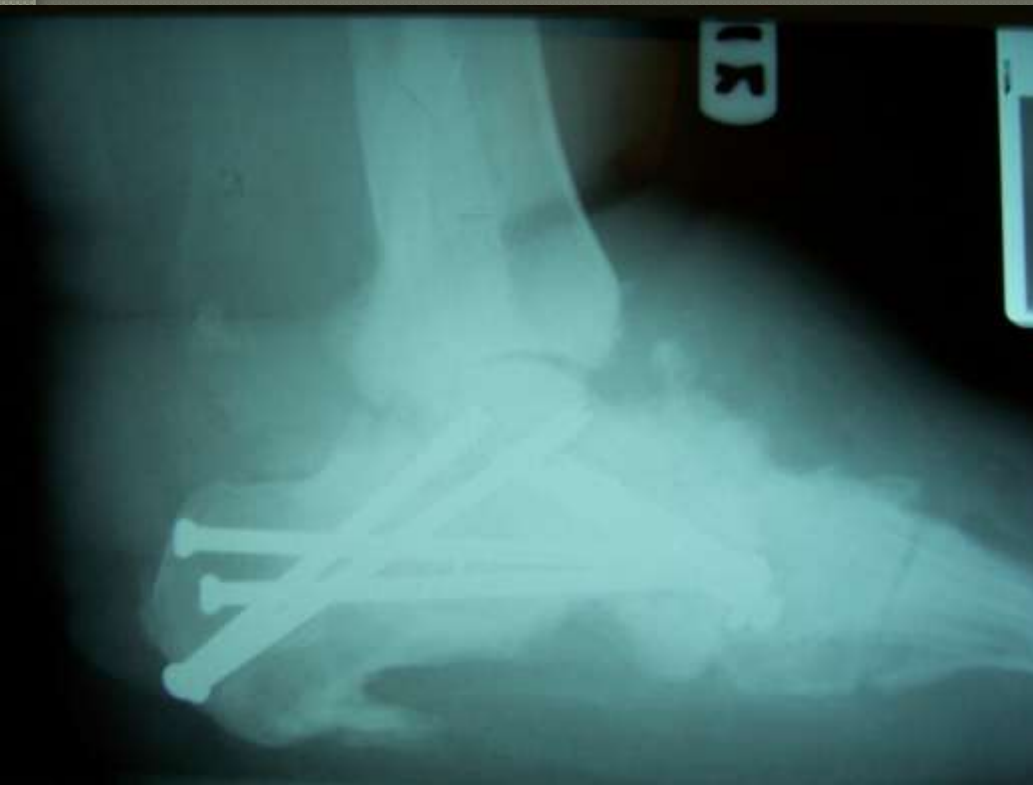
09/08/2003



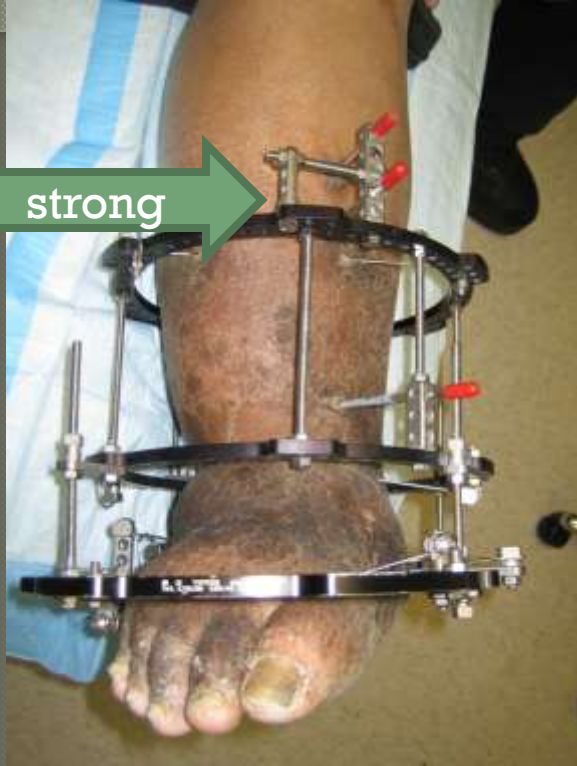

collapse

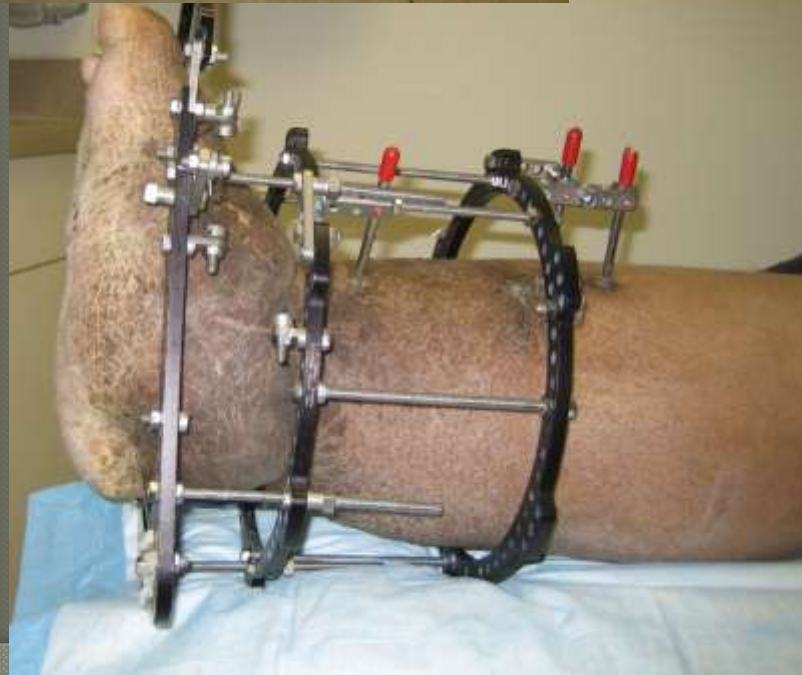



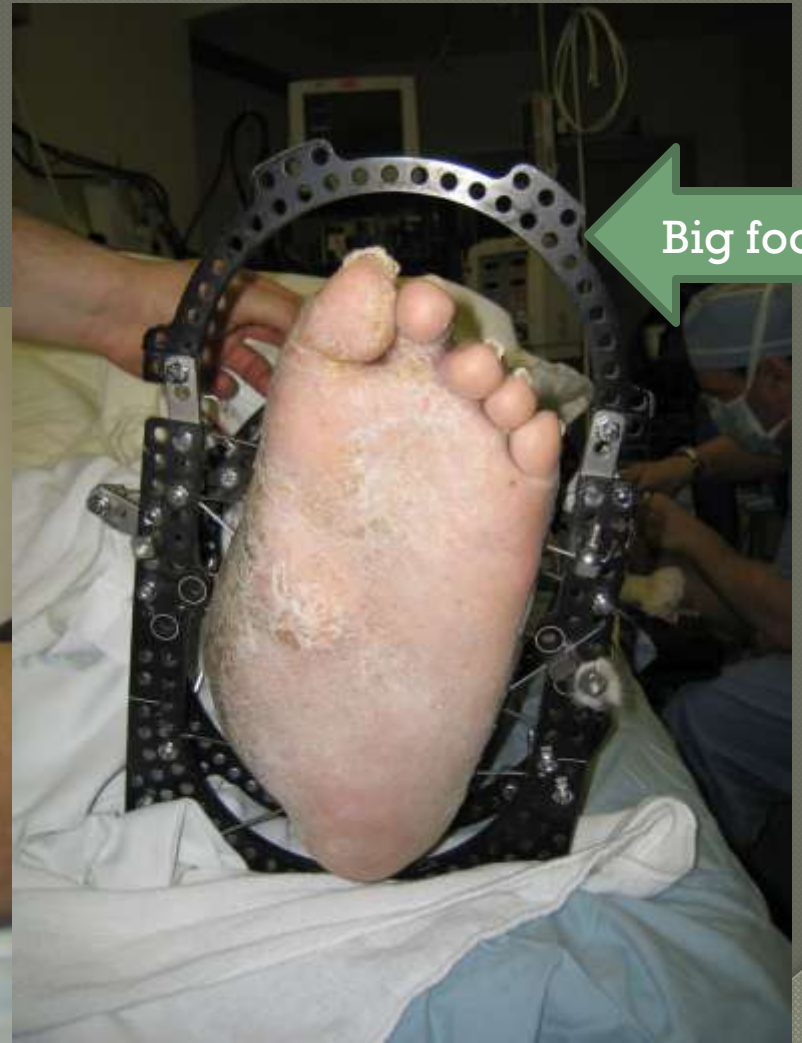strong

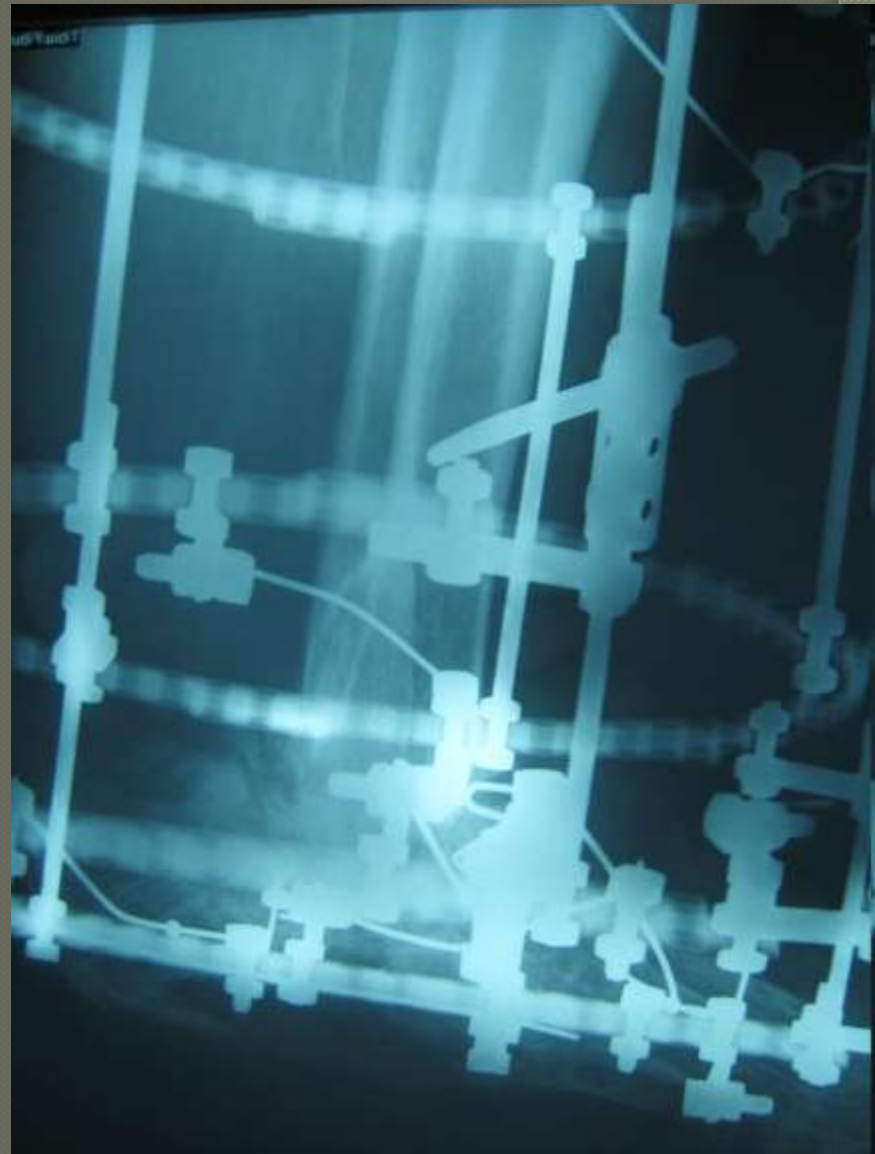
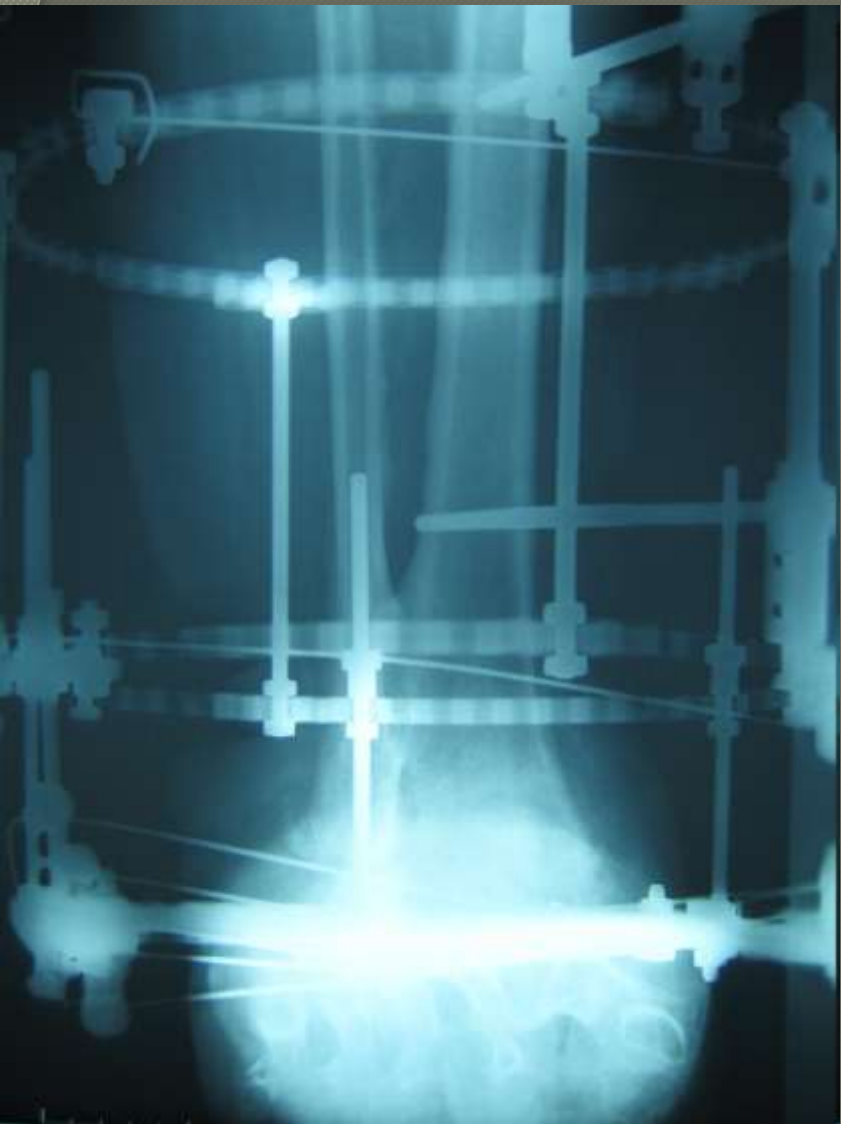

# Add Ankle fusion

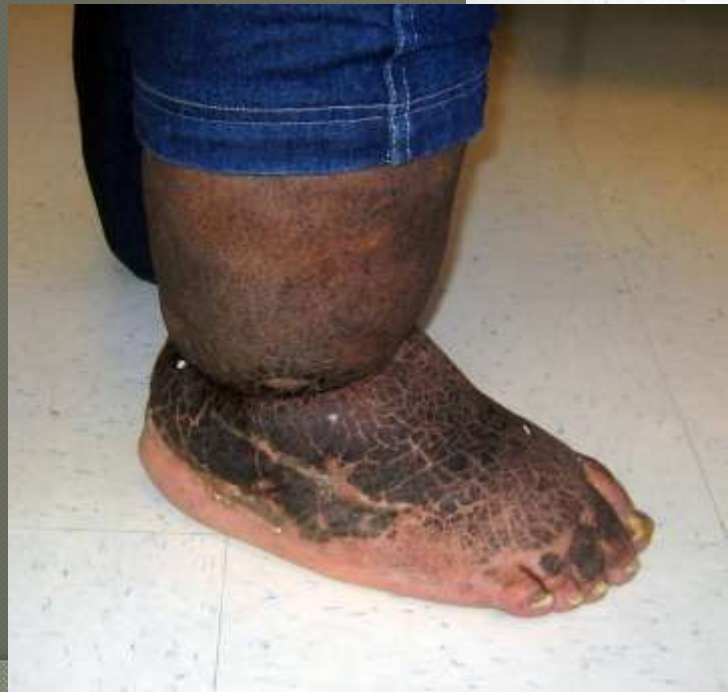
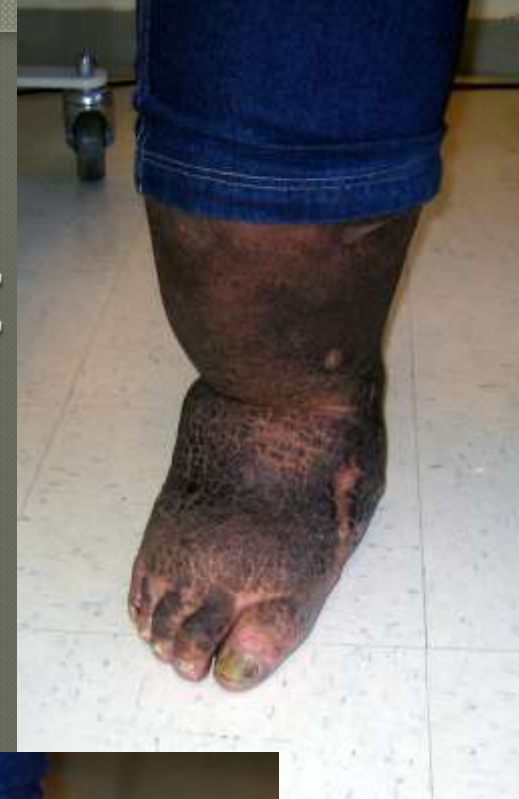
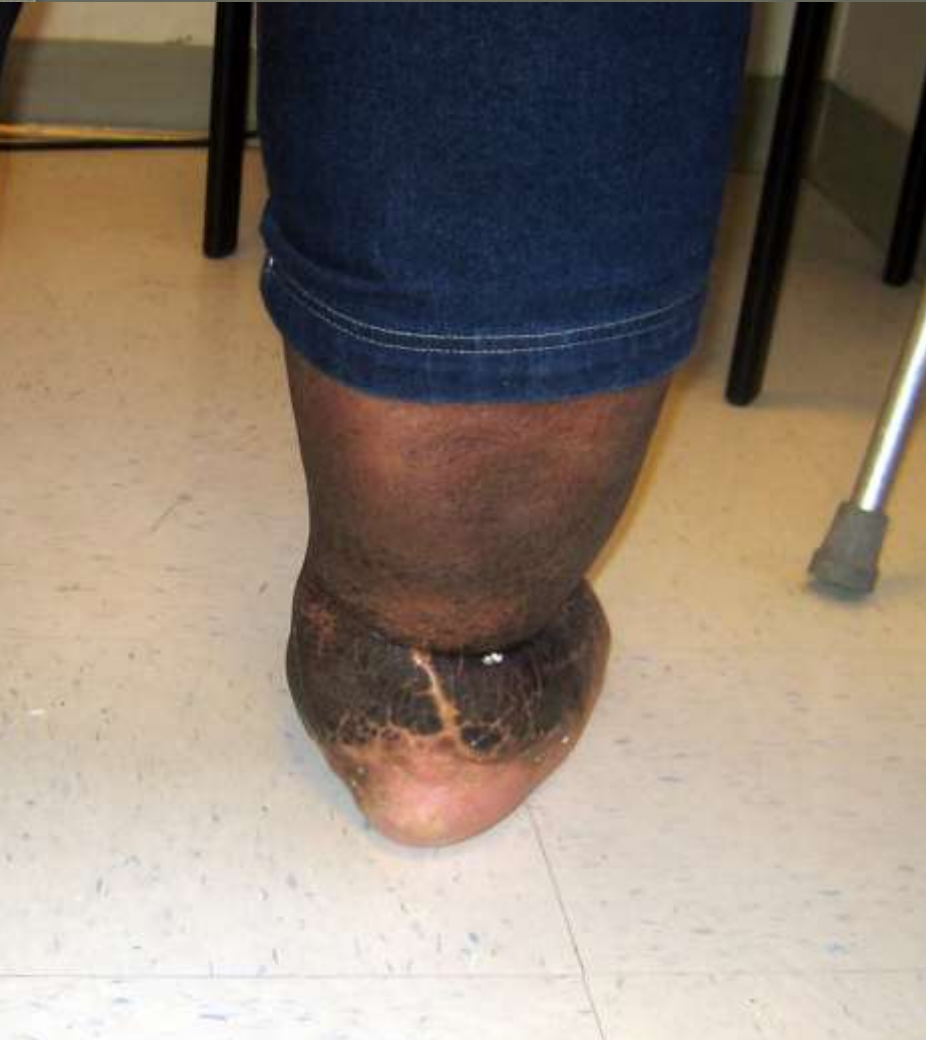Big foot

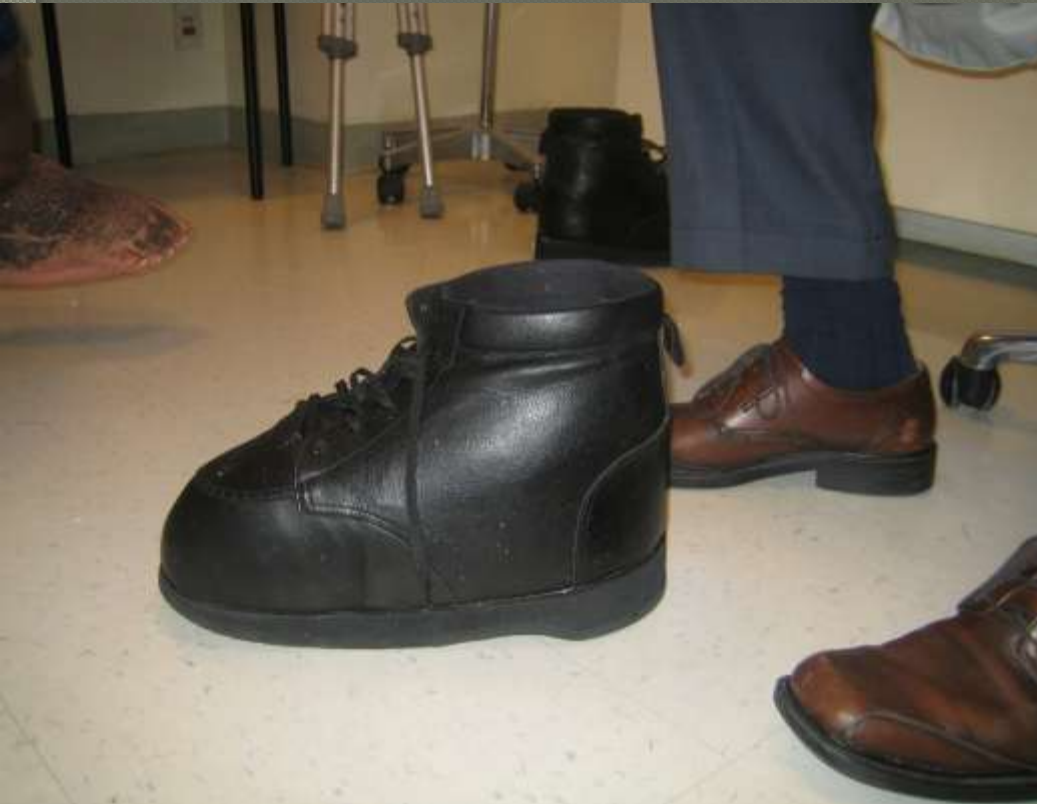



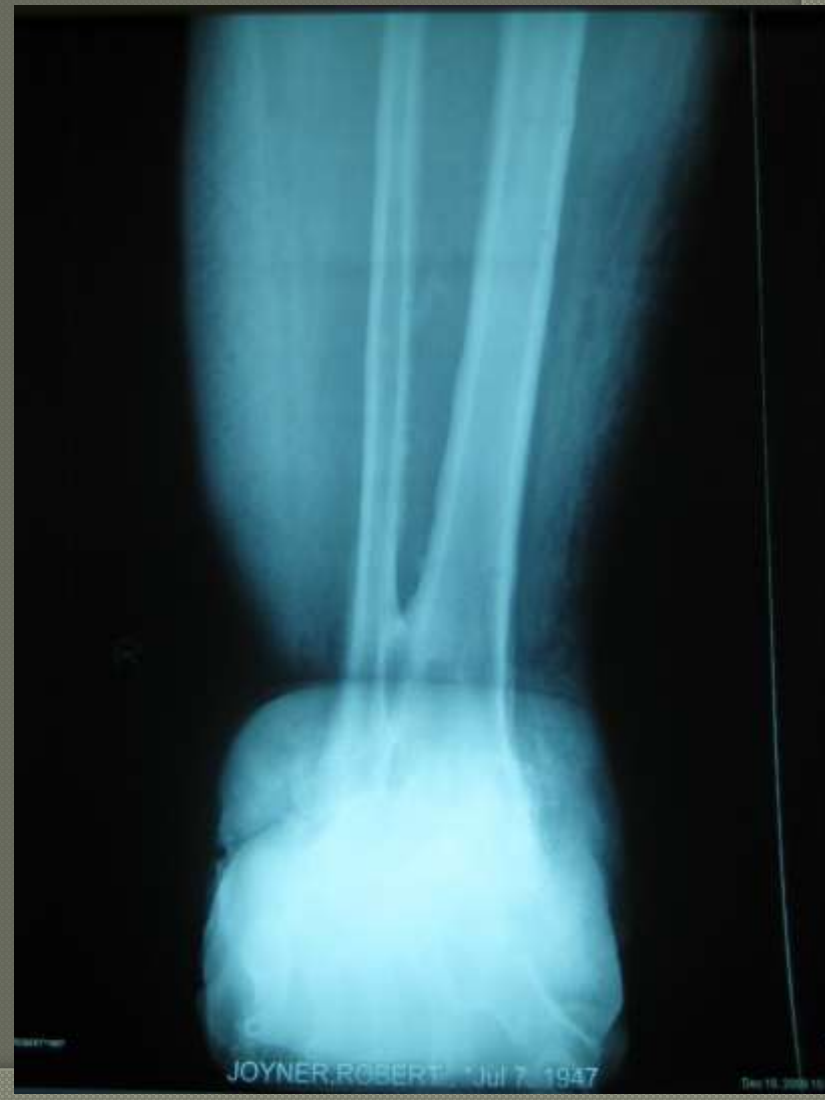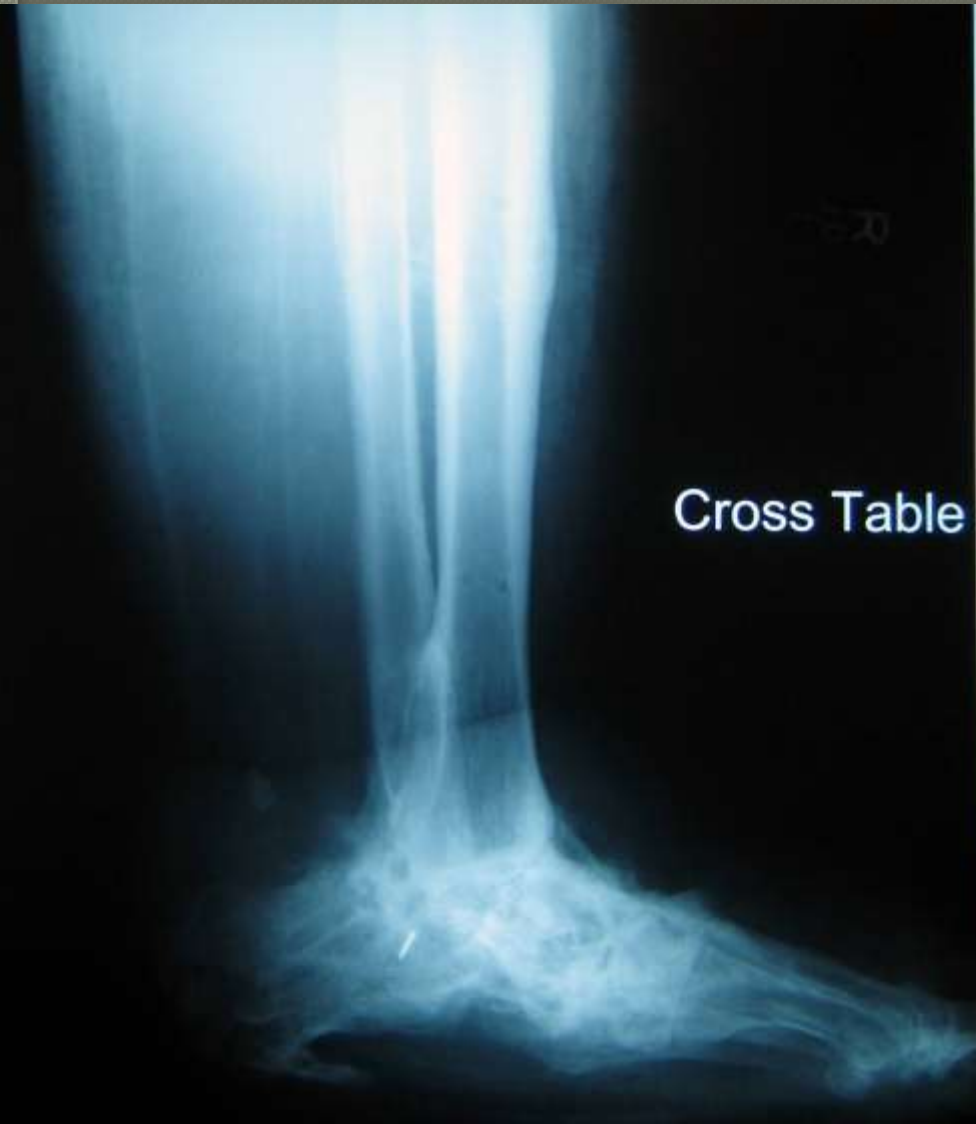After: plantigrade foot



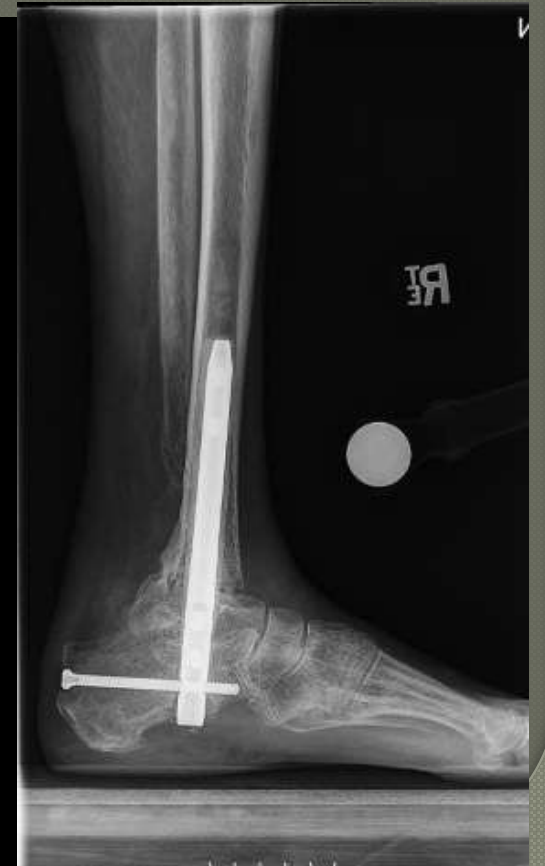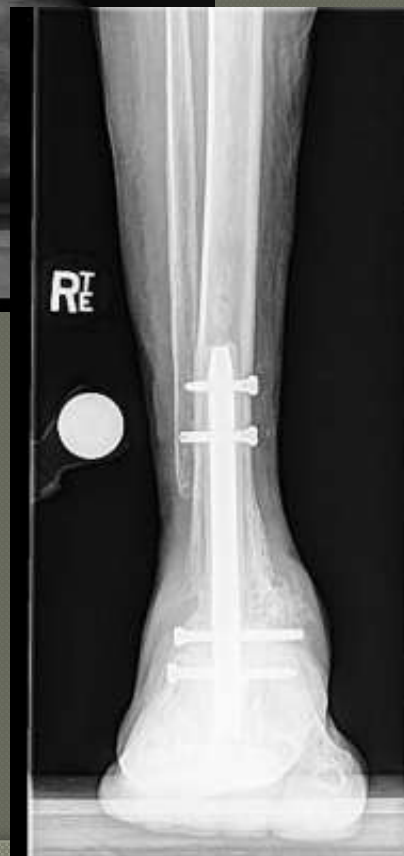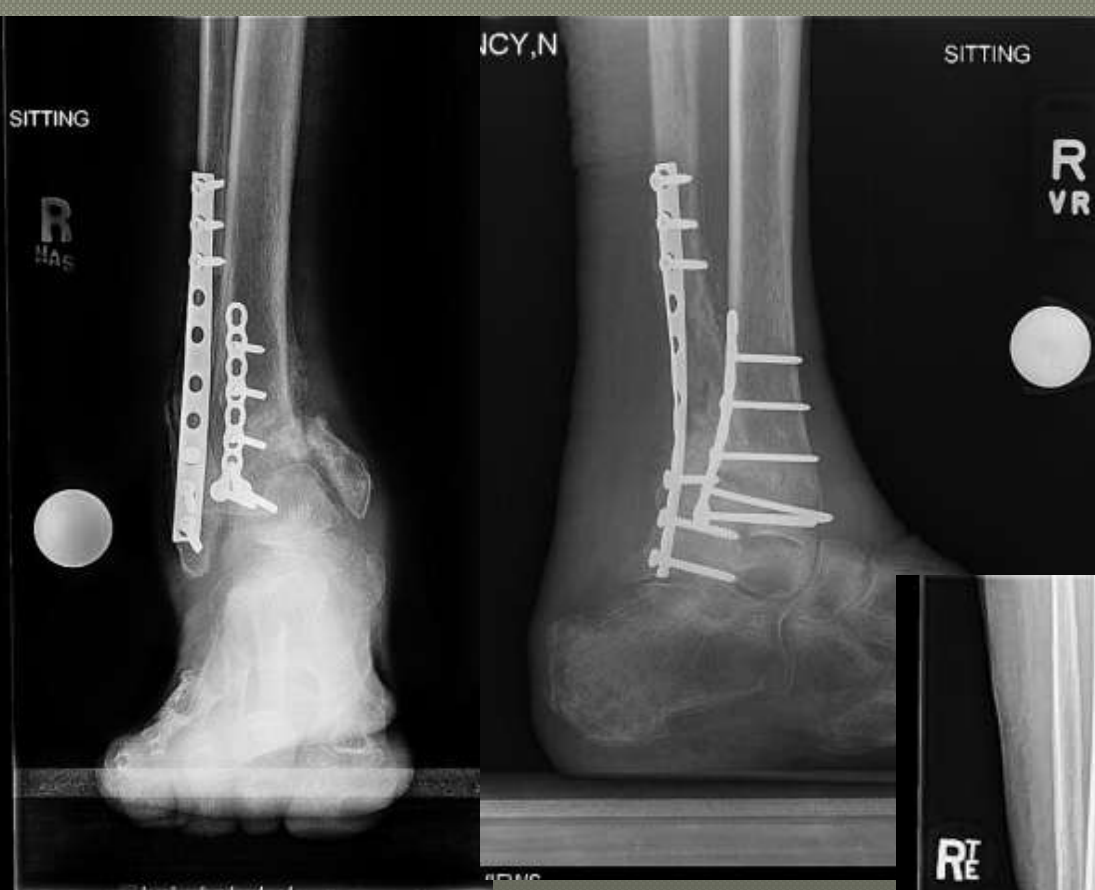# Custom shoe needed

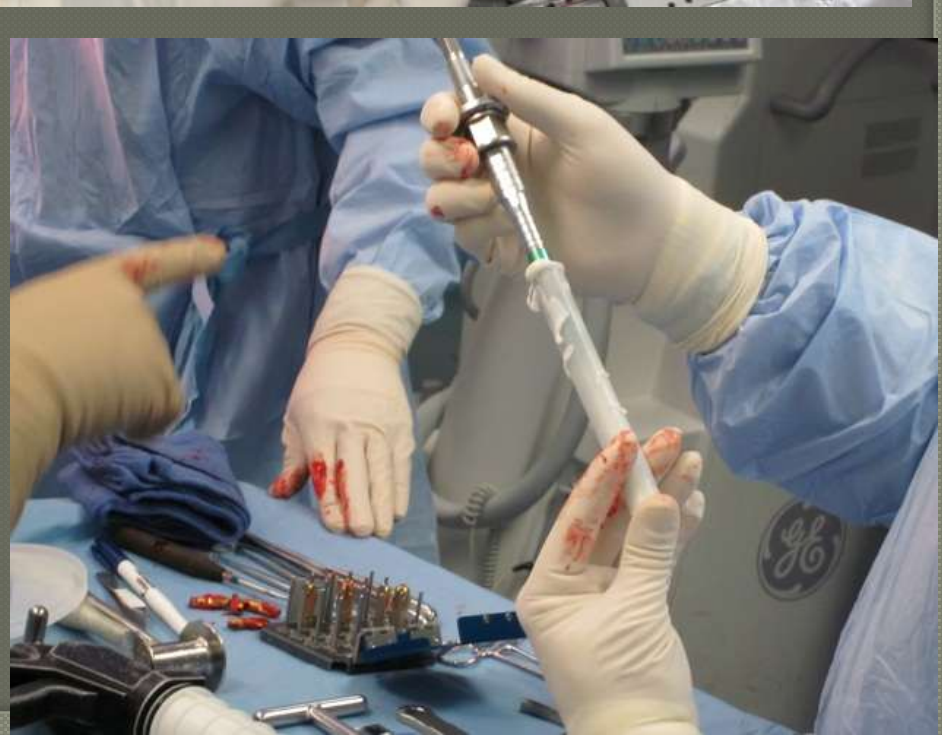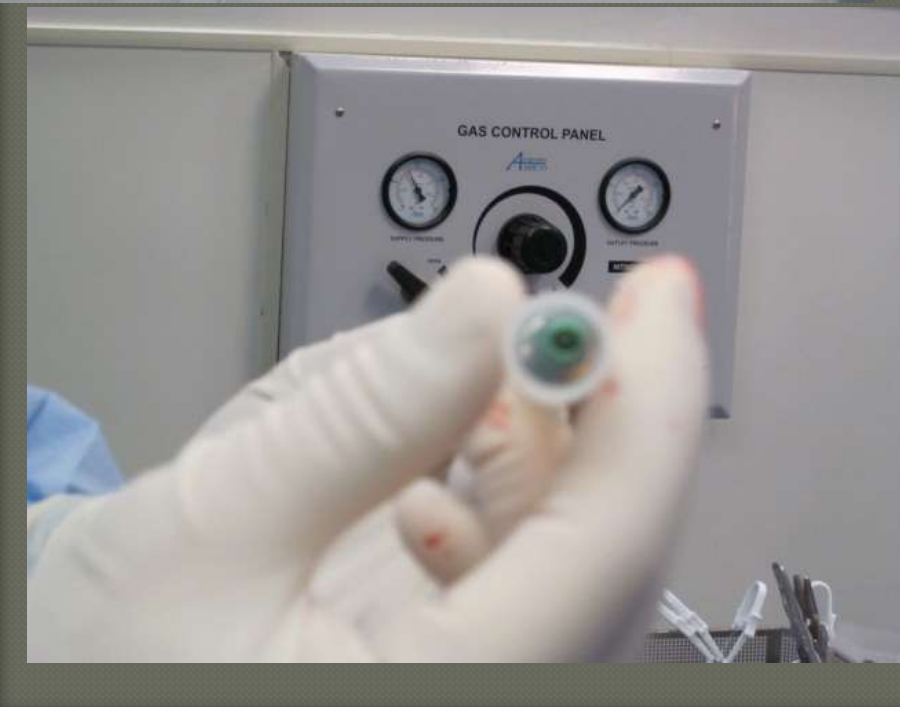

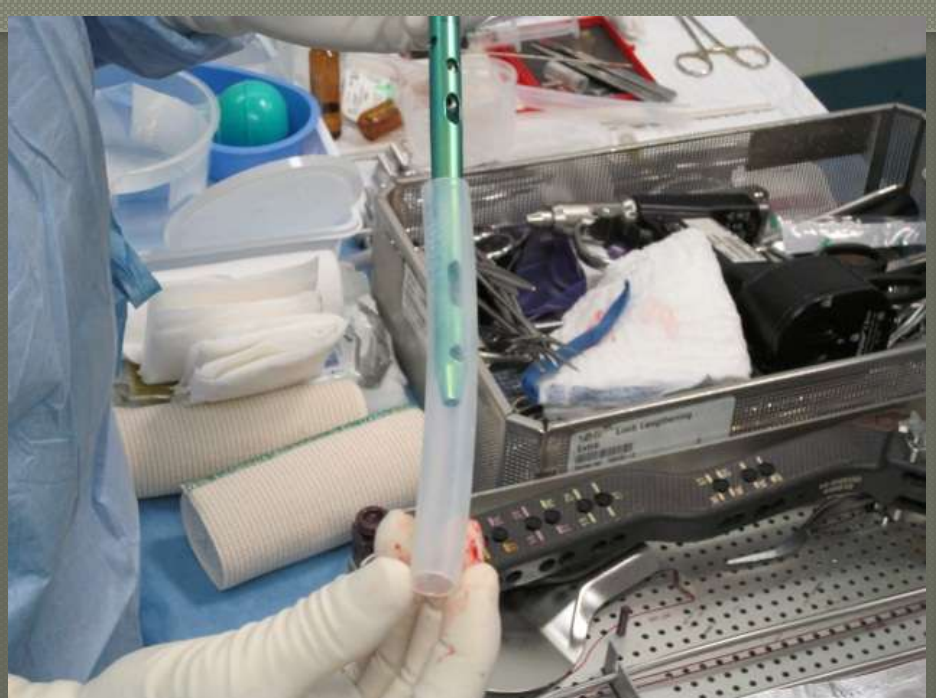
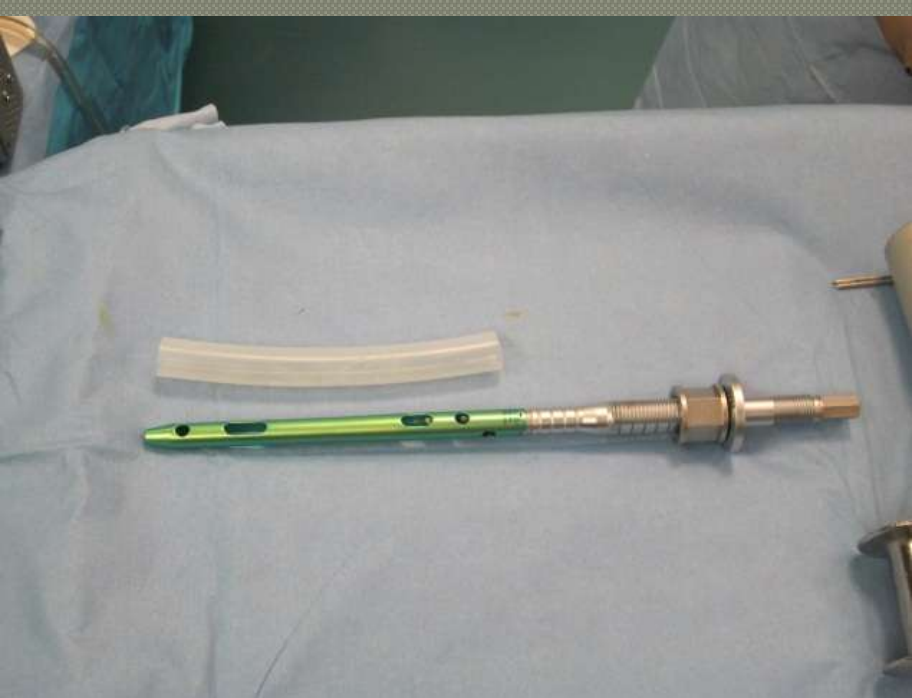# After: Solid TTC fusion





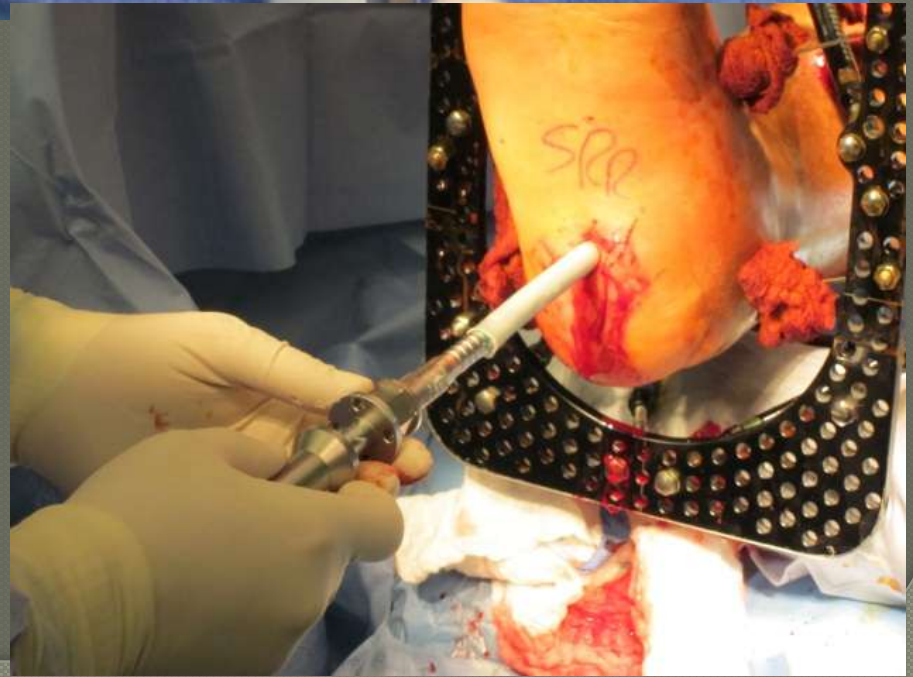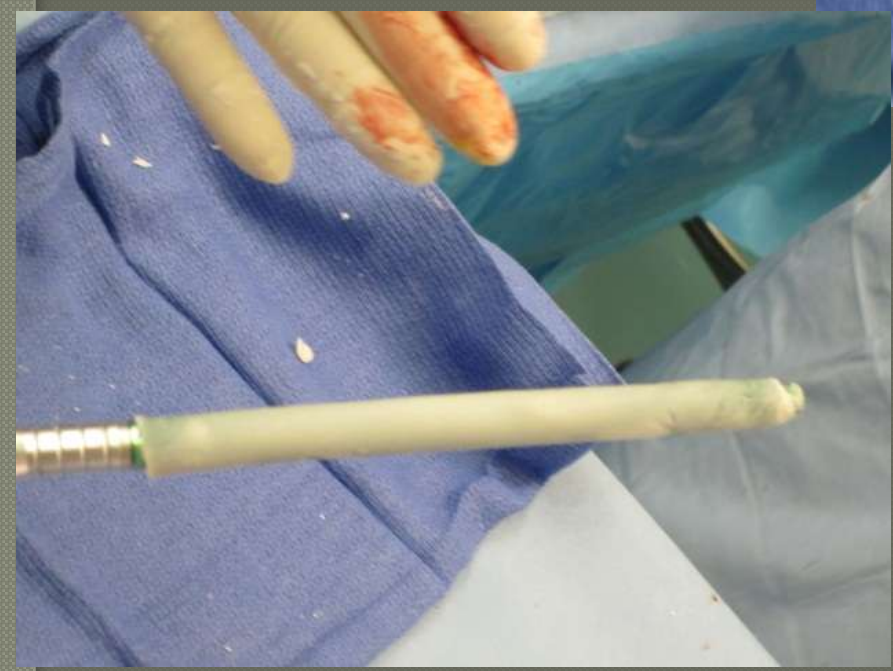

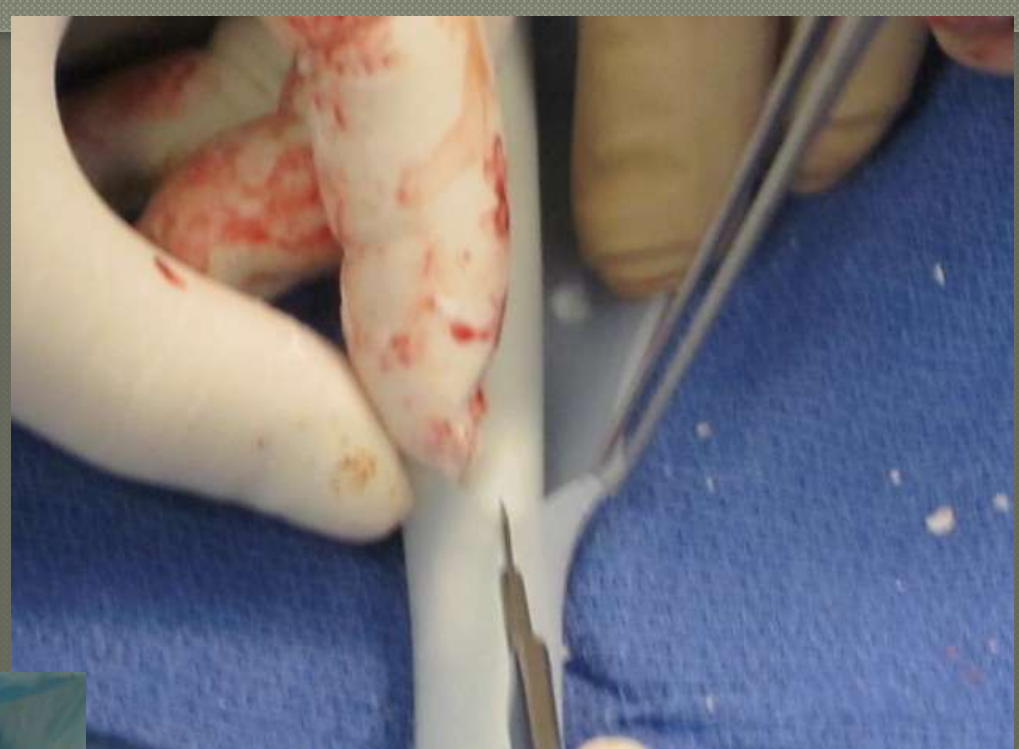




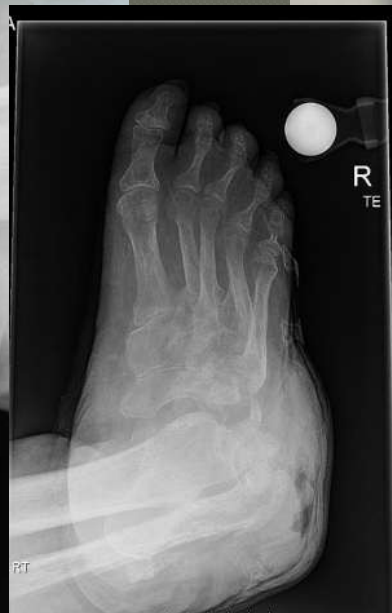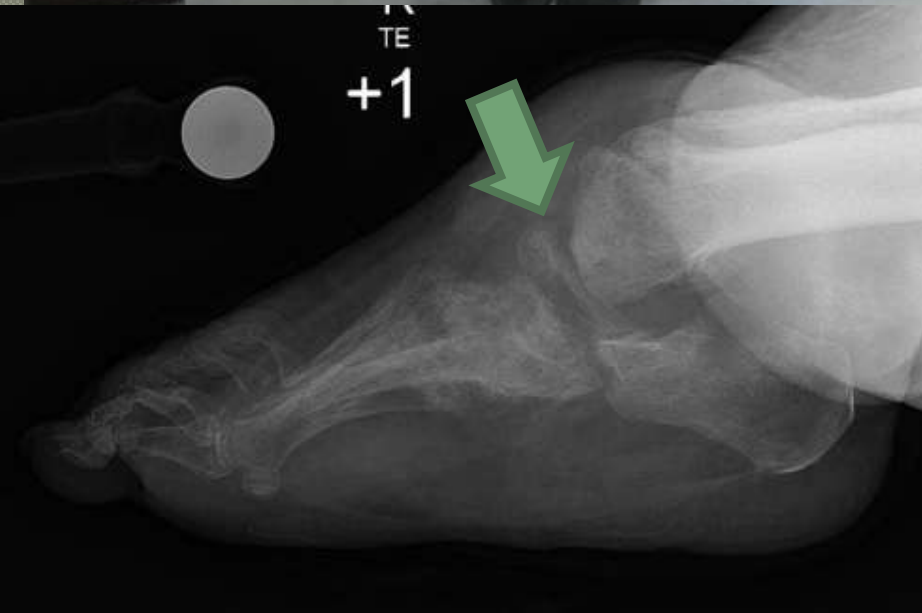
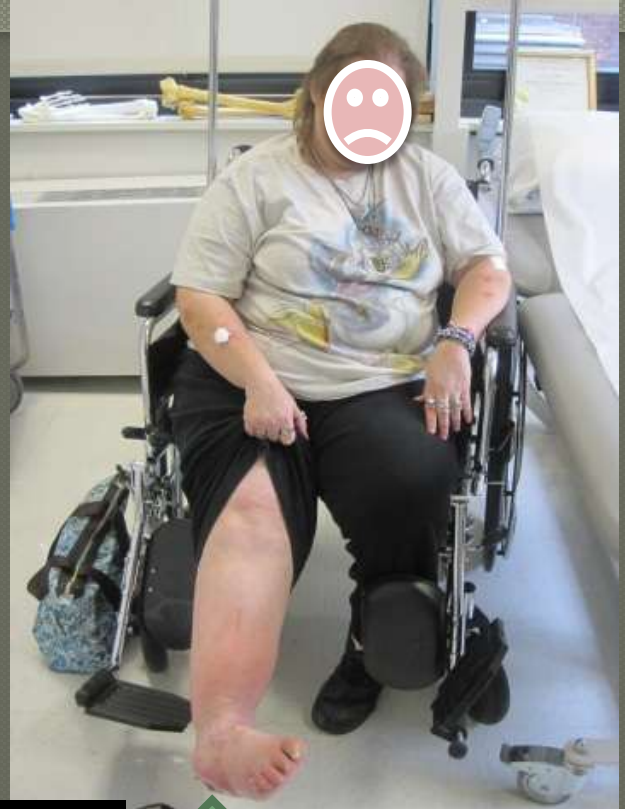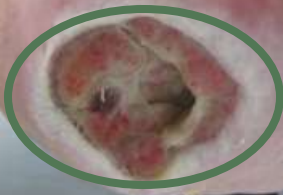
(1.0) 3.4 T

2g Vanco  
3.4g Tobra.  
per bag cement





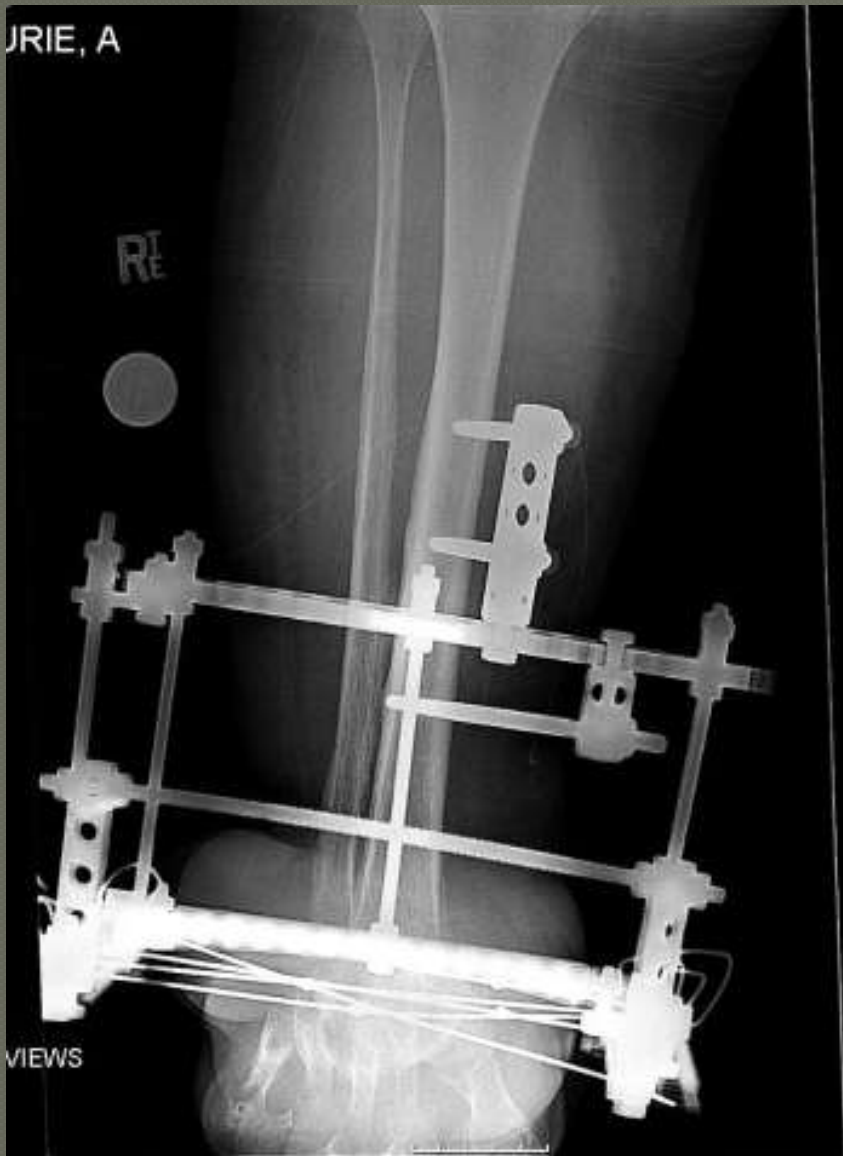
Before: Infected, ulcer

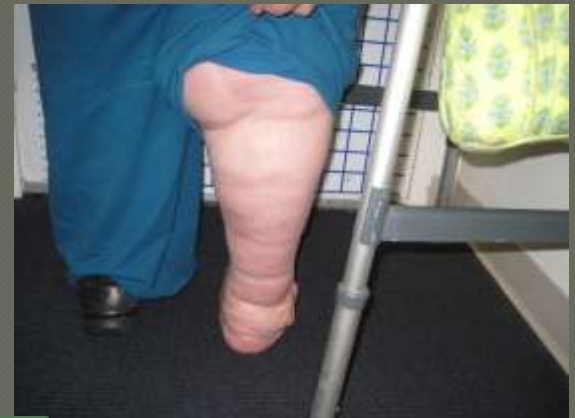
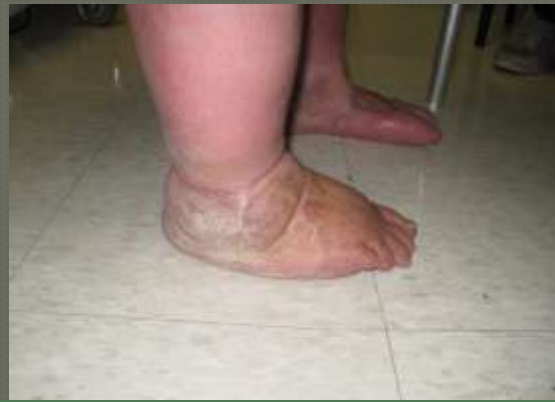
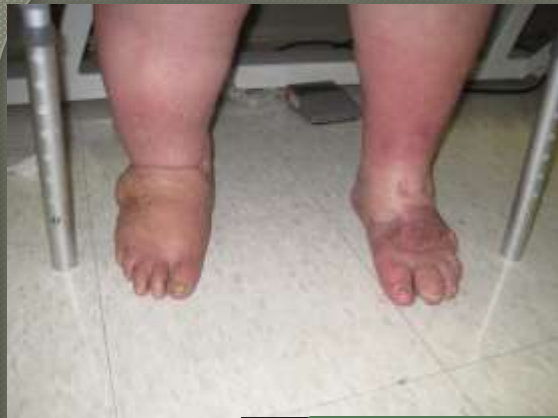JRIE, A

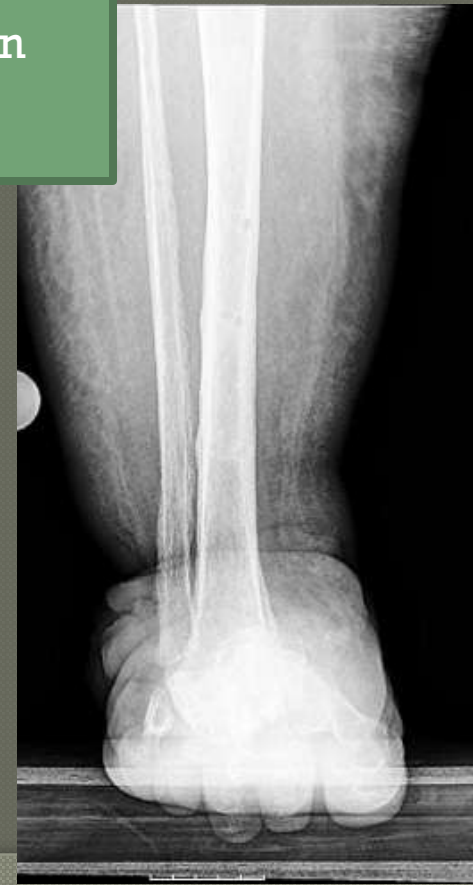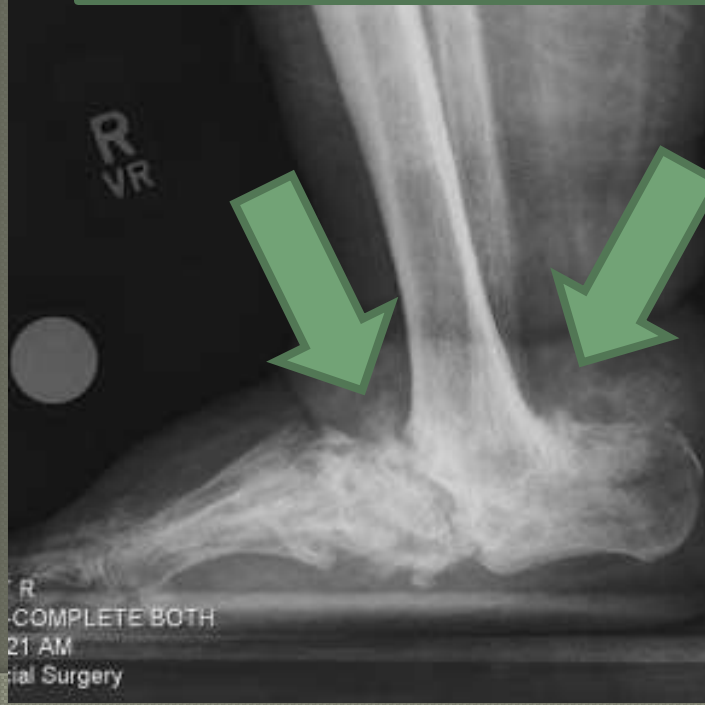RE

VIEWS

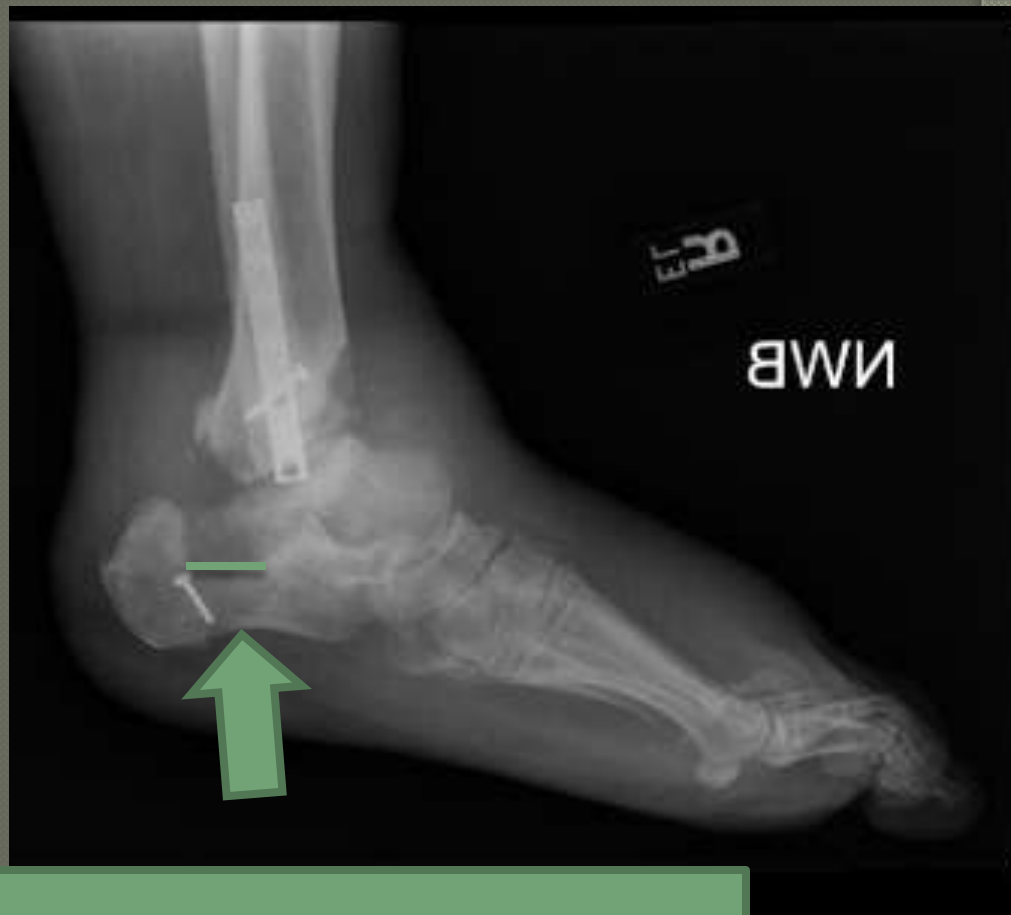
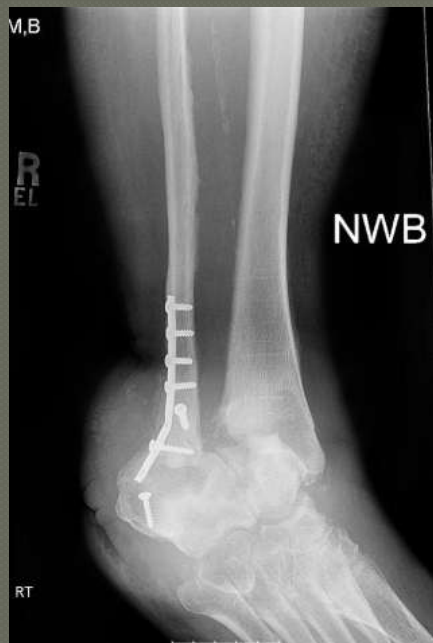
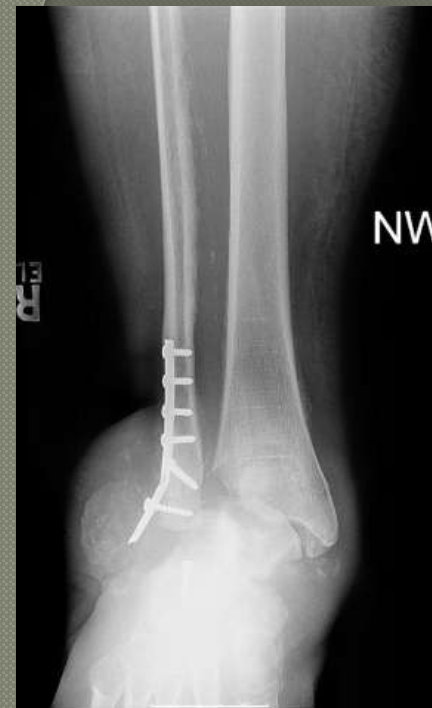

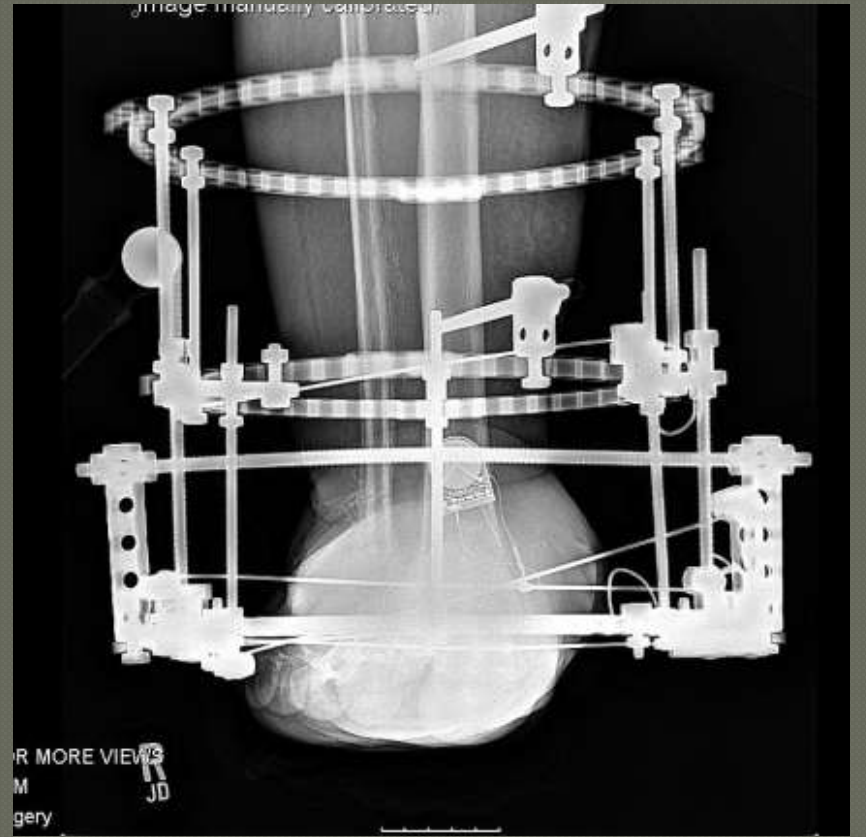
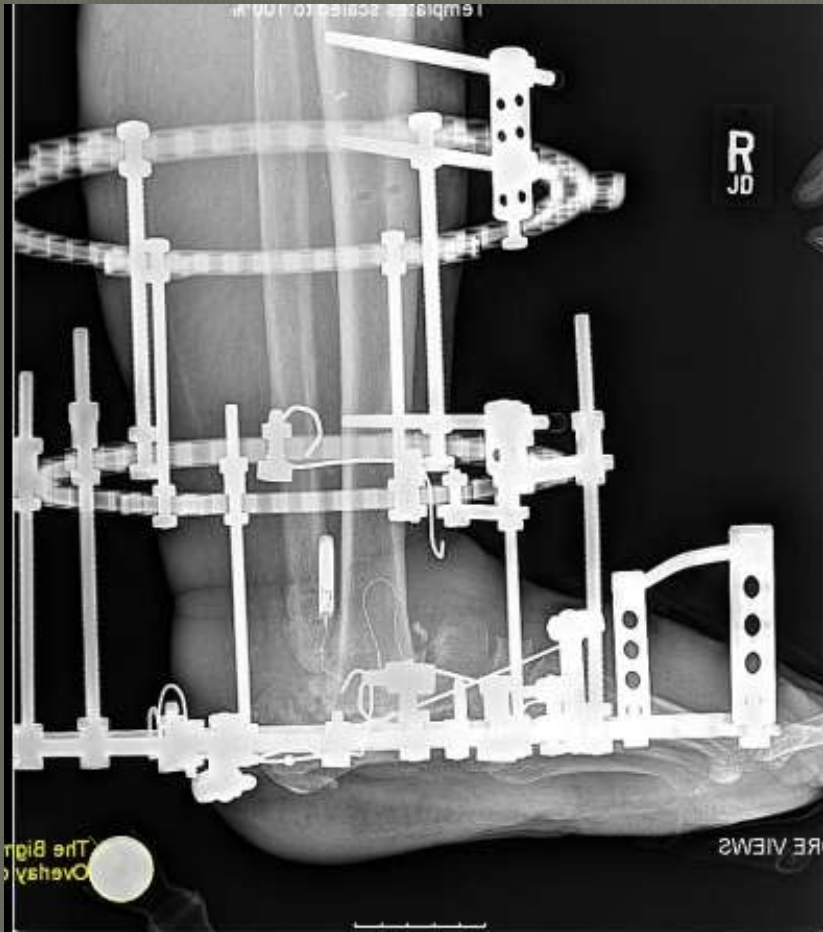
After: Solid Tibio-calcaneal fusion  
& eradication of infection



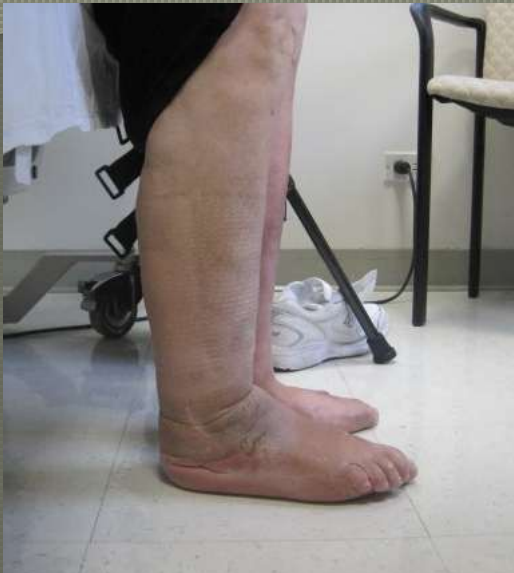



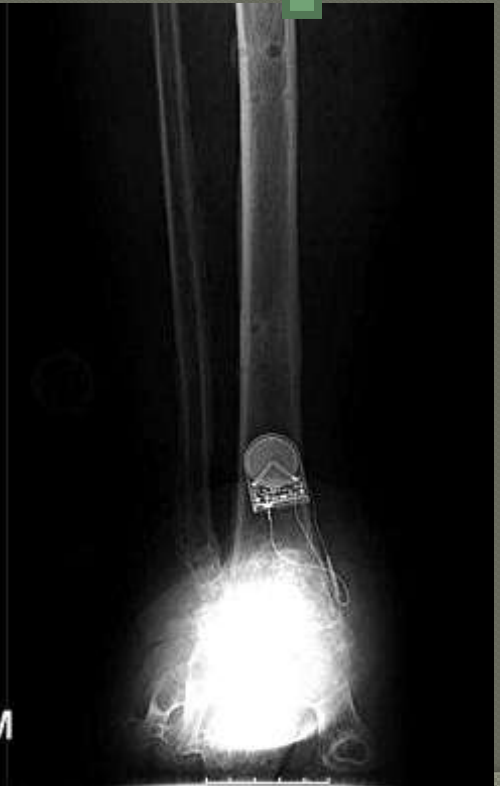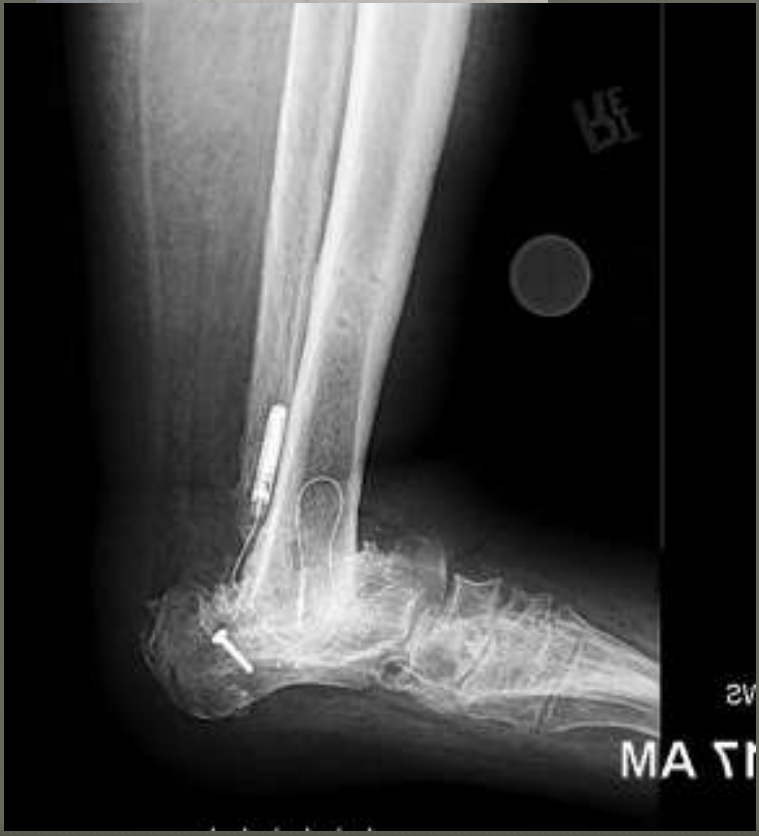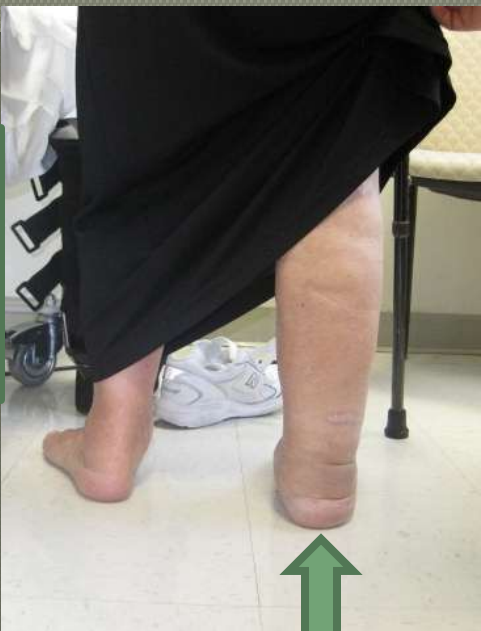Before: Poor Calcaneal  
bone stock





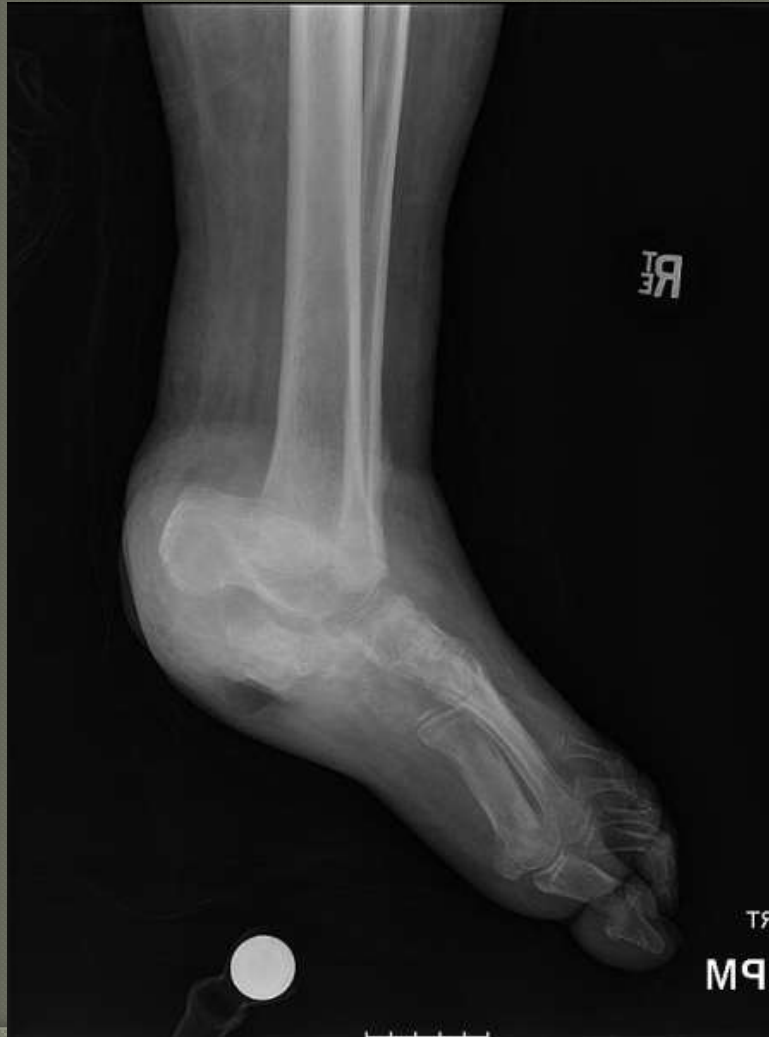
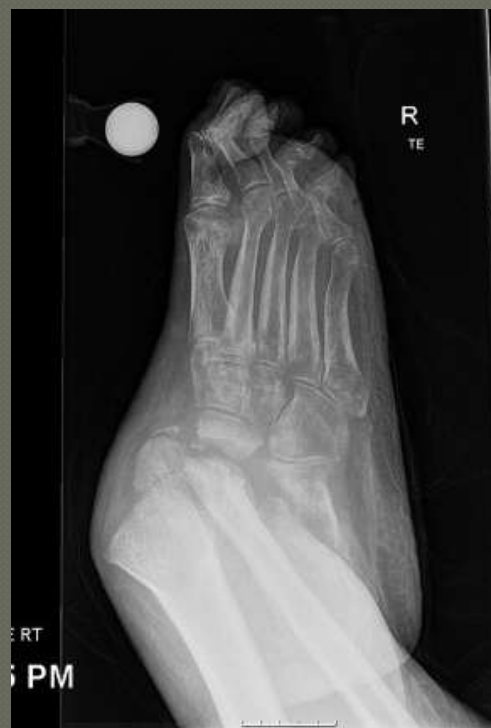
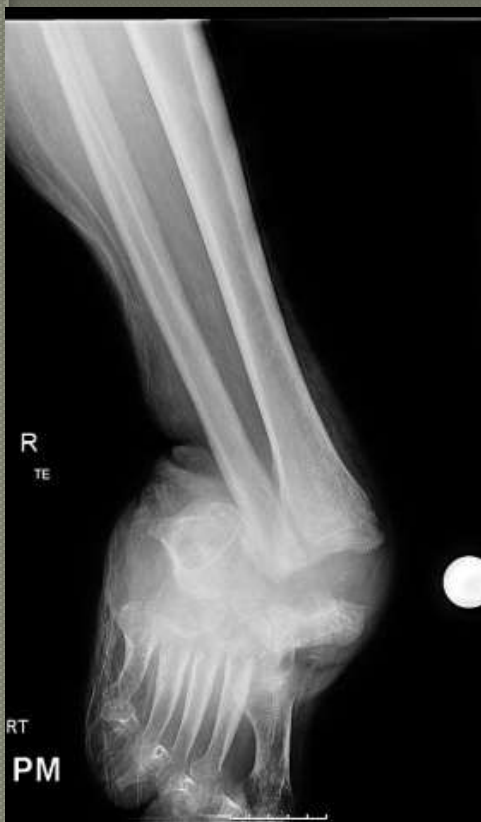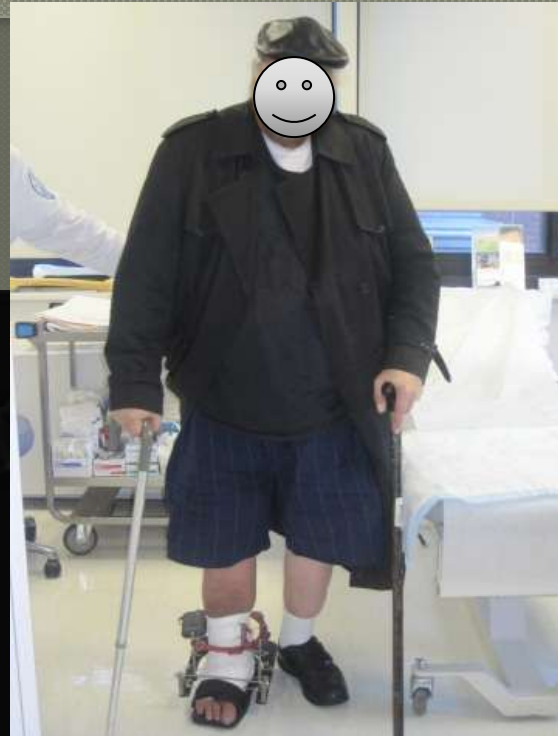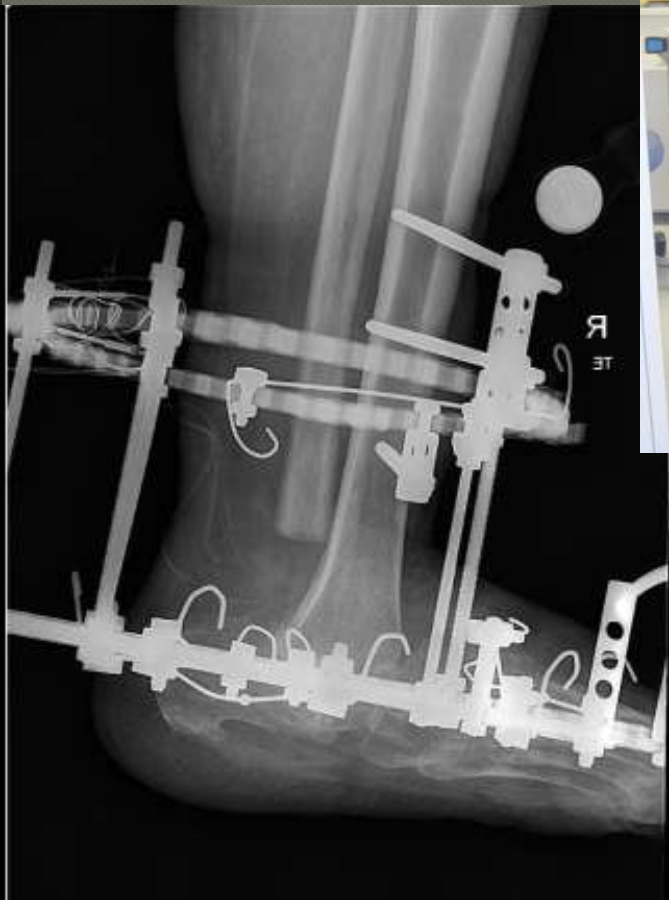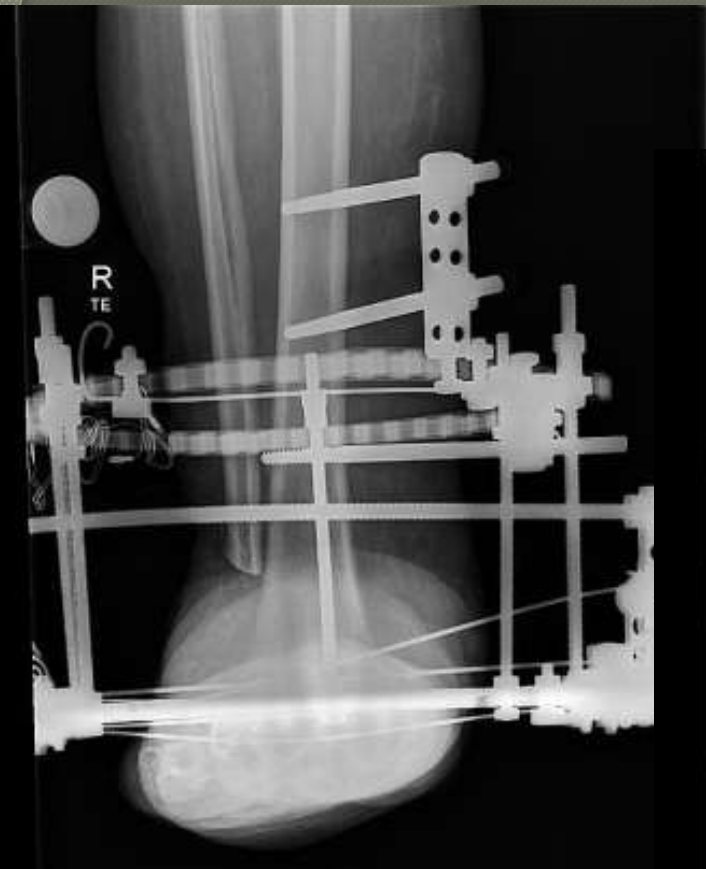After: Solid T-C fusion



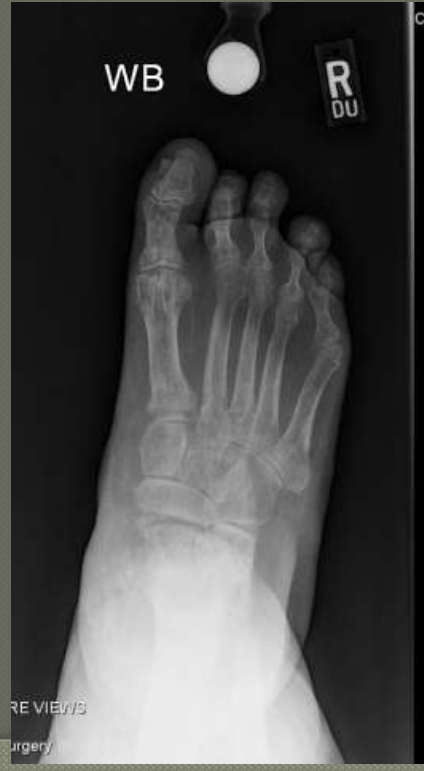
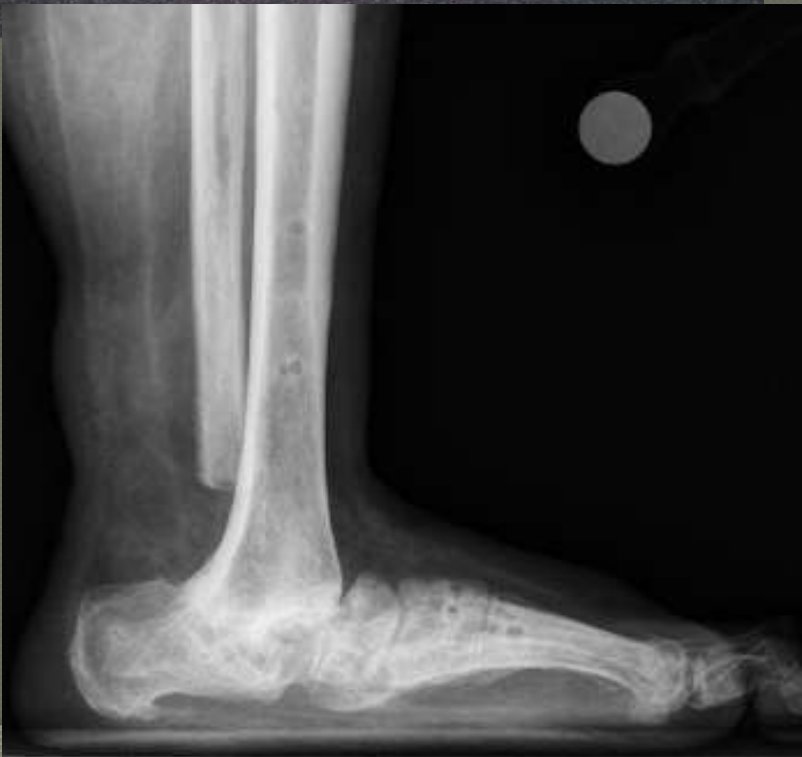
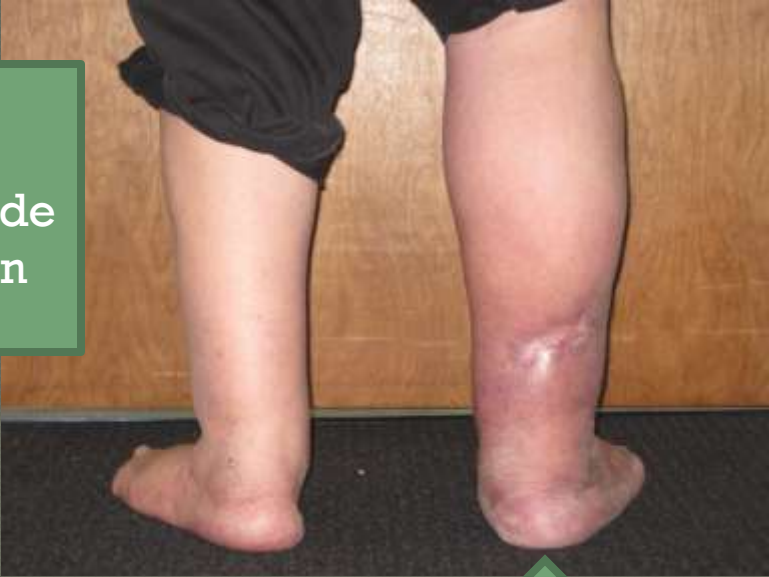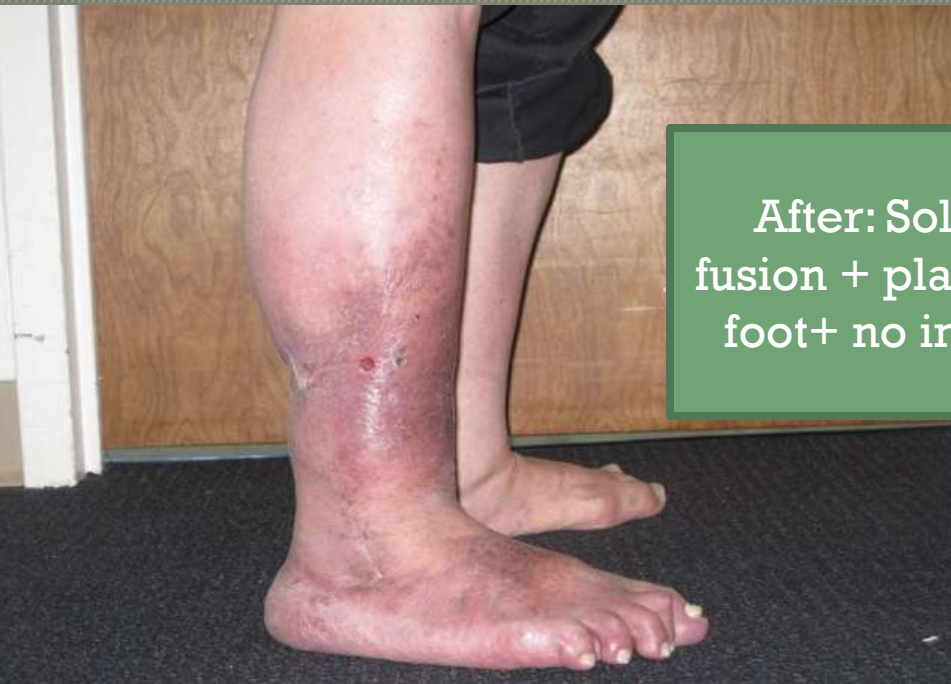Before: severe ankle hindfoot destruction with ulcer + infection





After: Solid T-C fusion + plantigrade foot + no infection

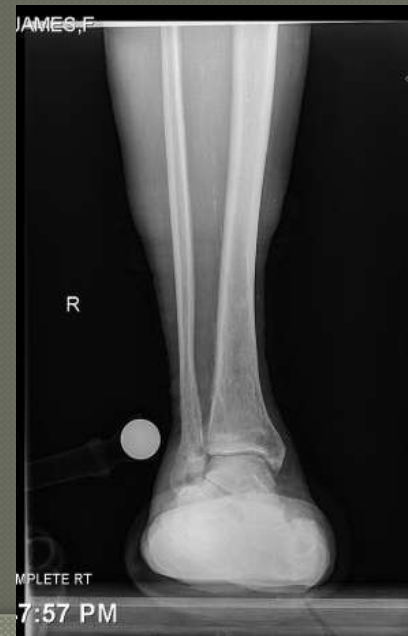
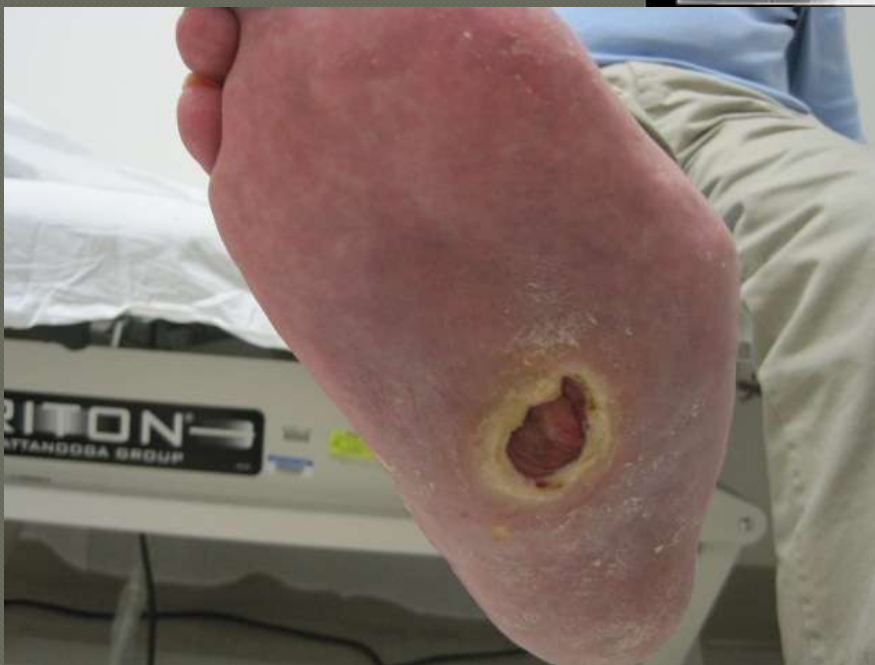
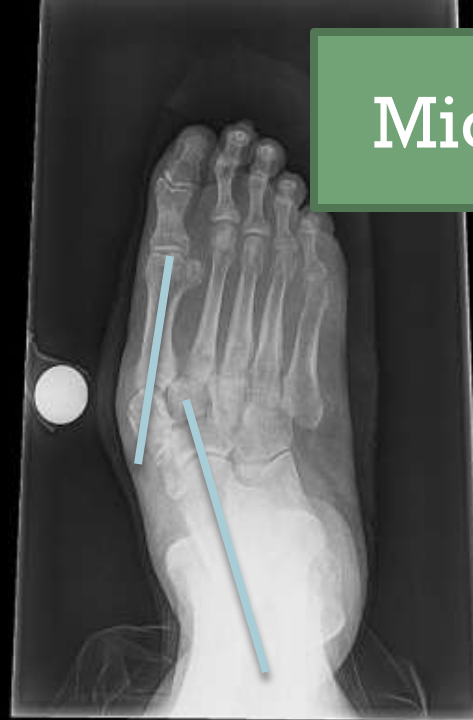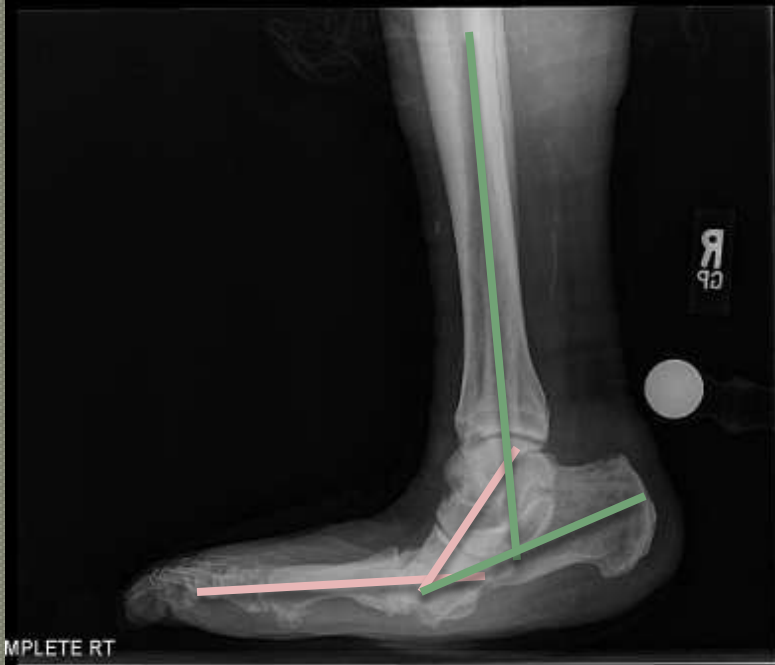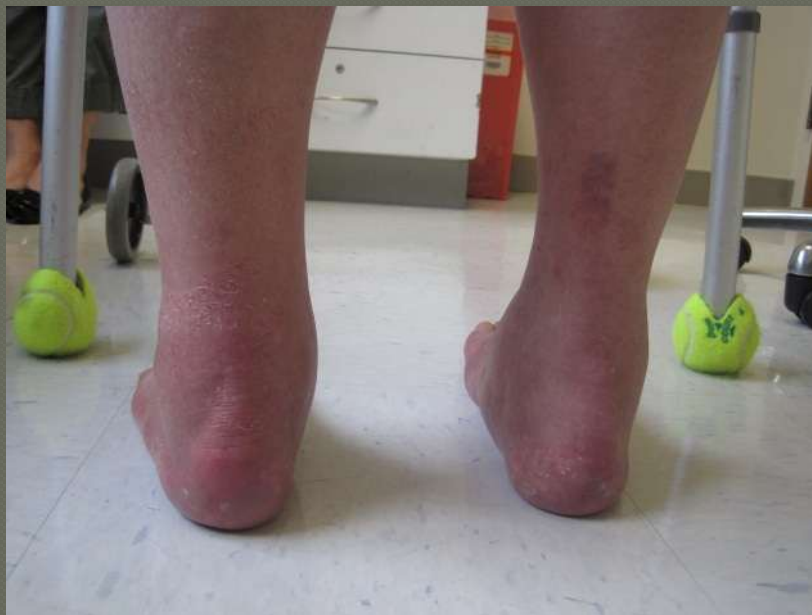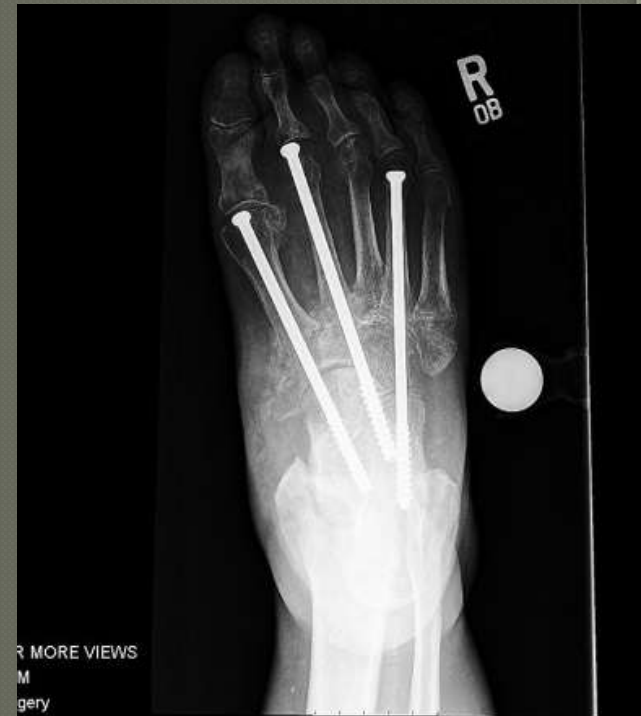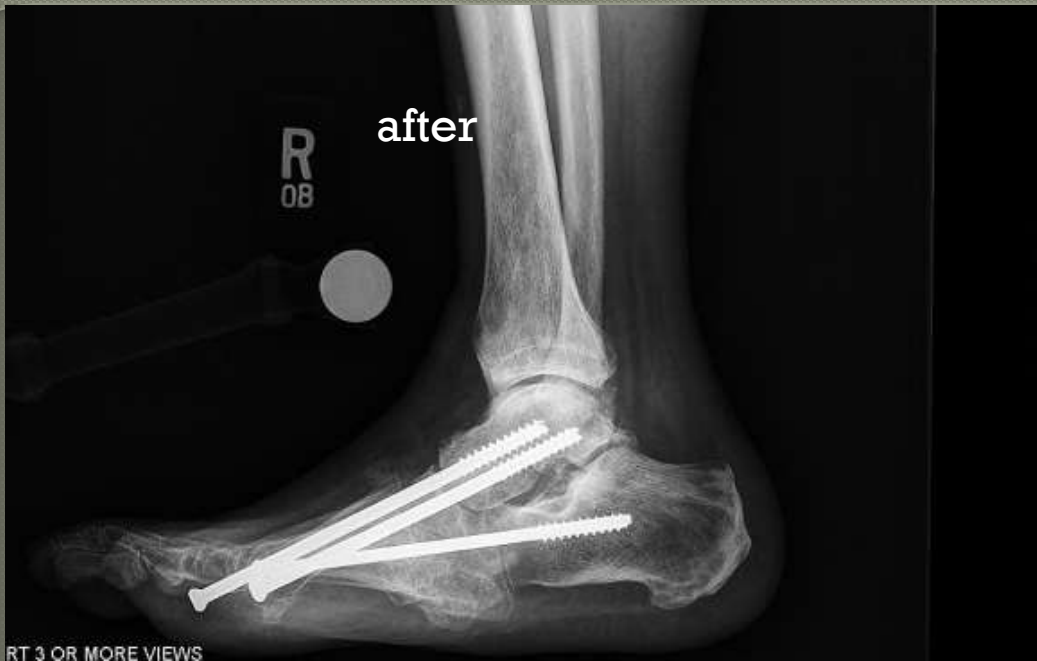# Ankle/ Hindfoot Lessons

- Ankle + ST fusion
- **Limit WB**
- Talus often non-viable
- **Tib-Calc fusion**  
**good option**
- Tibia lengthening  
good option for some
- **Custom Shoes**
- IM rod is option
- **Antx coated for infx**
- Infection can be addressed successfully
- **Excise ulcers**
- Poor calcaneal bone stock- frame is good

# Midfoot Charcot

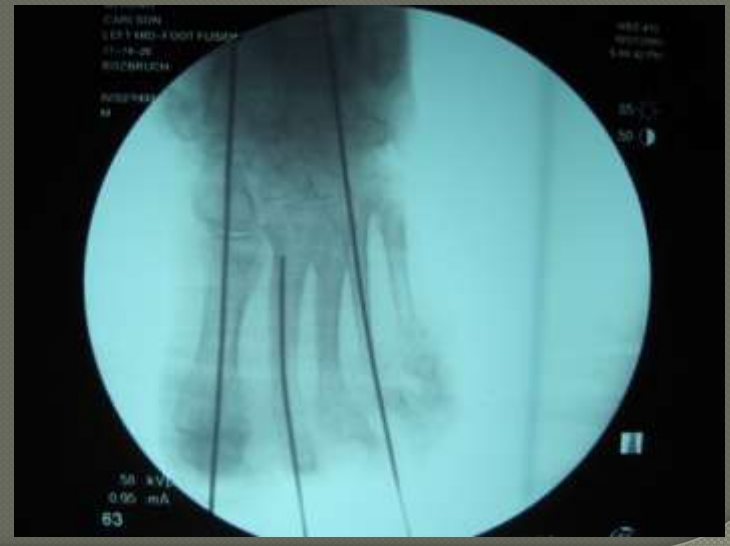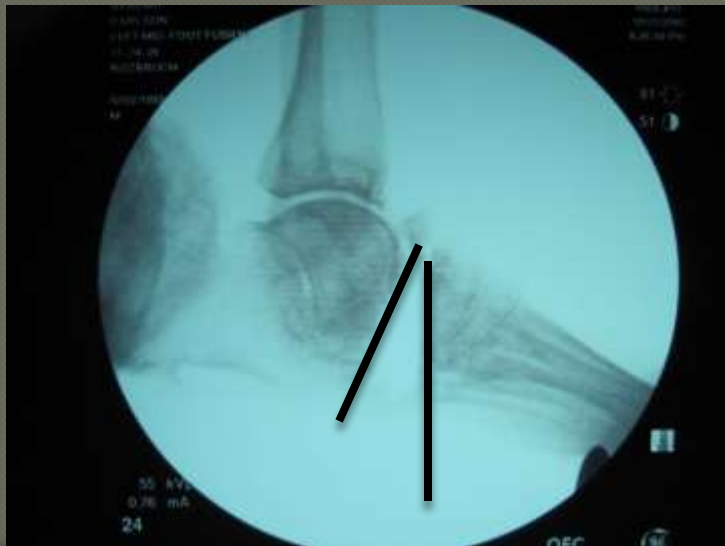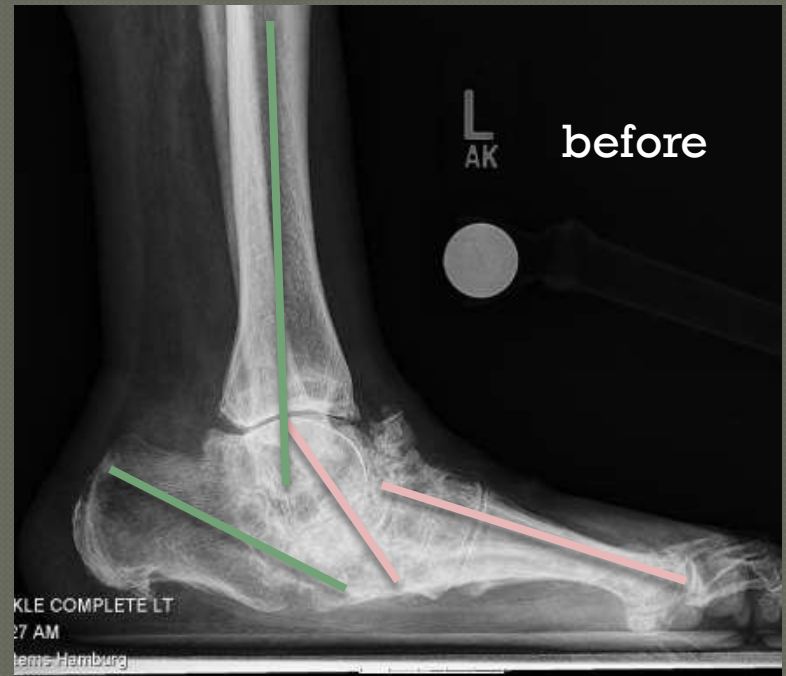
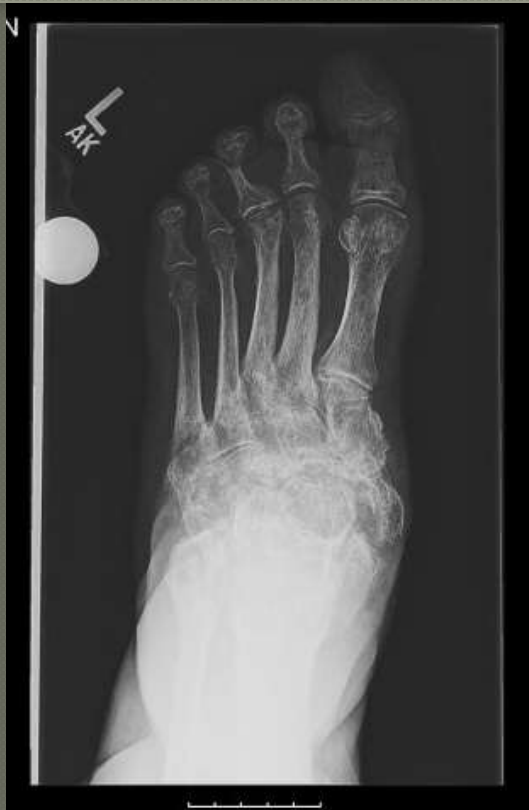## before

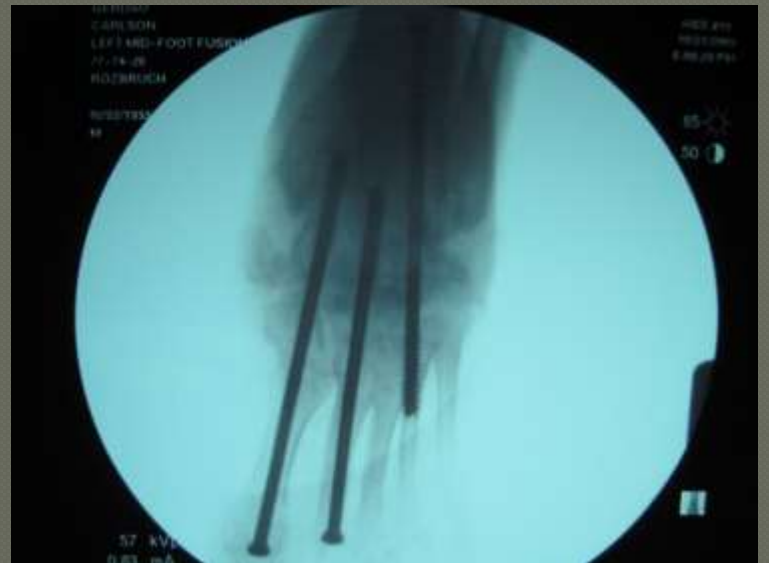
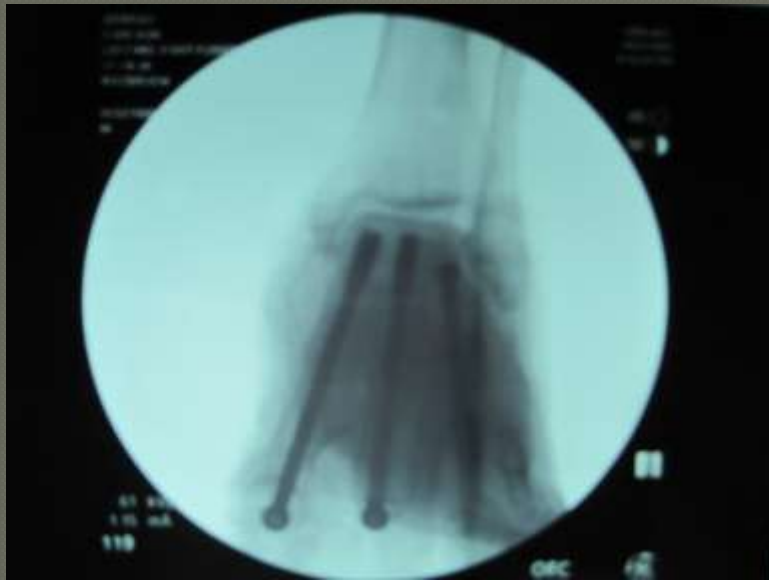
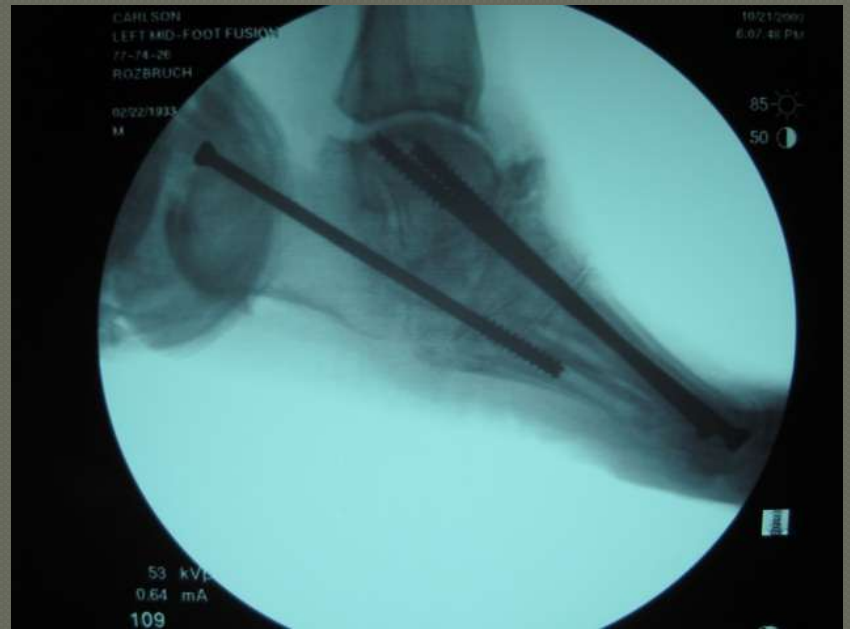
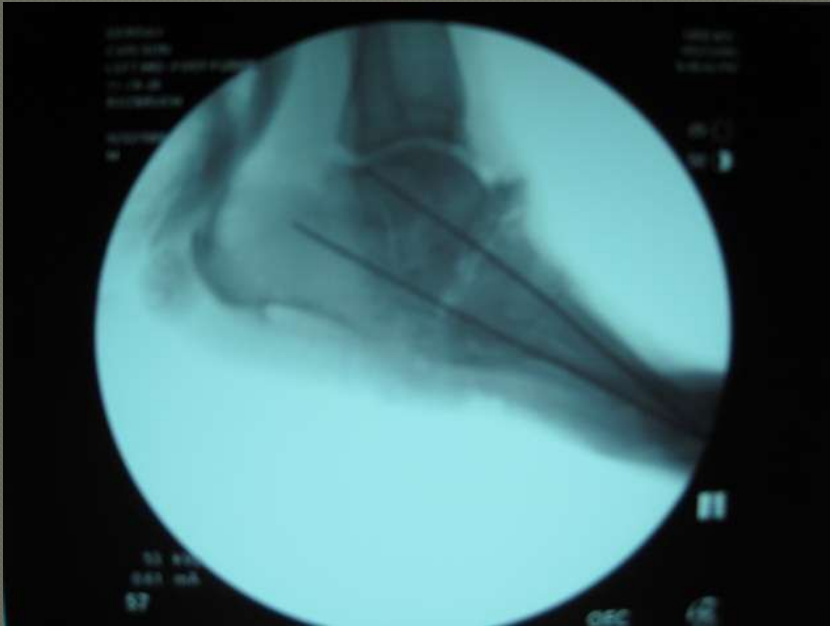


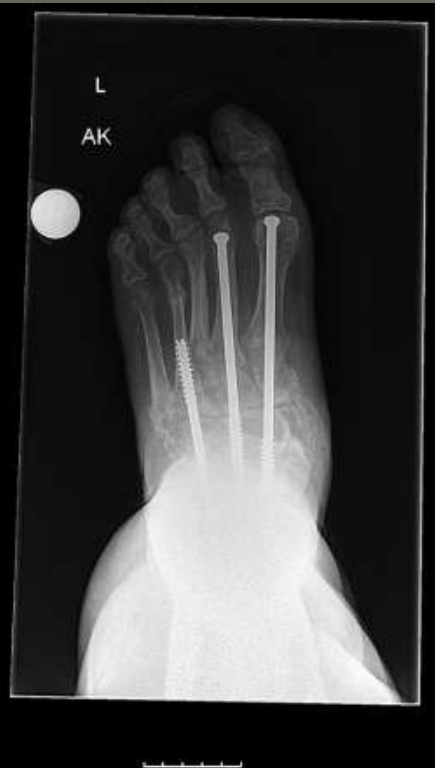
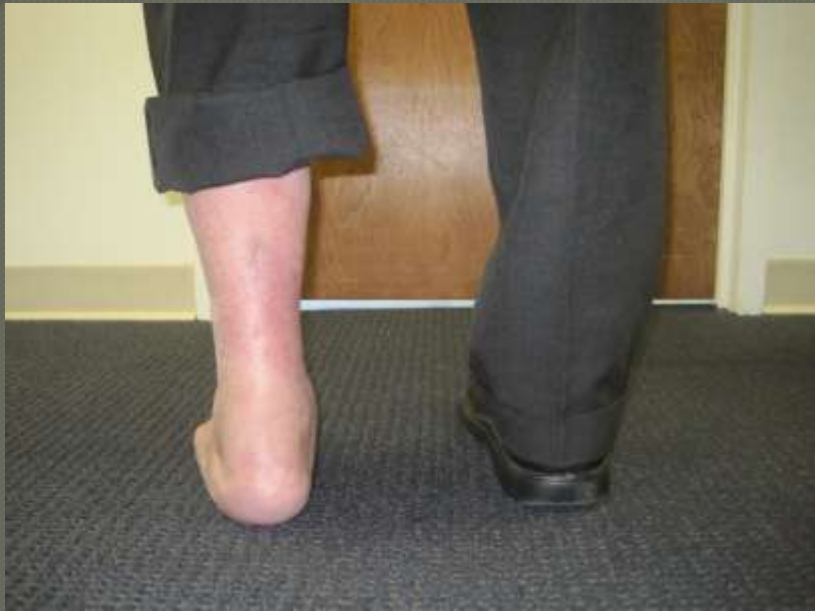




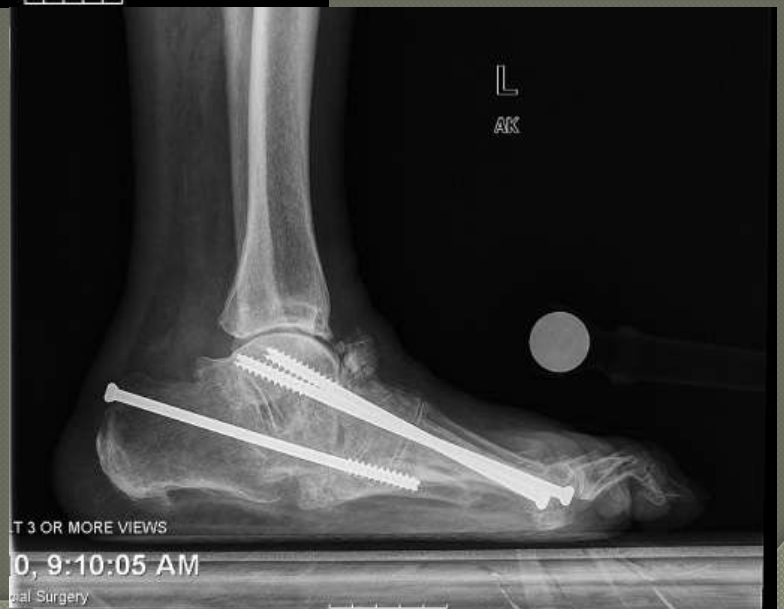
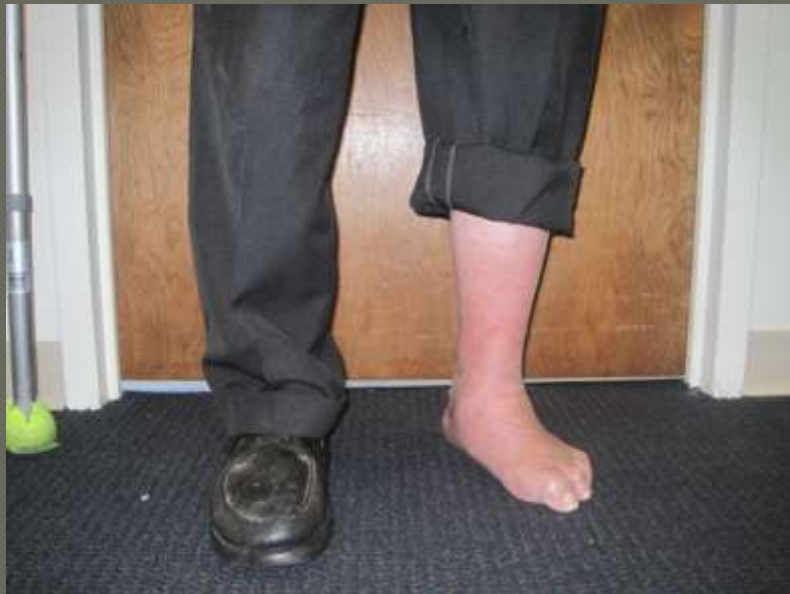
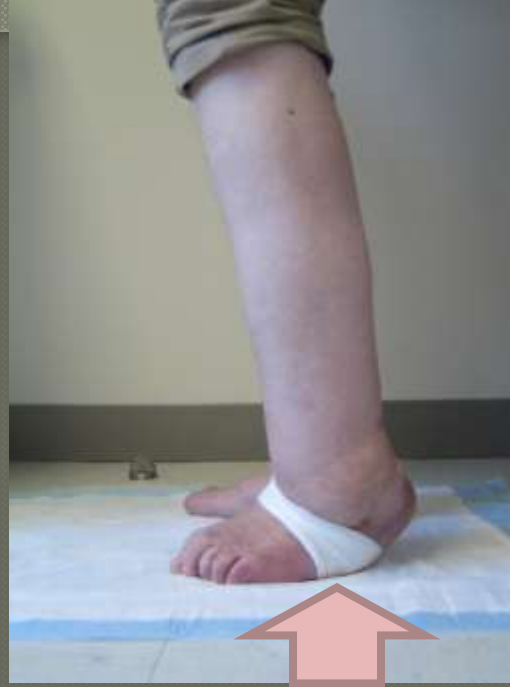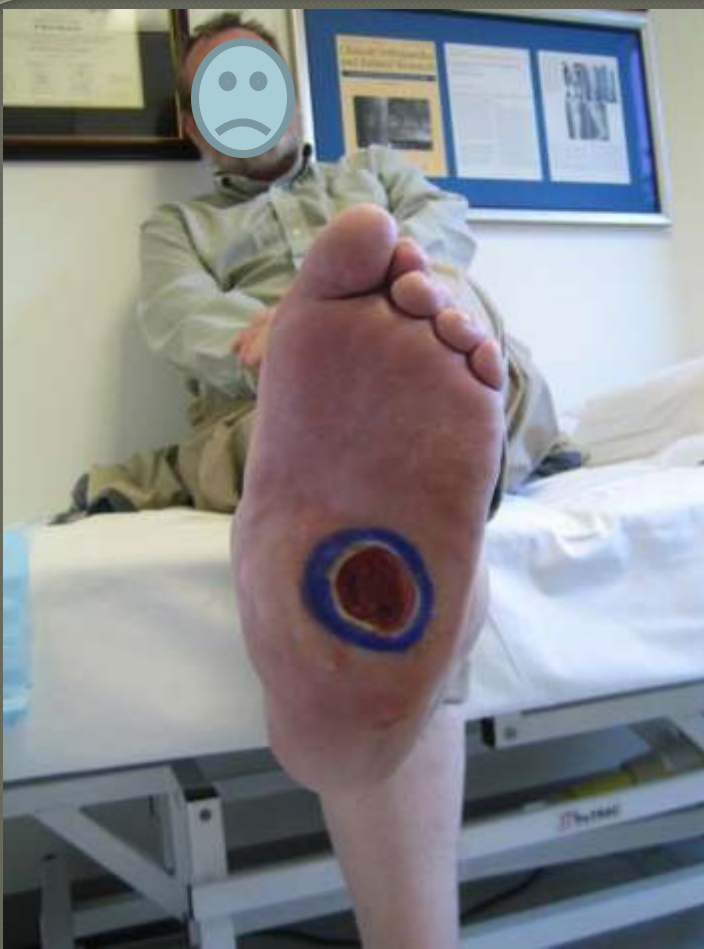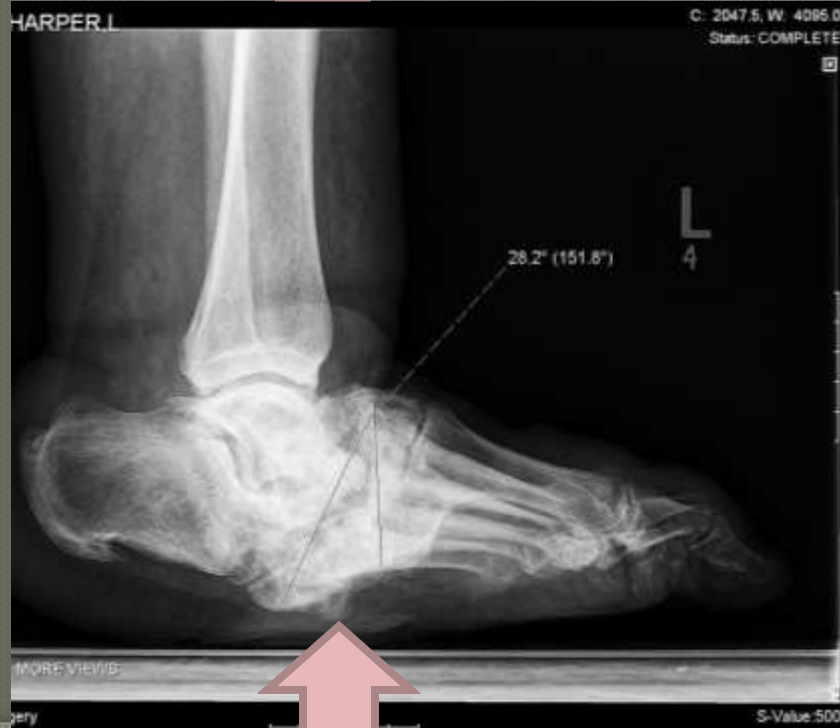after







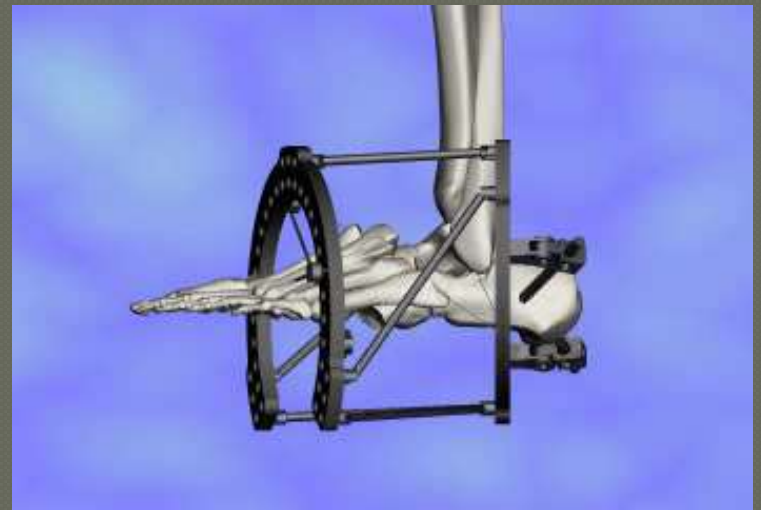
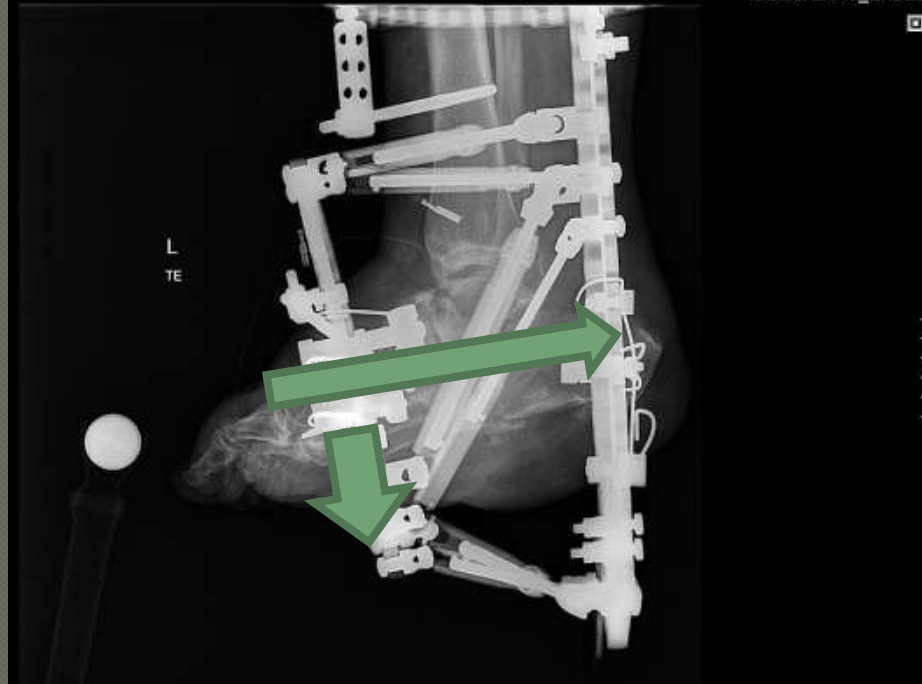
Before:  
Rocker-  
bottom



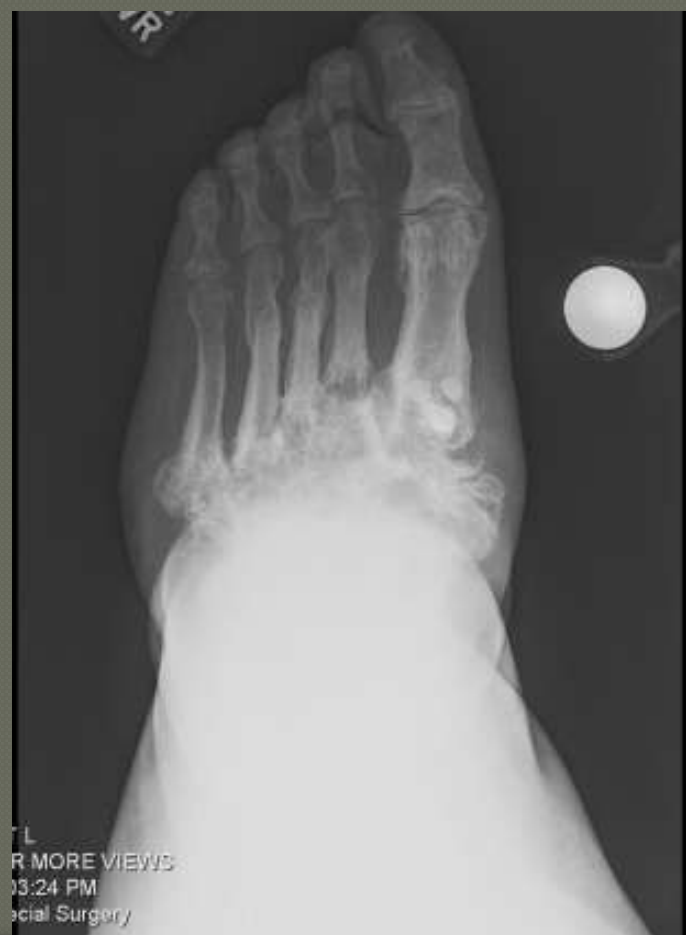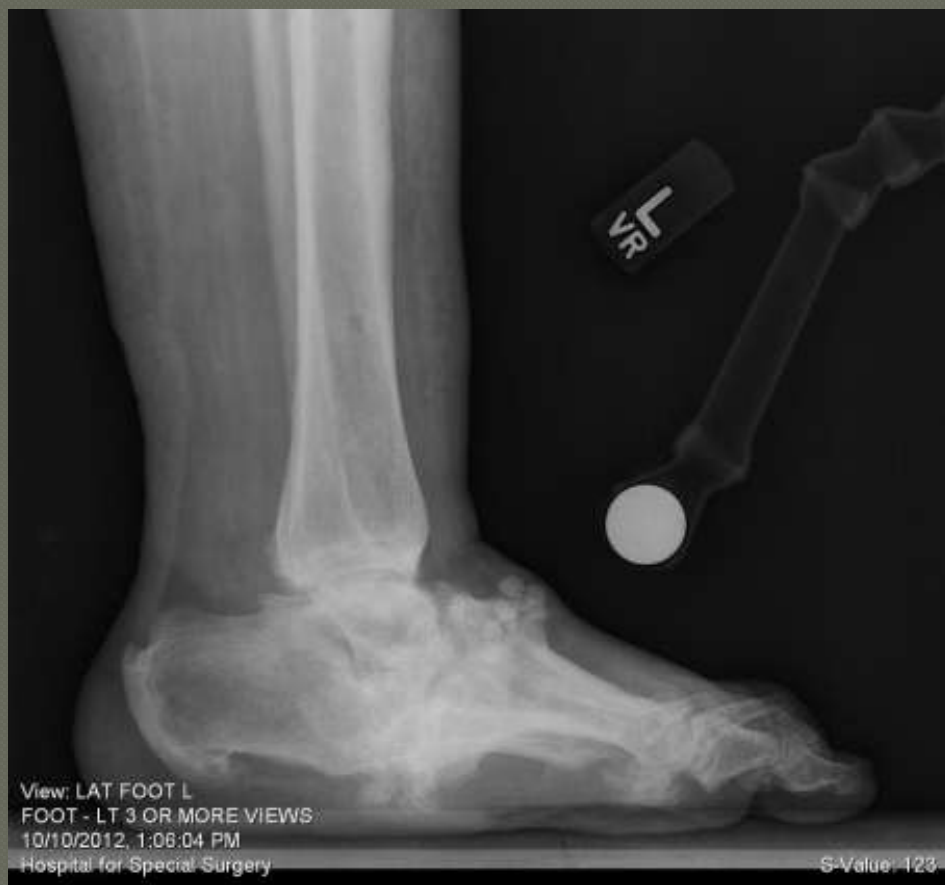RPER,L

C: 2047.0, W: 4095.0

Status: EXAM\_ENDED



after





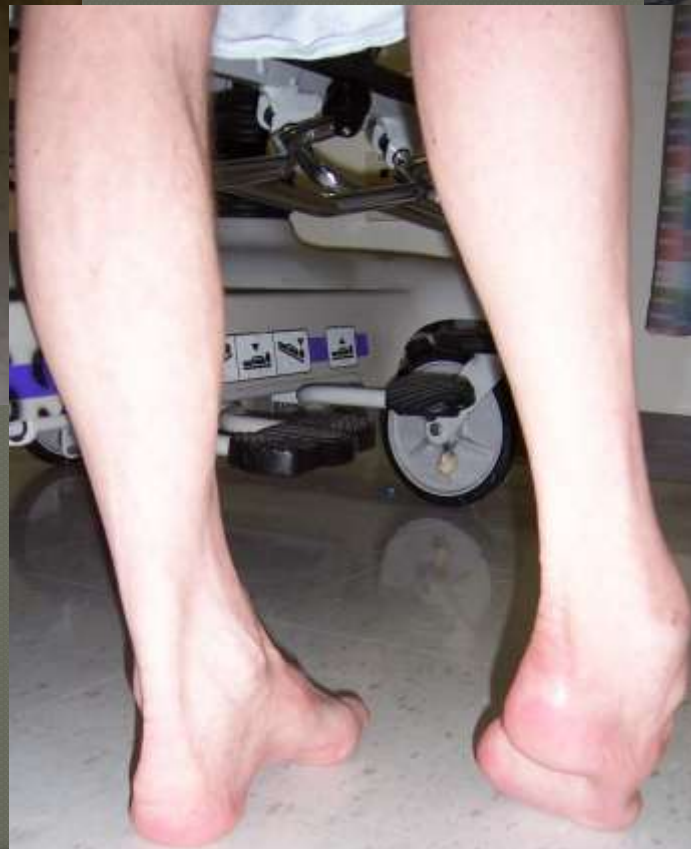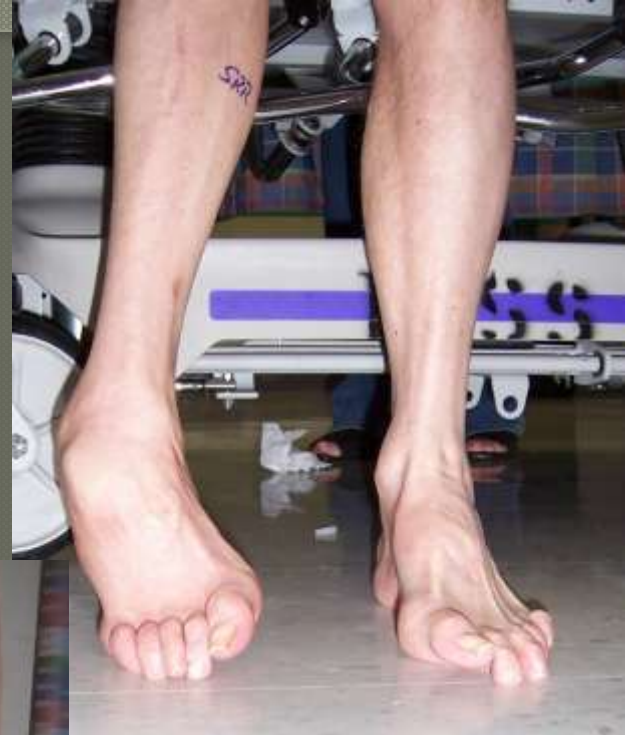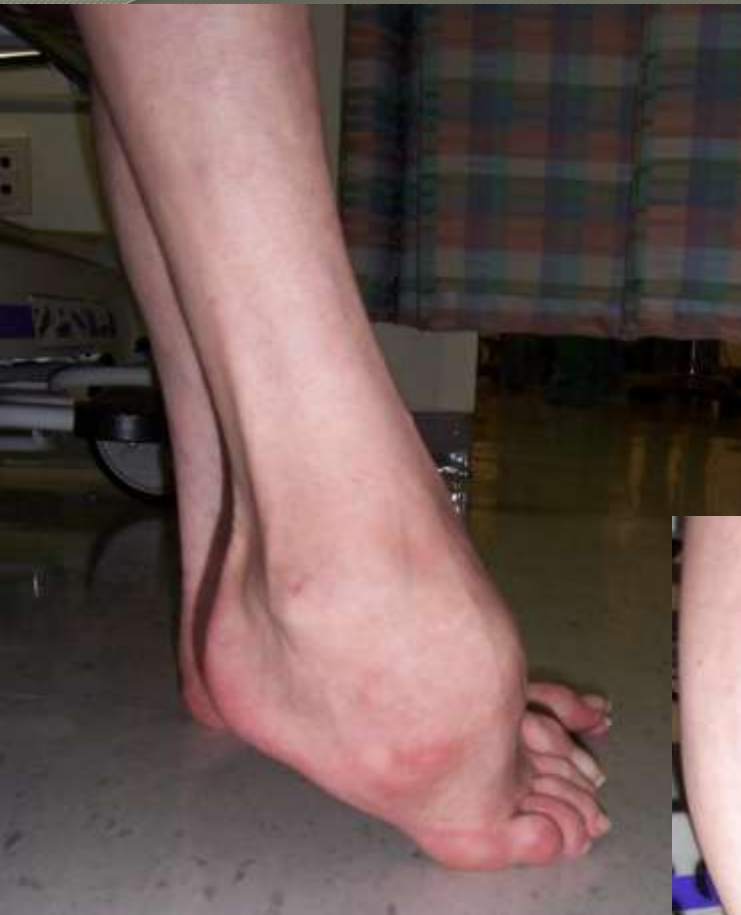# Midfoot Lessons

- Rule out infection
- Try to use IF
- If infected, use Ex Fix or stage
- Gastroc recession
- Indications for External Fixation
  - Large deformity
  - infection

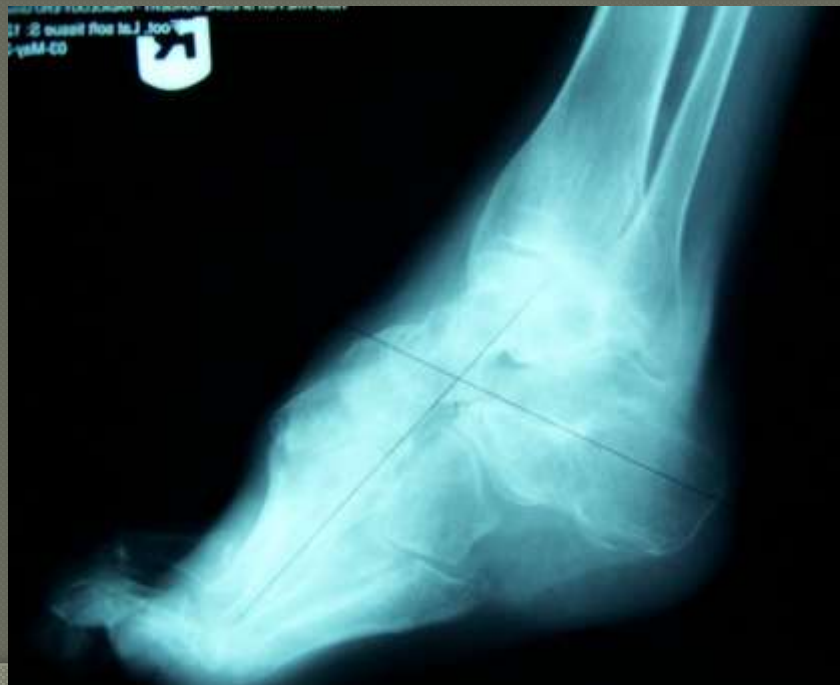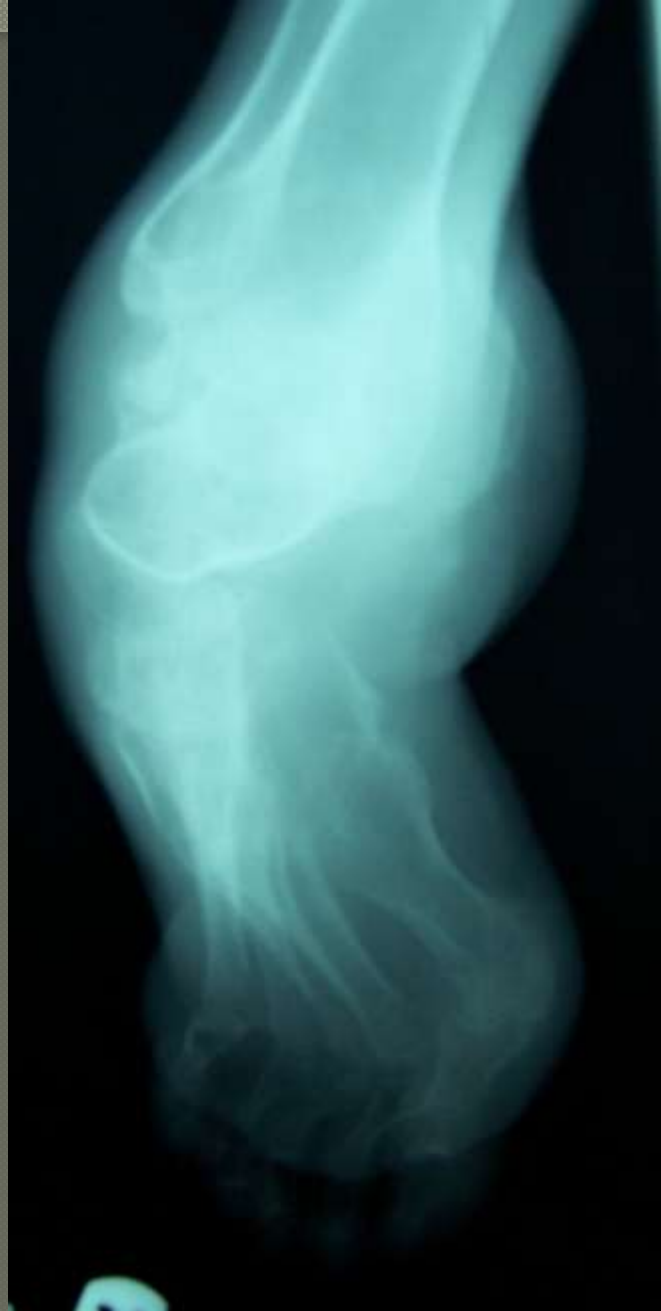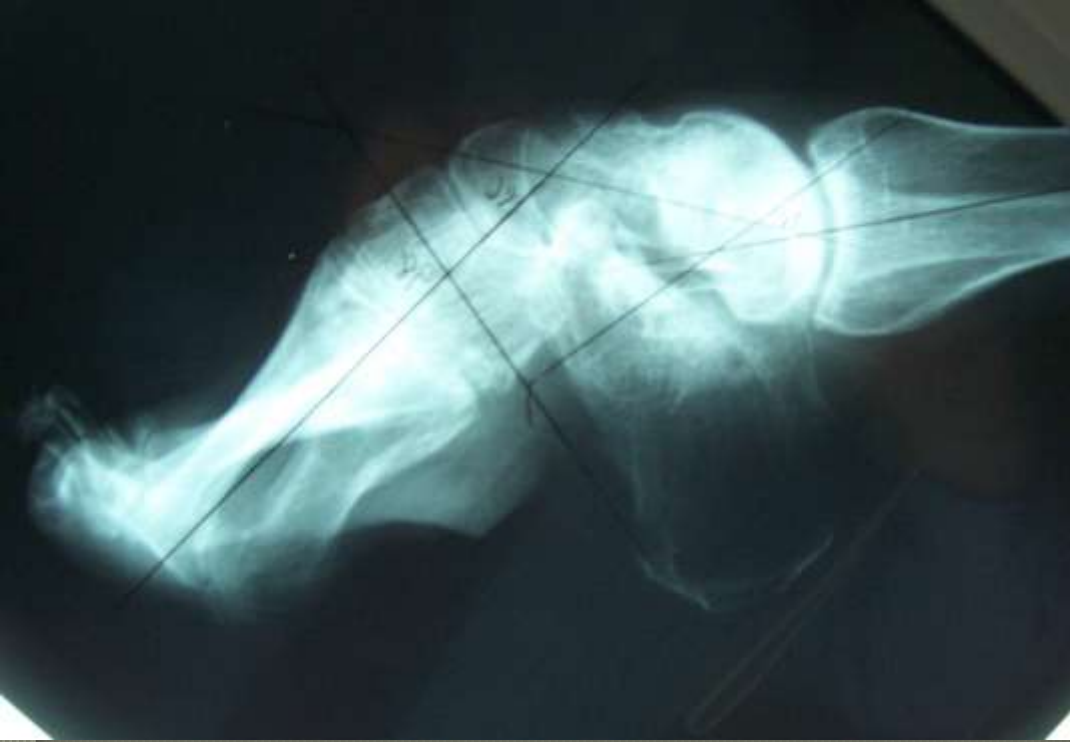# Foot deformity

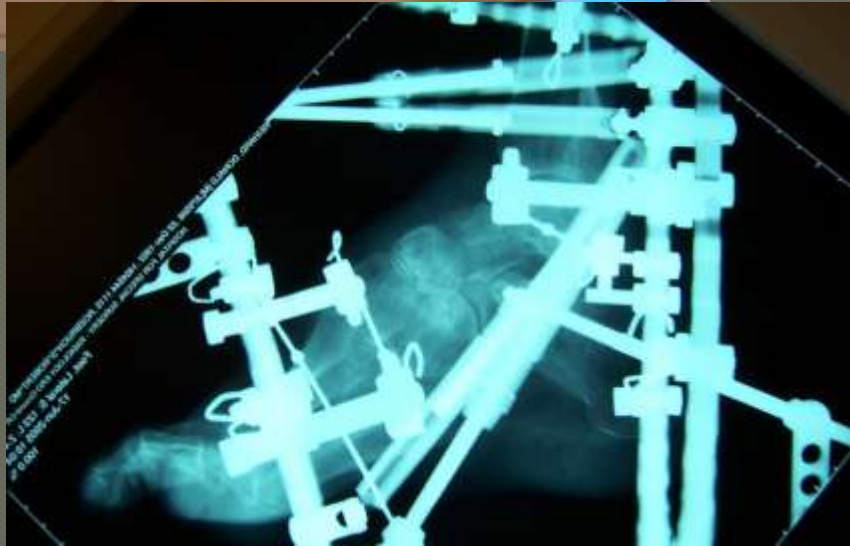
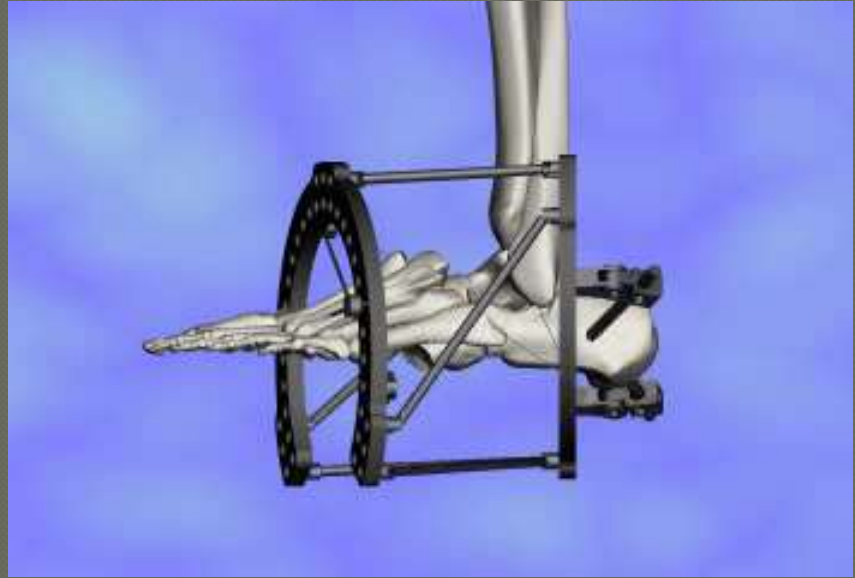
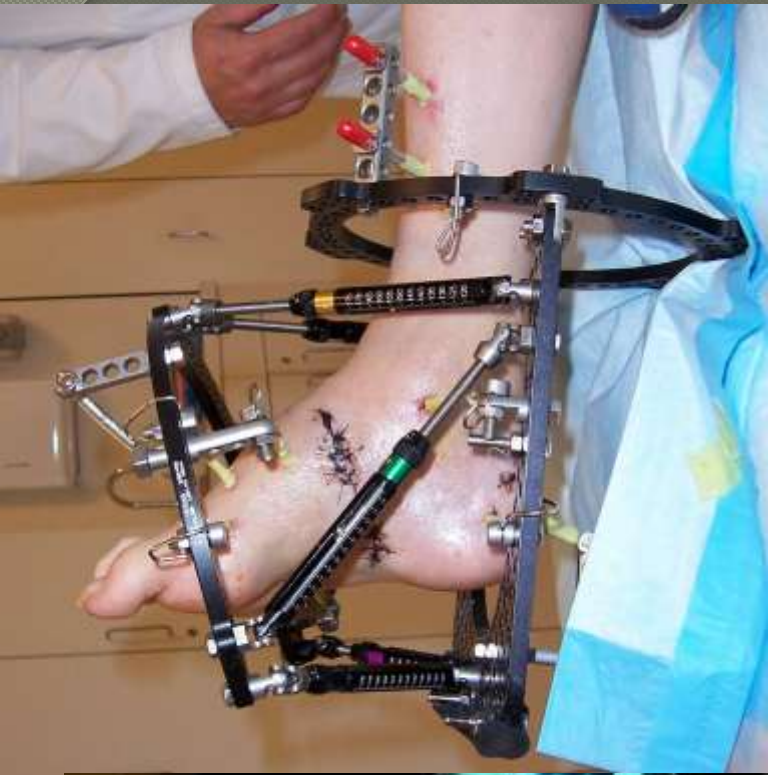- Charcot-Marie-Tooth Disease

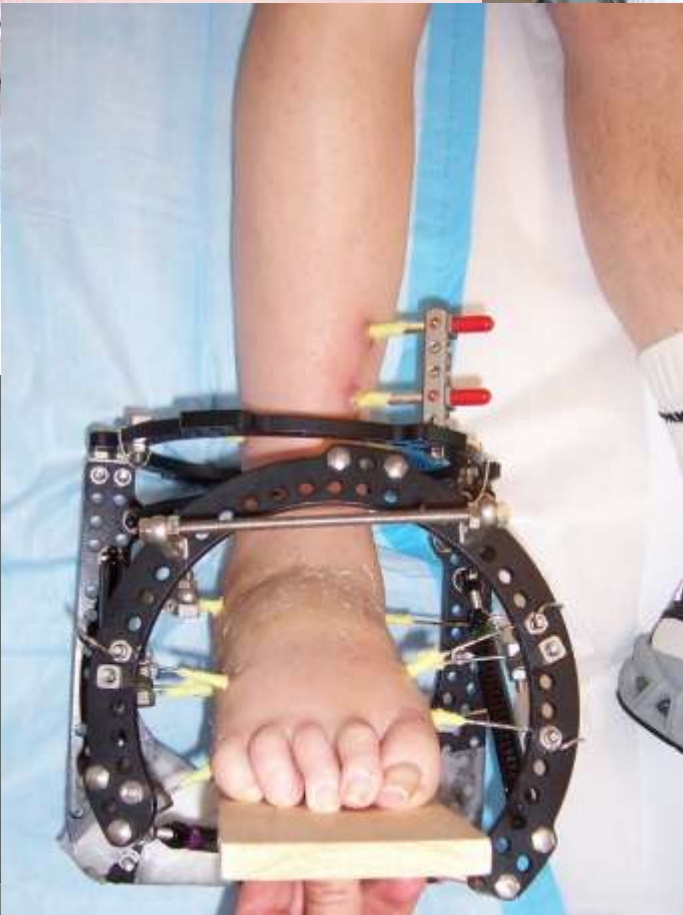
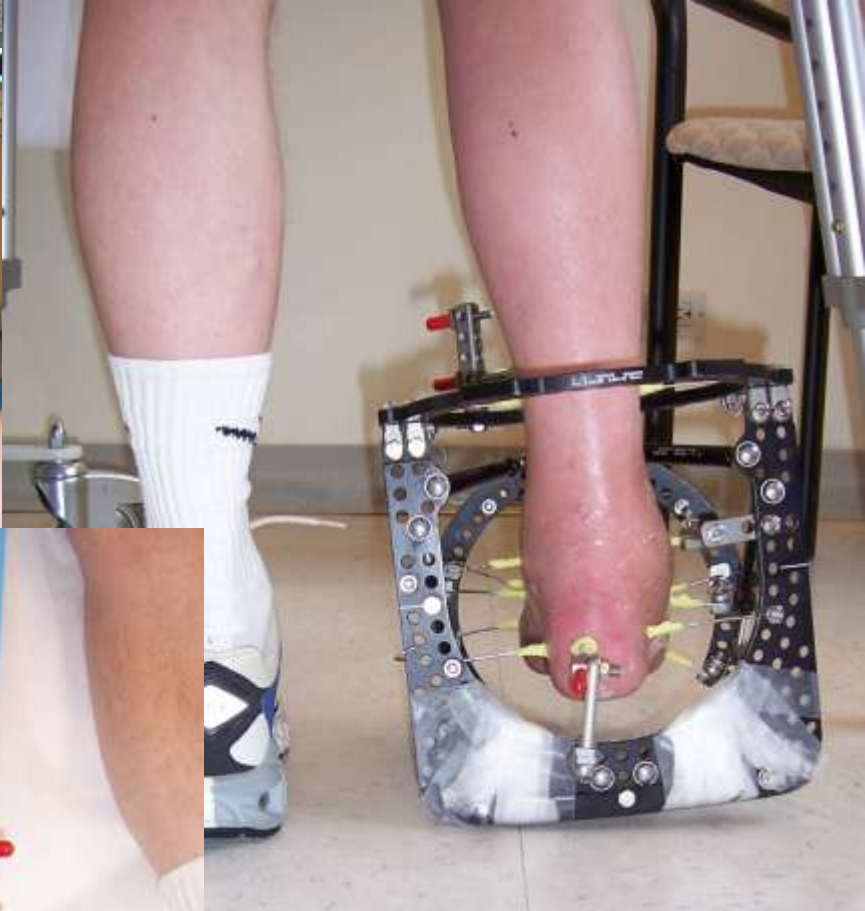
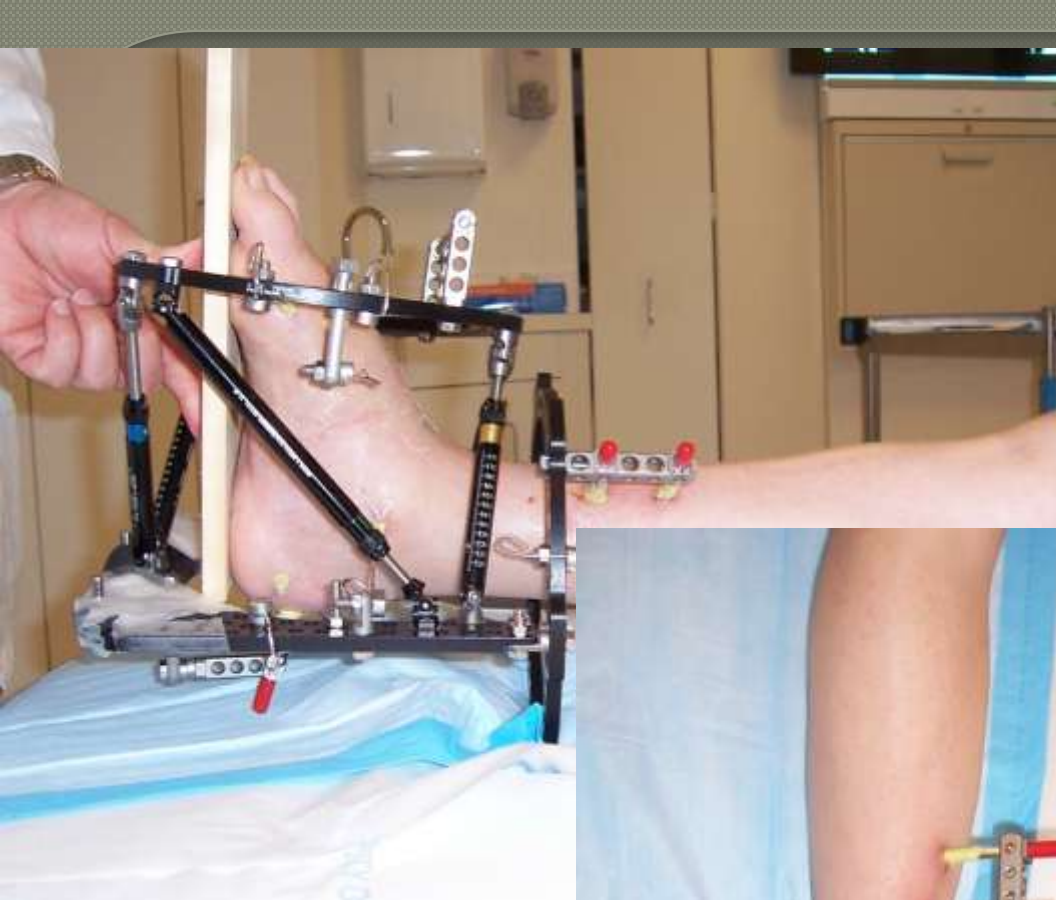Before

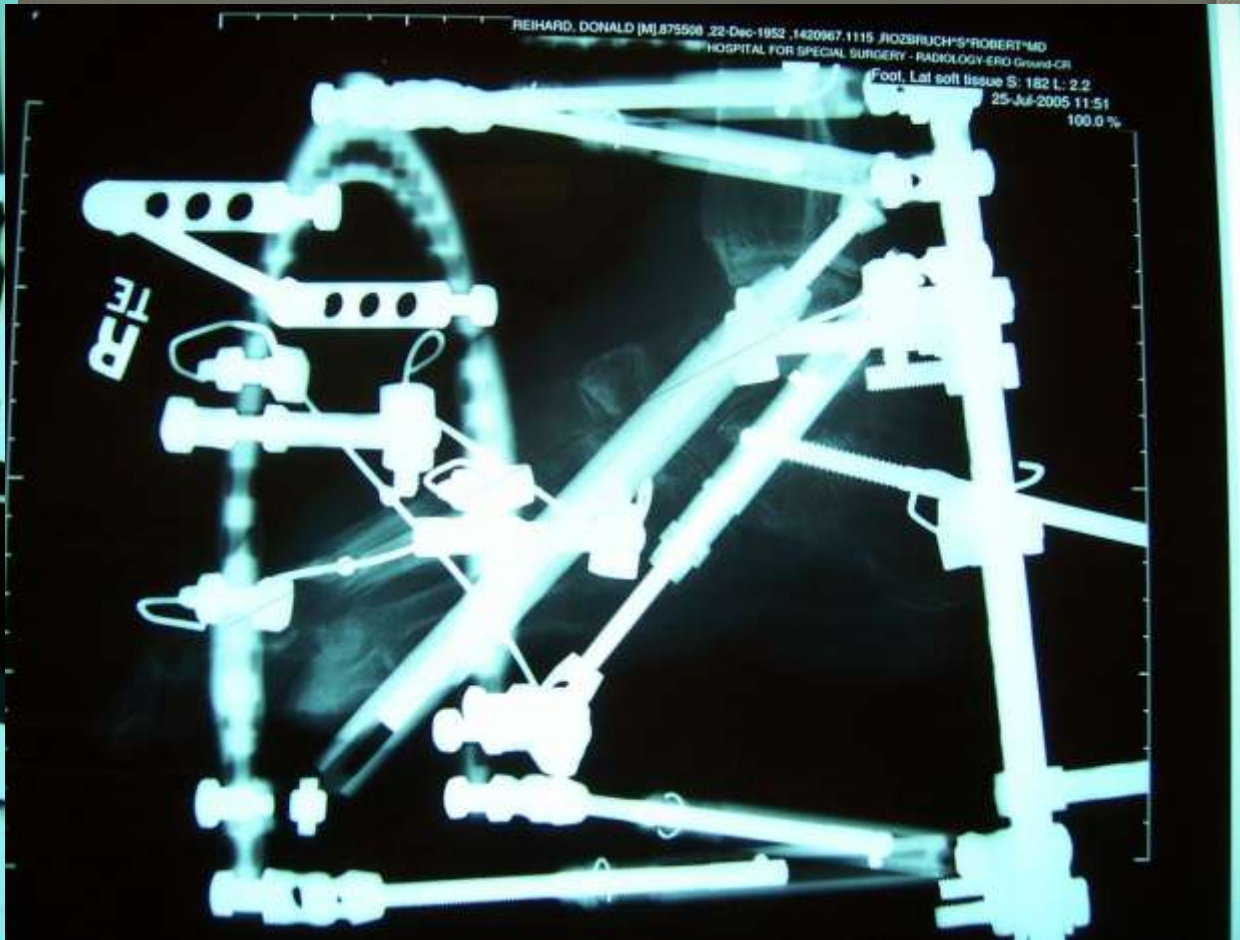
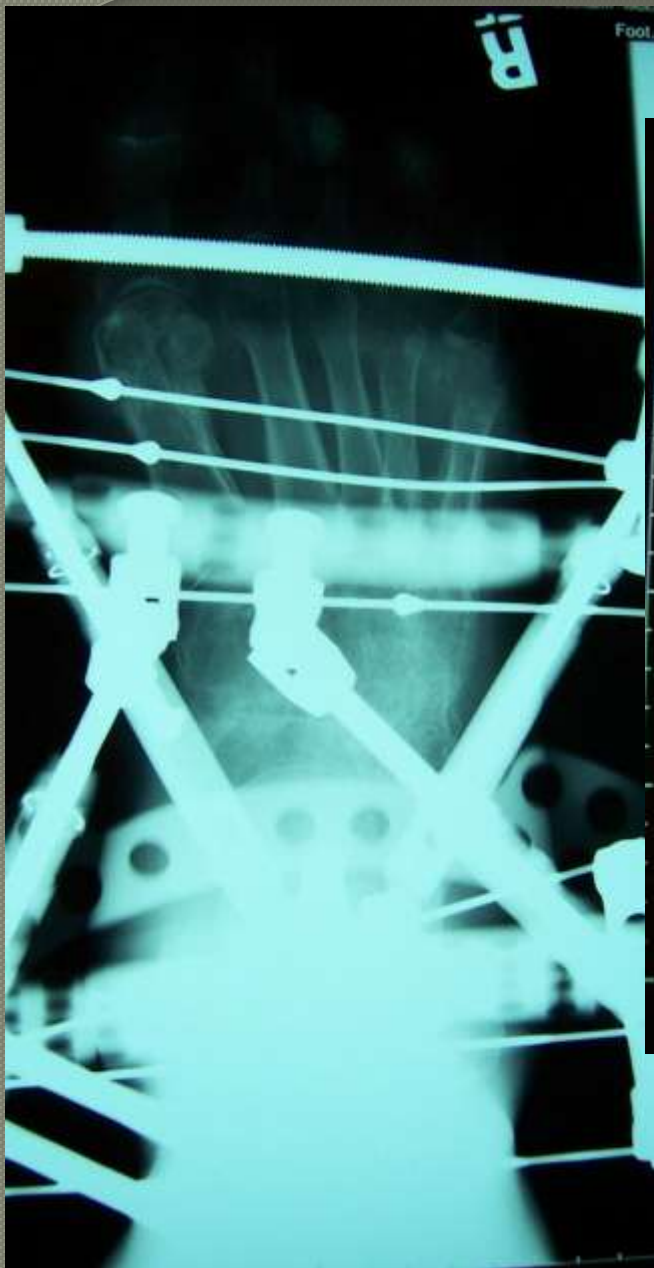


Equino-varus  
Cavus-supination

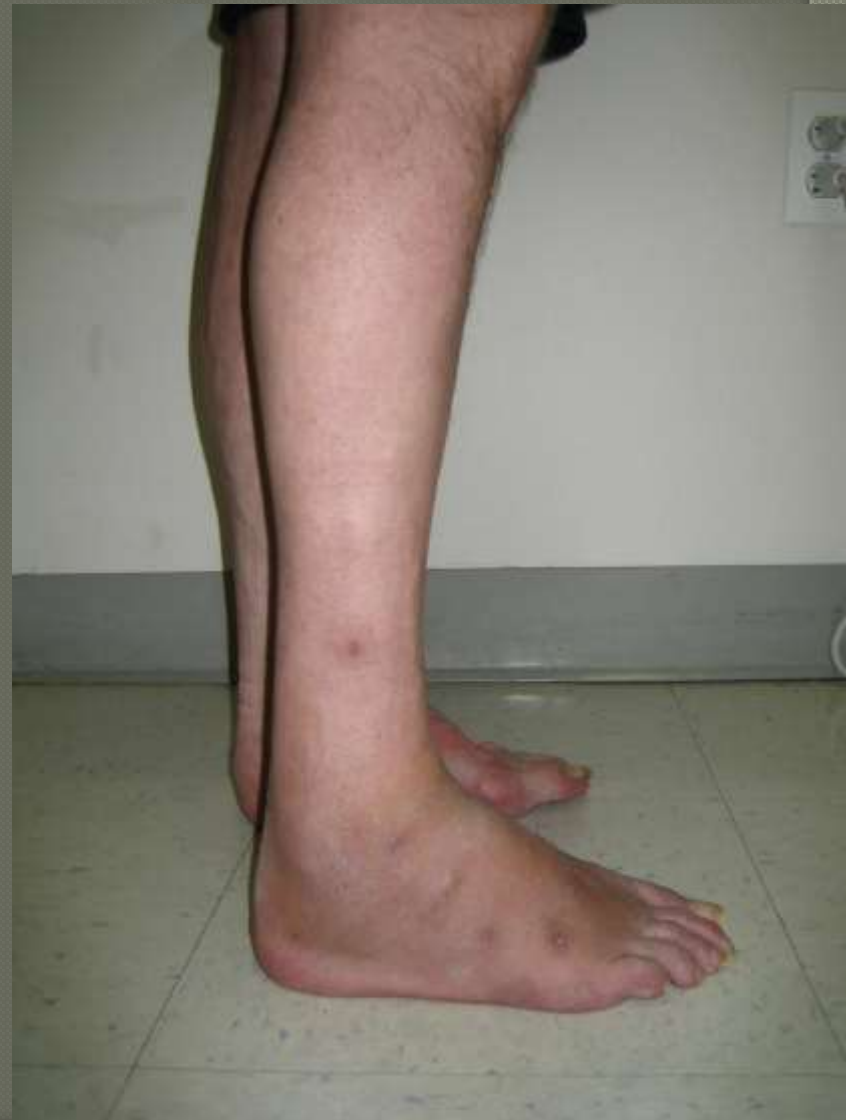
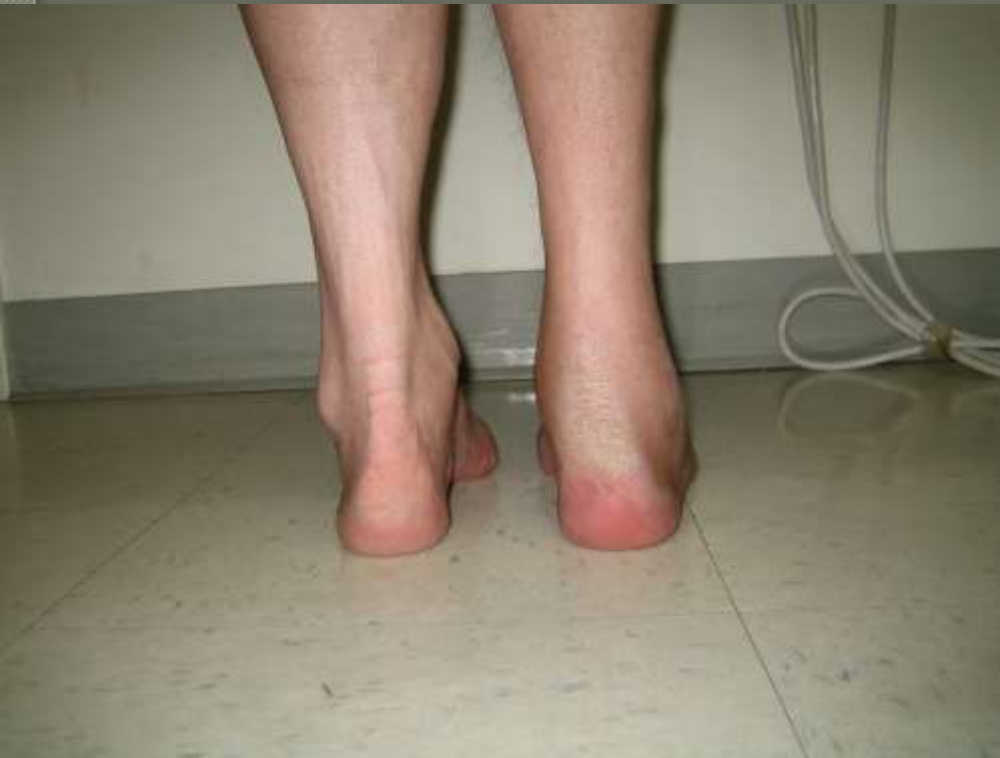




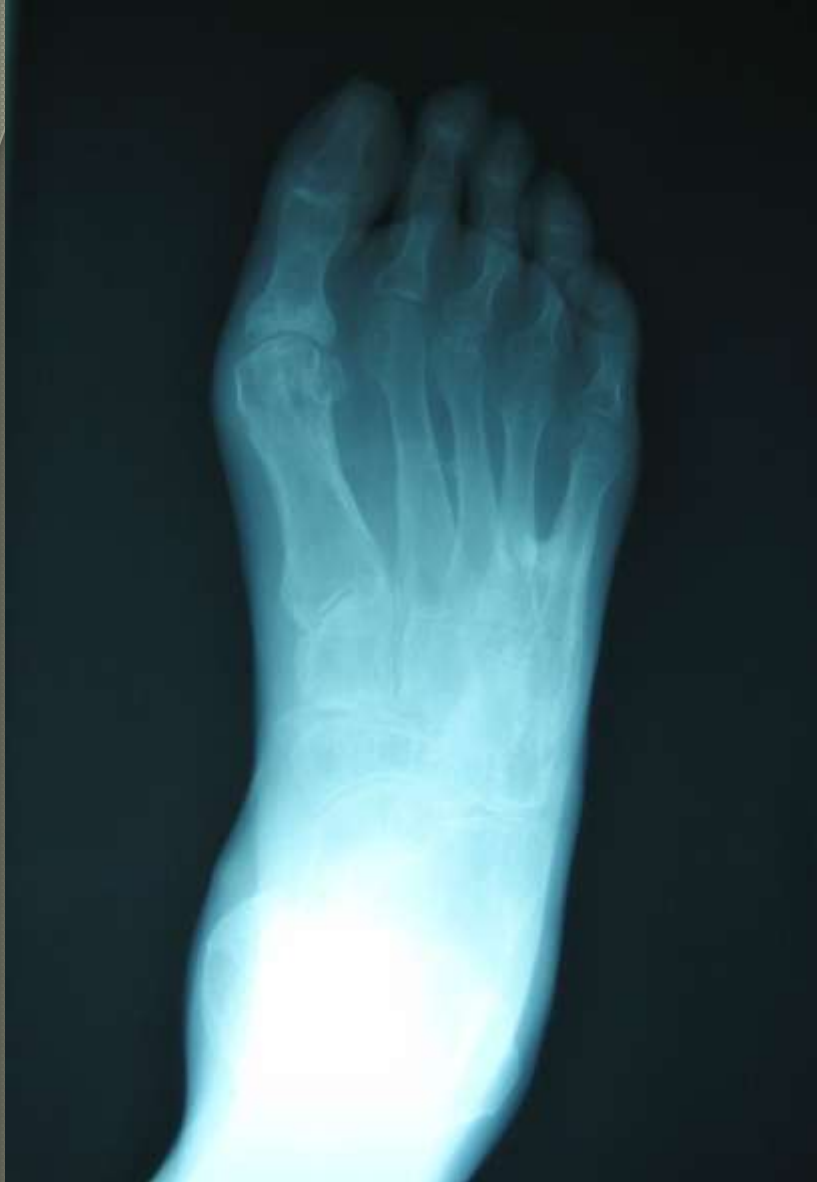

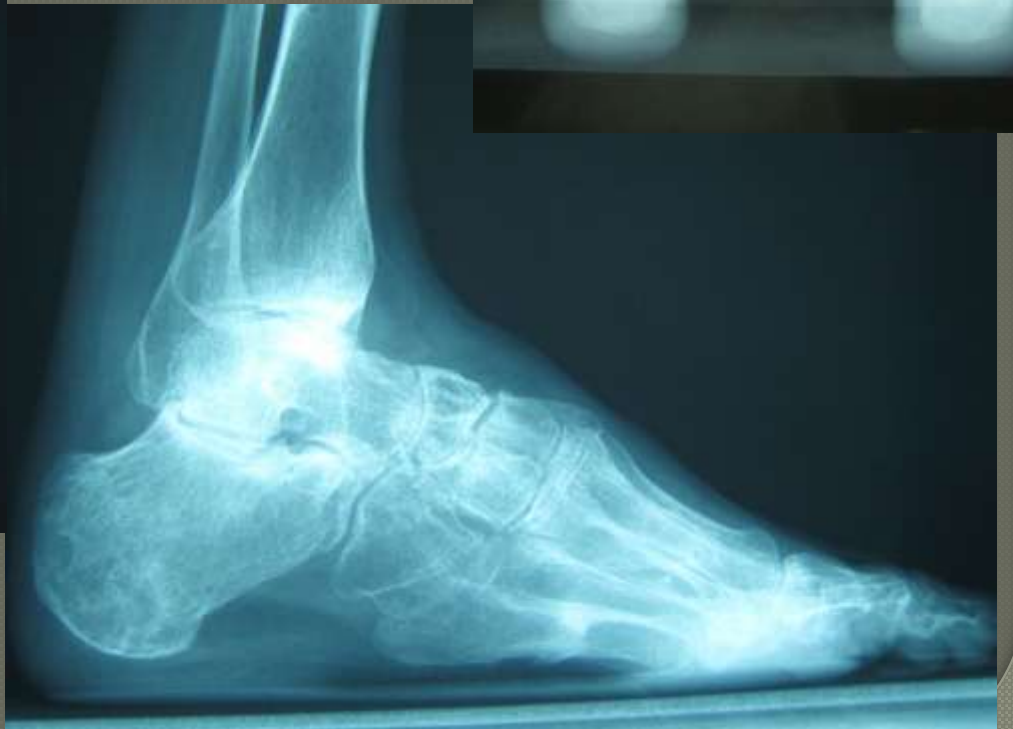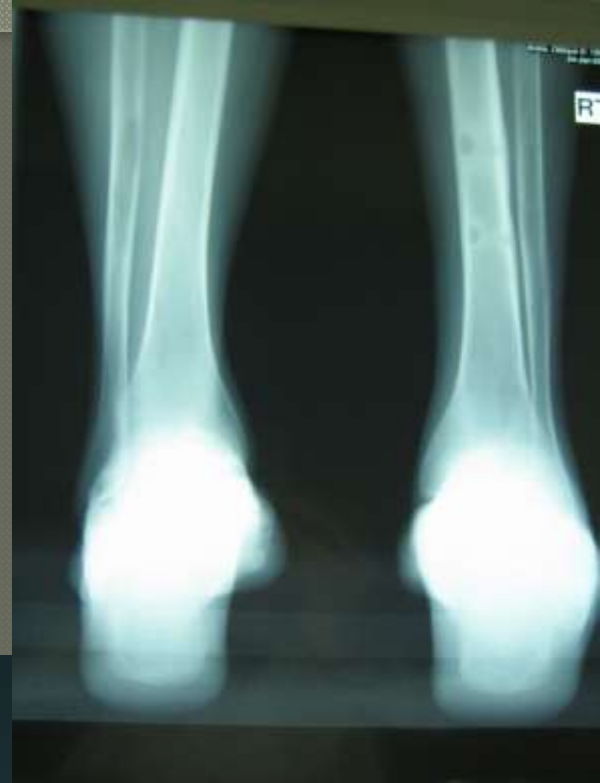After







After



# Thank You



LIMB .COM

[www.hss.edu/limblengthening](http://www.hss.edu/limblengthening)