

Limb Deformity Correction

presented at McGill University, Visiting Professor,
February 29 – March 1, 2012

S. Robert Rozbruch, MD

**Chief, Limb Lengthening & Complex Reconstruction Service
Professor of Clinical Orthopedic Surgery
Weill Cornell Medical College**



HOSPITAL FOR
SPECIAL SURGERY

LIMB .COM

The logo graphic for Limb Lengthening features the words "LENGTHENING" in a blue, sans-serif font, enclosed within a black rectangular frame that has vertical lines extending from the top and bottom edges, resembling a surgical frame or a measurement tool.

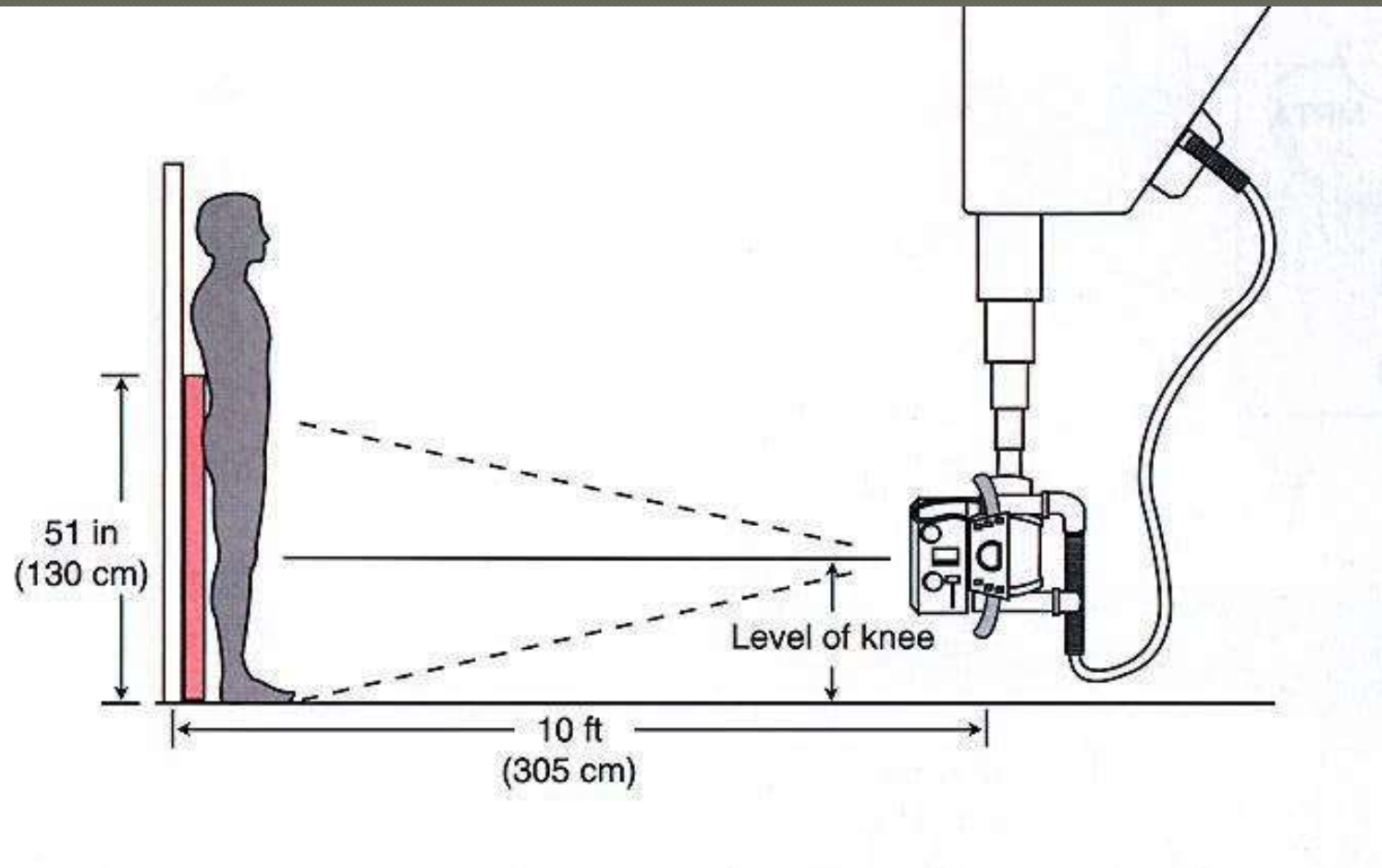
Assessment

- History
 - infection
 - static versus progressive deformity
- Physical Exam
 - scars, previous surgery
 - rotational deformities
- Radiographs

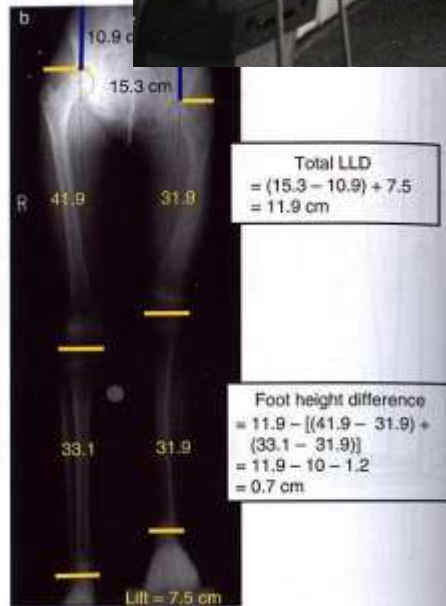
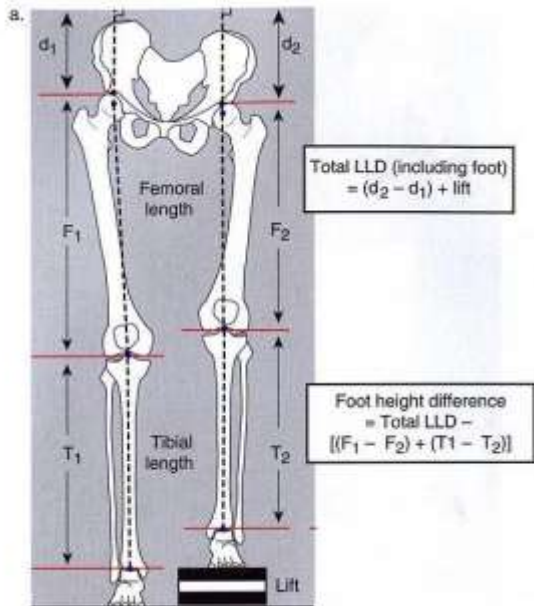
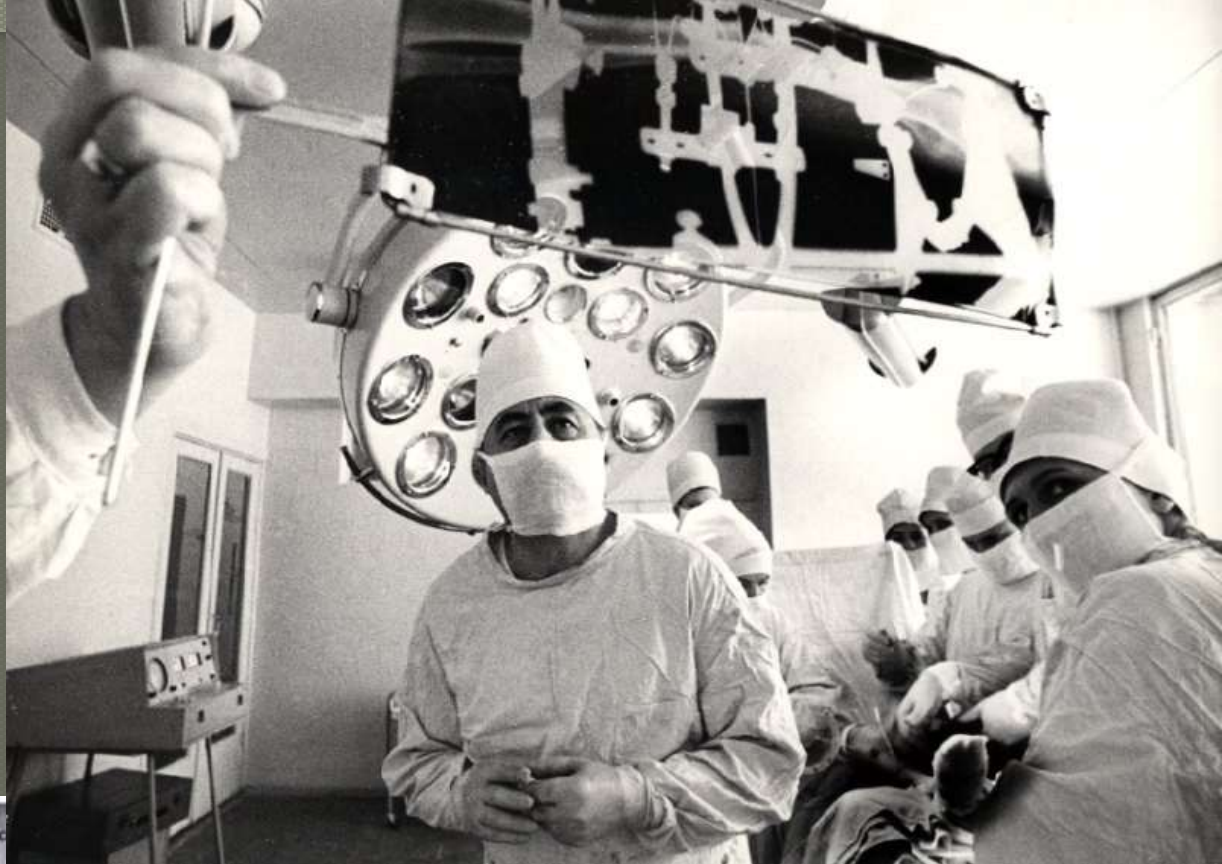


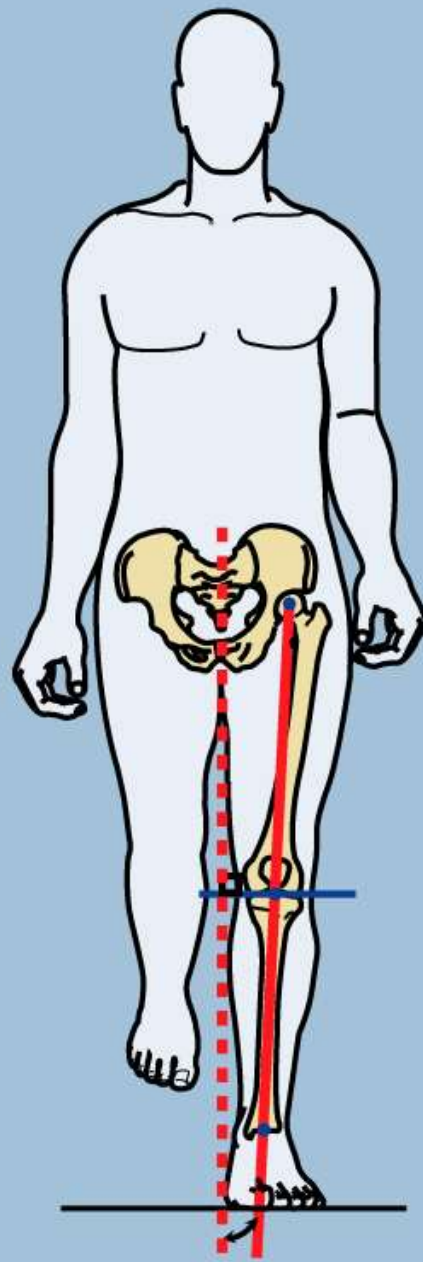
Erect-leg radiograph

10 feet, 5% mag.



Radiographic analysis



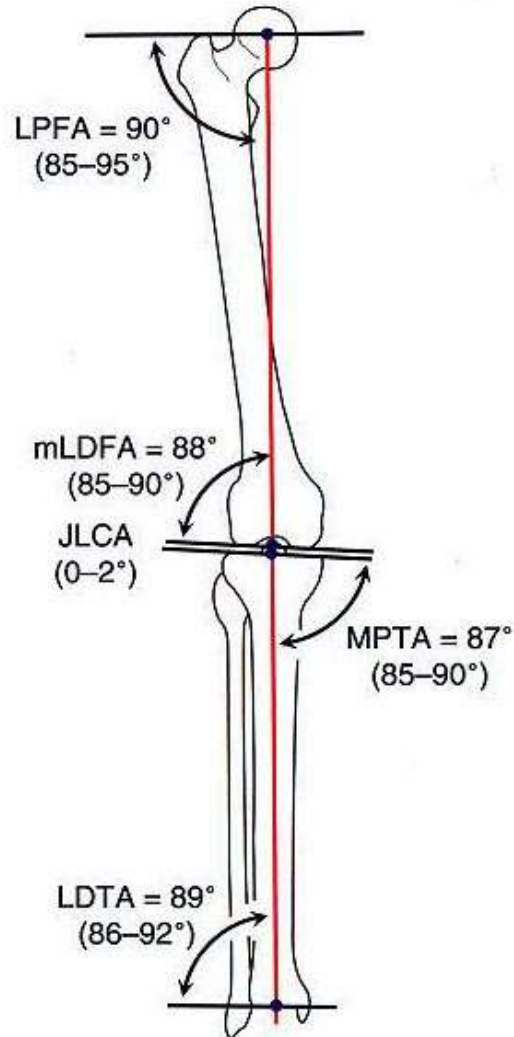


3°
Midline

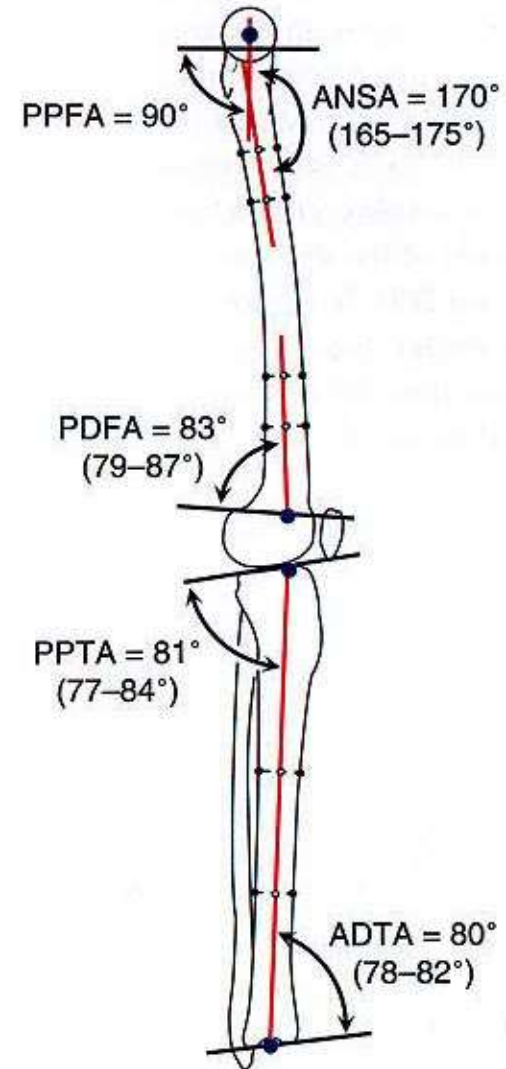
Normal alignment parameters

a.

Mechanical



Sagittal

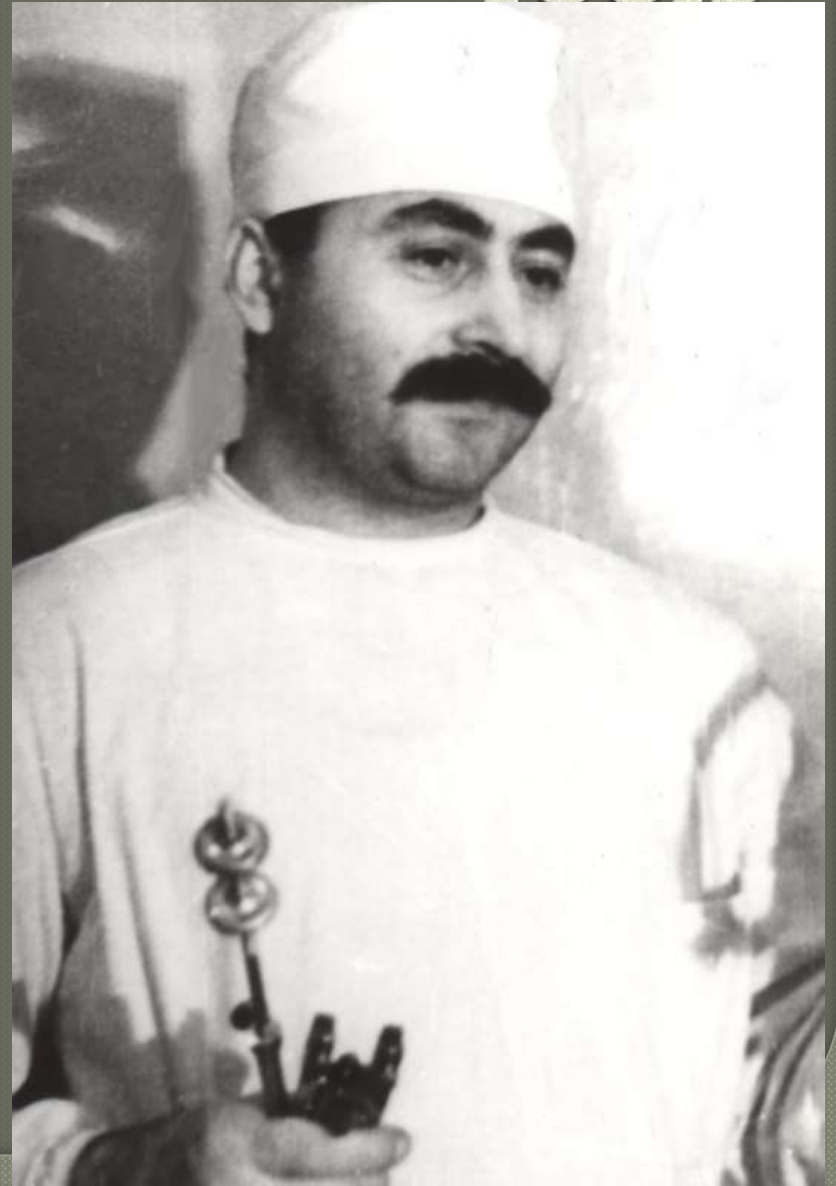

Method

- Osteotomy
- Correction through nonunion
- Acute
- Gradual
- Arthroplasty
- arthrodesis

Tools

- External Fixation
 - Static
 - Dynamic
- Intramedullary rod
 - Static
 - Dynamic
- Plate/ screws



The Ilizarov Method

- Address all facets of deformity including length
- Gradual correction
 - Less traumatic
 - Patient feedback for position
 - Less risk of NV insult
- Minimally invasive exposure
- Weight bearing is allowed

What's so great about the TSF

○ Easier, faster

- Simultaneous correction of angulation, translation, rotation, and length
- Uses a VIRTUAL hinge
- No major frame adjustments needed
- Ease of application
 - Rings first total residual method
 - Apply rings comfortably to each limb segment
- Computer assisted

Does the Taylor Spatial Frame Accurately Correct Tibial Deformities?

S. Robert Rozbruch MD, Kira Segal BA,
Svetlana Ilizarov MD, Austin T. Fragomen MD,
Gabriel Ilizarov MD

Received: 23 March 2009 / Accepted: 27 October 2009 / Published online: 13 November 2009
© The Association of Bone and Joint Surgeons® 2009

Abstract

Background Optimal leg alignment is the goal of tibial osteotomy. The Taylor Spatial Frame (TSF) and the Ilizarov method enable gradual realignment of angulation and translation in the coronal, sagittal, and axial planes, therefore, the term six-axis correction.

Questions/purposes We asked whether this approach would allow precise correction of tibial deformities.

Methods We retrospectively reviewed 102 patients (122 tibiae) with tibial deformities treated with percutaneous osteotomy and gradual correction with the TSF. The proximal osteotomy group was subdivided into two sub-

with a varus deformity and from 96° to 85° in patients with a valgus deformity. In the middle osteotomy group, all patients had less than 5° coronal plane deformity and 15 of 17 patients had less than 5° sagittal plane deformity. In the distal osteotomy group, the lateral distal tibial angle improved from 77° to 86° in patients with a valgus deformity and from 101° to 90° for patients with a varus deformity.

Conclusions Gradual correction of all tibial deformities with the TSF was accurate and with few complications.

Level of Evidence Level IV, therapeutic study. See the Guidelines for Authors for a complete description of levels

Deformity Parameters

○ Frontal plane

- Angulation (e.g., varus)
- Translation

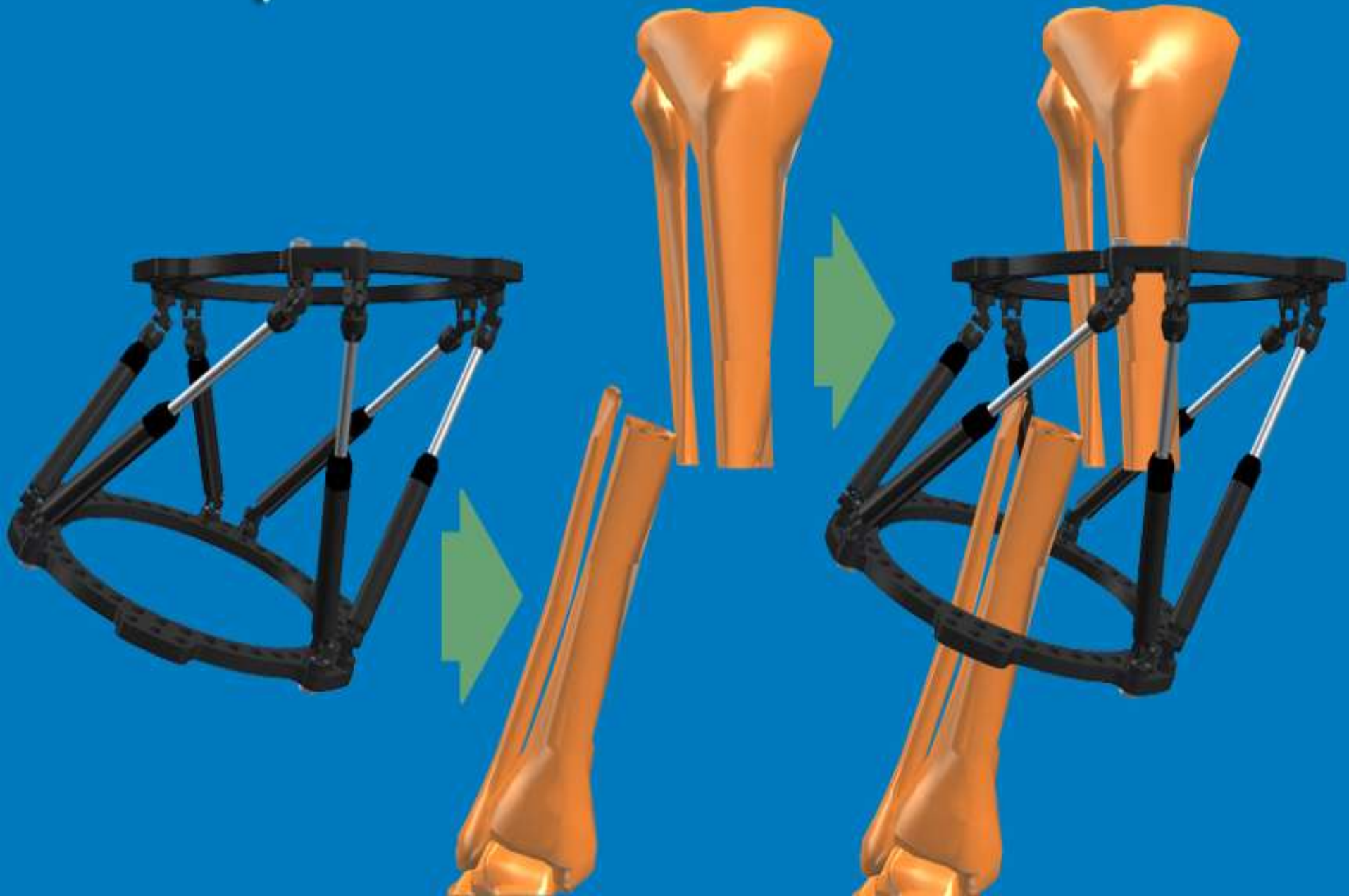○ Sagittal Plane

- Angulation (e.g., procurvatum)
- Translation

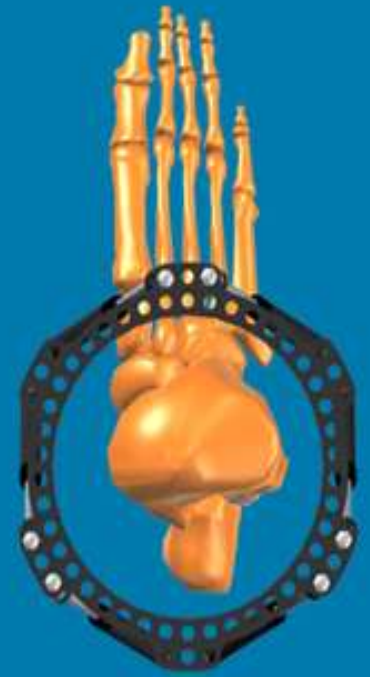
○ Axial Plane

- Angulation (rotational deformity)
- Translation (length, e.g, short)

Chronic Deformity



Chronic Deformity - Corrected



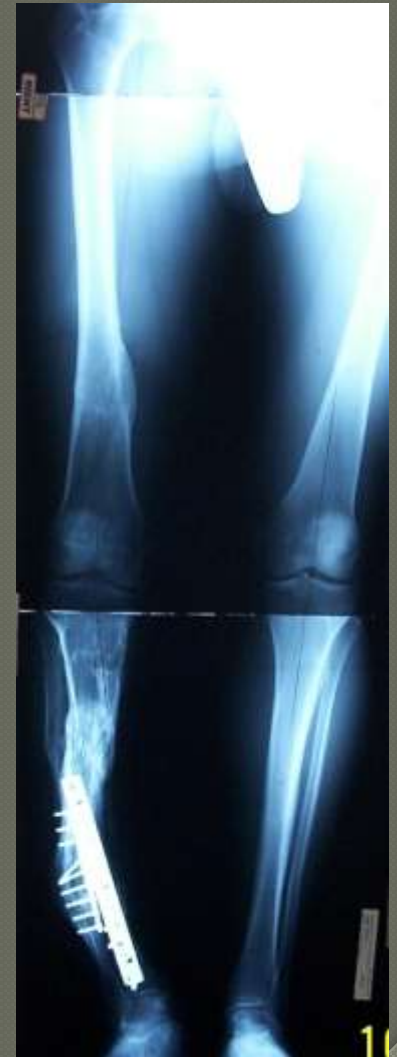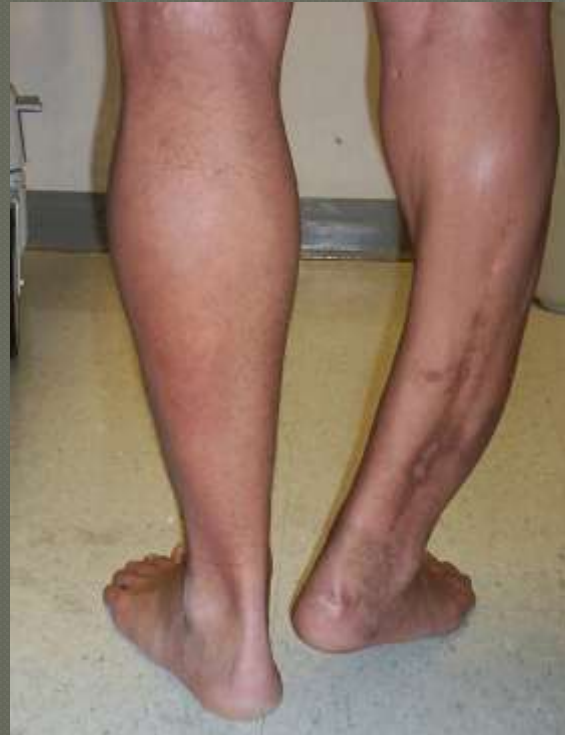Nonunions

Malunions



Indications for External Fixation

- Large/ complex deformity
- Multi-level deformity
- Poor skin
- Infection
- LLD
- Bone loss



Repair of Tibial Nonunions and Bone Defects with the Taylor Spatial Frame

S. Robert Rozbruch, MD, Jacob S. Pugsley, MD, Austin T. Frugomen, MD, and Svetlana Ilizarov, MD

Objective: To investigate the outcomes of tibial nonunions and bone defects treated with the Taylor Spatial Frame (TSF) using the Ilizarov method.

Design: Retrospective.

Setting: Limb Lengthening and Deformity Service at an academic medical center.

Patients: Thirty-eight consecutive patients with 38 tibial nonunions were treated with the TSF. There were 23 patients with bone defects (average 5.9 cm) and 22 patients with leg-length discrepancy (LLD) (average 3.1 cm) resulting in an average longitudinal deficiency (sum of bone defect and LLD) of 6.5 cm in 31 patients (1–16). The average number of previous surgeries was 4 (0–20). At the time of surgery, 19 (50%) nonunions were diagnosed as infected.

Intervention: All patients underwent repair of the nonunion and application of a TSF. Patients with bone loss were additionally treated with lengthening. Infected nonunions were treated with 6 weeks of culture-specific antibiotics.

Main Outcome Measurements: Bony union, time in frame, eradication of infection, leg-length discrepancy, deformity, Short Form-36 (SF-36) scores, American Academy of Orthopedic Surgeons (AAOS) lower-limb scores, and Association for the Study of the Method of Ilizarov (ASAMI) bone and functional results.

Results: Bony union was achieved after the initial treatment in 27 (71%) patients. The presence of bone infection correlated with initial failure and persistent nonunion ($P = 0.03$). The 11 persistent nonunions were re-treated with TSF reapplication in 4, intramedullary nailing in 3, plate fixation in 2, and amputation in 2 patients. This resulted in final bony union in 36 (95%) patients. The average LLD was 1.8 cm (0–6.8) (SD 2). Alignment with deformity less than 5° was achieved in 32 patients and alignment between 6° and 10° was achieved in 4 patients. Significant improvement of Short Form-36 (SF-36) scores was noted in physical role ($P = 0.03$) and physical function ($P = 0.001$). AAOS lower-limb module scores significantly improved from 36 to 82 ($P < 0.001$). ASAMI bone and functional outcomes were excellent or good in 36 and 34 patients, respectively. The number of

previous surgeries correlated inversely with the ASAMI bone ($P = 0.003$) and functional ($P = 0.001$) scores.

Conclusions: One can comprehensively approach tibial nonunions with the TSF. This is particularly useful in the setting of stiff hypertrophic nonunion, infection, bone loss, LLD, and poor soft-tissue envelope. Infected nonunions have a higher risk of failure than noninfected cases. Treatment after fewer failed surgeries will lead to a better outcome. Internal fixation can be used to salvage initial failures.

Key Words: Taylor Spatial Frame (TSF), Ilizarov method, tibial nonunions, bone defects

(*J Orthop Trauma* 2008;22:88–95)

INTRODUCTION

Tibial nonunions have been treated with a variety of surgical methods including plate osteosynthesis with bone graft,^{1–3} intramedullary nailing,^{4–7} and external fixation.^{8–14} The complexity of a tibial nonunion can be variable and depends on several factors. The “personality of a fracture” is a term and concept introduced by Schatzker¹⁵ and its use underscores the complexity of a particular problem and helps organize a treatment approach. We have found it helpful to apply this concept to nonunion. The personality of a tibial nonunion is determined by a number of factors including bone loss; radiographic appearance and stiffness as they relate to the nonunion biology; deformity; leg-length discrepancy (LLD); presence or history of infection; soft-tissue envelope; retained hardware; and patient factors including diabetes, smoking, and neuropathy. Although the use of internal fixation is effective in the treatment of selected tibial nonunions, these techniques have their limitations.

The Ilizarov method has gained many advocates for the treatment of tibial nonunions over the last 2 decades, particularly hypertrophic nonunions^{5,11,13,15,16,19} and nonunions associated with bone loss,^{9,12,20–23} infection,^{9,20,21} and a poor soft-tissue envelope.^{12,20,26} The classic Ilizarov frame has been used to correct all deformity,^{10,18,27–40} including lengthening and bone transport.^{30,32,36} However, deformity correction with components of angulation, translation, and rotation requires a staged correction and frame modifications.

The TSF (Smith and Nephew, Inc., Memphis, Tennessee) is an evolution of the original Ilizarov frame and uses the same concepts of distraction osteogenesis as the classic frame. However, it uses a virtual hinge and a computer program to

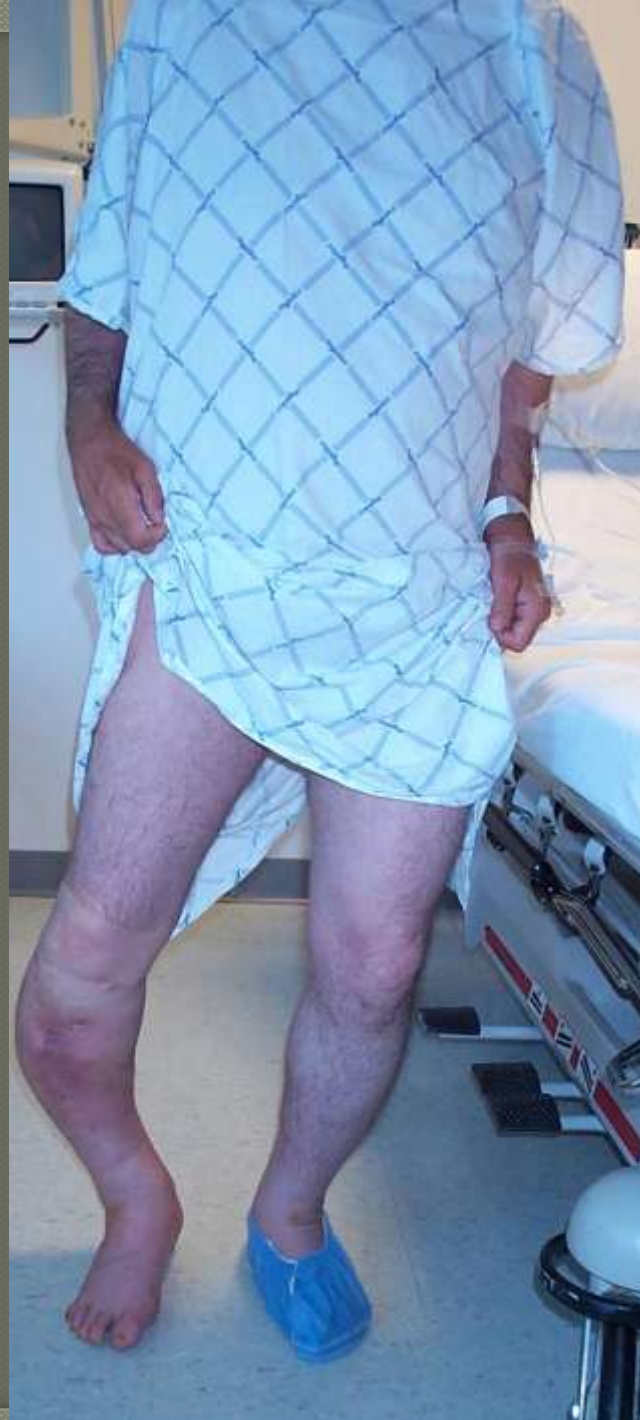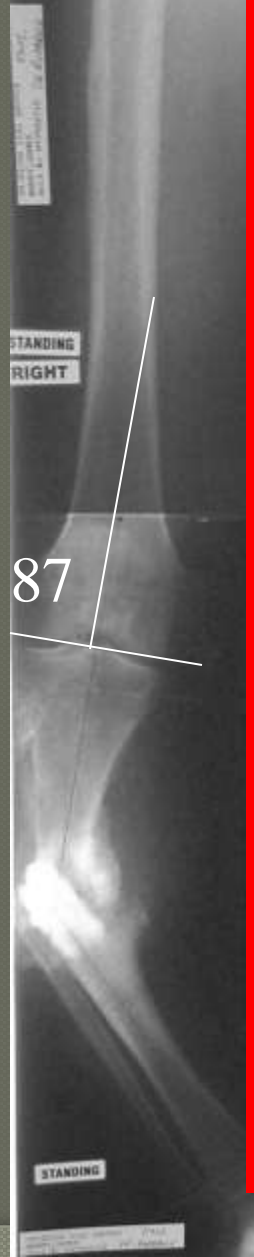Accepted for publication November 19, 2007.

From the Institute for Limb Lengthening and Reconstruction, Limb Lengthening and Deformity Service, Hospital for Special Surgery, Weill Medical College of Cornell University, New York, New York.
Reprints: S. Robert Rozbruch, MD, 535 East 70th Street, New York, New York 10021 (e-mail: Rozbruch@hss.edu).

Copyright © 2008 by Lippincott Williams & Wilkins

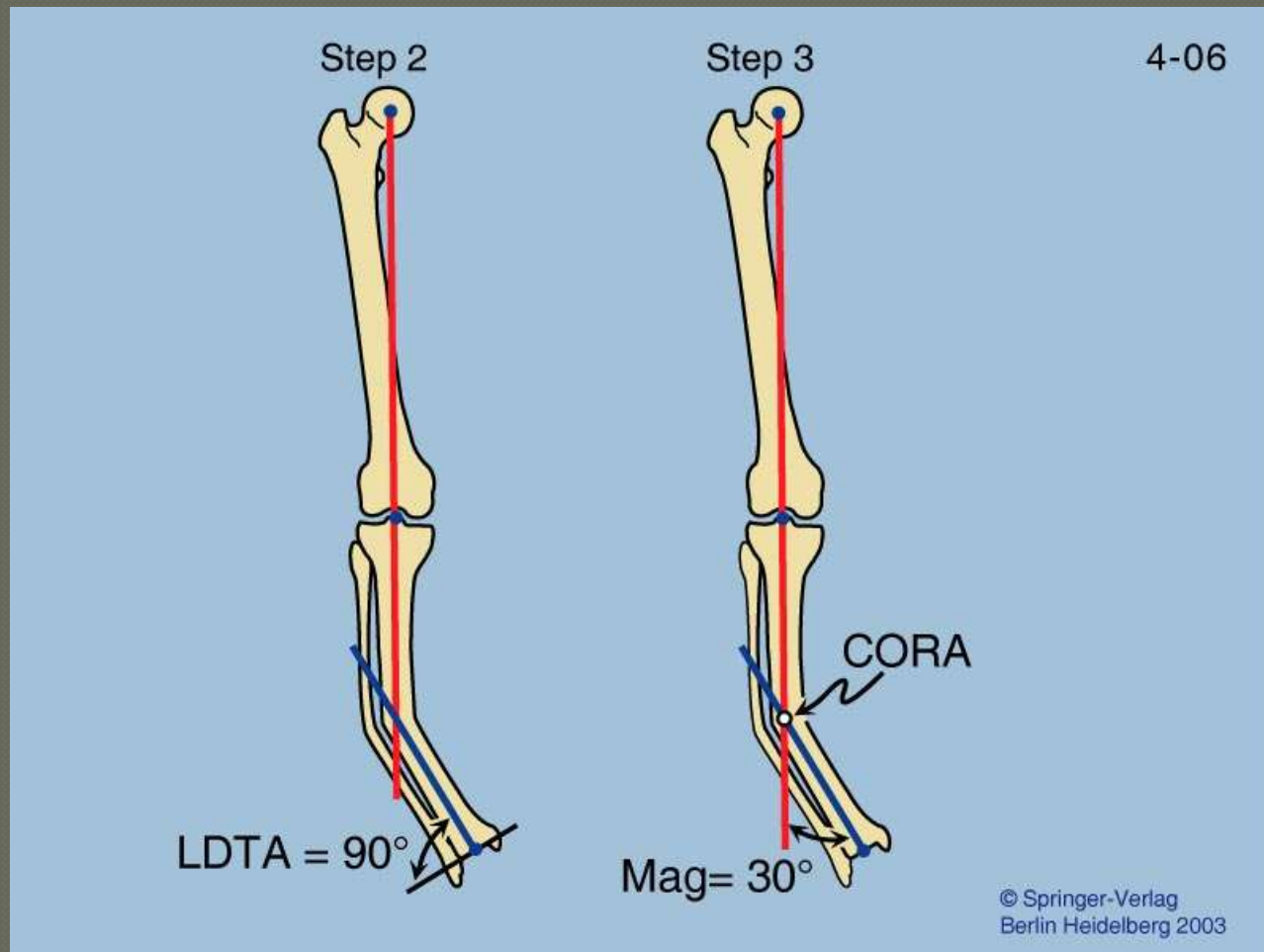
Rozbruch et al. Repair of Tibial Nonunions and Bone Defects with the Ilizarov/TSF; JOT 2008

- 38 patients with tibial nonunions
- **Nonunion type:**
 - Mobile/ atrophic (23)
 - Partially mobile/ normotrophic (9)
 - Stiff/ hypertrophic (6)
- Bone Defects (23)
 - Average 5.9 cm (range: 1.5-16 cm)
- **50% infected nonunions**
- 90% union rate

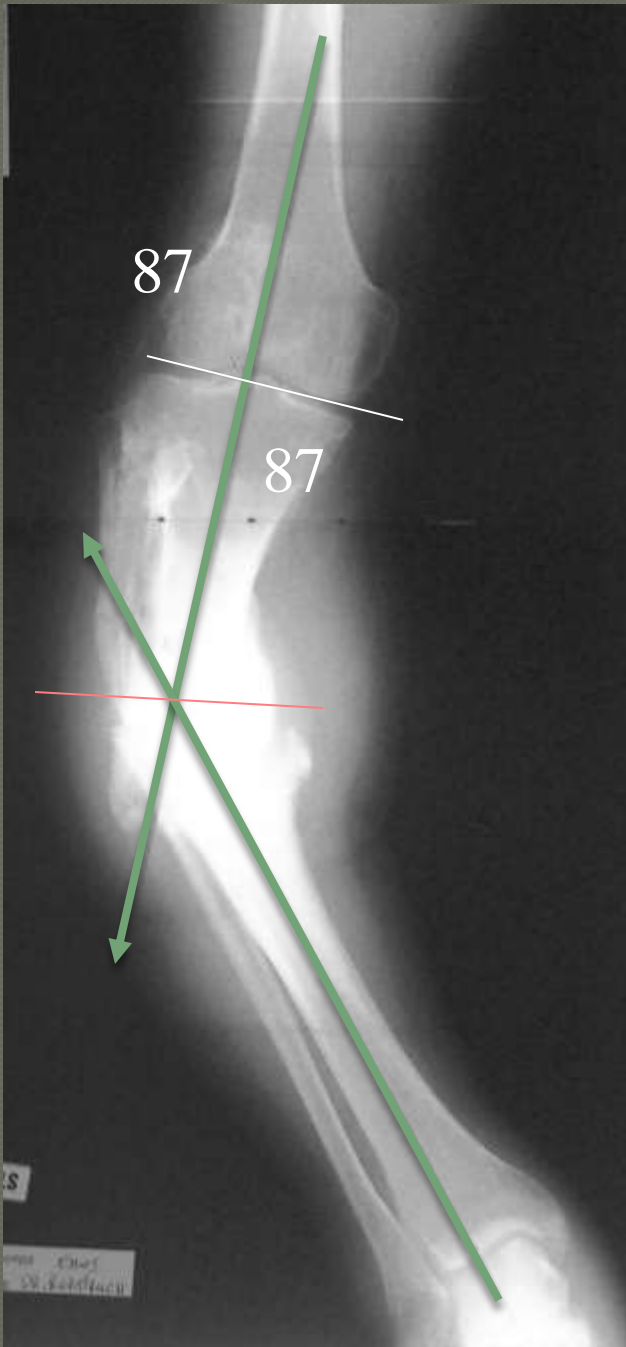


CORA and magnitude of deformity

Normal Femur and Varus Tibia



Use extension of femur mech axis for proximal tibia mech. axis

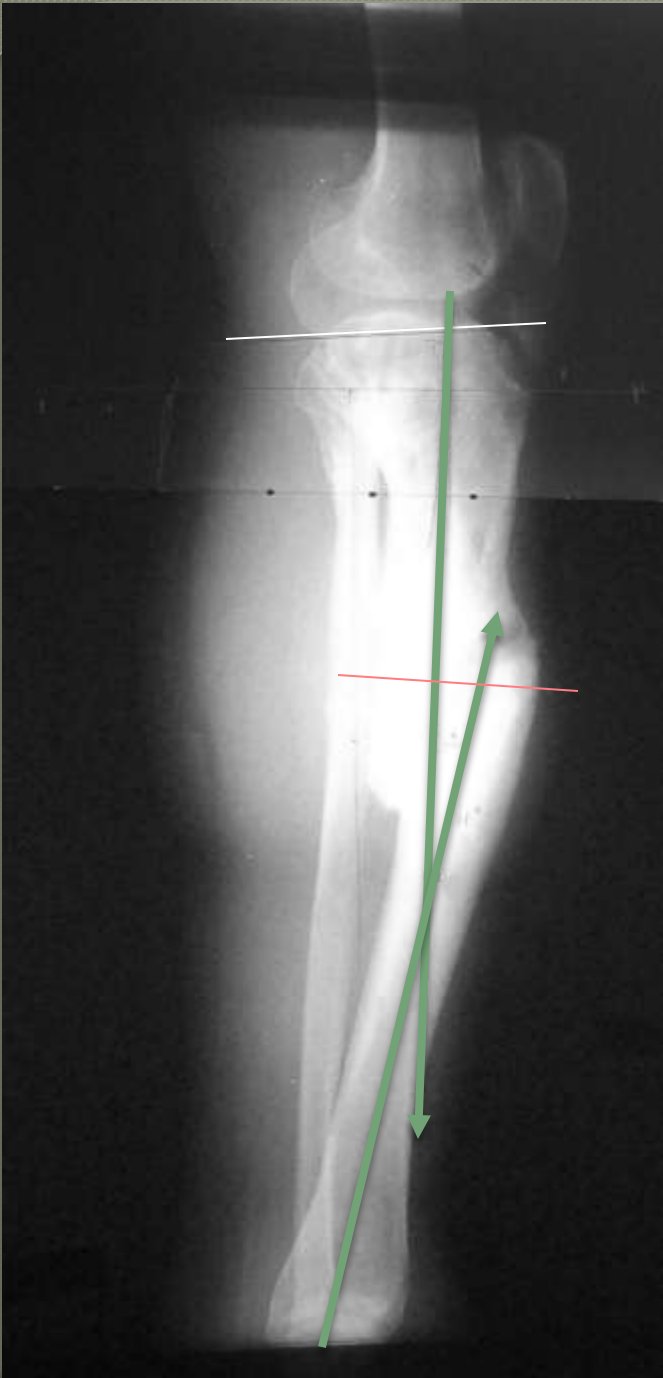

Radiographs


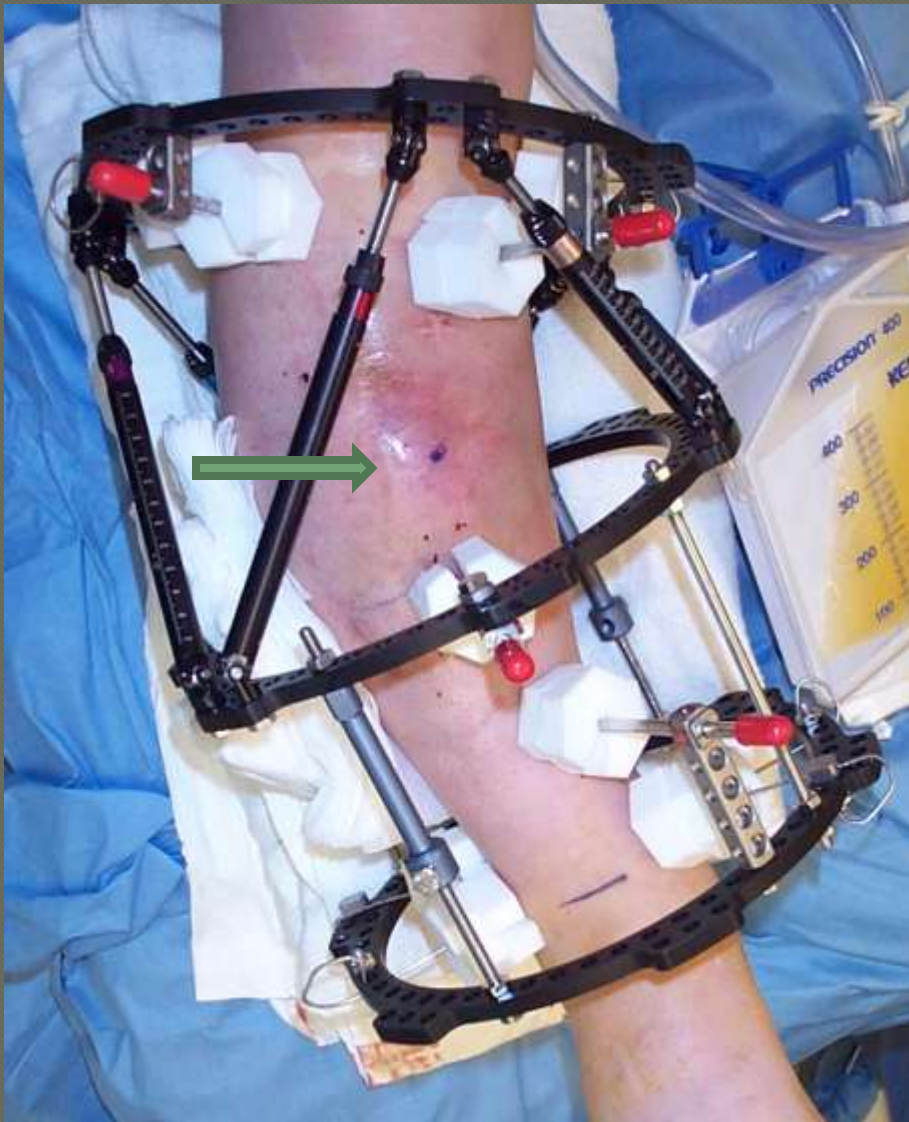
- 39 degrees varus deformity

Radiographs

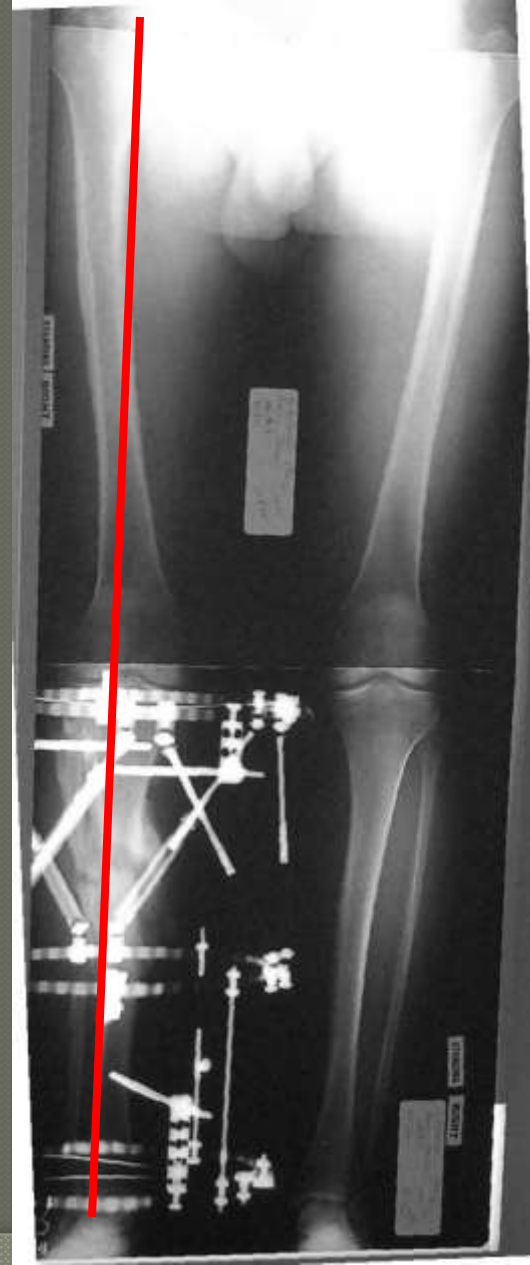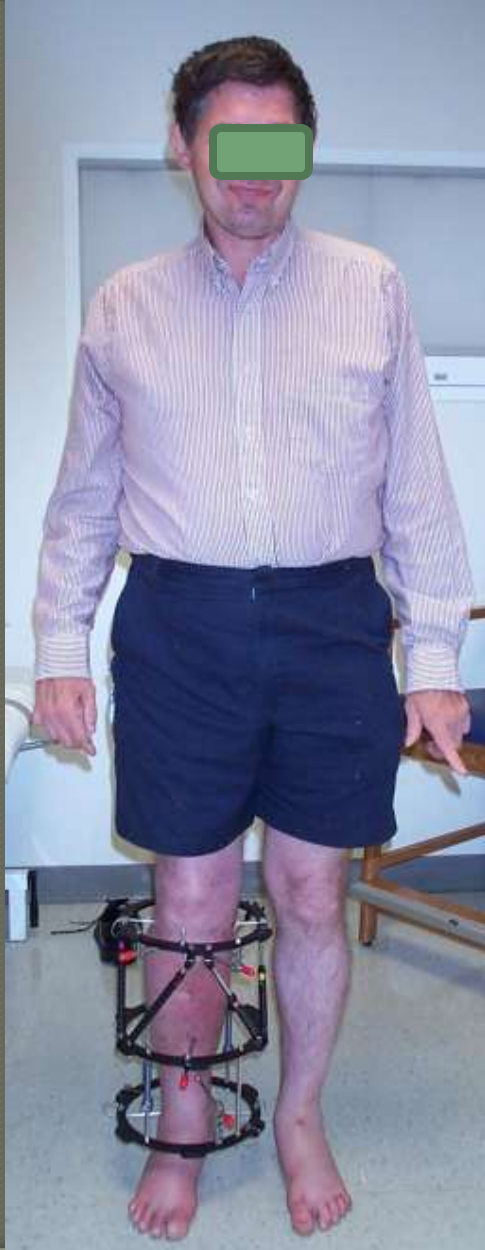- 11 degrees procurvatum
- Anterior translation
 - 9 mm
- Hypertrophic Nonunion

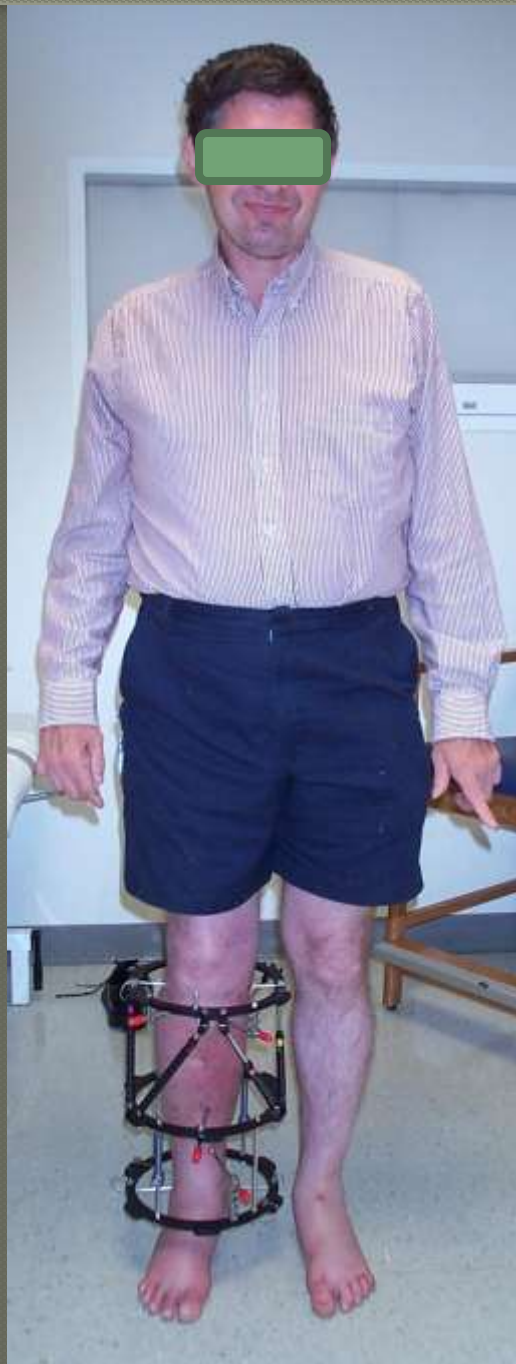
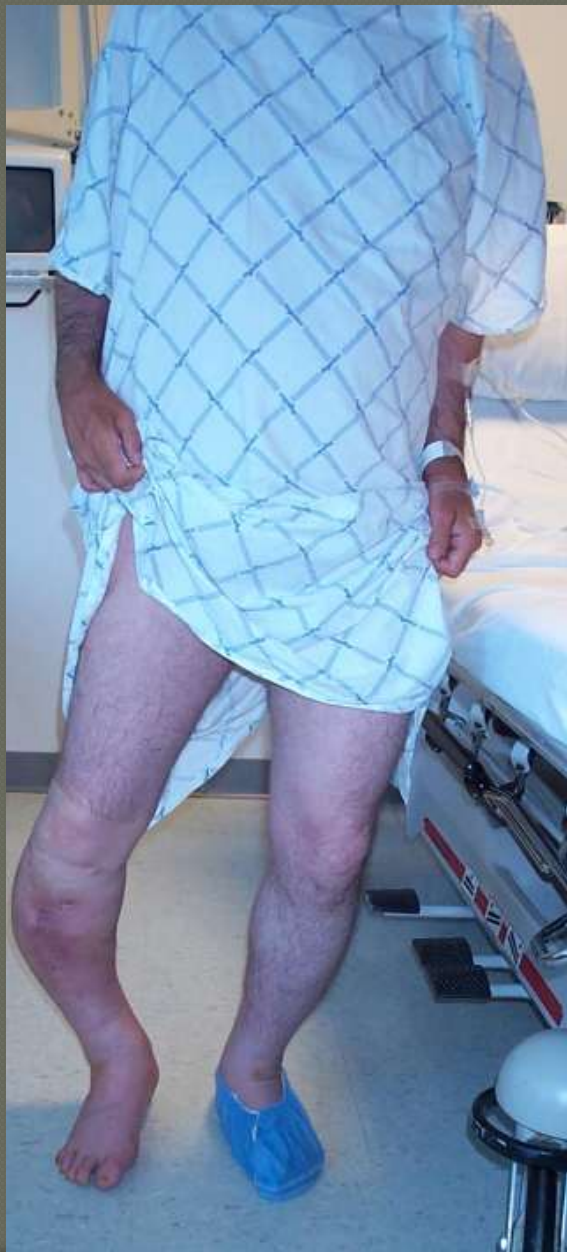
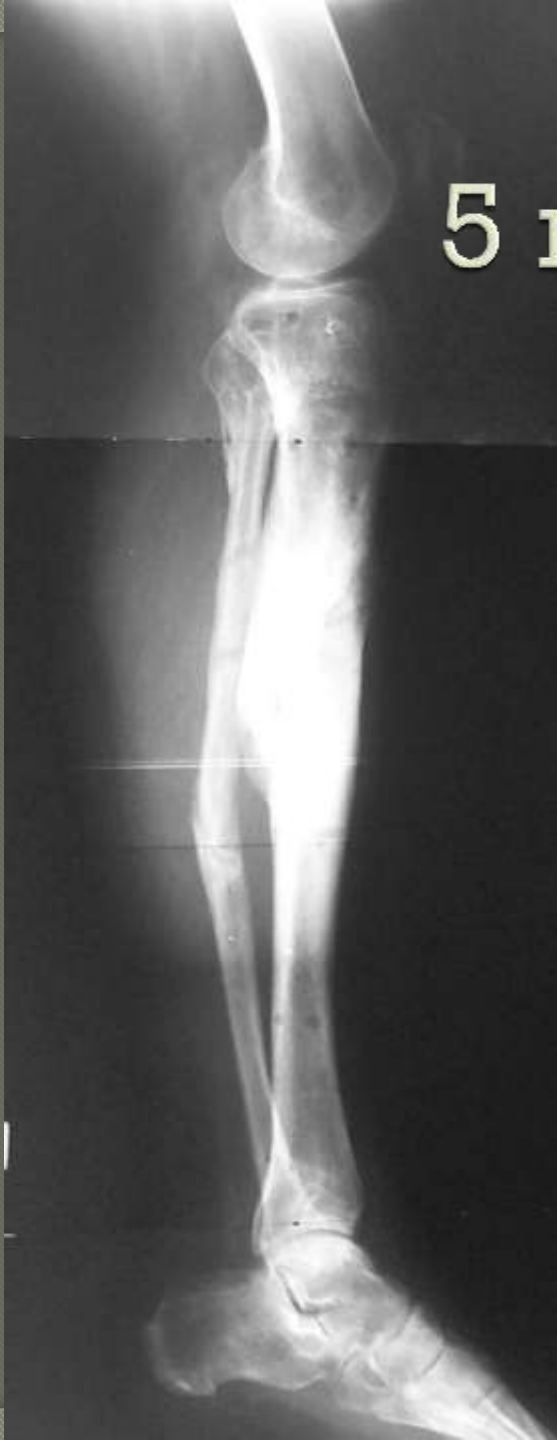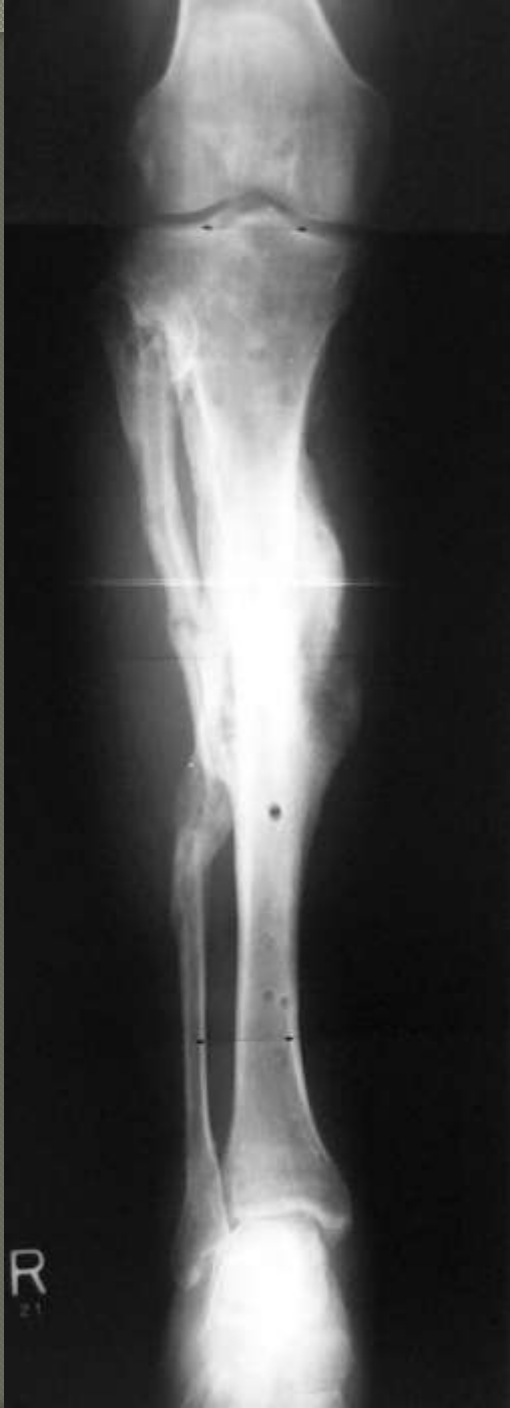Surgery



End of Distraction, day #38





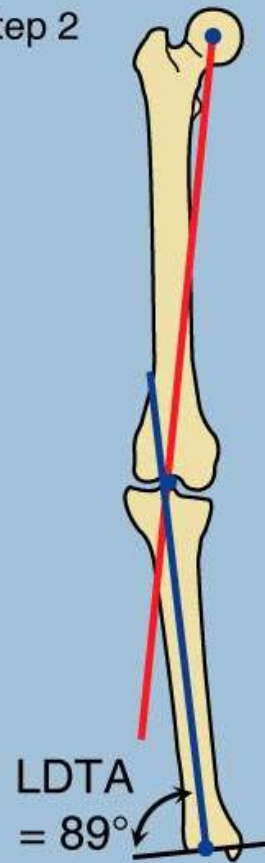


5 months

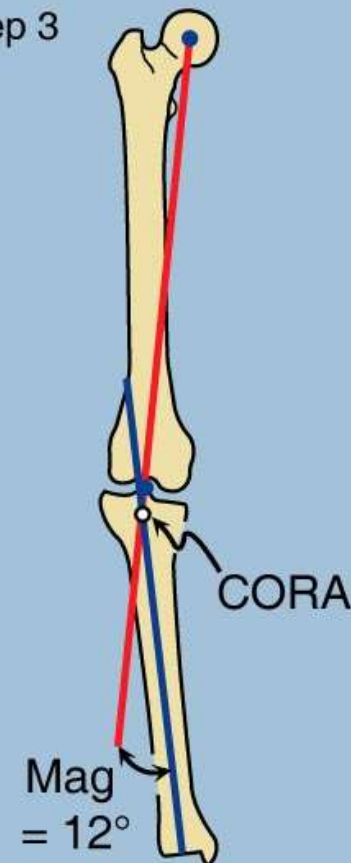
R

Normal Femur and Varus Tibia Metaphyseal deformity

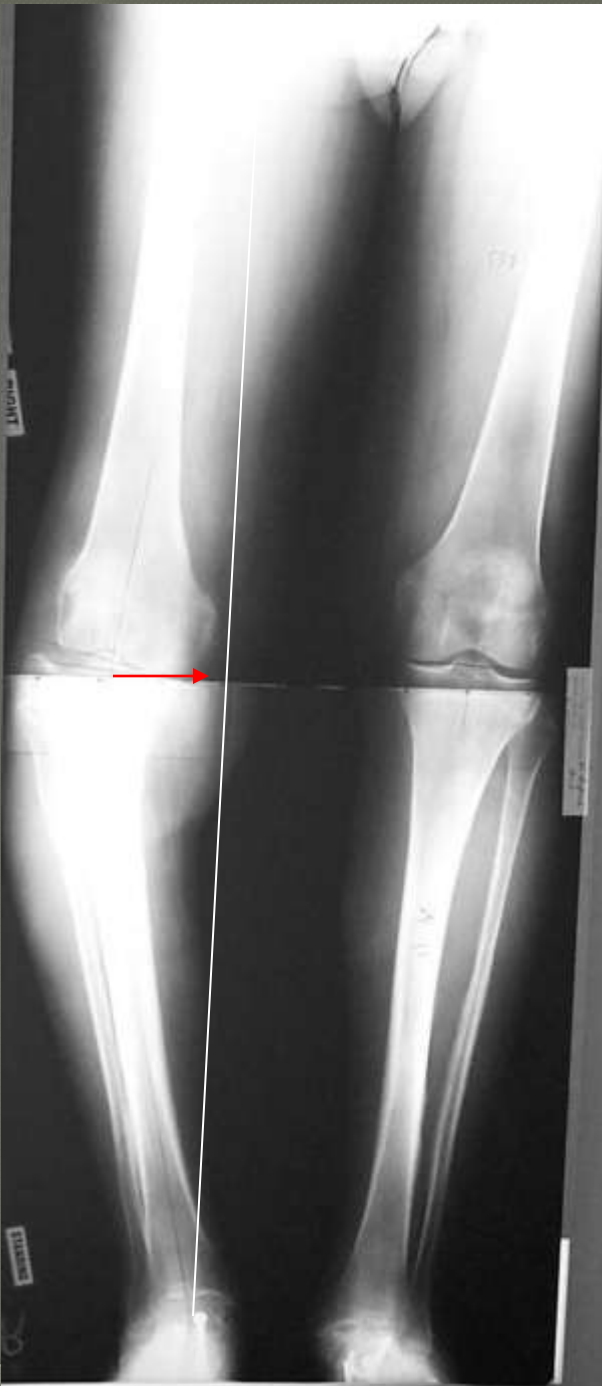Step 2

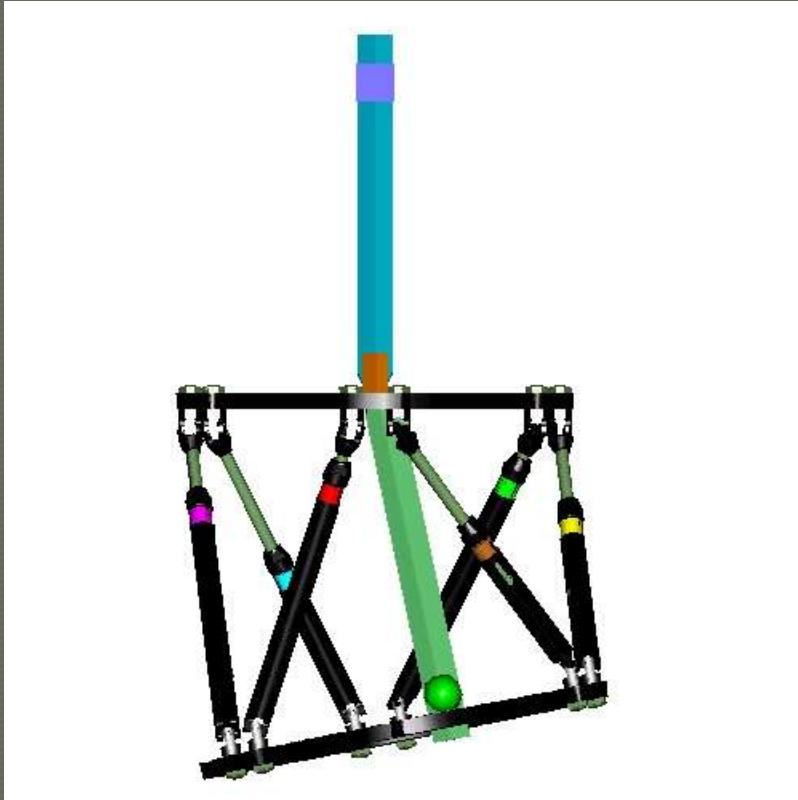


Step 3

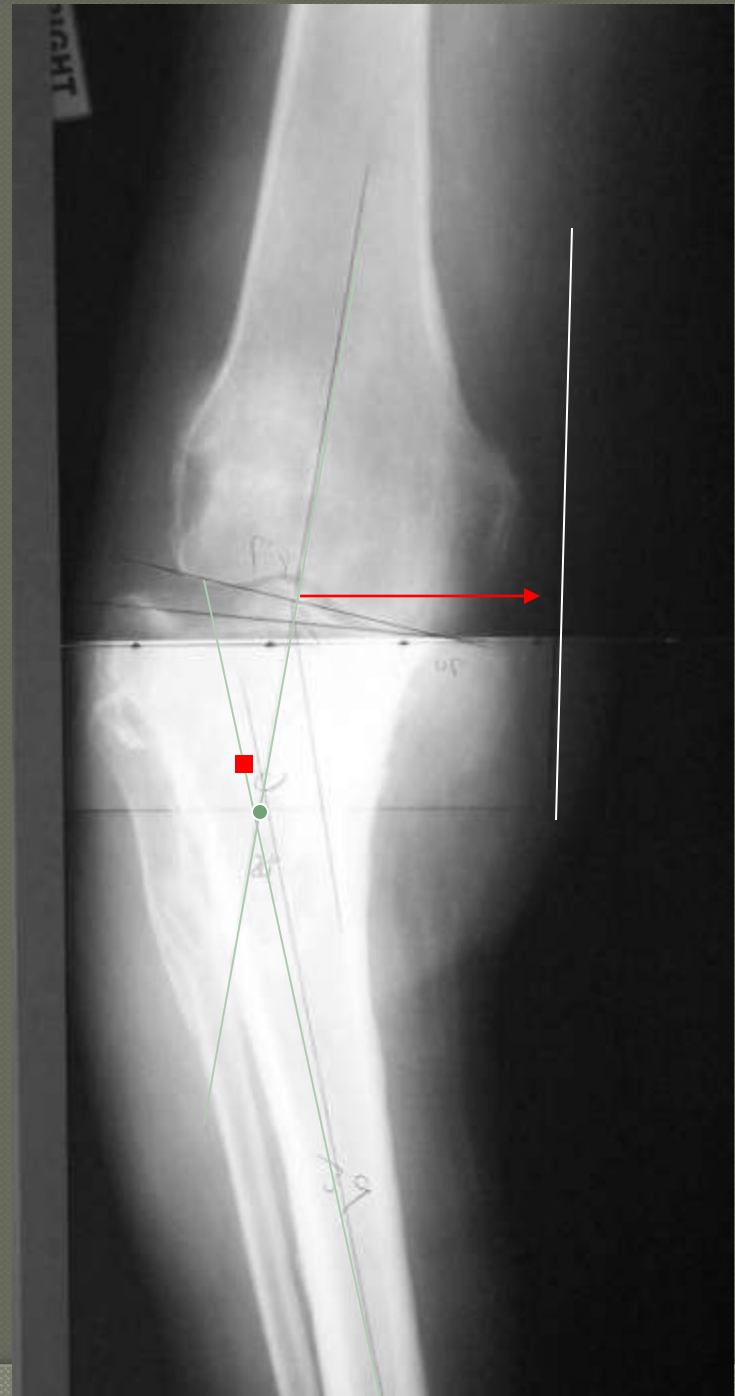


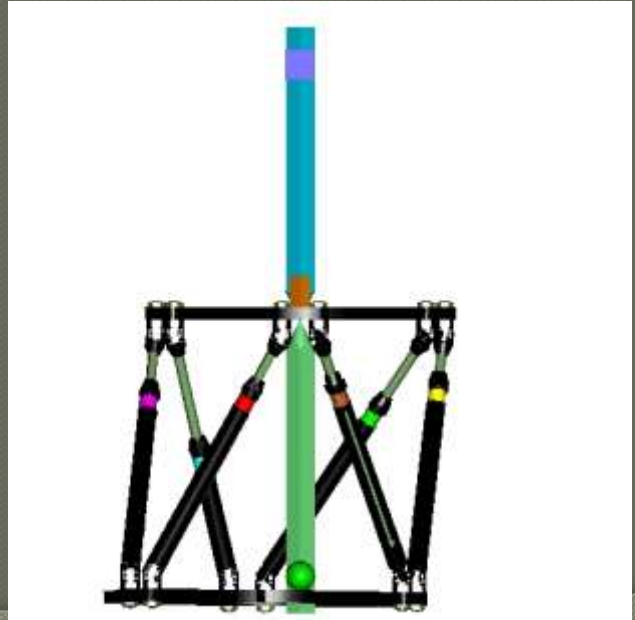
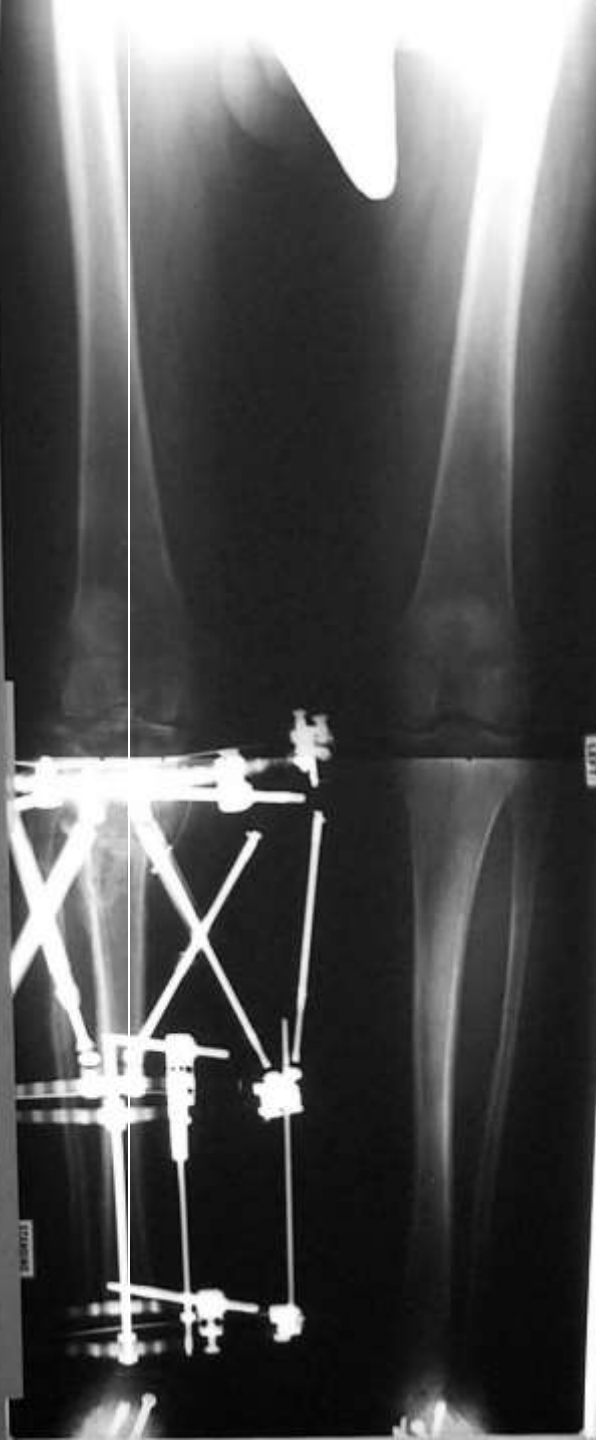4-08

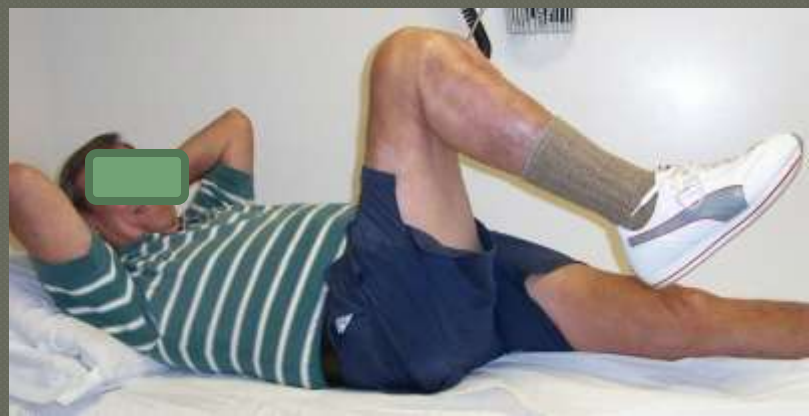
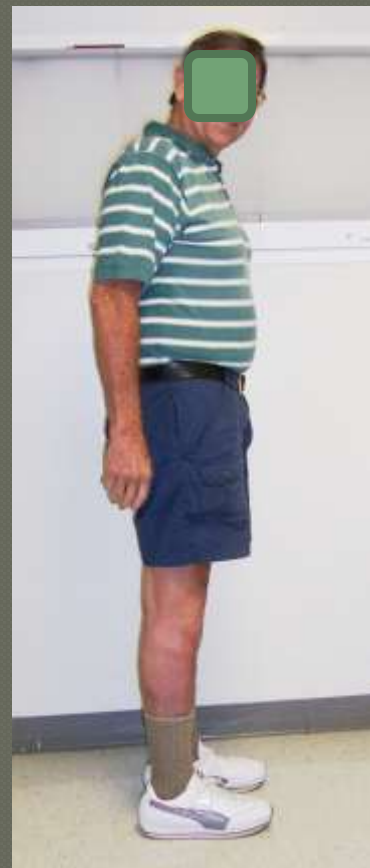
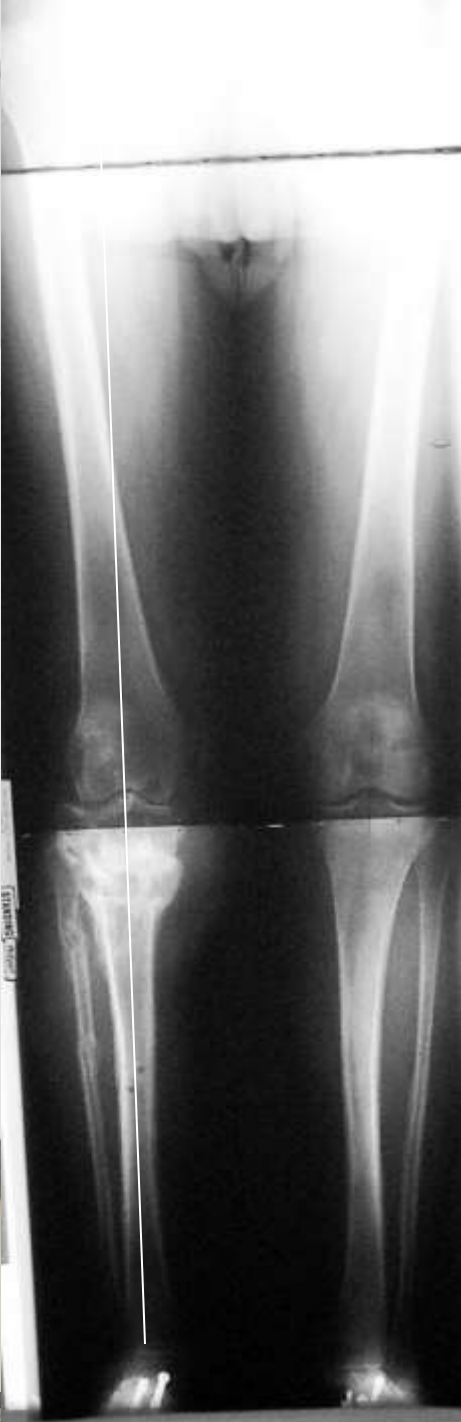

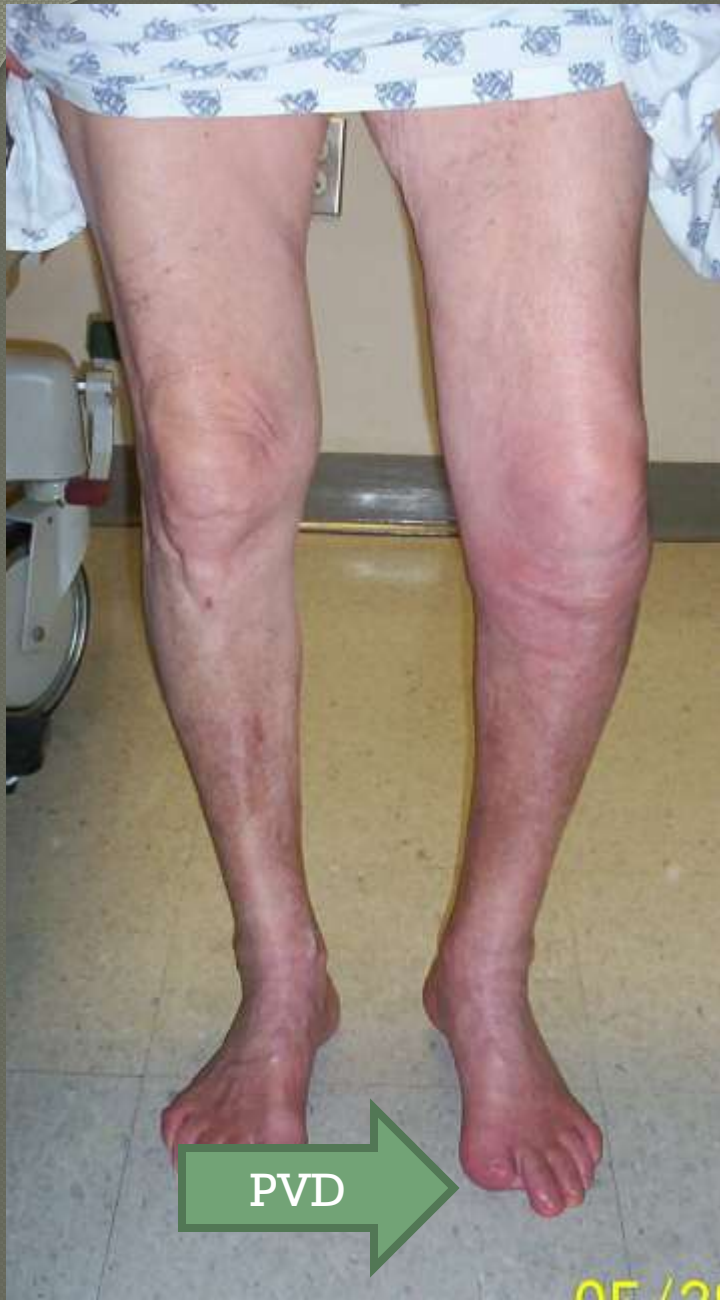Short = $w \sin(\text{angle})$



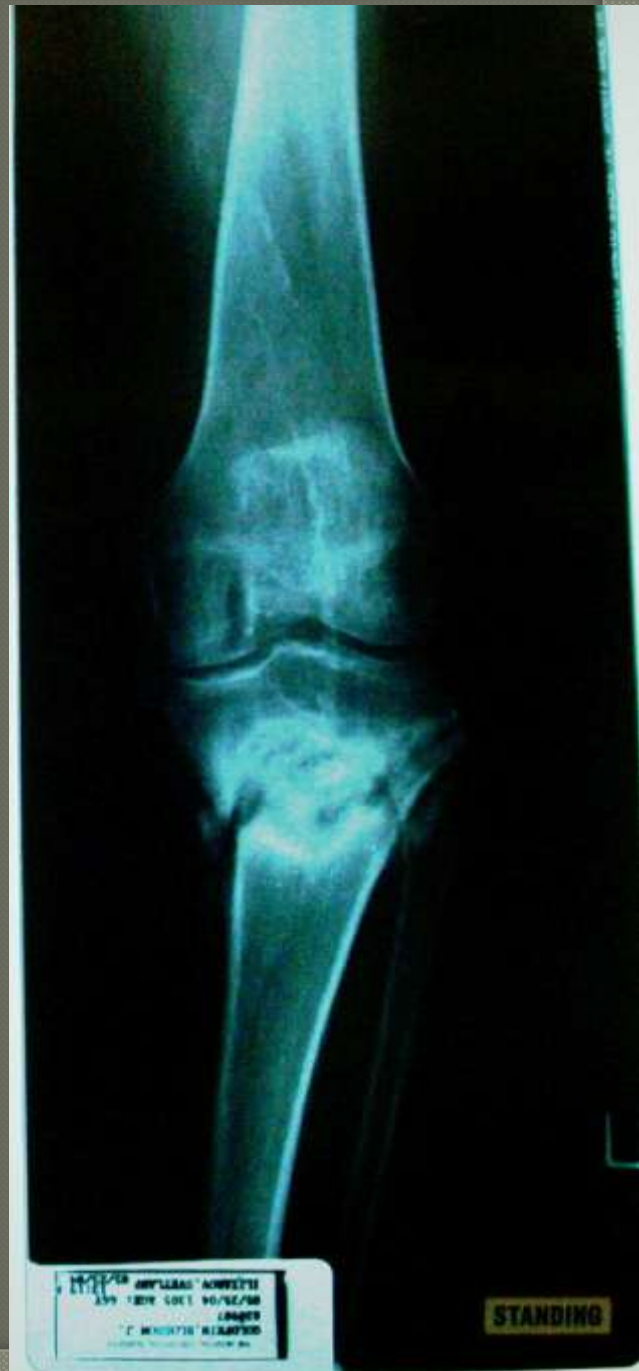
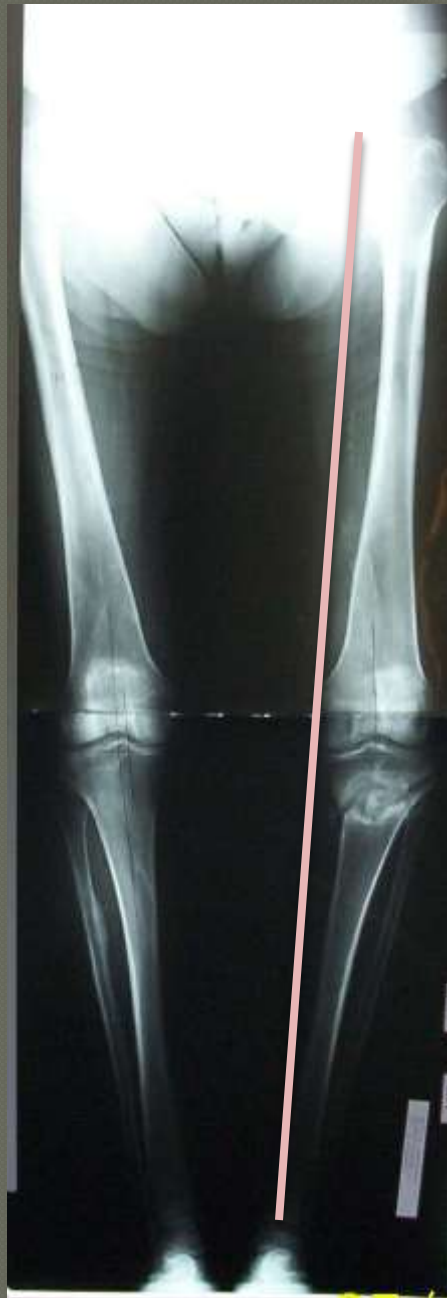


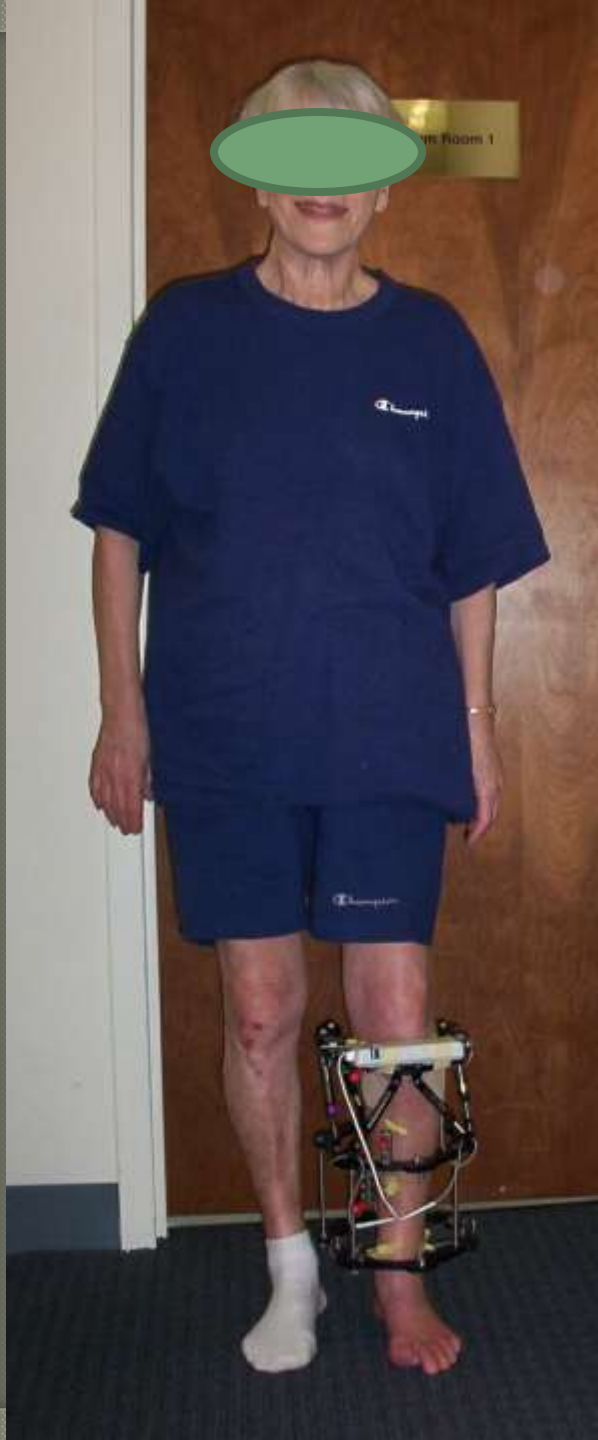
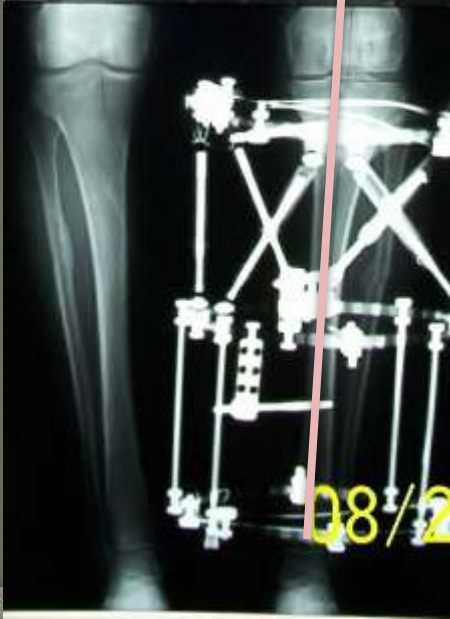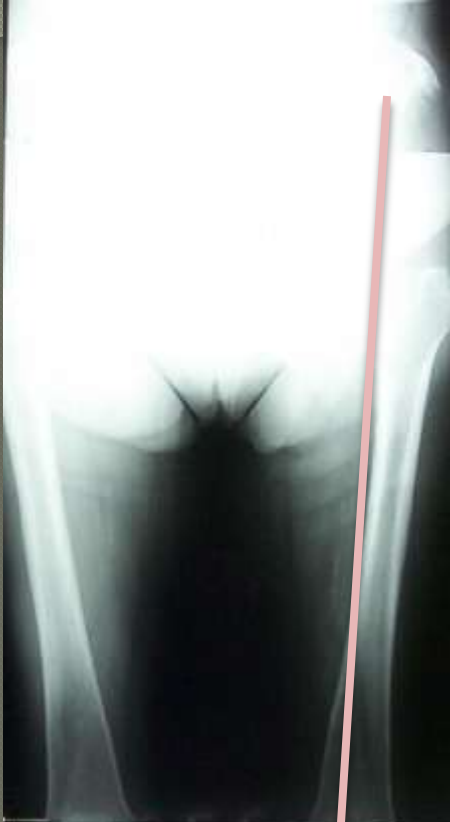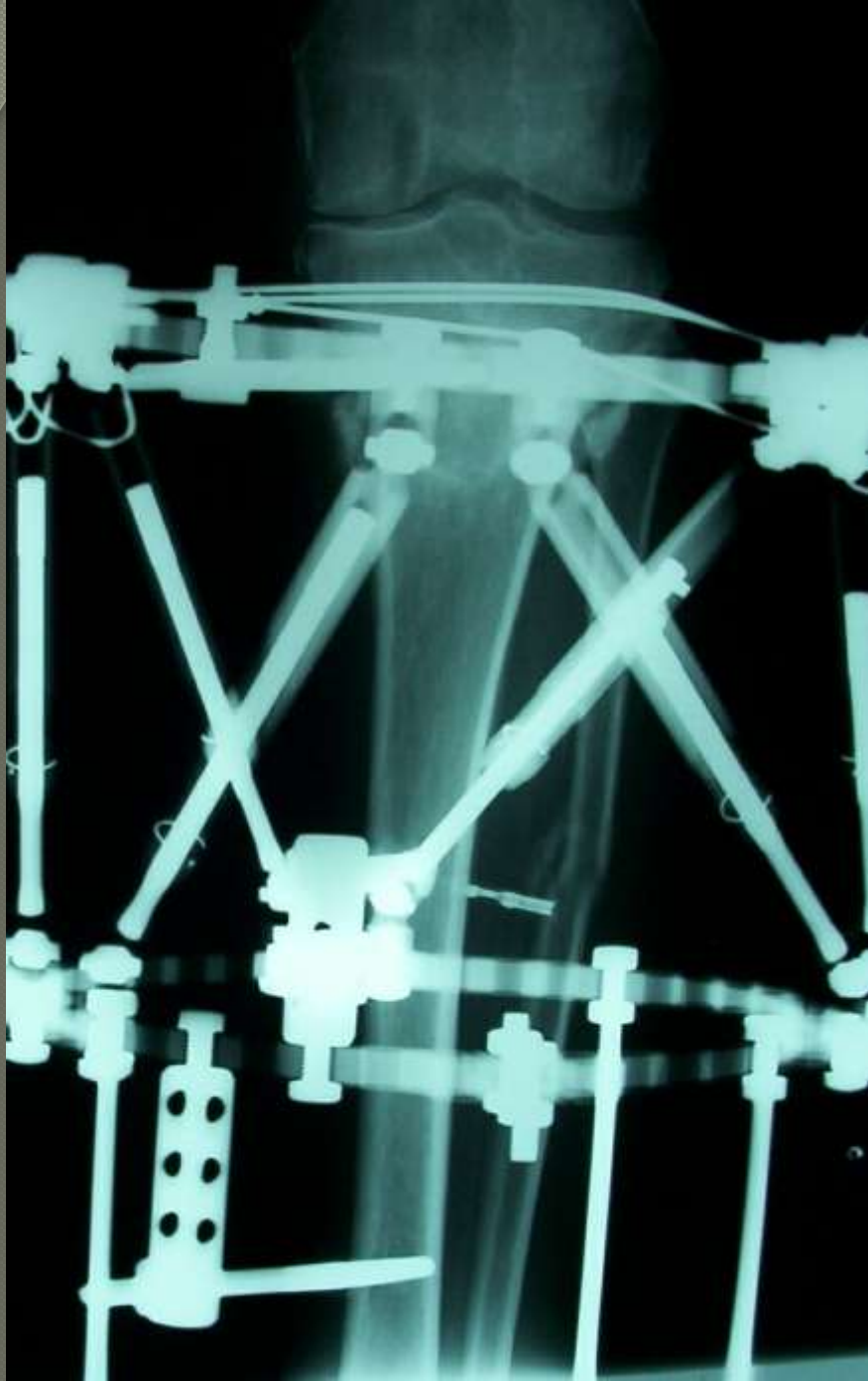




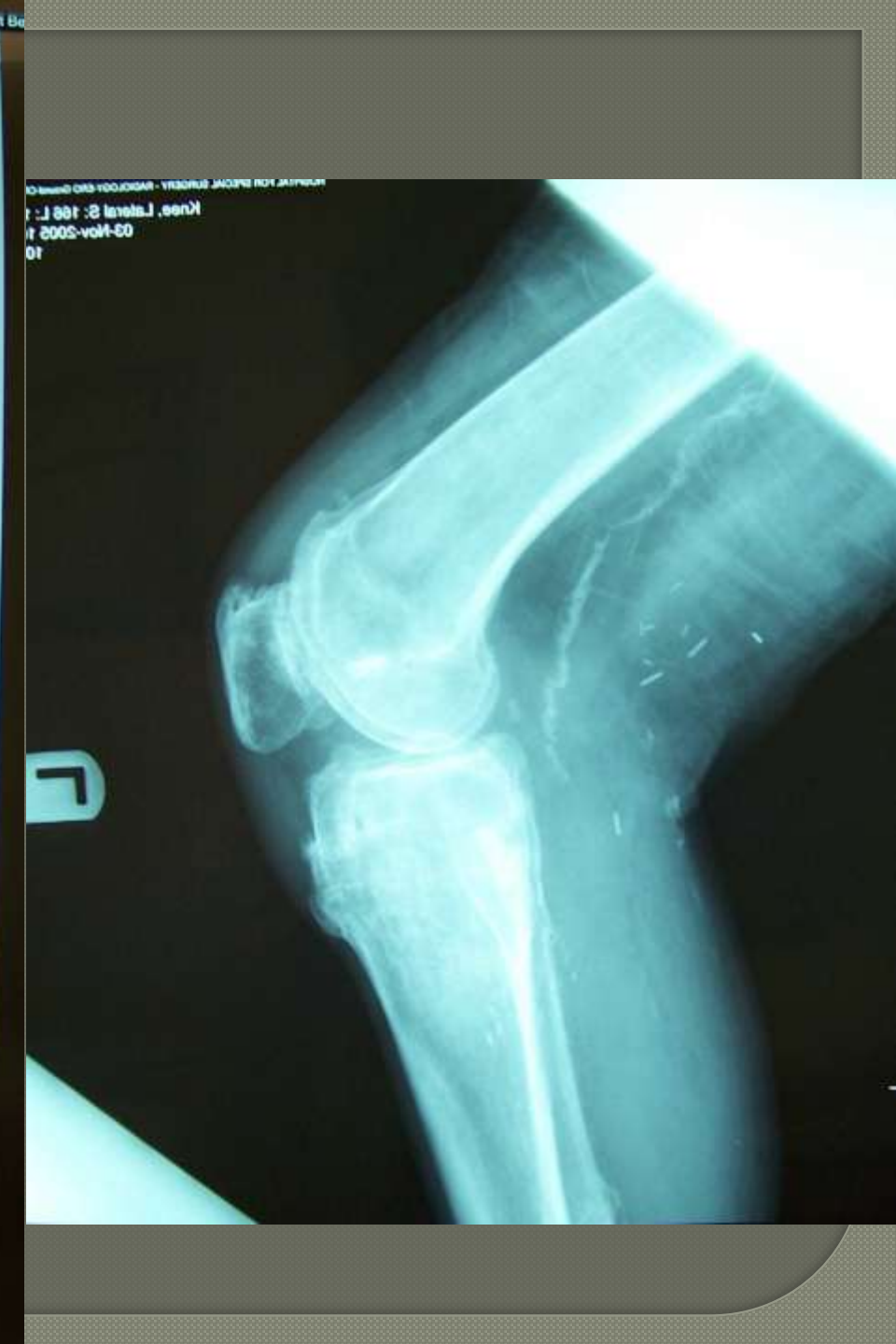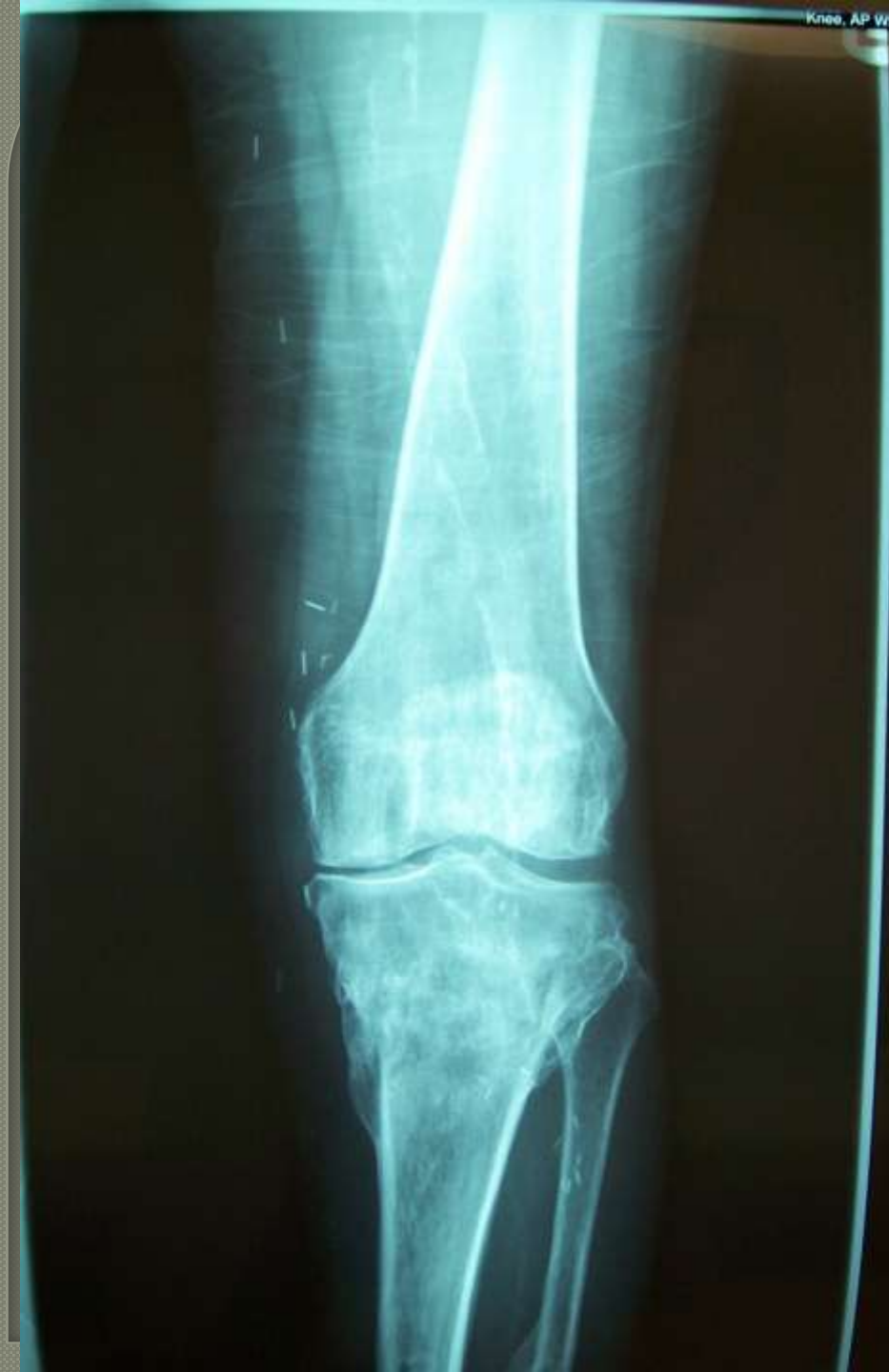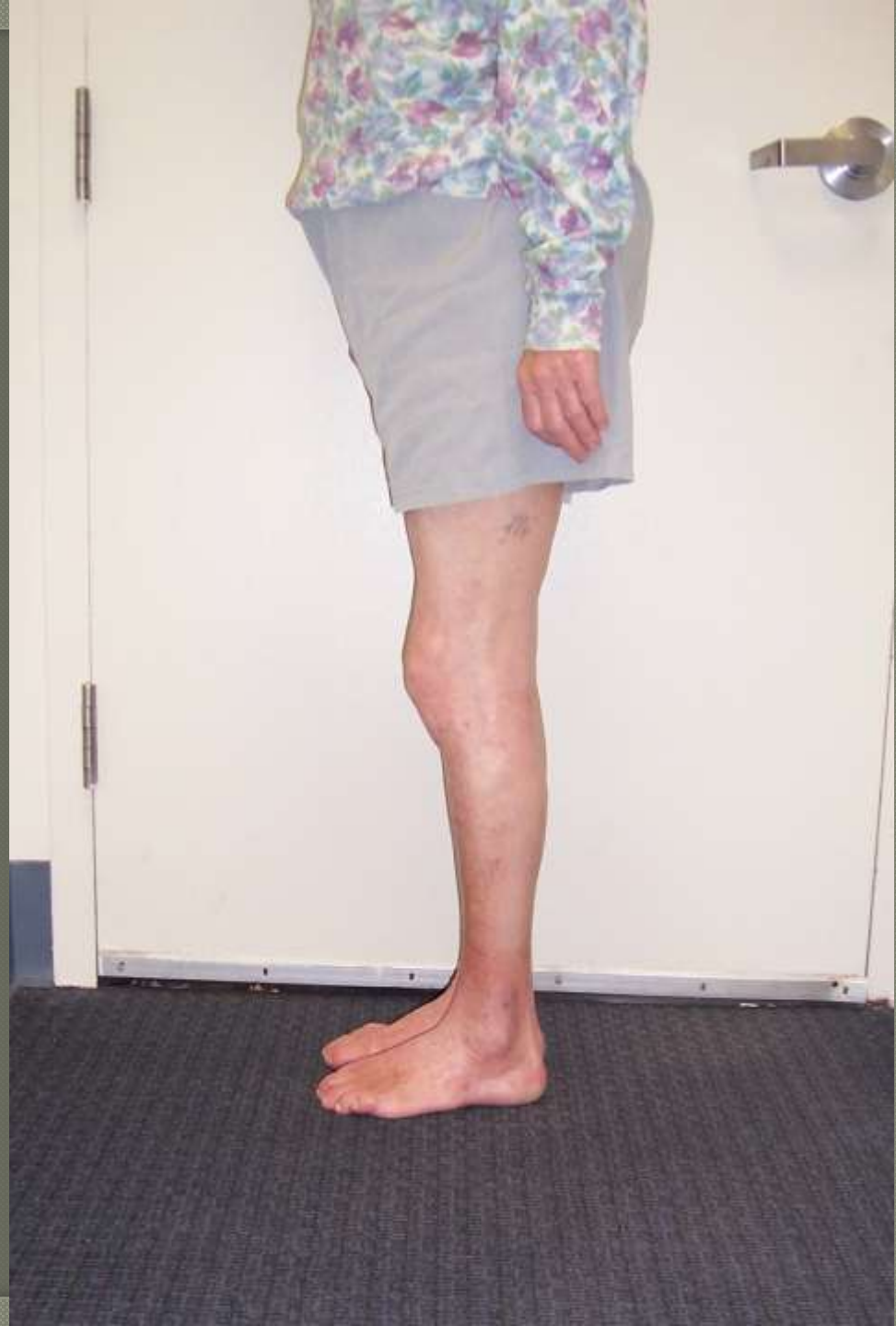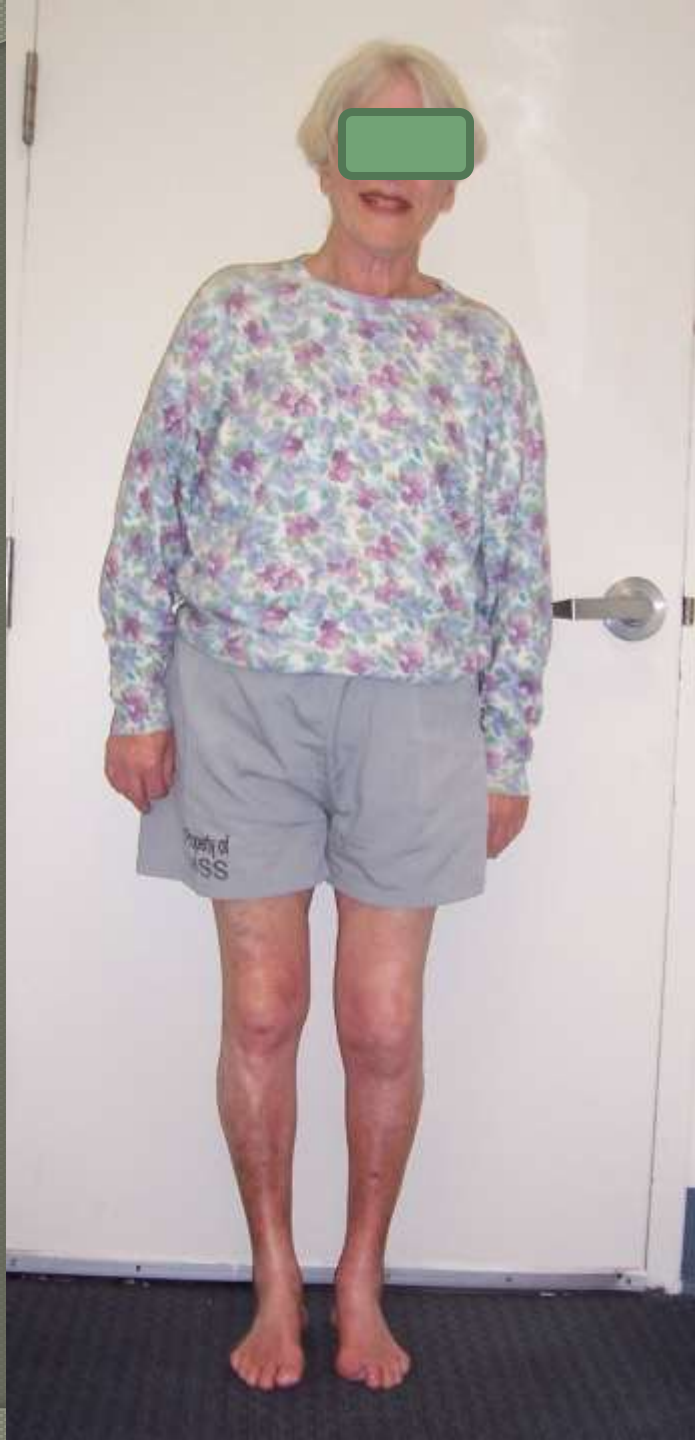PVD



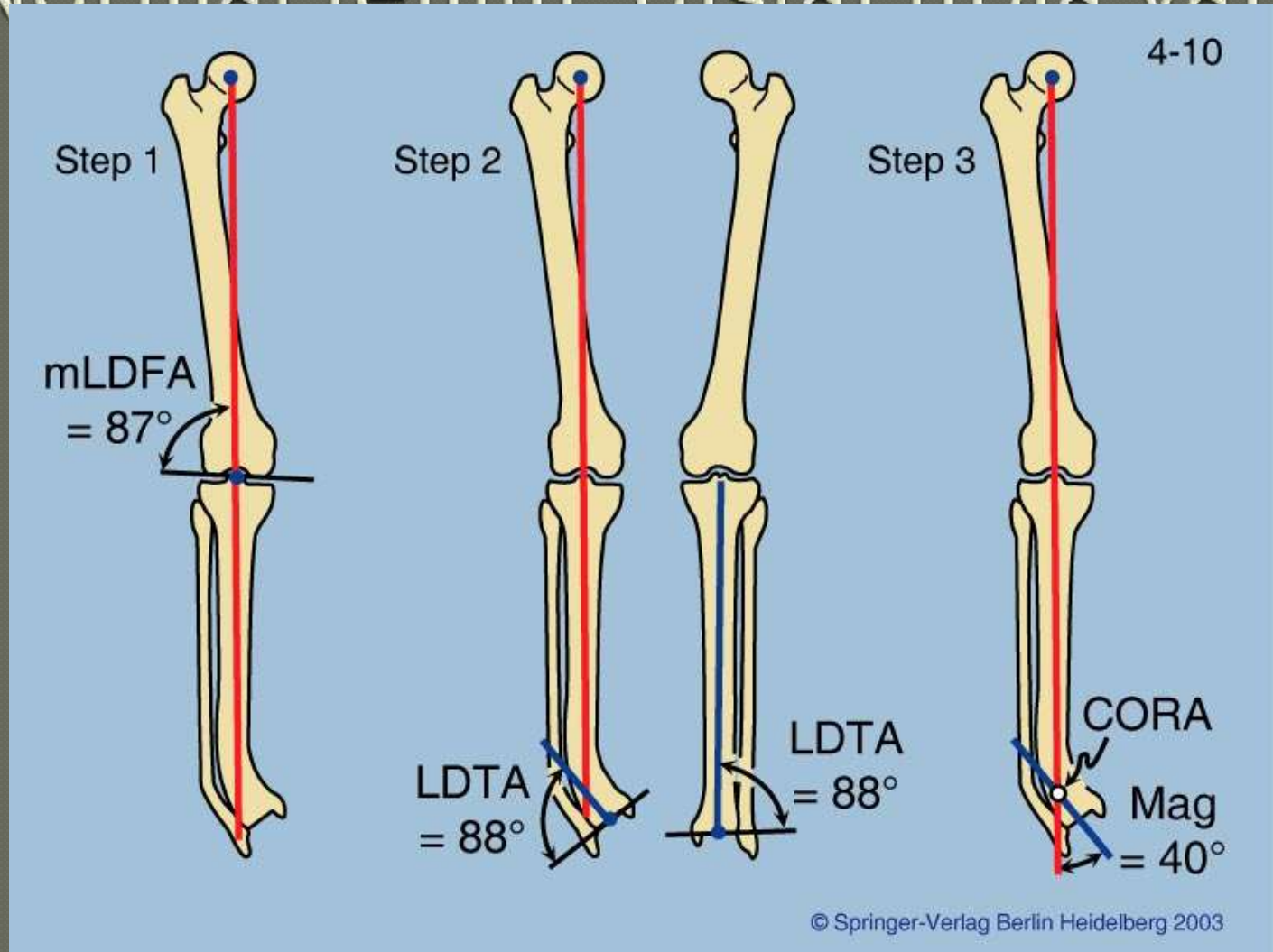






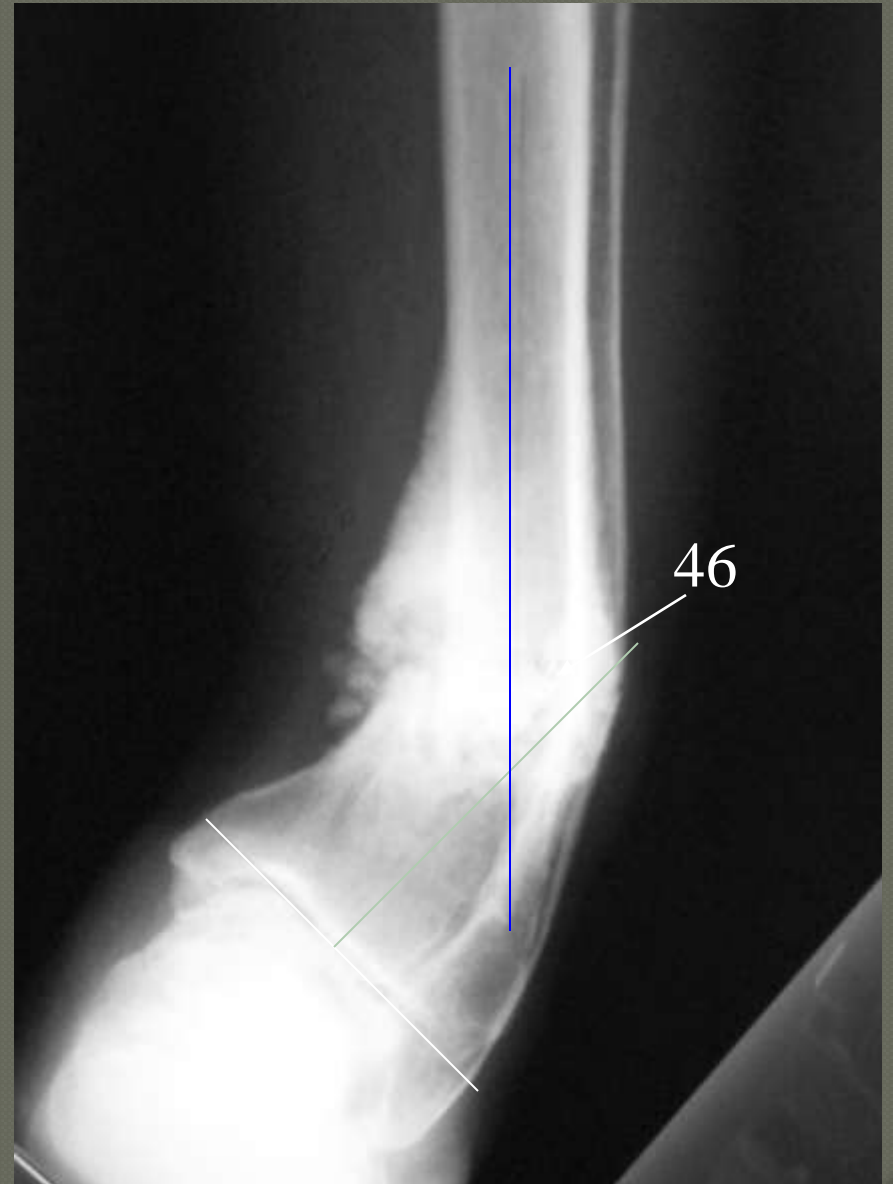
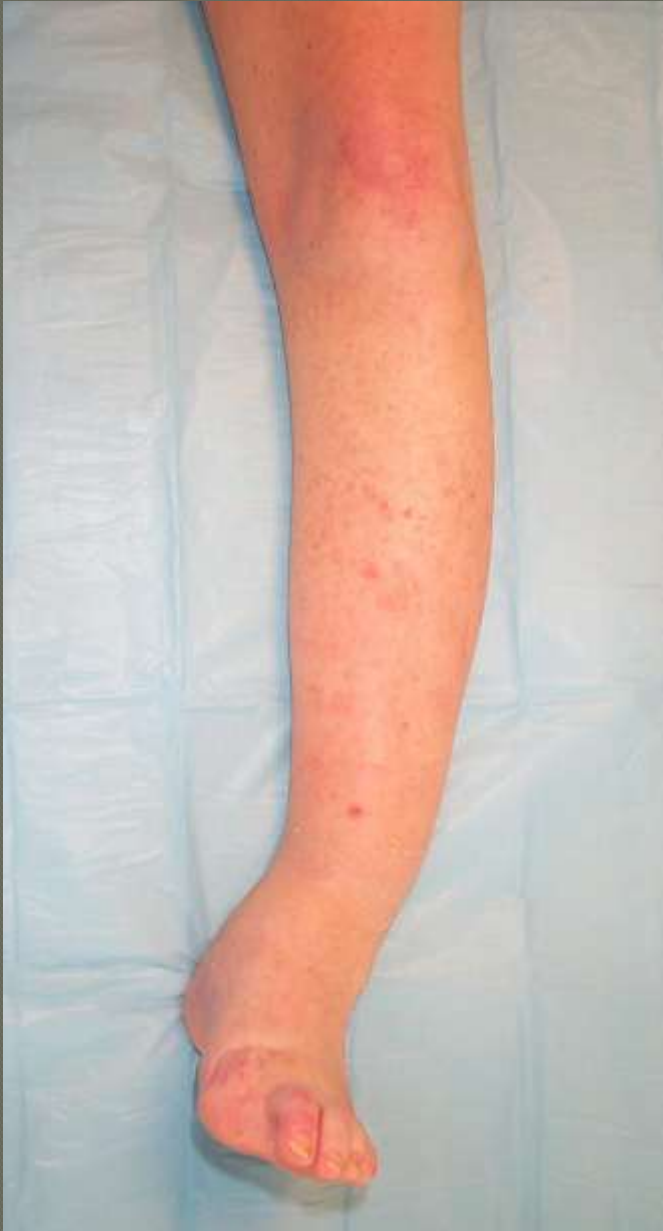
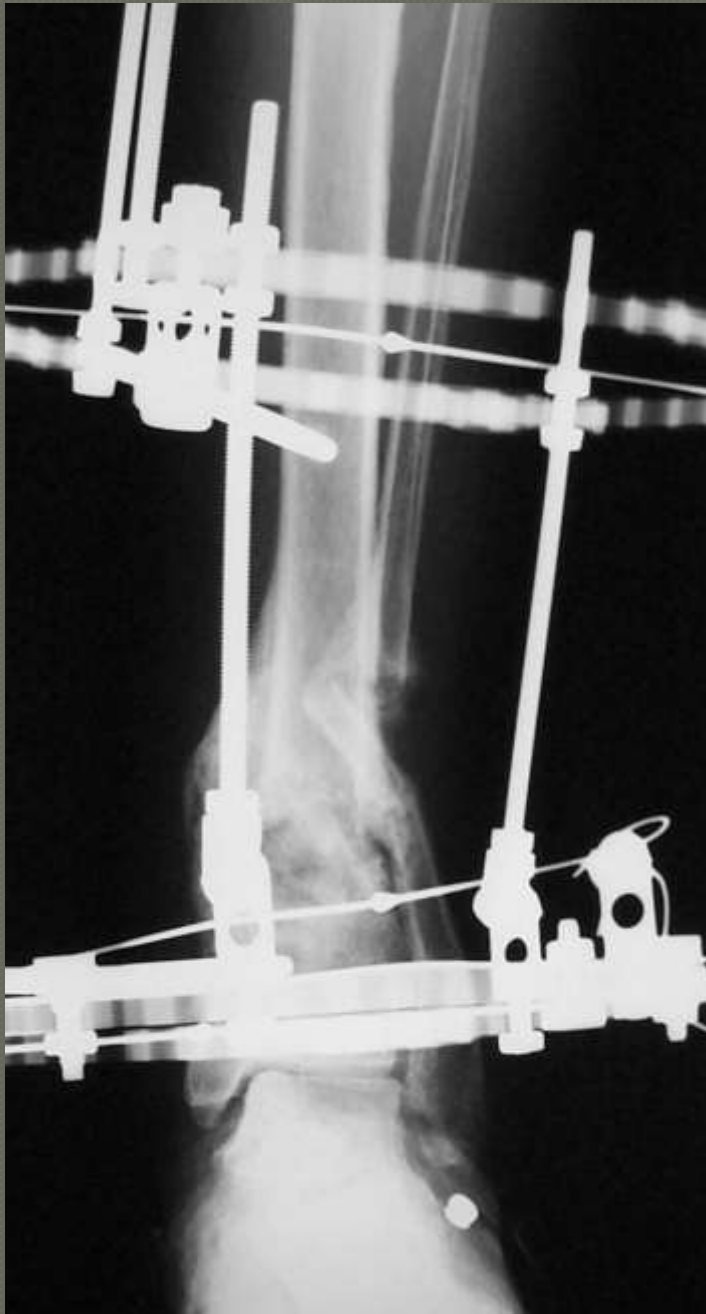Normal femur distal tibia varus



Use extension of femur mech axis for proximal tibia mech. axis

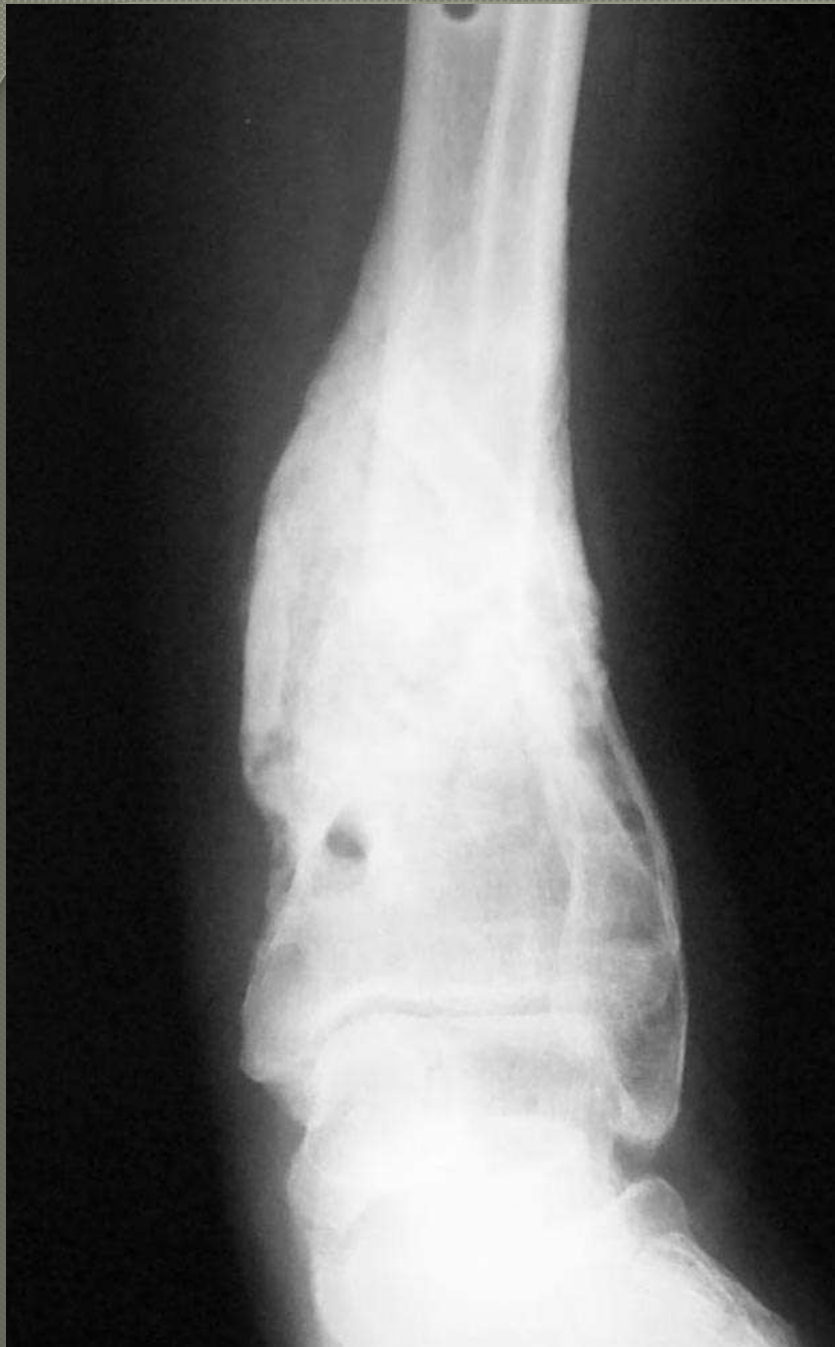PREOP





3 months

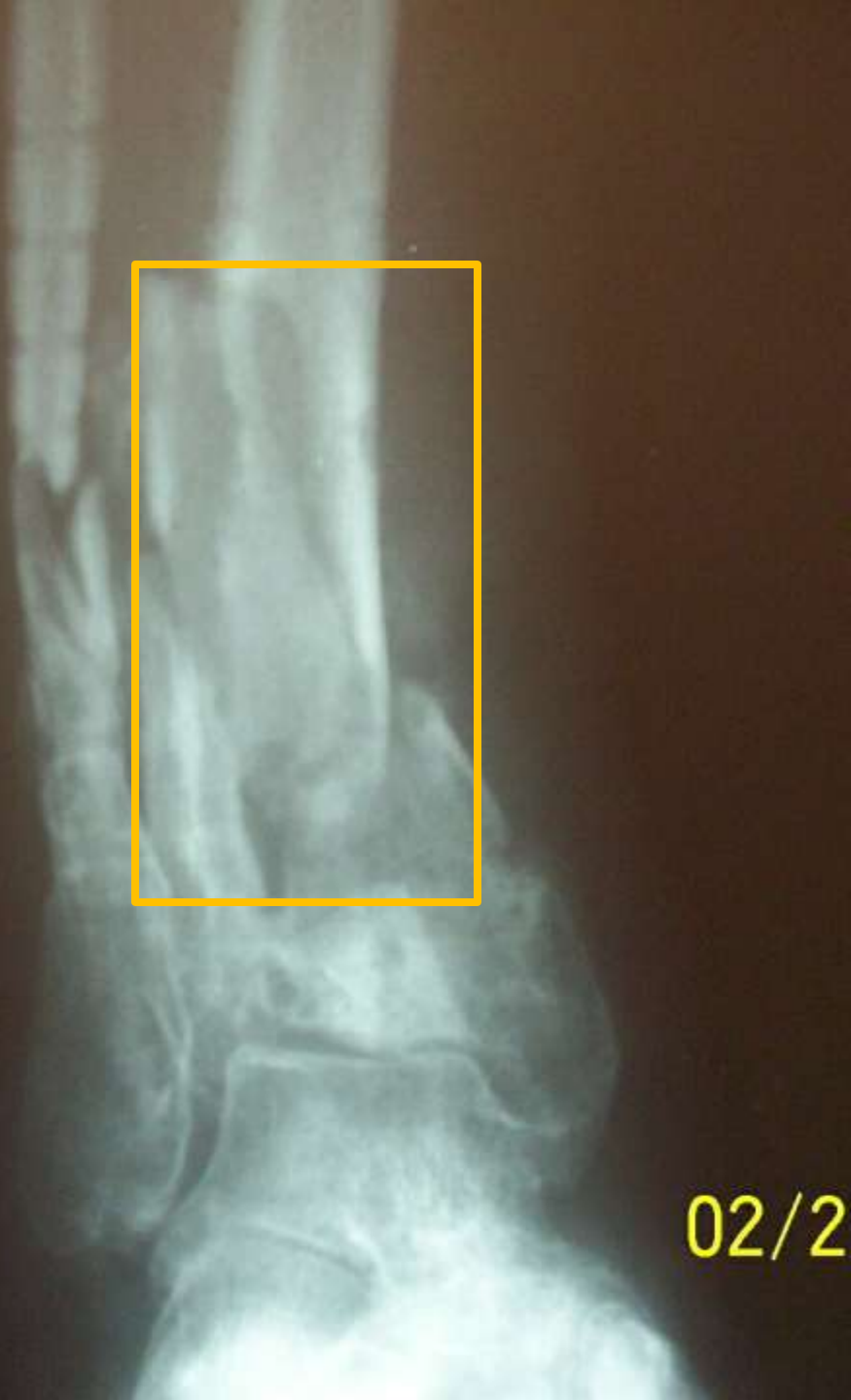
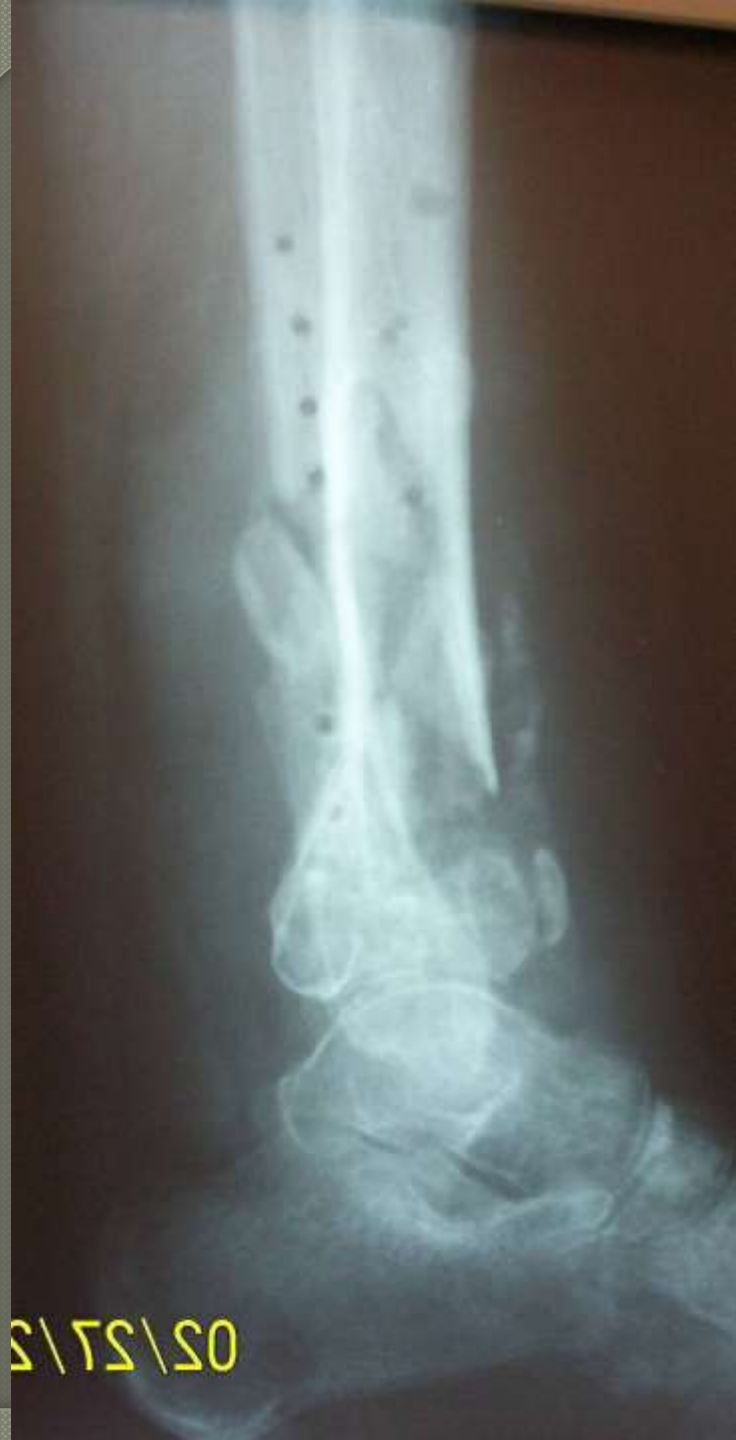
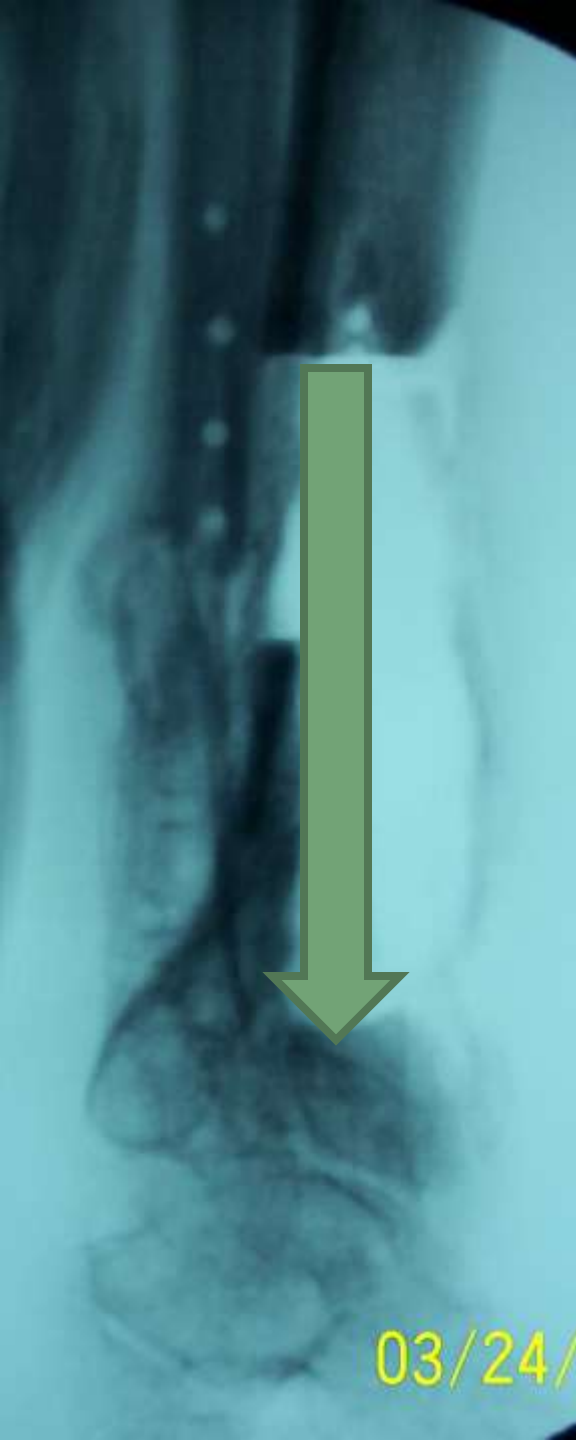


5 months



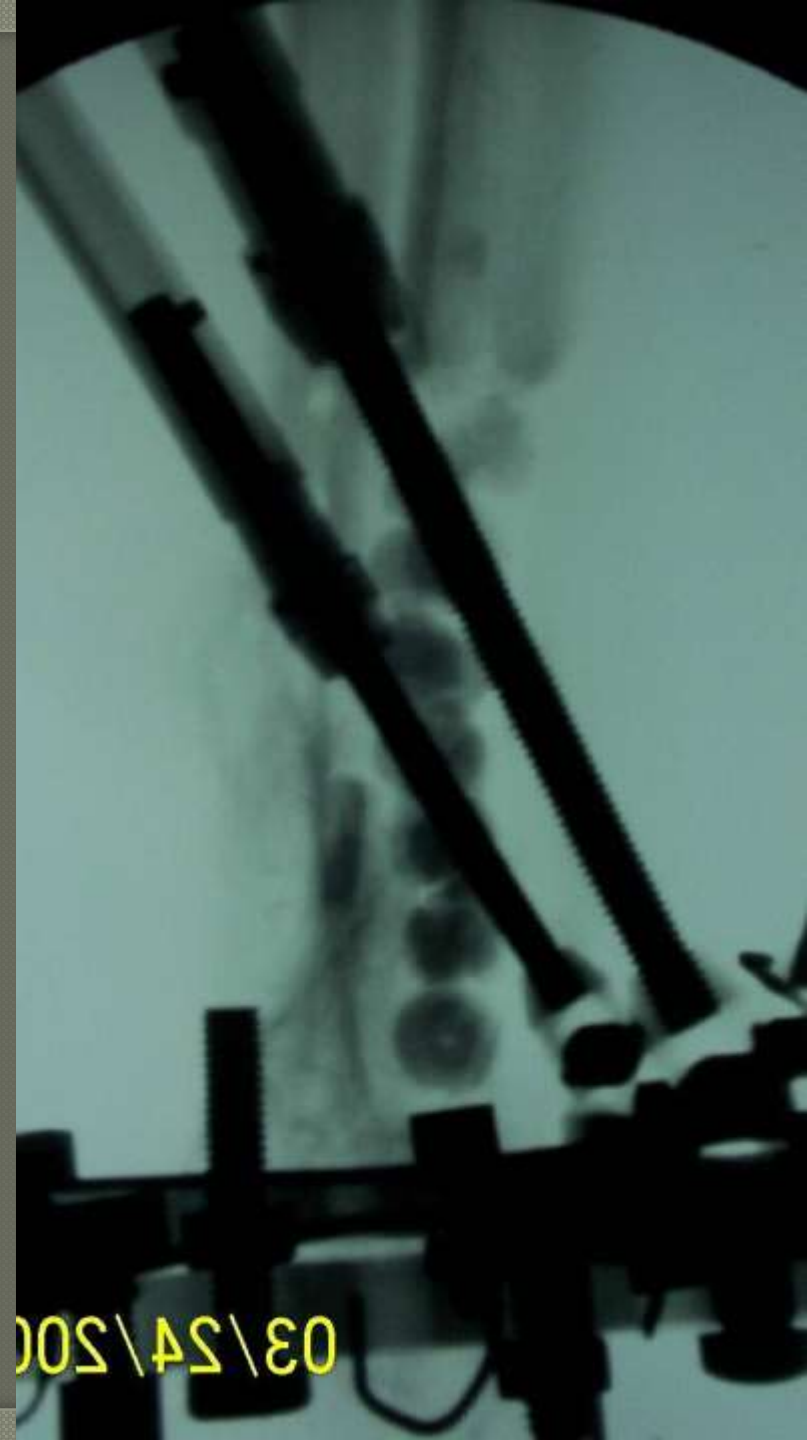




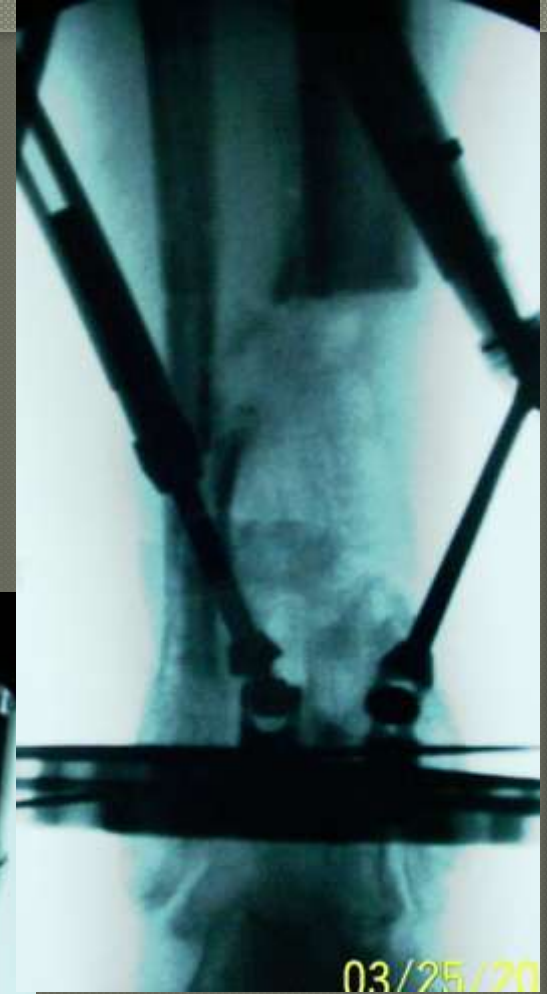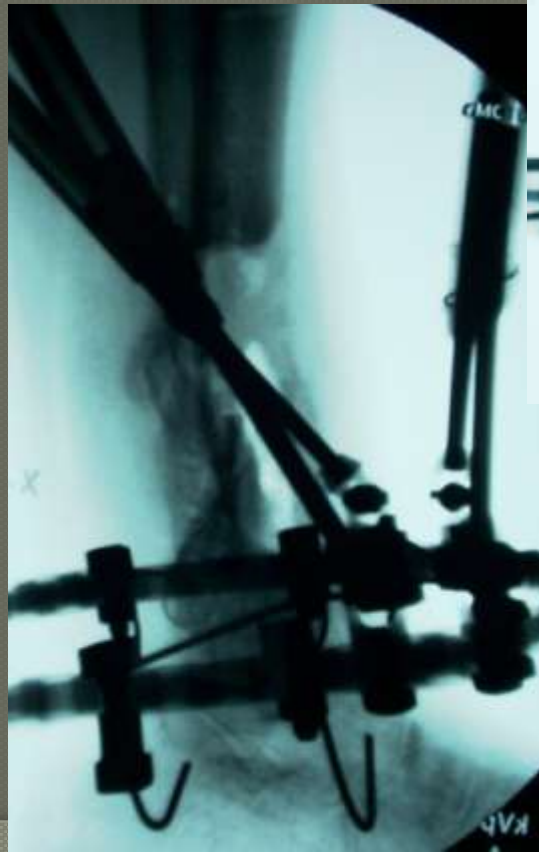

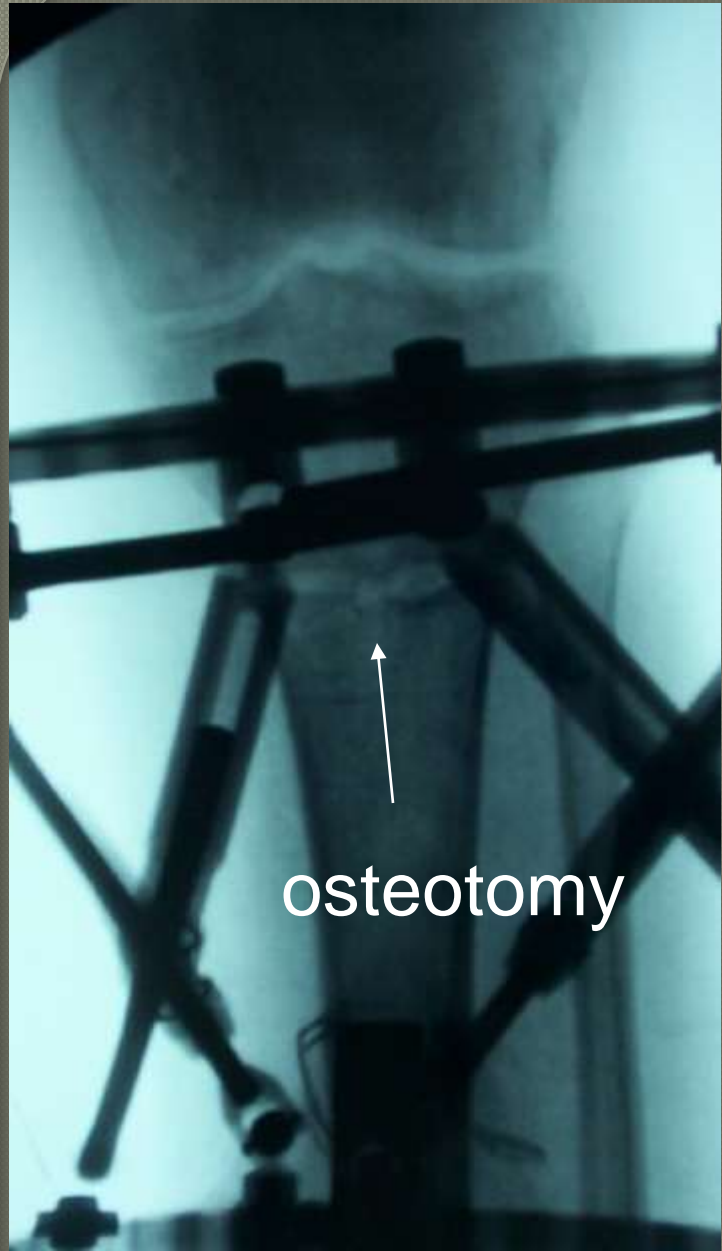

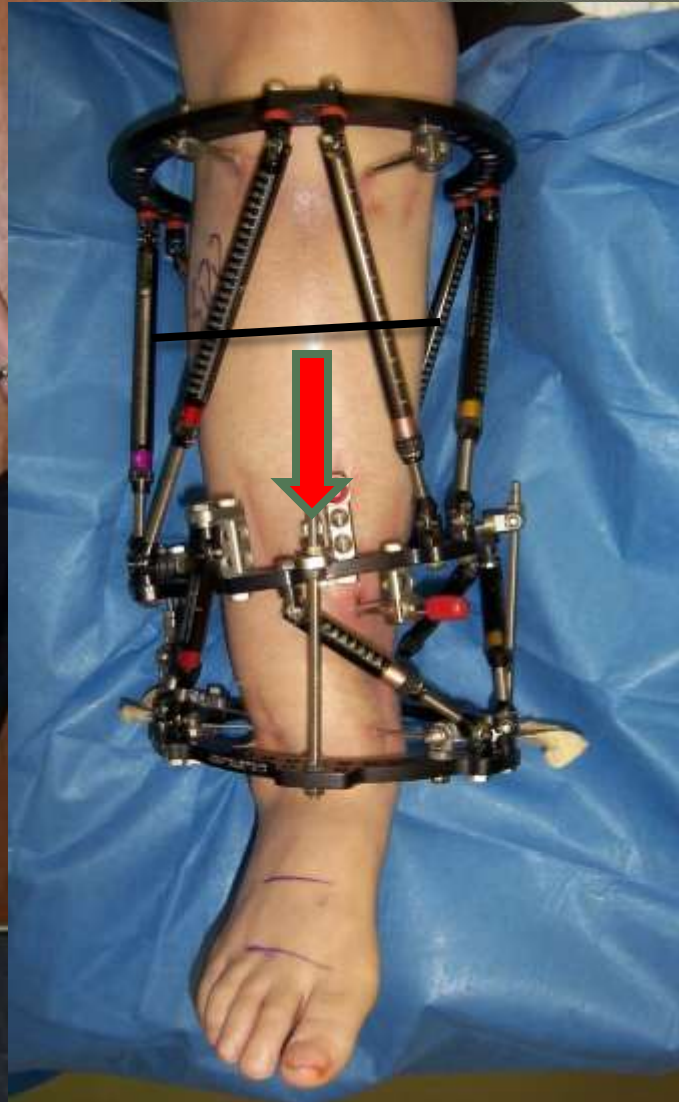
03/24/

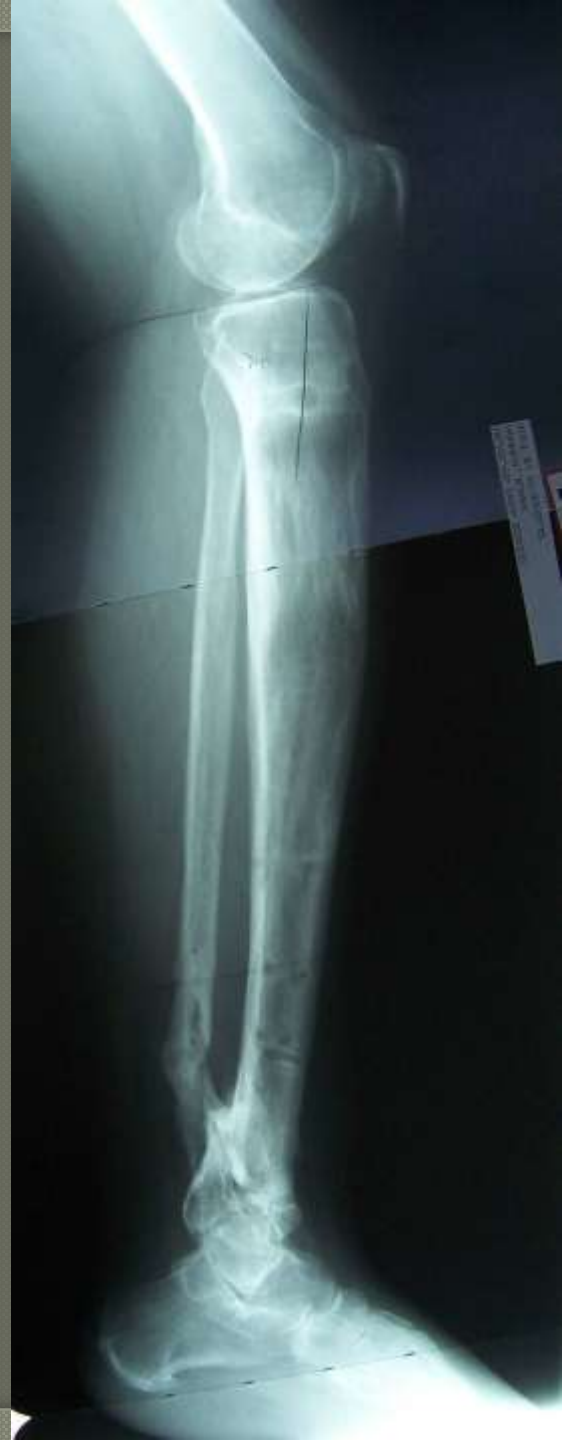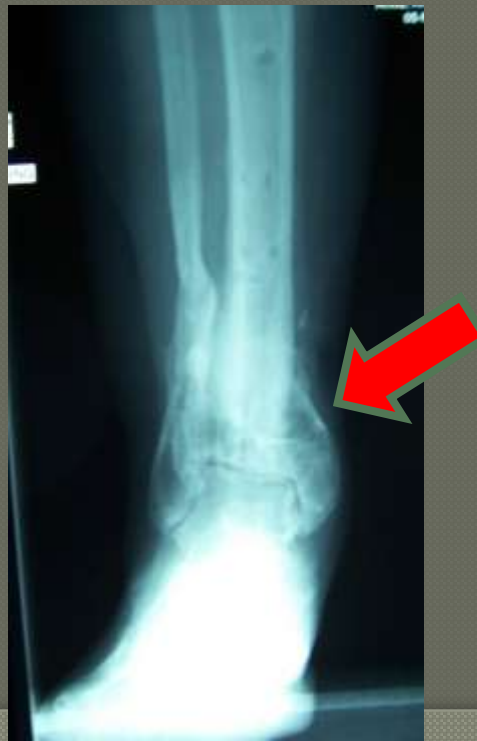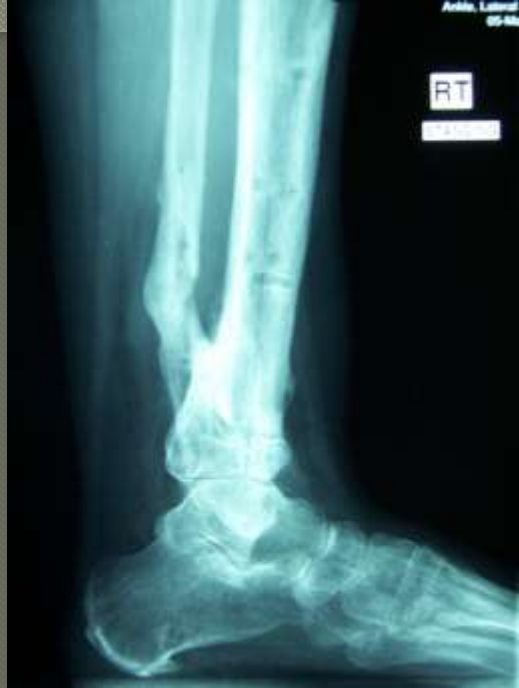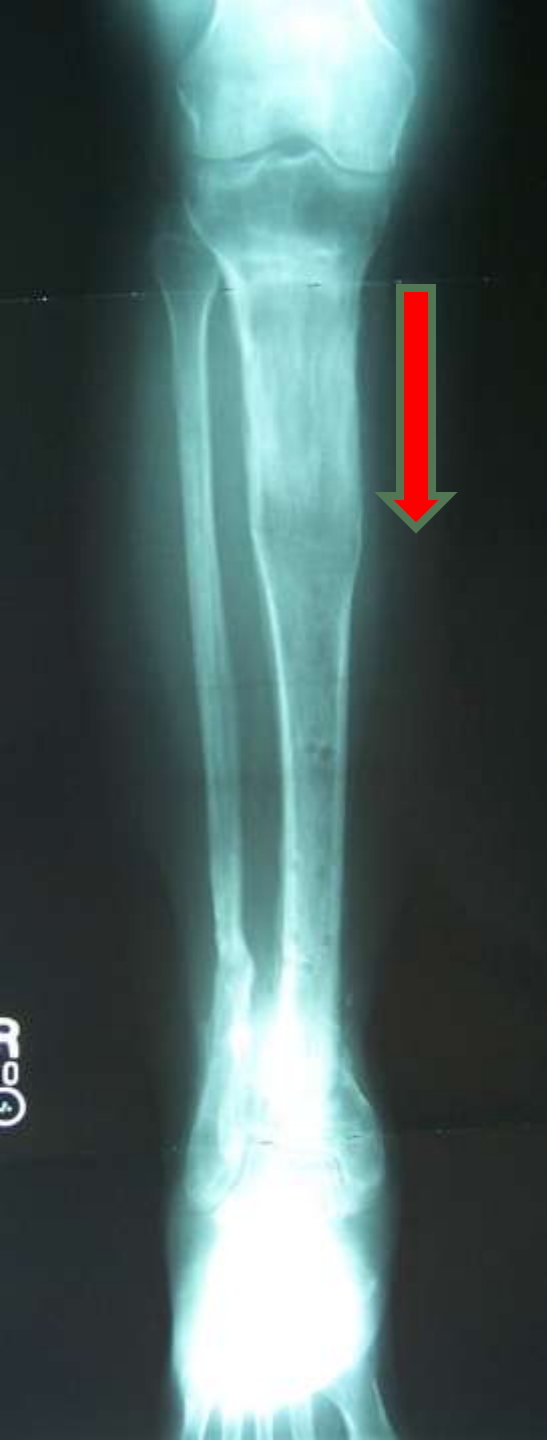After resection
And bead
placement

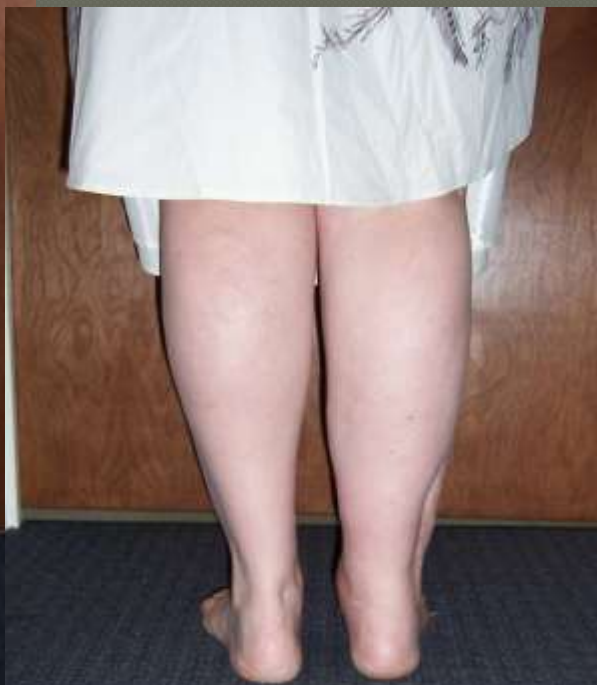
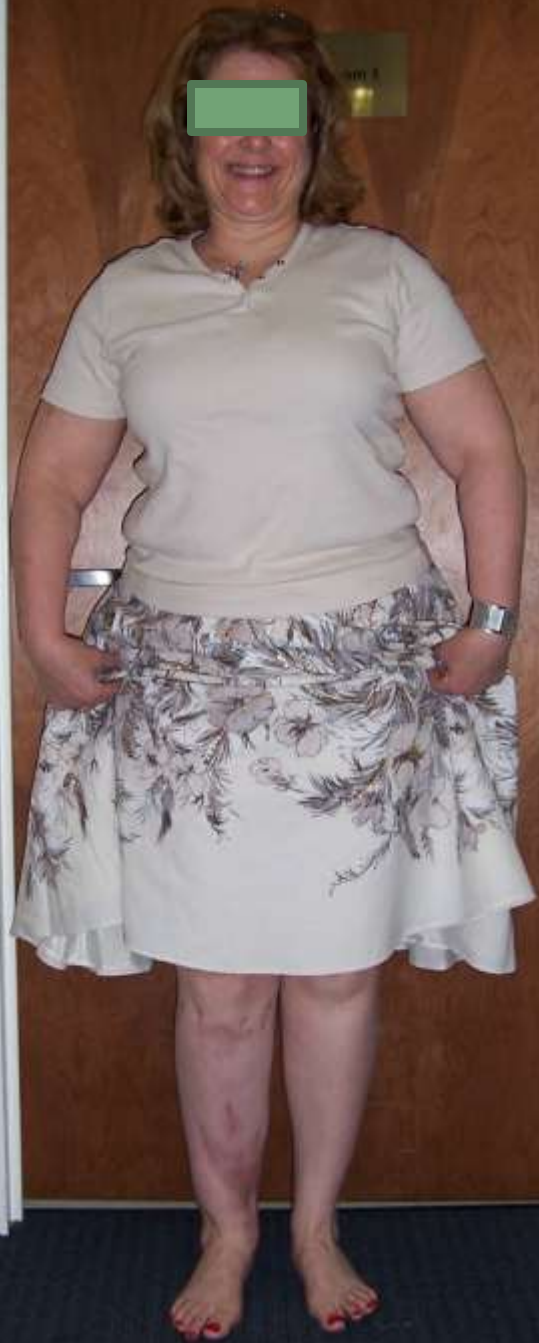
03\24\500









Temporary Intentional Leg Shortening and Deformation to Facilitate Wound Closure Using the Ilizarov/Taylor Spatial Frame

Shane J. Nho, MD, David L. Helfet, MD, and S. Robert Rozbruch, MD

Summary: Infected tibial nonunions with bone loss pose an extremely challenging problem for the orthopaedic surgeon. A comprehensive approach that addresses the infection, bone quality, and overlying soft-tissue integrity must be considered for a successful outcome. Acute shortening with an Ilizarov frame has been shown to be helpful in the treatment of open tibia fractures with simultaneous bone and soft-tissue loss. Cases in which the soft-tissue defect considerably exceeds bone loss may require an Ilizarov frame along with a concomitant soft-tissue procedure; however, there are a number of potential difficulties with vascularized pedicle flaps and free tissue flaps, including anastomotic complications, partial flap necrosis, and flap failure. The technique described in this report involves acute shortening and temporary bony deformation with the Ilizarov apparatus to facilitate wound closure and does not require a concomitant soft-tissue reconstructive procedure. Once the wound is healed, osseous deformity and length are gradually corrected by distraction osteogenesis with the Ilizarov/Taylor Spatial frame.

Key Words: Ilizarov, Taylor Spatial frame, nonunion, acute shortening, deformity correction, wound closure

J Orthop Trauma 2006;20:419-424

The Ilizarov method has been described alone or in combination with soft-tissue reconstruction for the management of open tibia fractures, limb shortening, deformity, joint contractures, and infections. Shortening with bifocal compression-distraction has been successfully used in the treatment of open tibia fractures with primary wound closure or delayed primary wound closure.¹⁻³ The technique is called bifocal because there are 2 segments with activity. One segment (the defect) is

undergoing compression/shortening, and 1 segment (the bony regenerate) is undergoing distraction/lengthening to maintain the length of the limb. Bone defects < 3 cm can usually be acutely shortened, and defects of > 3 cm should usually be gradually shortened.¹ Acute shortening is easier and safer to accomplish in the acute rather than chronic situation. Acute shortening of > 3 cm may be safe if the vascular physical examination does not change. Bifocal compression-distraction not only leads to solid osseous union but also corrects limb length discrepancy, deformity, joint contractures, and infection throughout the treatment period. The Ilizarov method does not eliminate or "correct" the infection solely because it is applied to the bone. Removal of the dead bone, sequestrum, debridement, irrigation, local, and systemic antibiotics, etc., all contribute to the elimination of the infection from the bone. It does supply stability as an adjunct to the whole process. Additionally, the absence of internal fixation may be safer in the setting of active or history of infection.

In the present article, the authors present the technique of acute shortening and intentional temporary bony deformation to facilitate wound closure, thereby avoiding a soft-tissue flap, along with an illustrative case example. With the leg stabilized in the Ilizarov/Taylor Spatial frame (TSF; Smith & Nephew, Inc., Memphis, TN), the wound was allowed to completely heal in the deformed position. The deformed leg was gradually corrected until anatomic reduction of the bony fragments was achieved, and through a second tibial osteotomy, the leg was lengthened to correct the leg length discrepancy (LLD). The TSF, which is particularly useful for this technique, is an evolution of the Ilizarov frame that allows simultaneous correction of length, angulation, translation, and rotation about a virtual axis.⁴⁻⁶ With the TSF, a crooked frame mounted on a deformed bone can be used to gradually correct the leg deformity.⁷

SURGICAL TECHNIQUE

Surgery is usually performed under regional anesthesia. Preoperative antibiotics are withheld until after intraoperative cultures are obtained. Bony edges are debrided with the goal of removing all dead bone. The bony edges are cut flat and perpendicular to the axis of the tibia with a power saw cooled with saline. An equalized segment of the fibula must be removed at about the

Accepted for publication October 31, 2005.

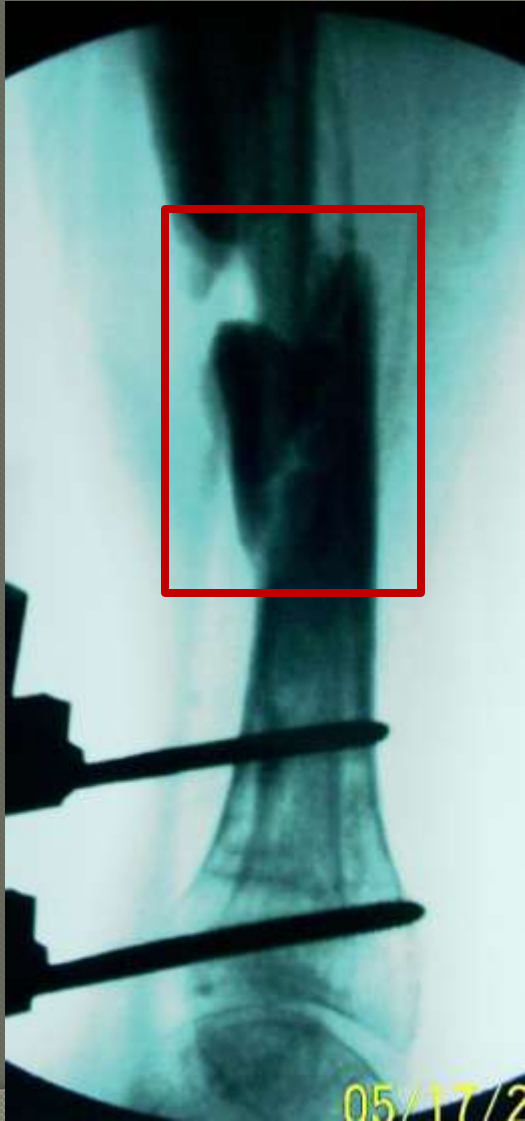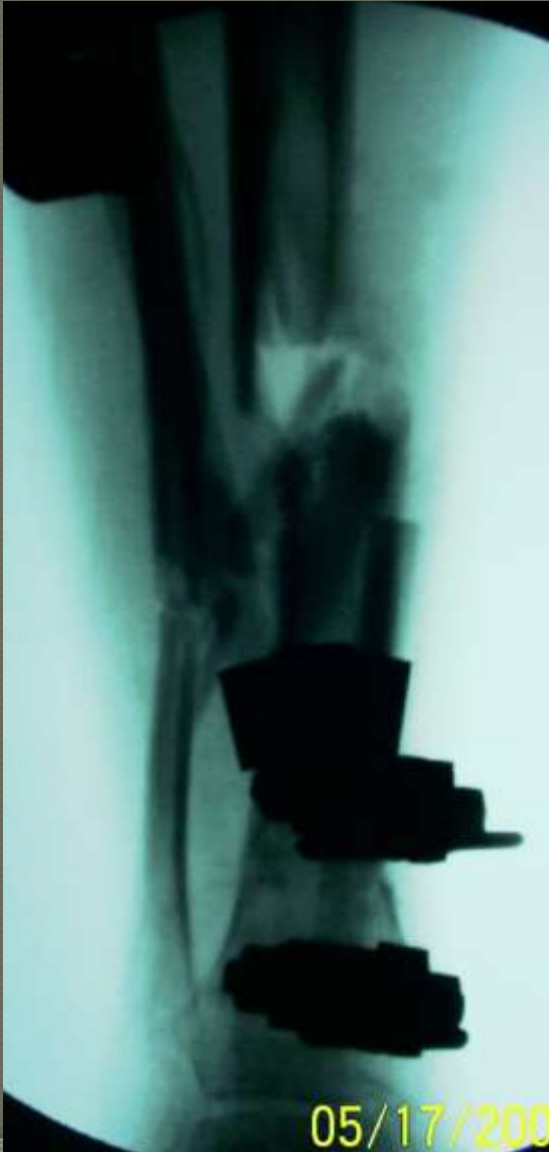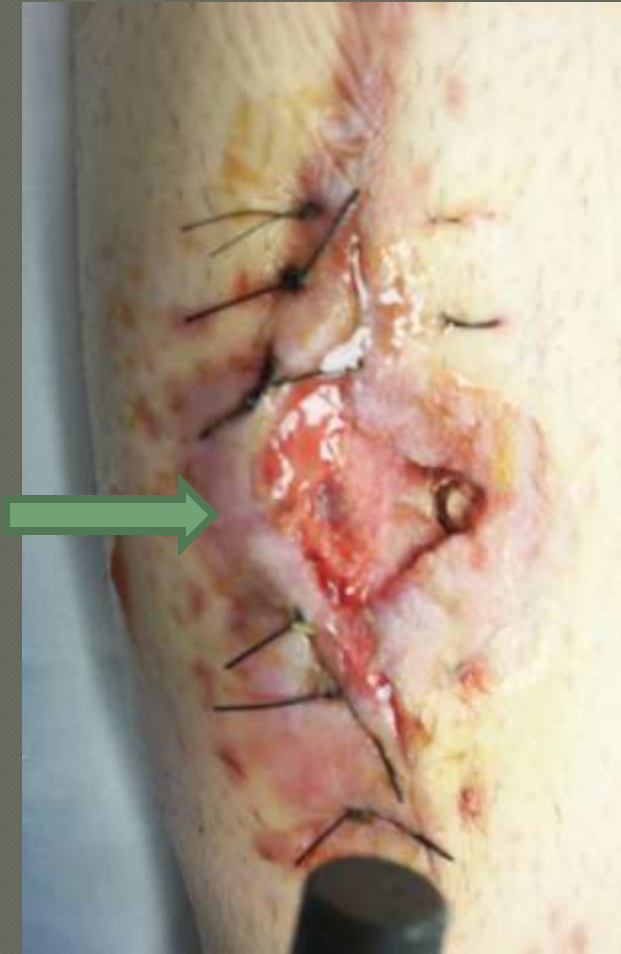From the Limb Lengthening and Deformity Service, Orthopaedic Trauma Service, Hospital for Special Surgery, Weill Medical College of Cornell University, New York, New York, 10021.

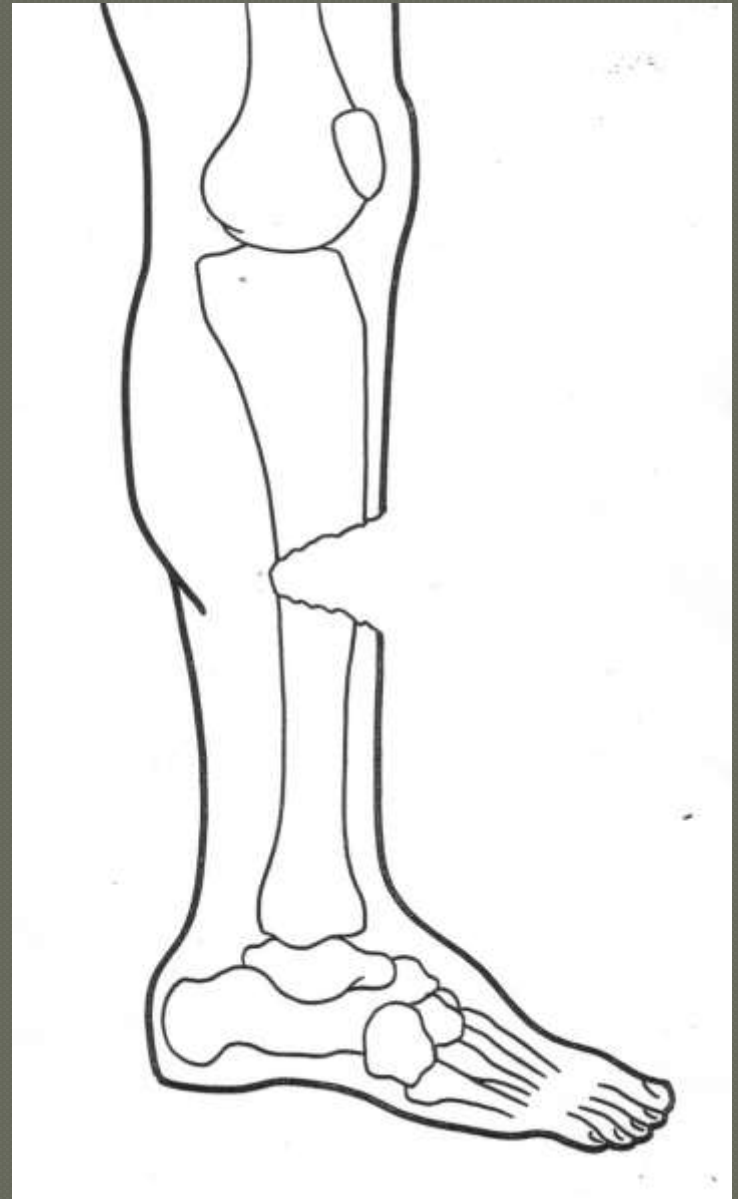
No authors received financial support for the research or preparation of the manuscript.

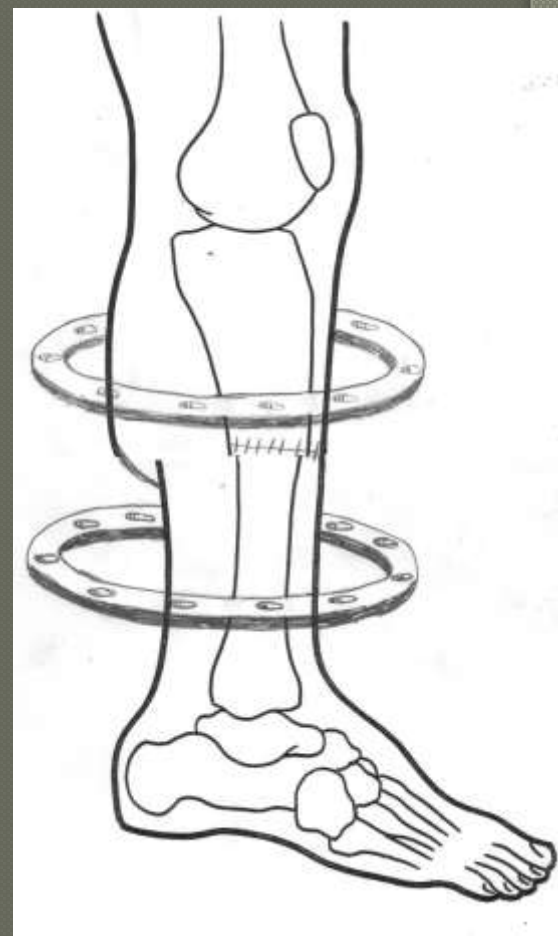
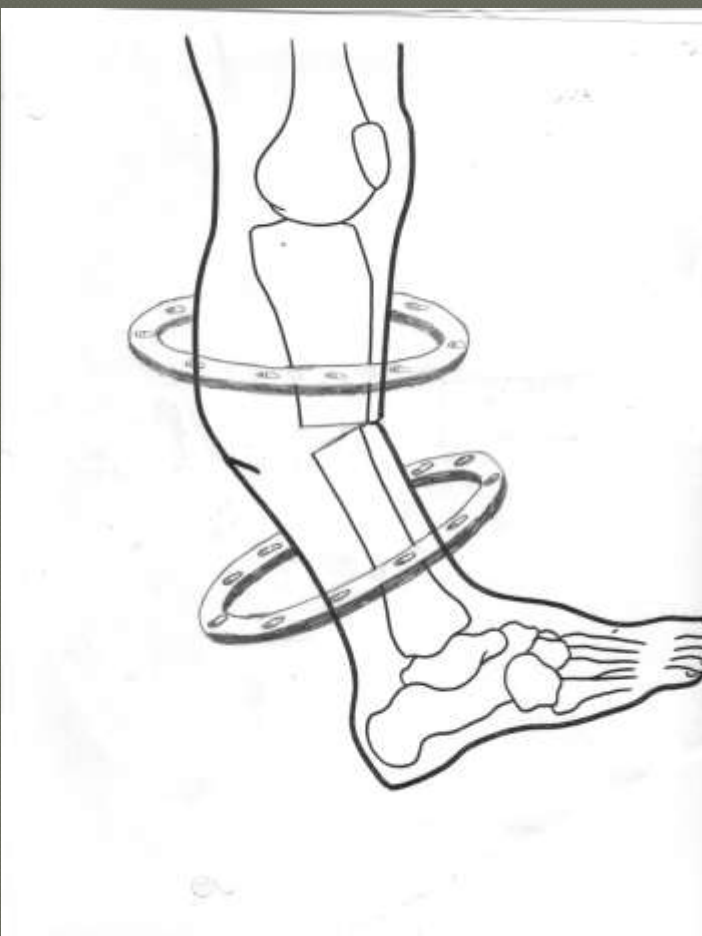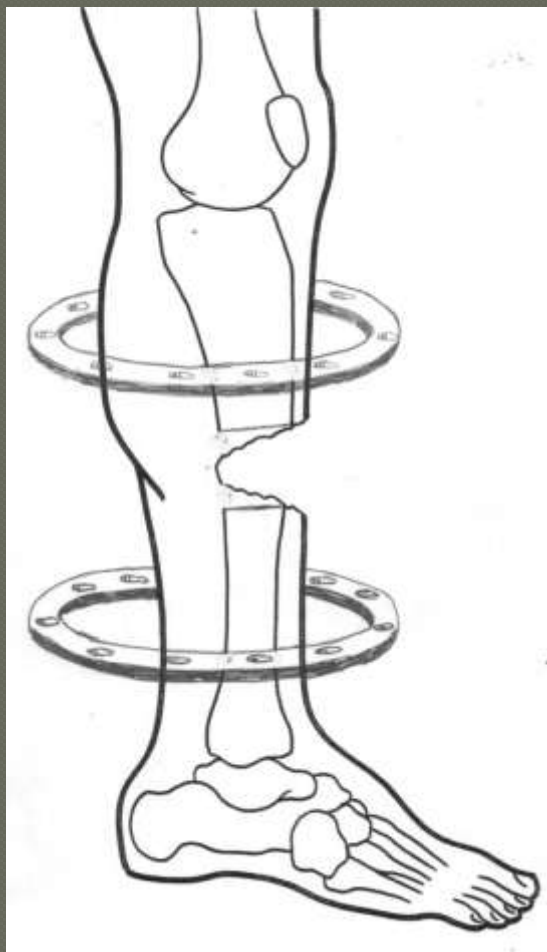
The devices that are the subject of this manuscript are FDA approved. Reprints: S. Robert Rozbruch, MD, The Hospital for Special Surgery, 535 East 70th Street, New York, NY 10021 (e-mail: RozbruchSR@hss.edu).

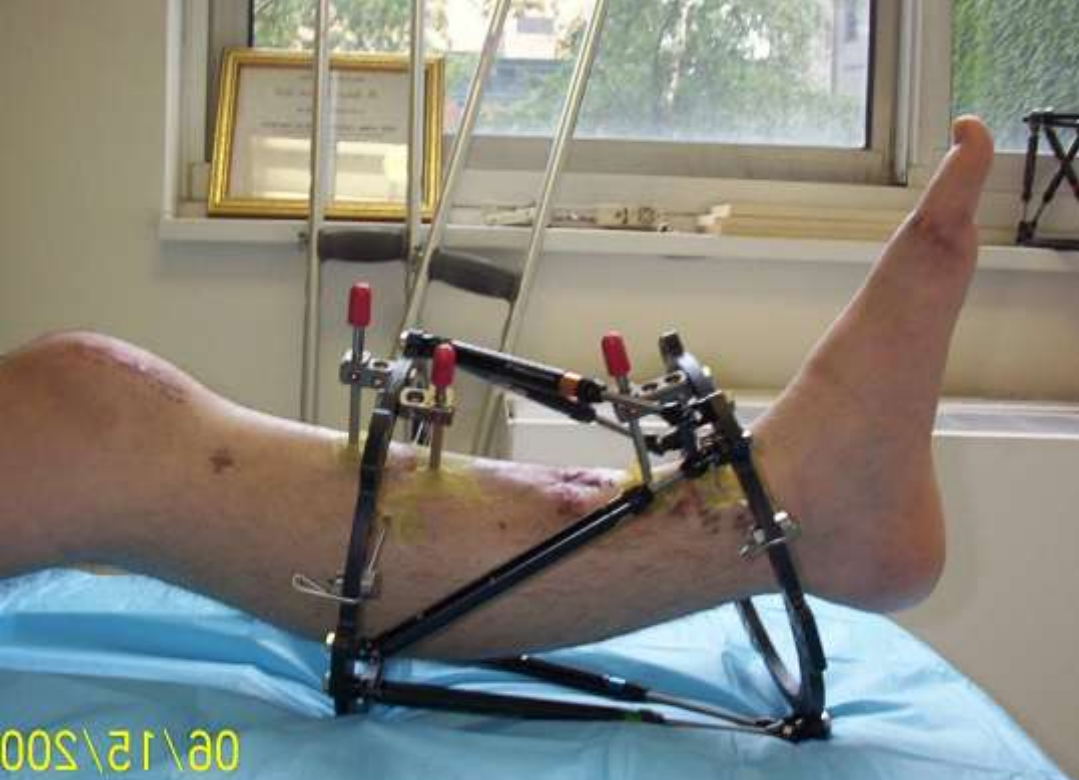Copyright © 2006 by Lippincott Williams & Wilkins

Infected nonunion, bone loss, soft-tissue defect

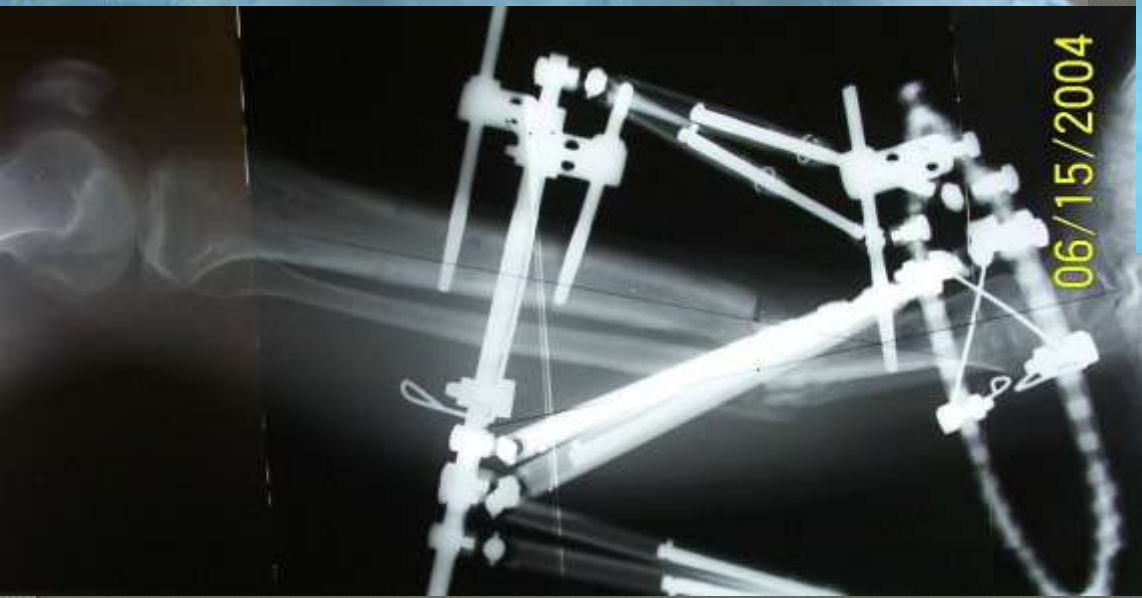
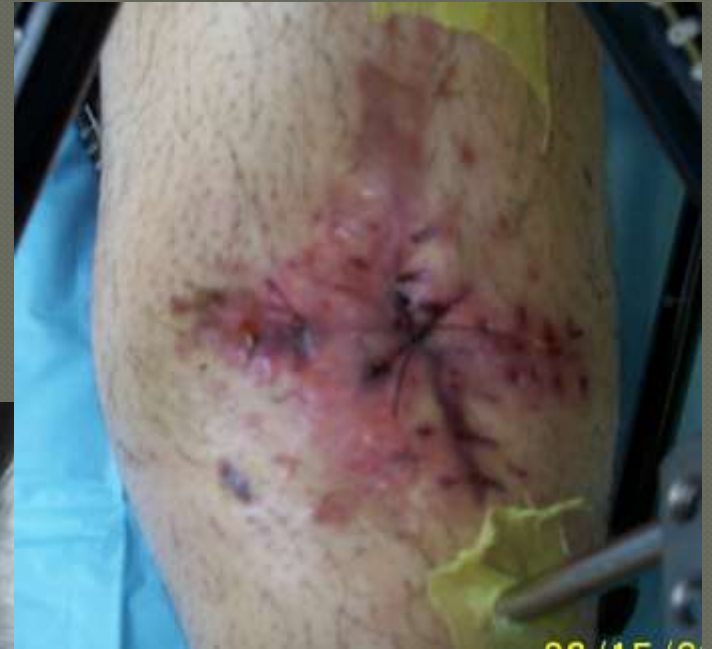

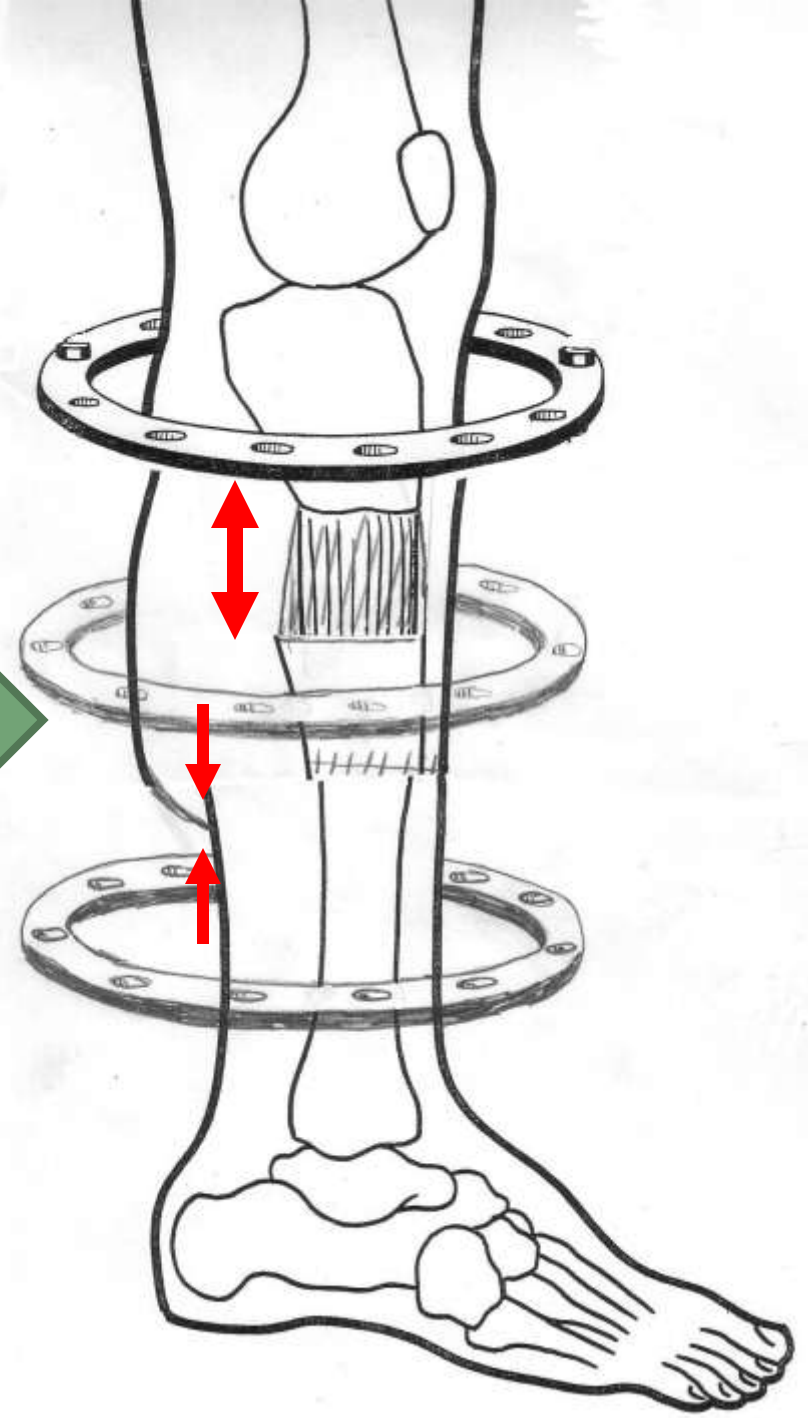

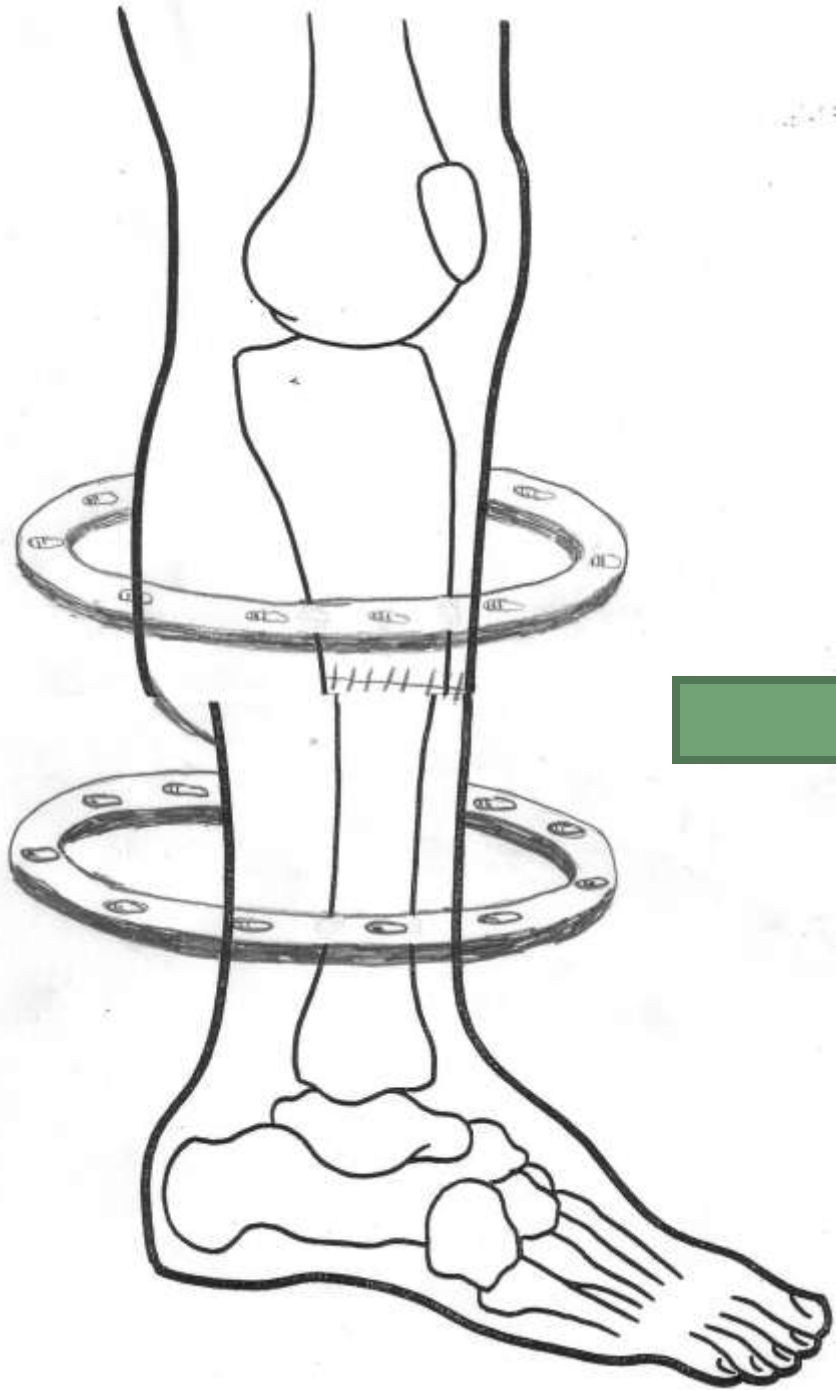


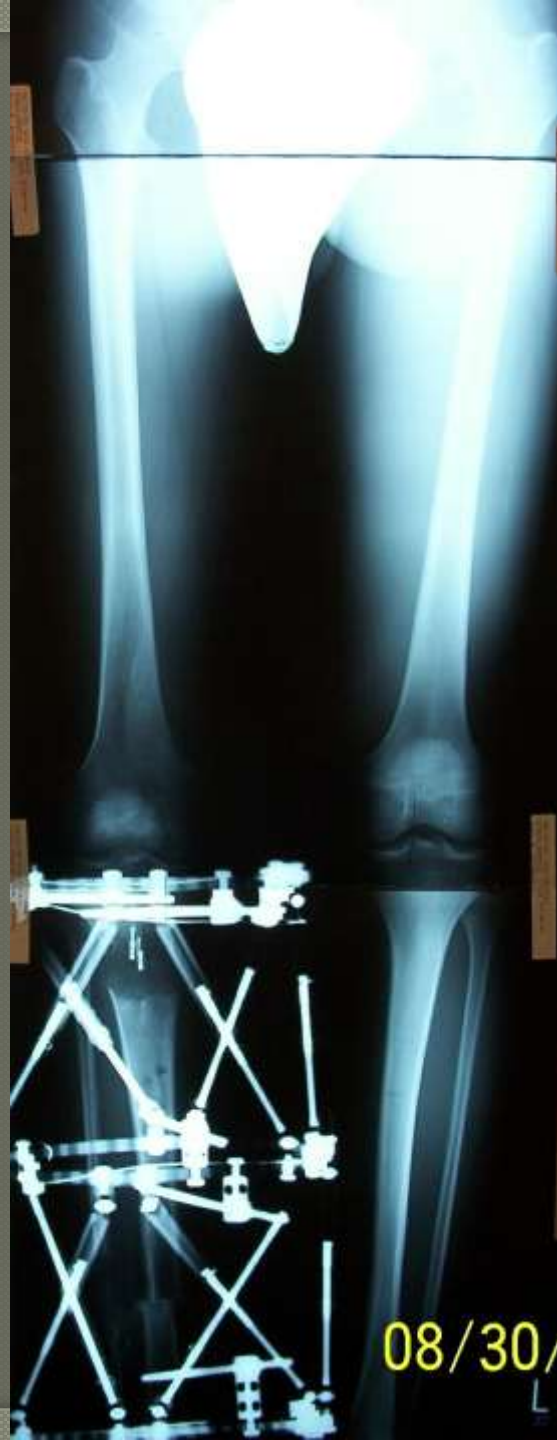
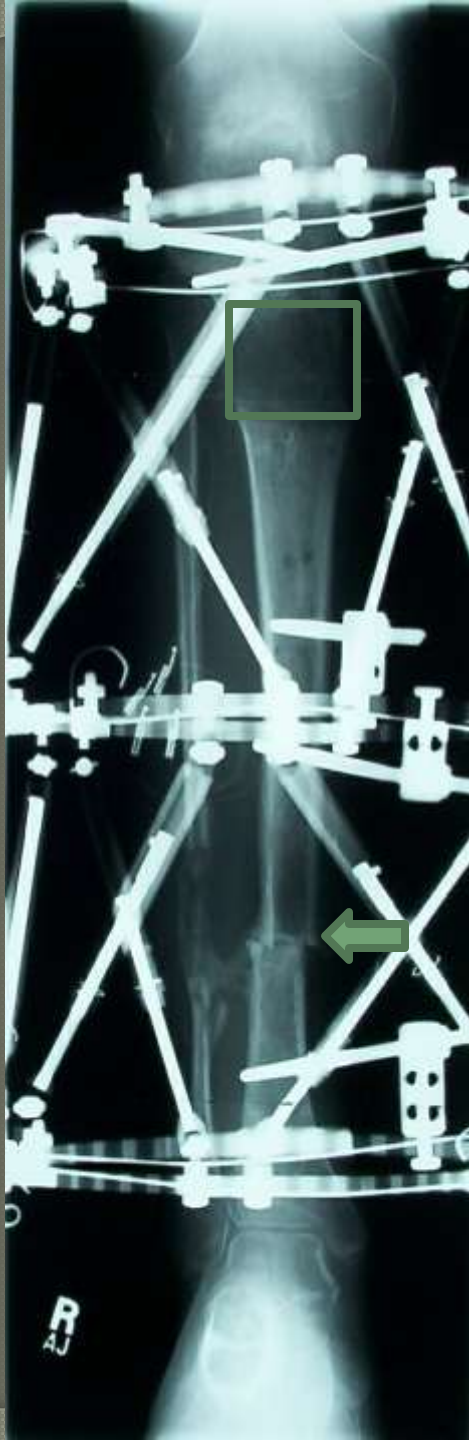


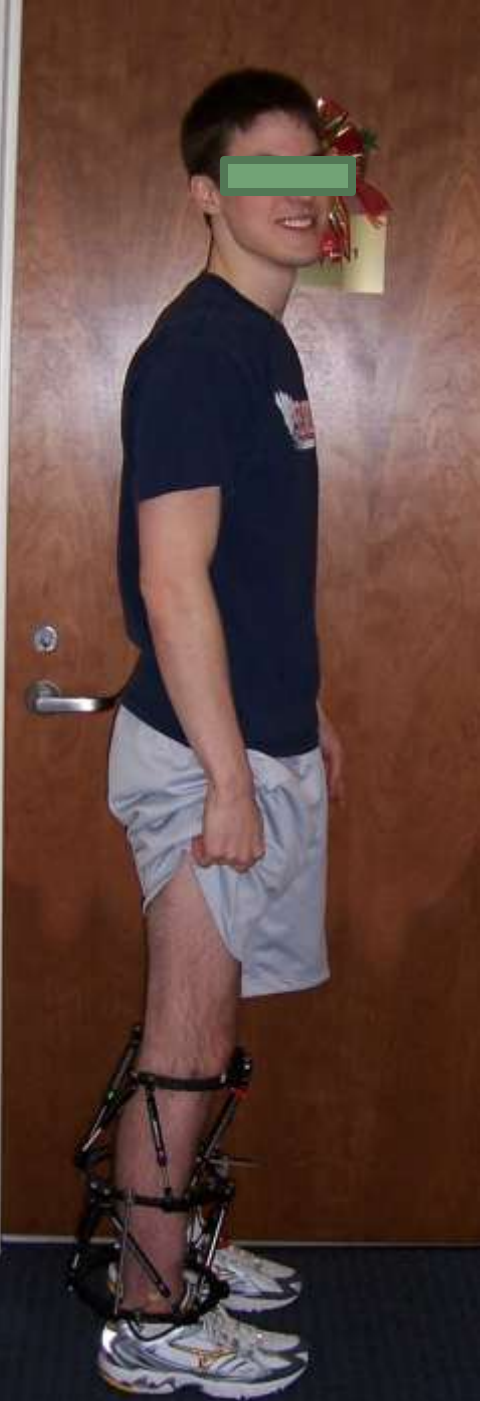
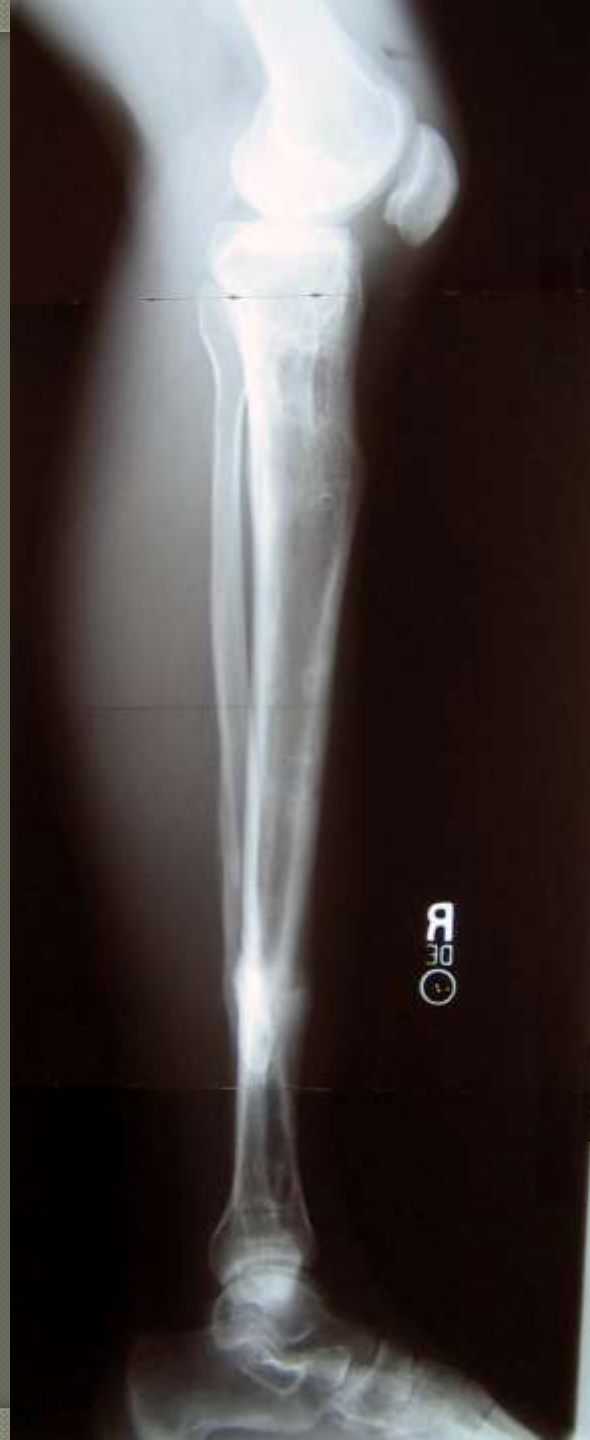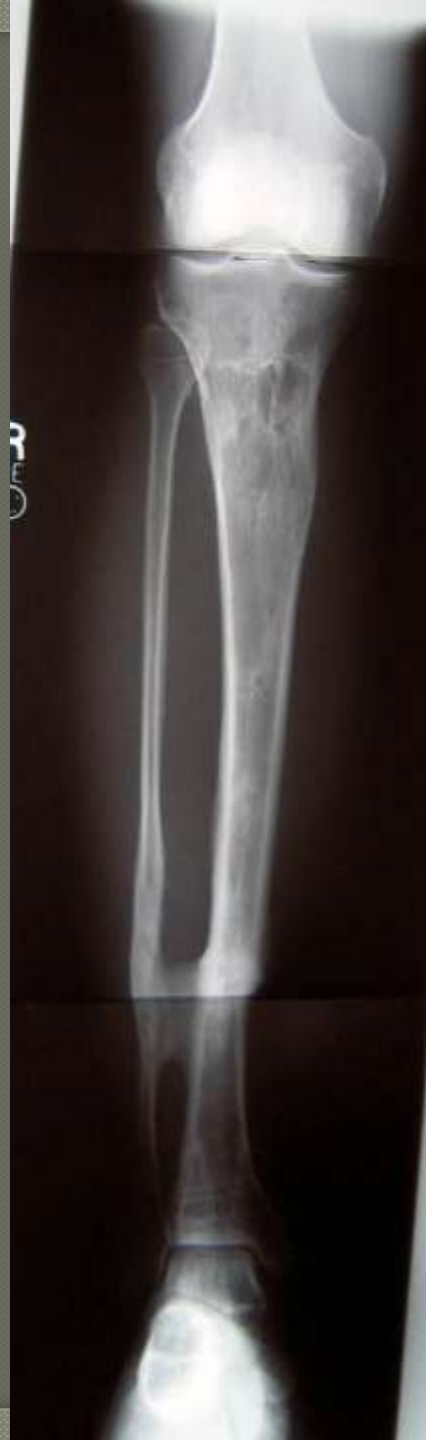1 month

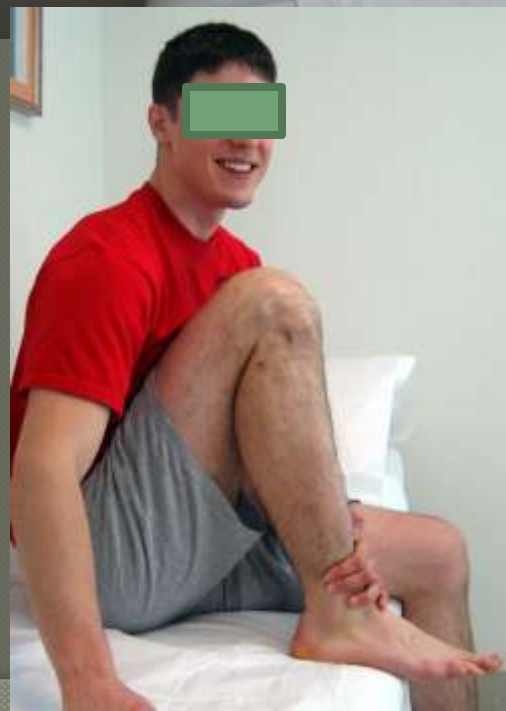
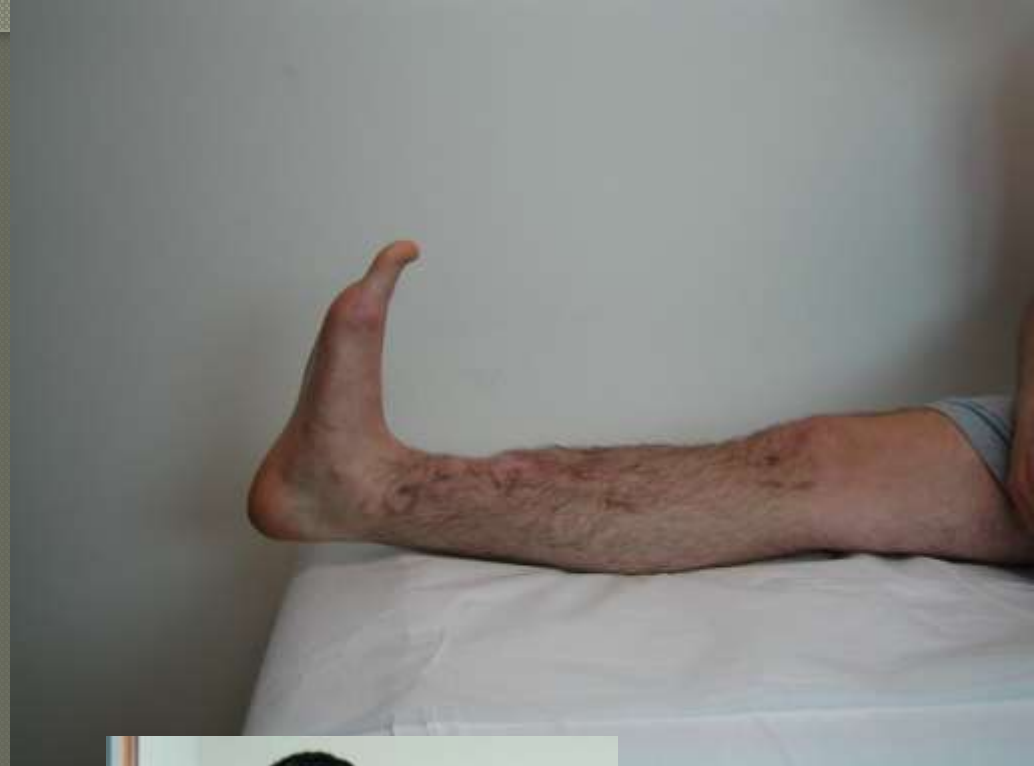
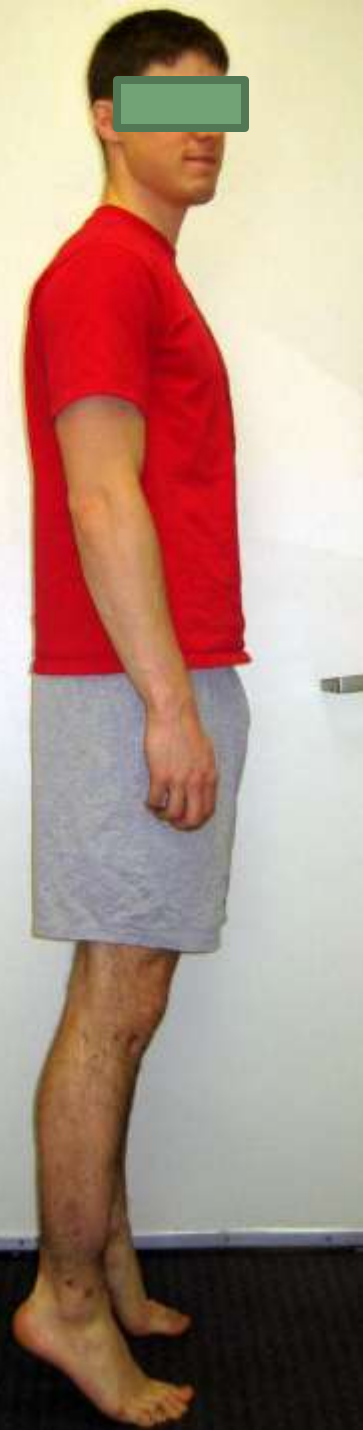






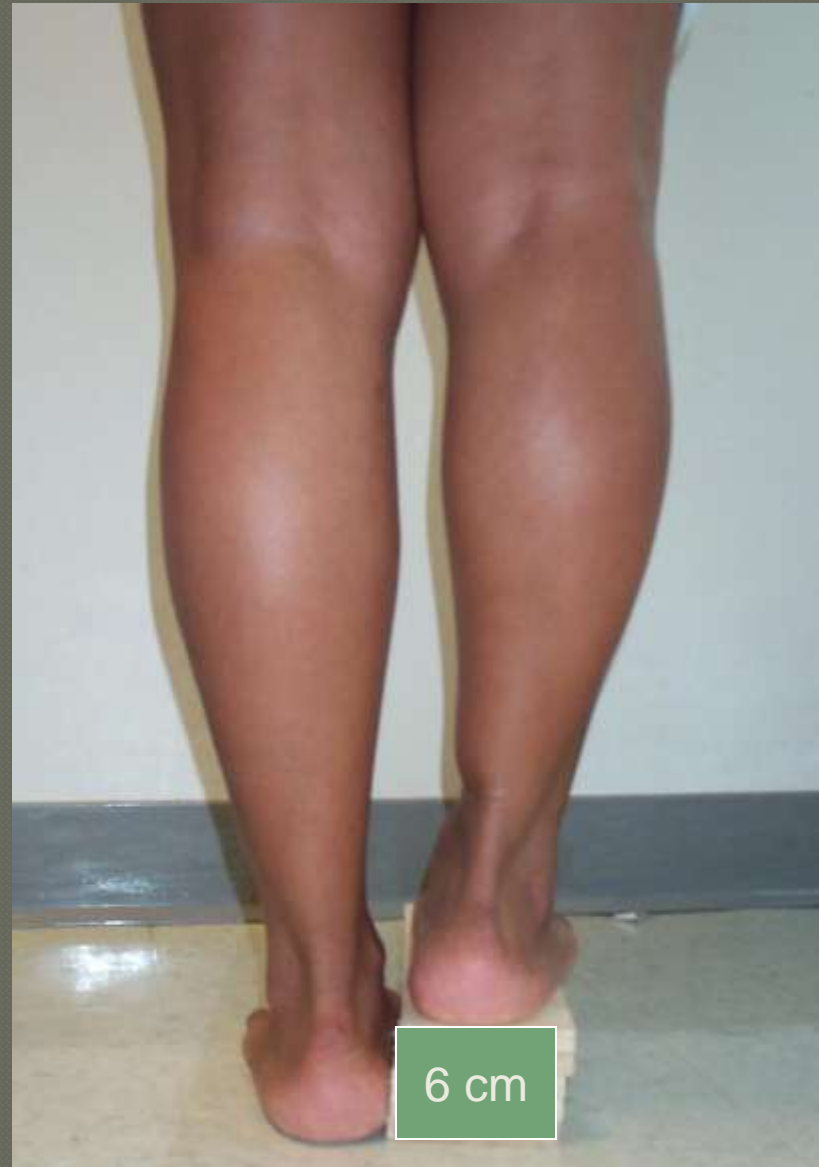


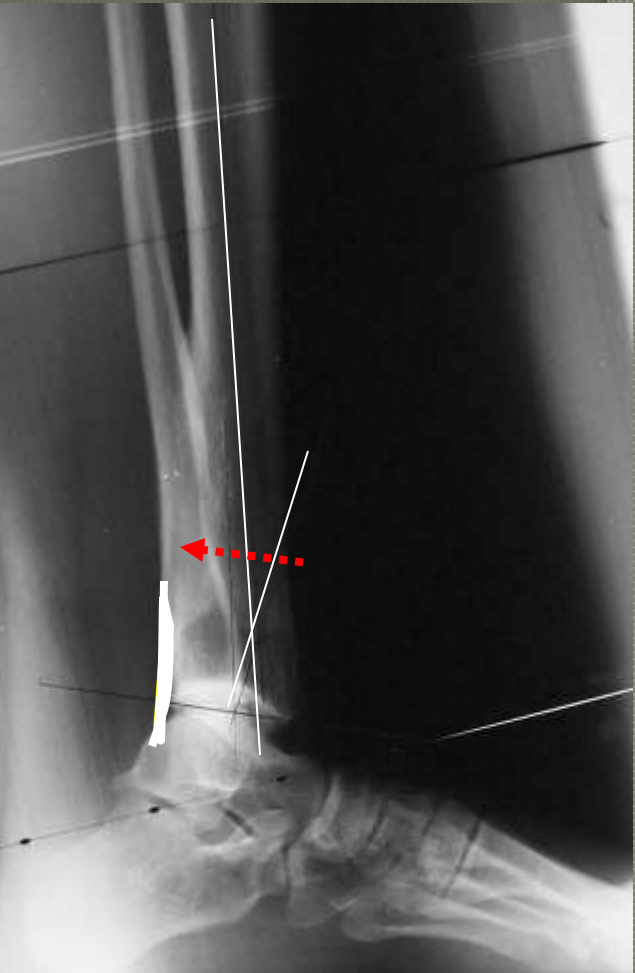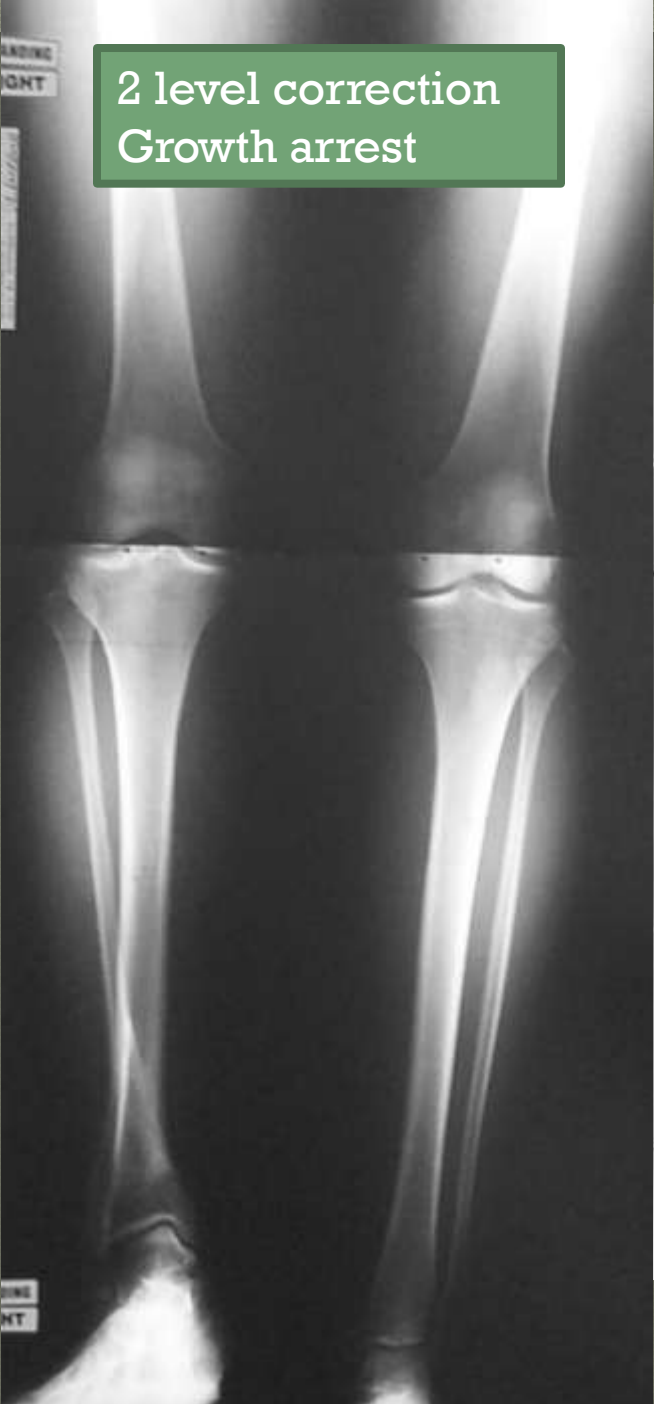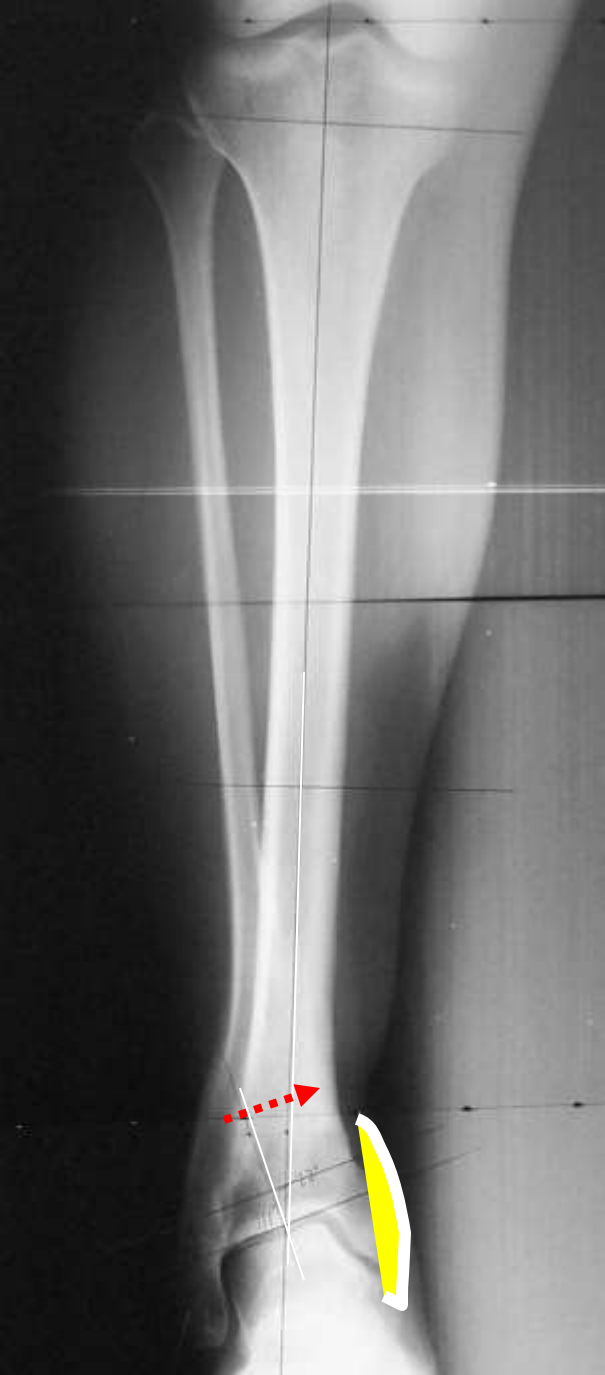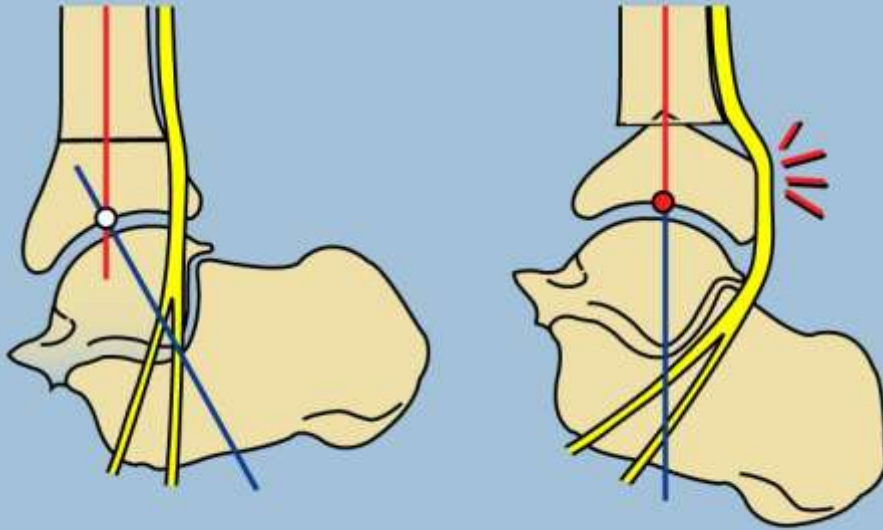


Tibia malunion, LLD 6cm, preop



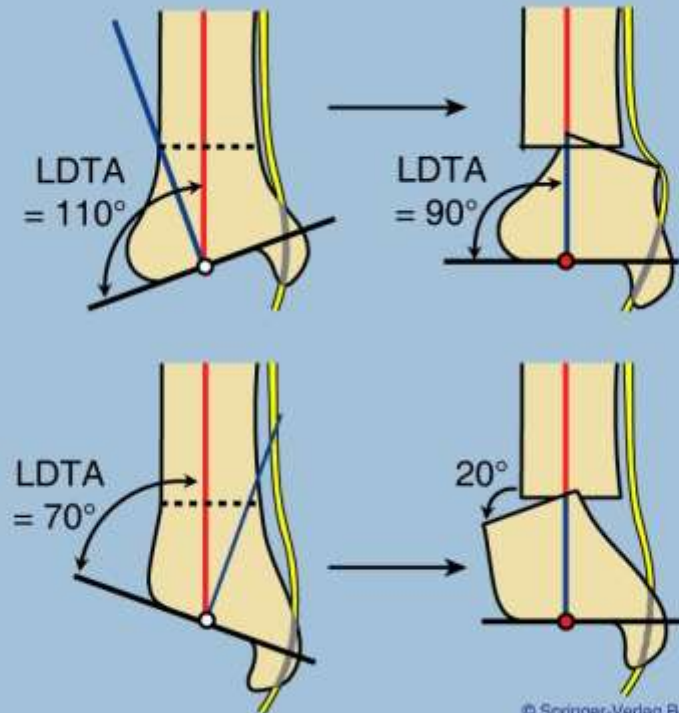
2 level correction
Growth arrest





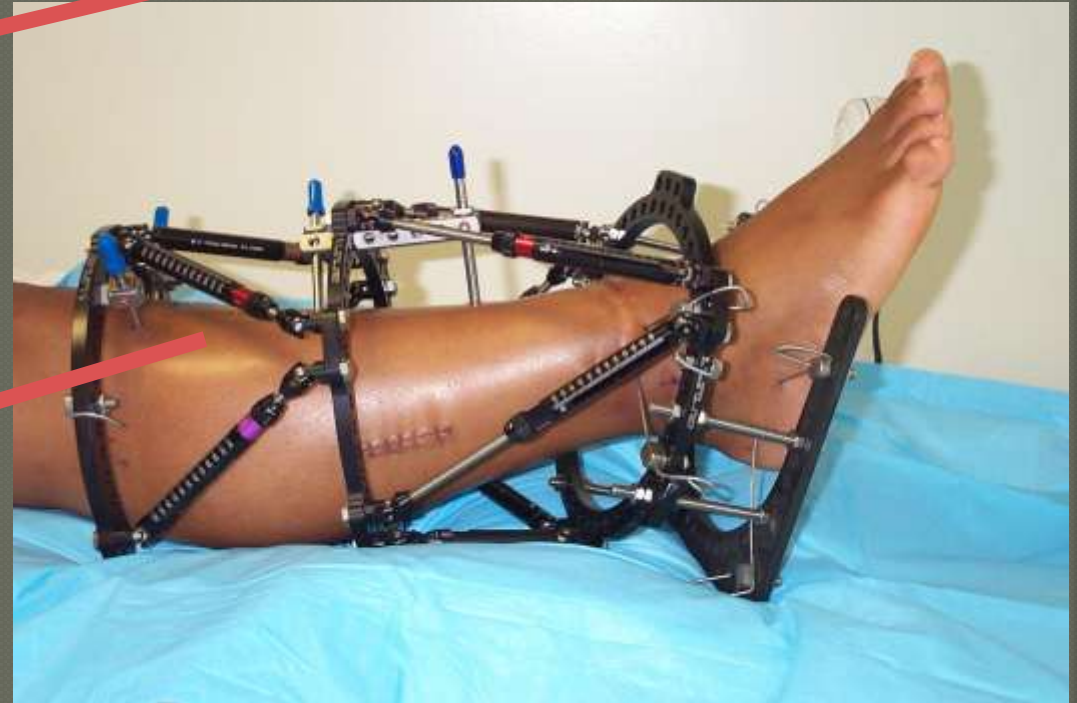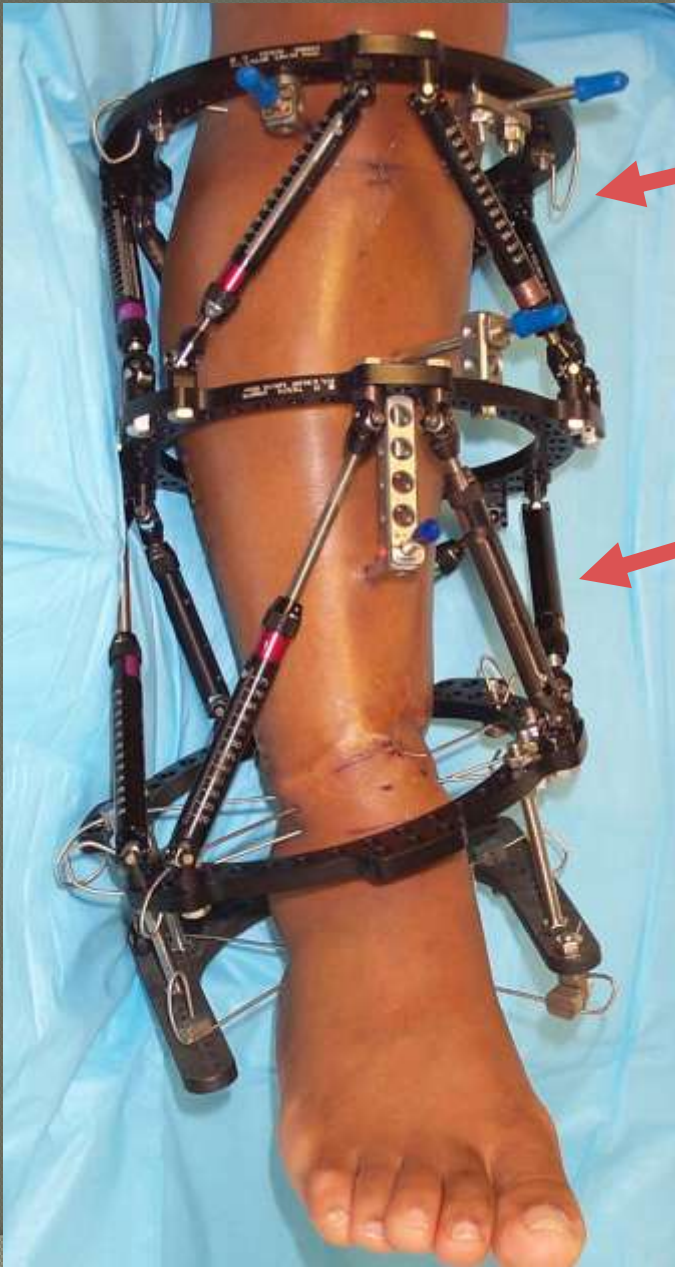© Springer-Verlag Berlin Heidelberg 2003

Neurologic compromise



© Springer-Verlag Berlin Heidelberg 2003

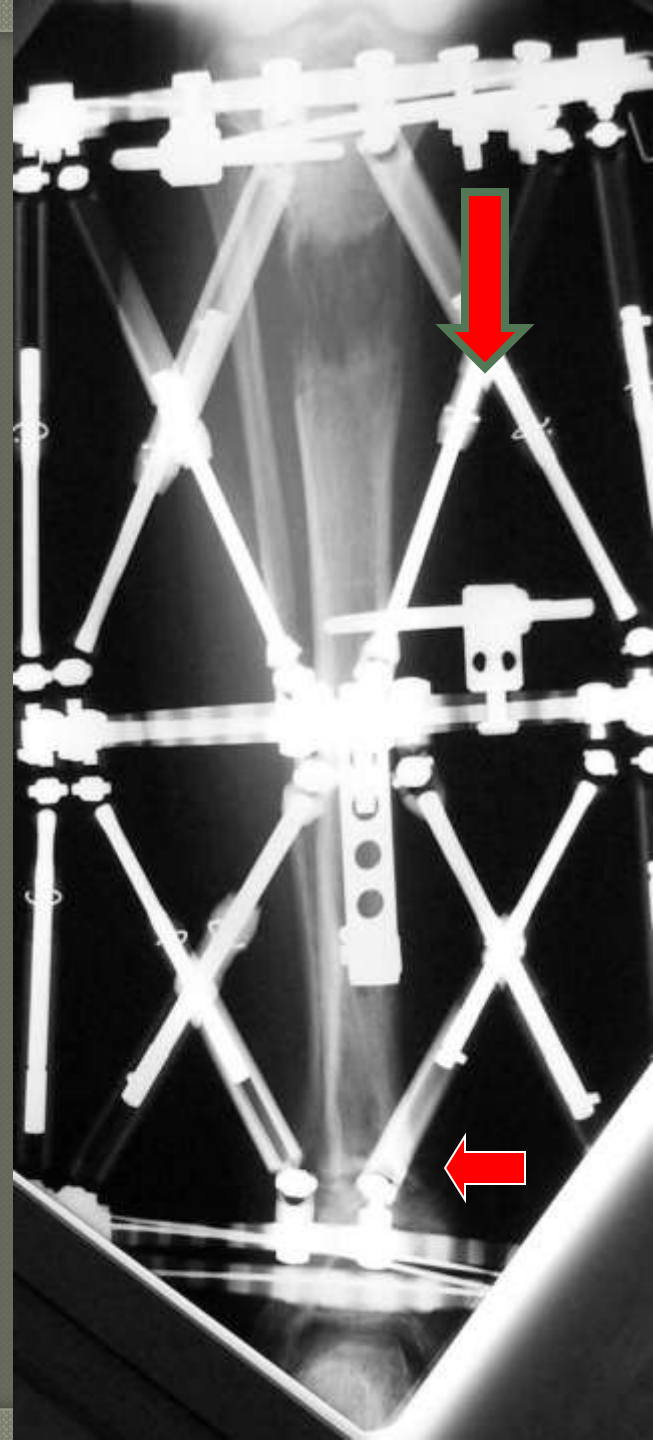Postop, Double level osteotomy

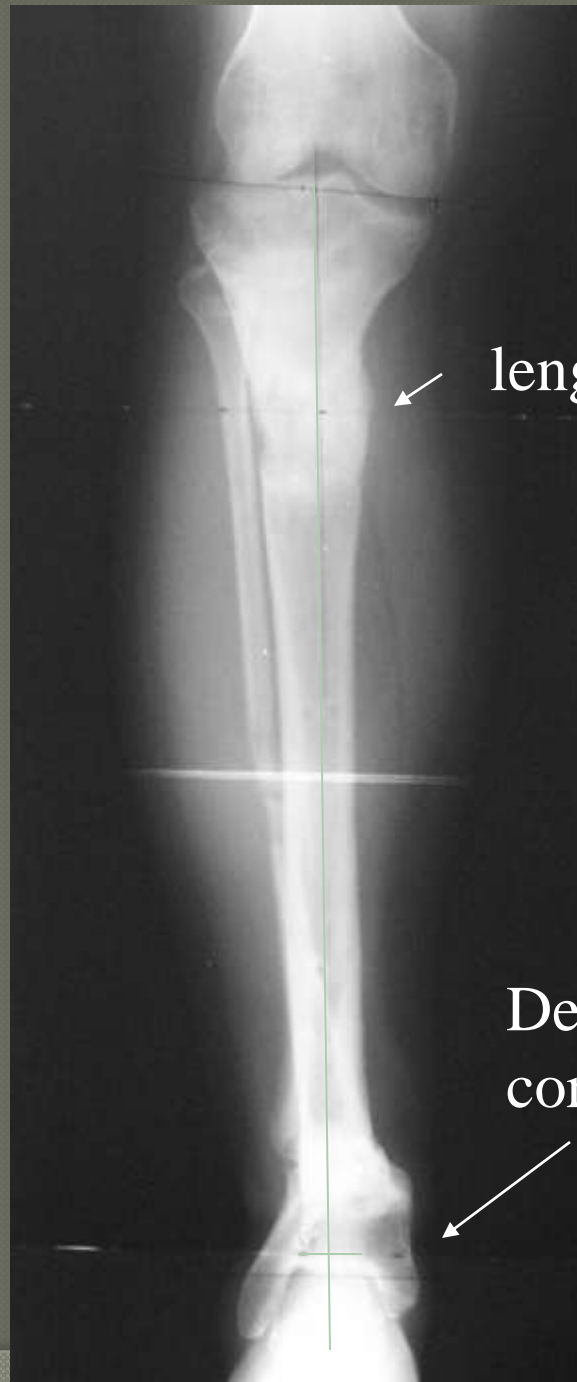

2 separate programs
Independent of each other



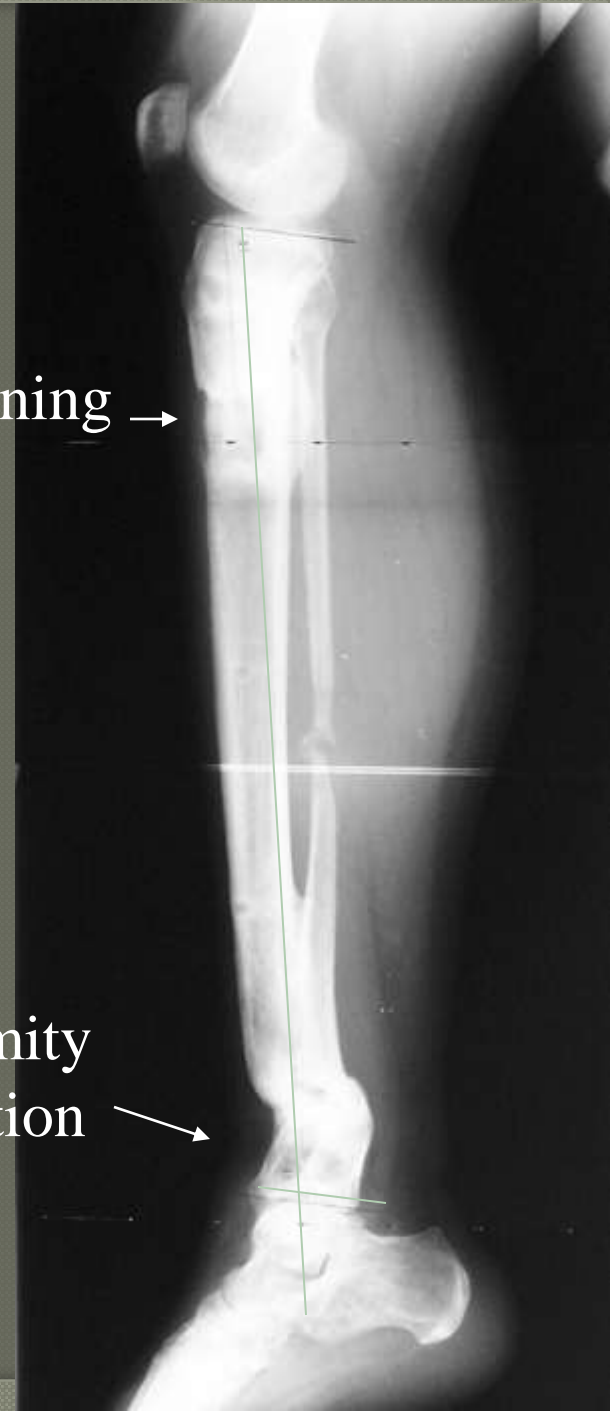4 months



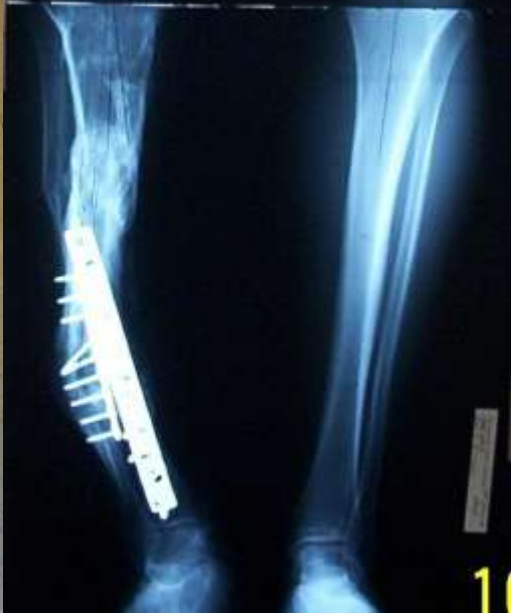
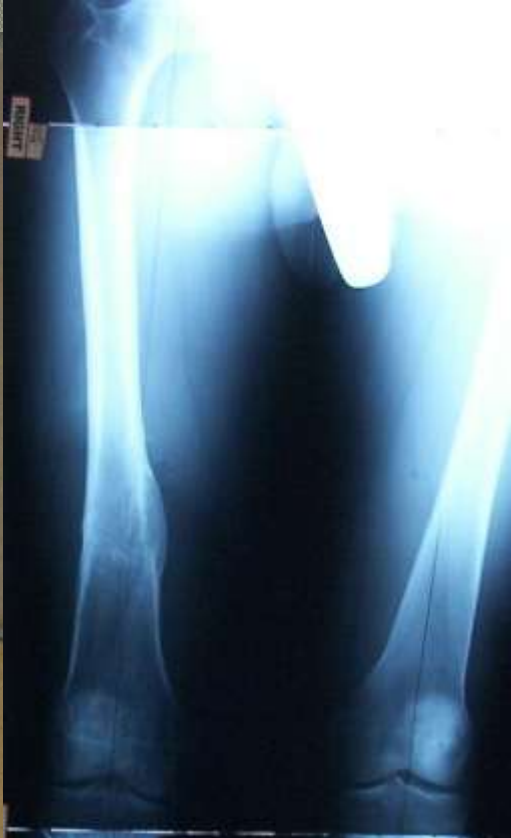
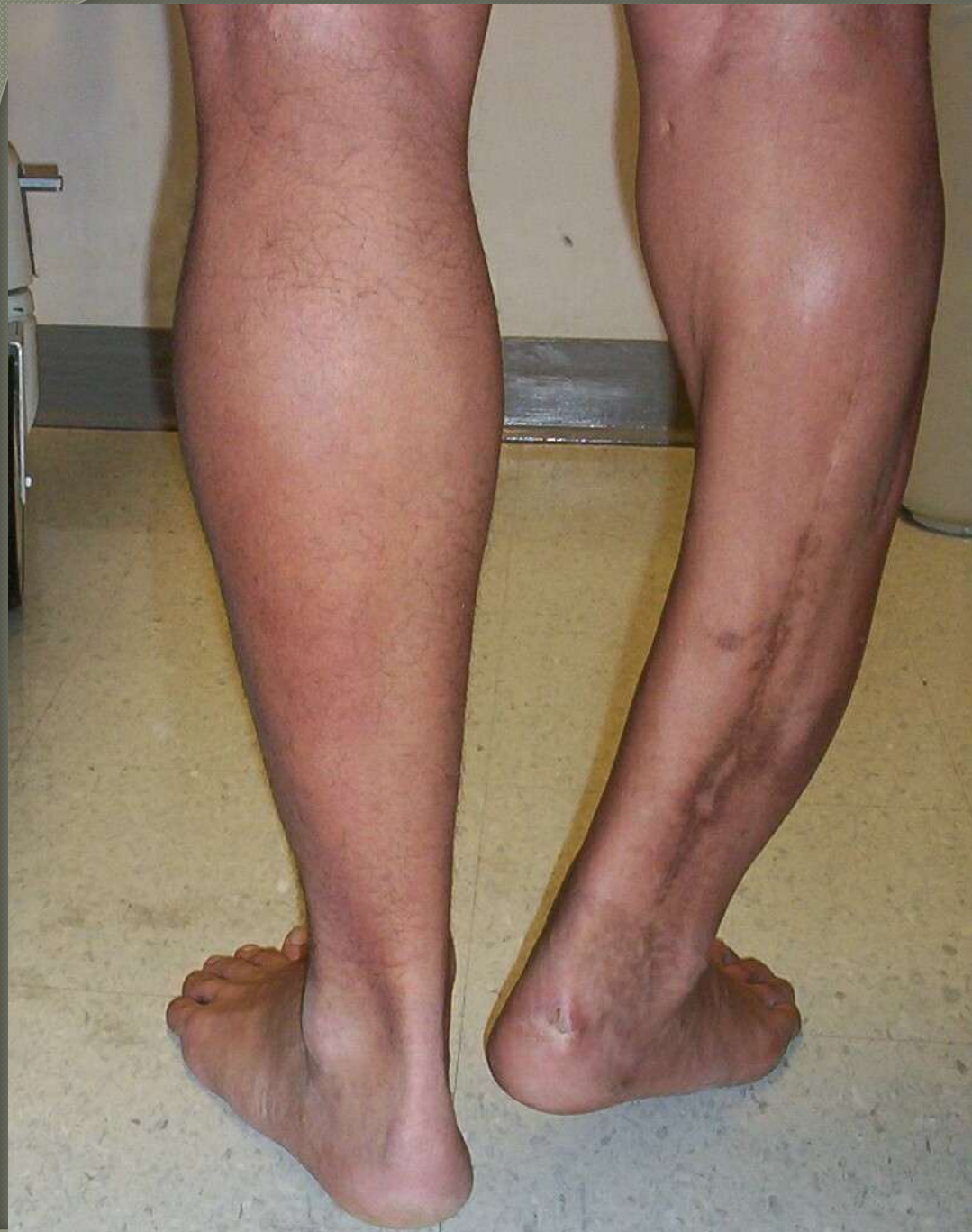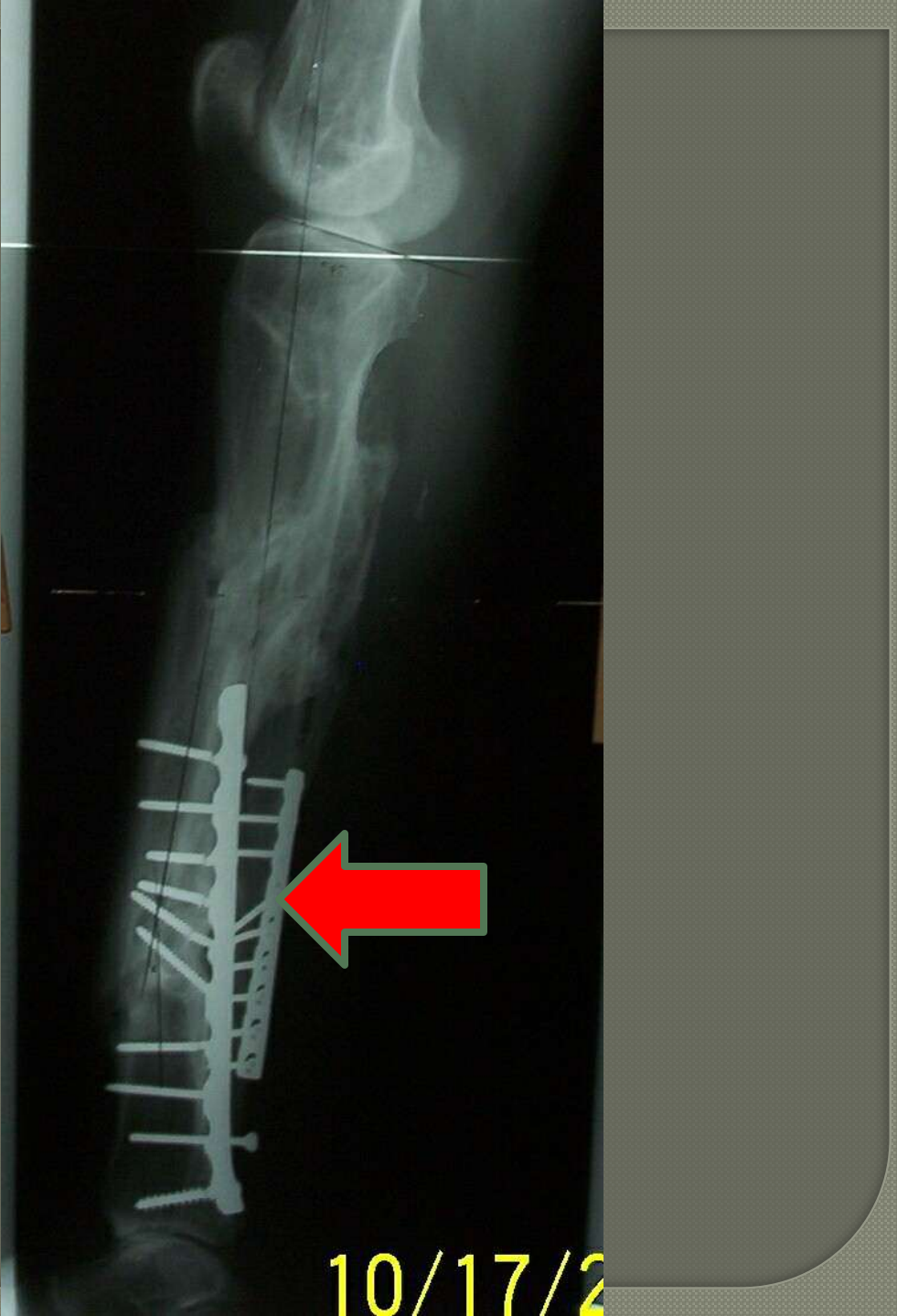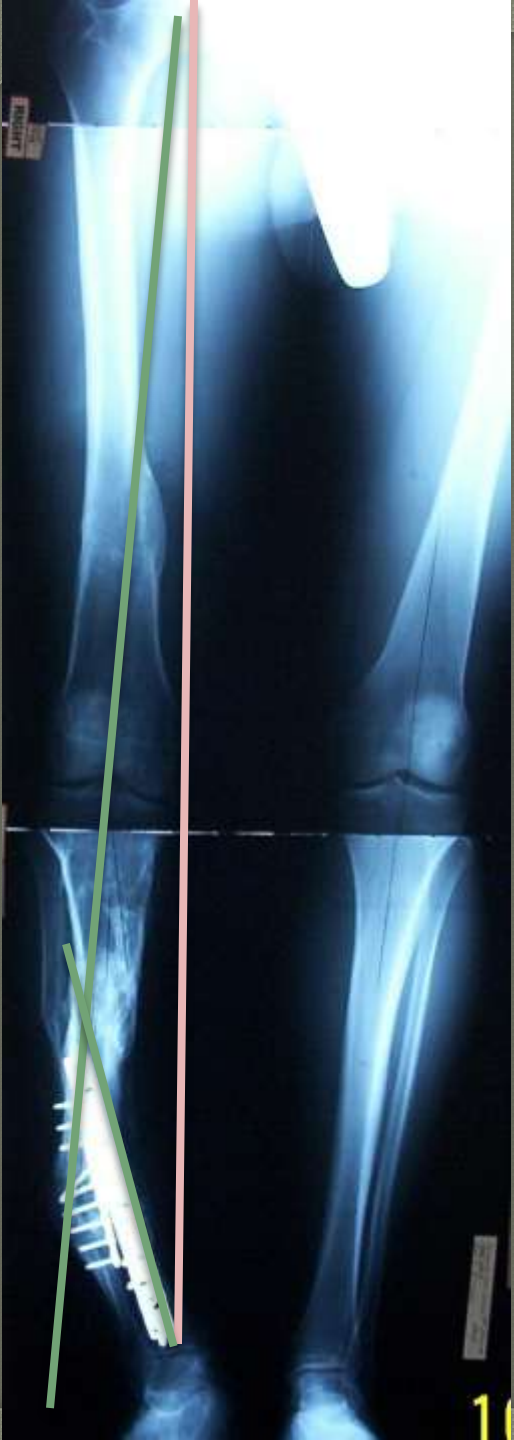lengthening →

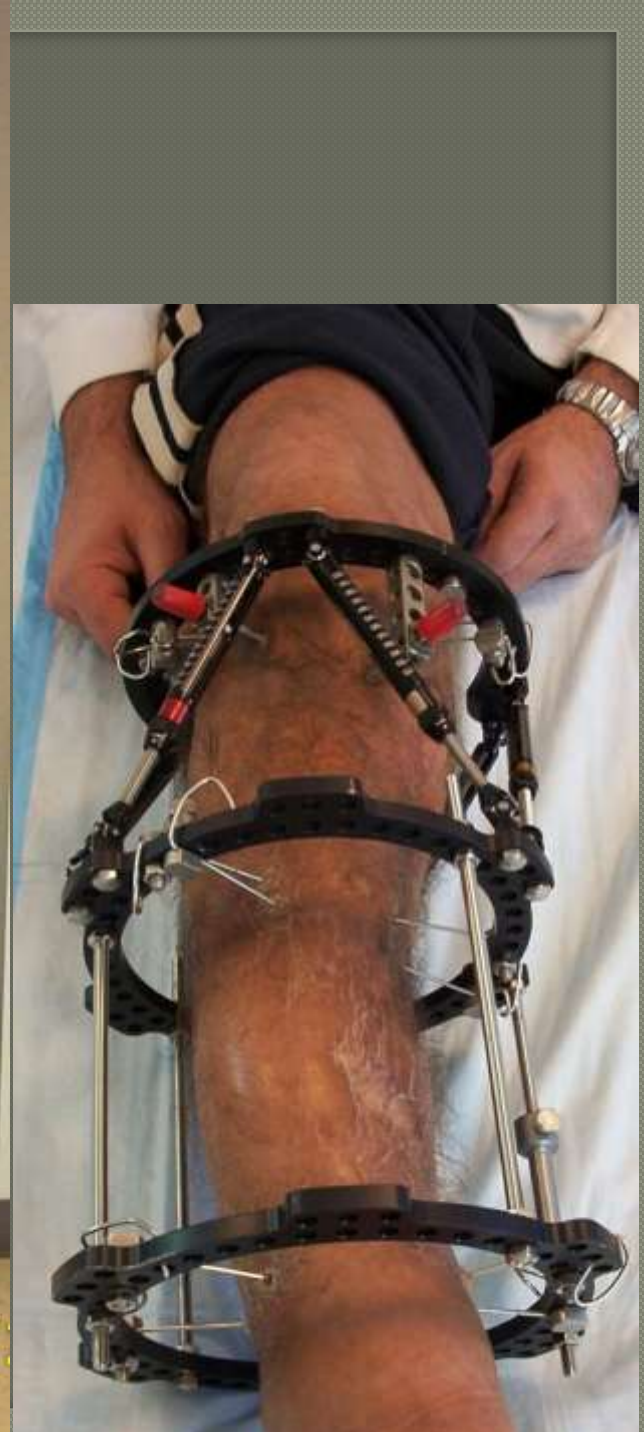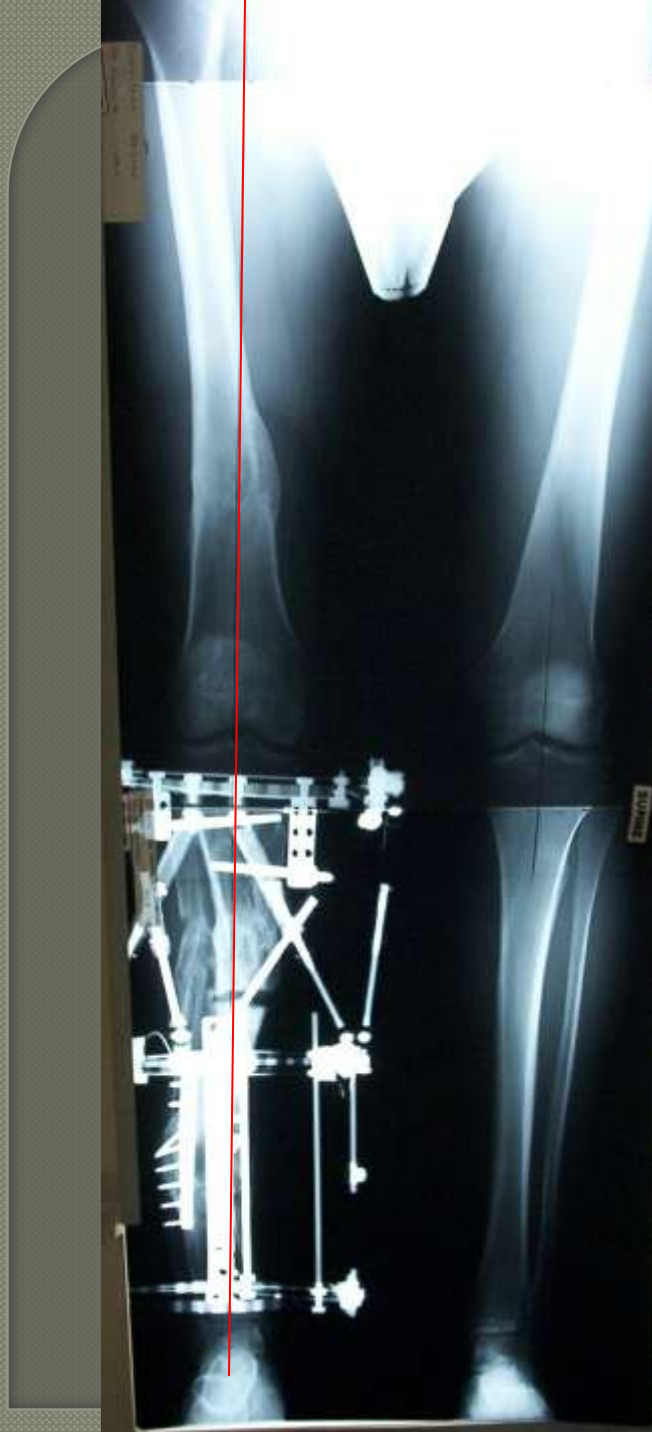Deformity
correction →





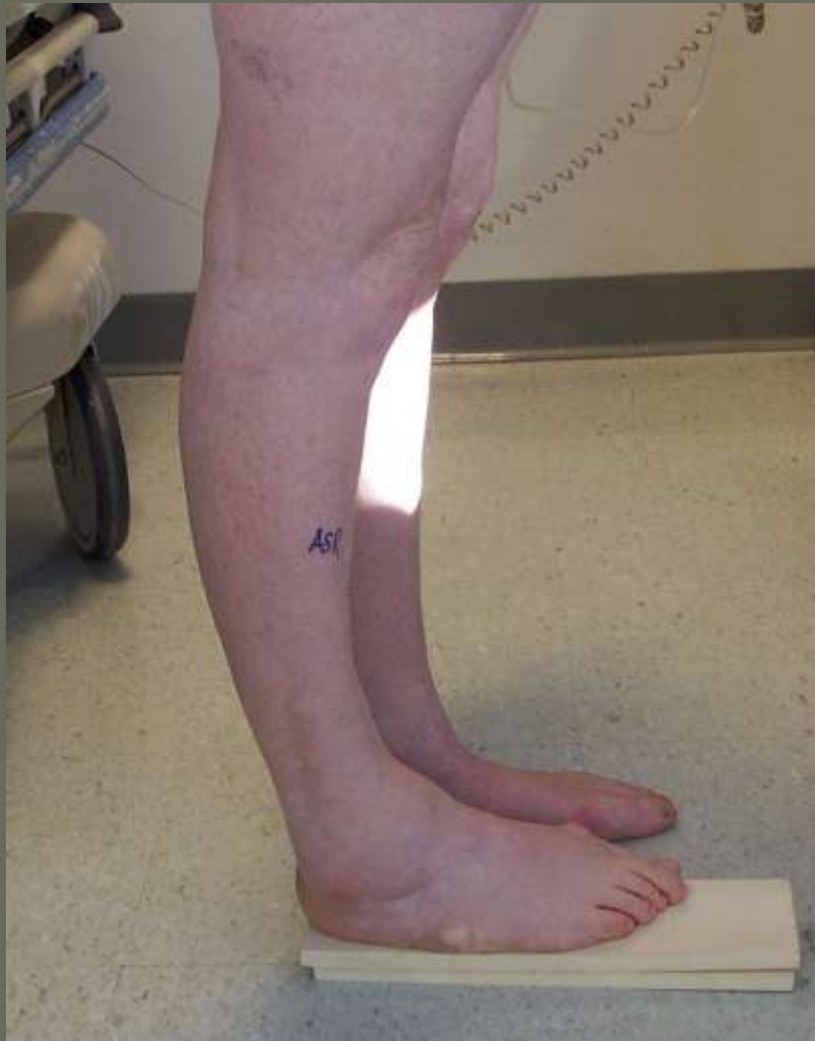




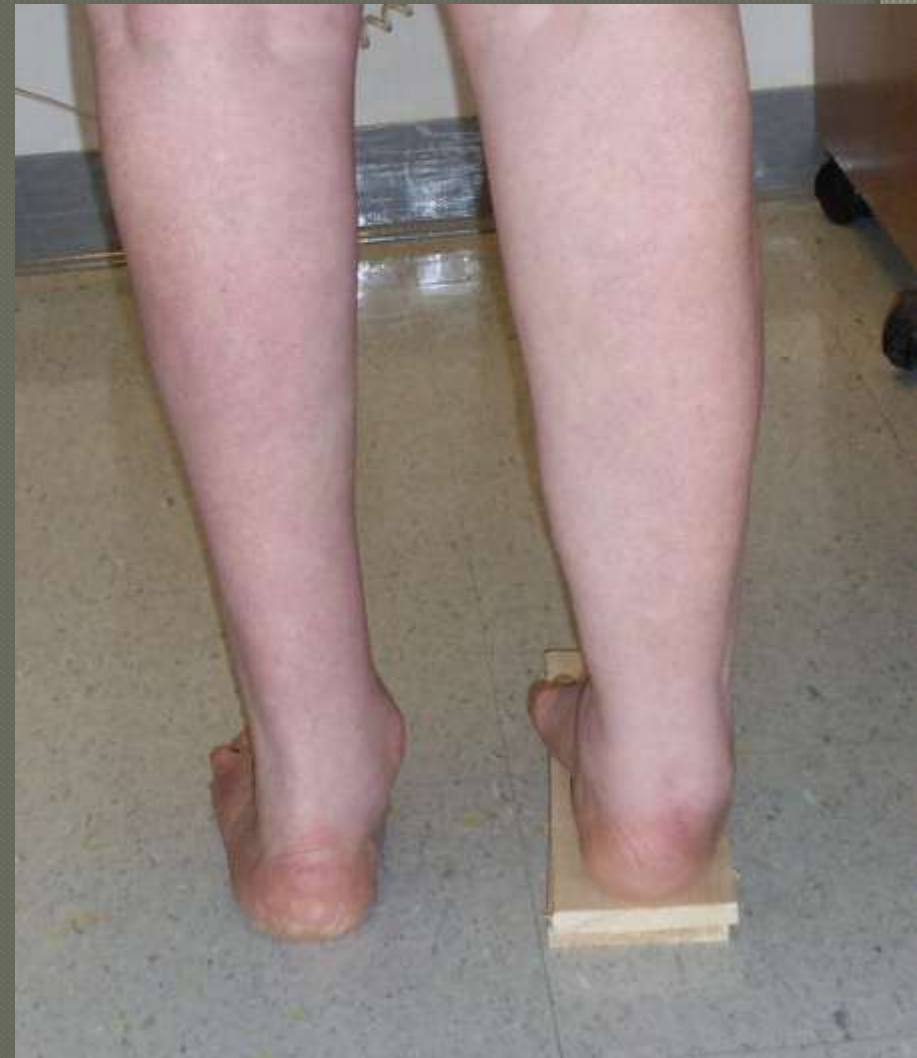





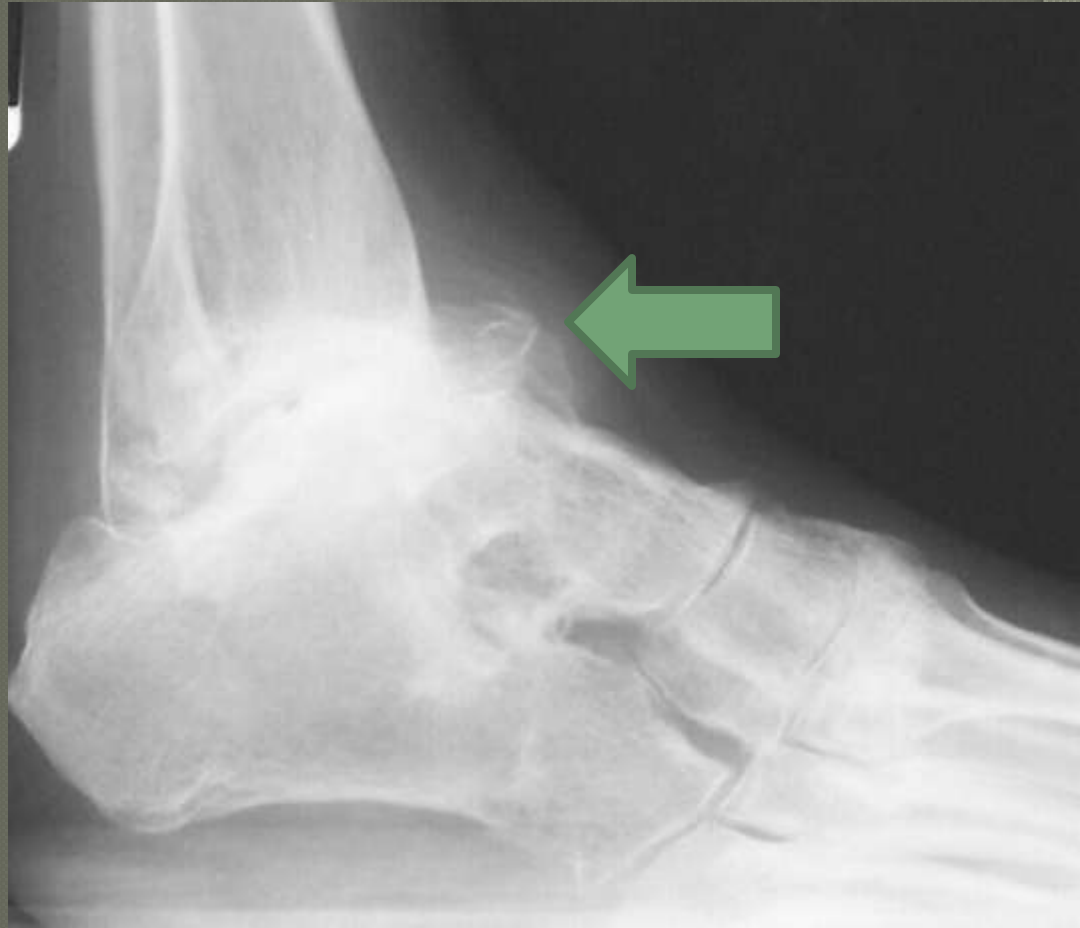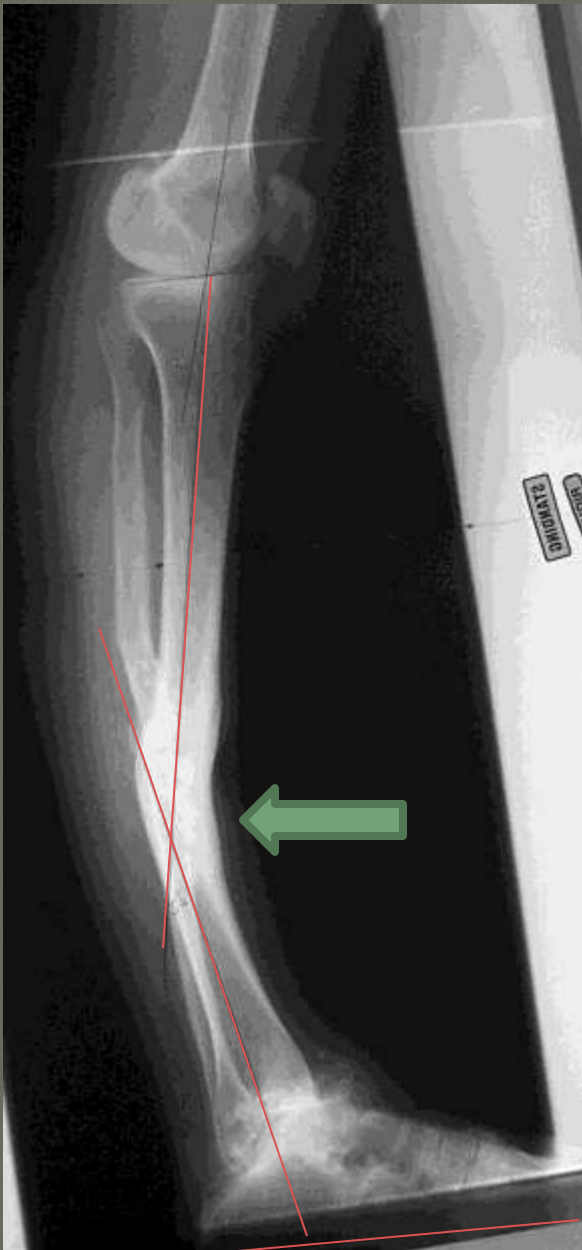


Recurvatum
Foot forward

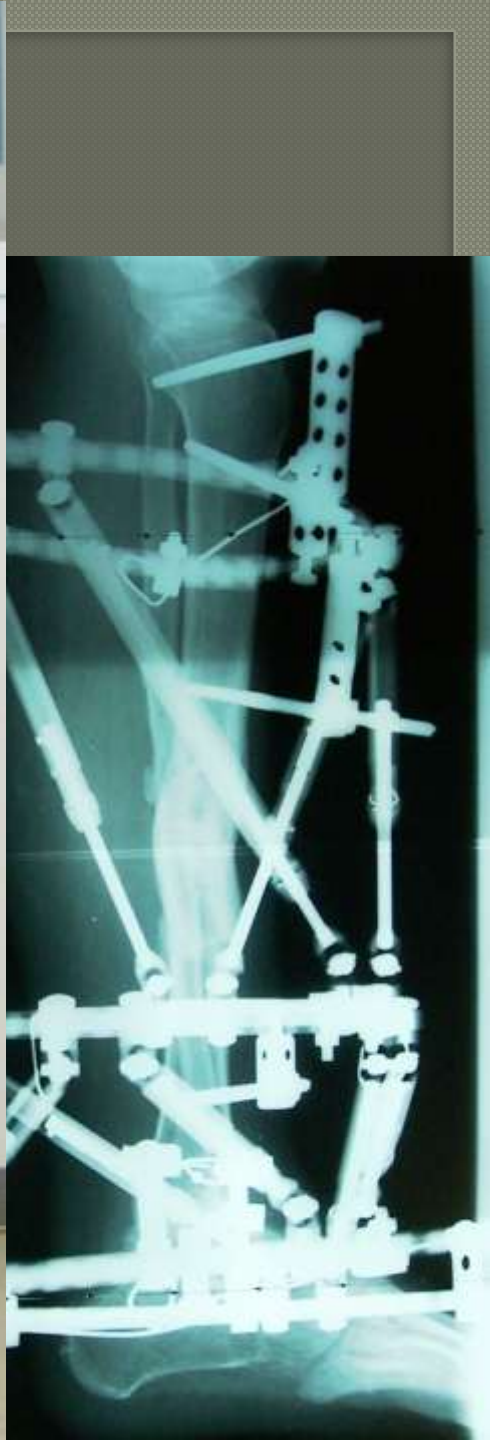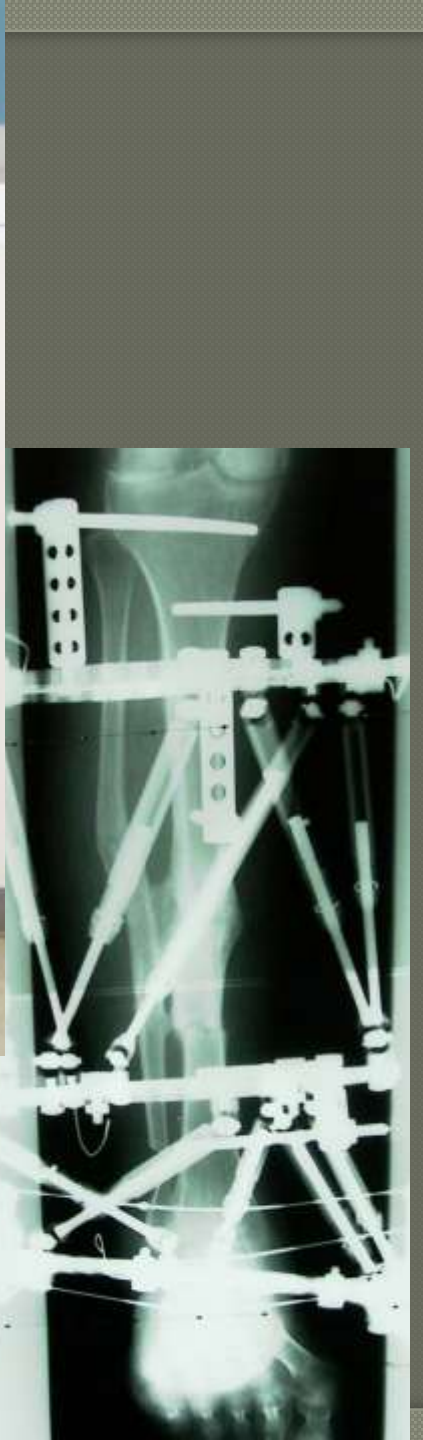


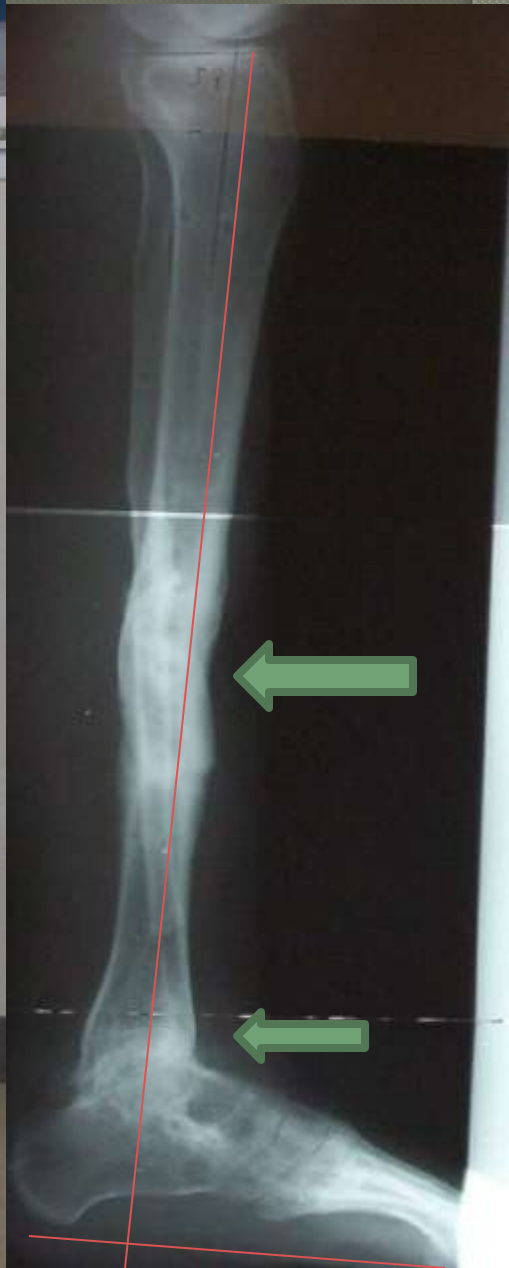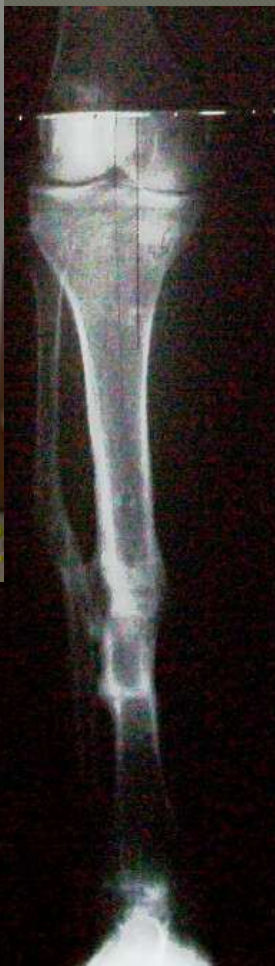LLD
varus

2 level : malunion and fusion

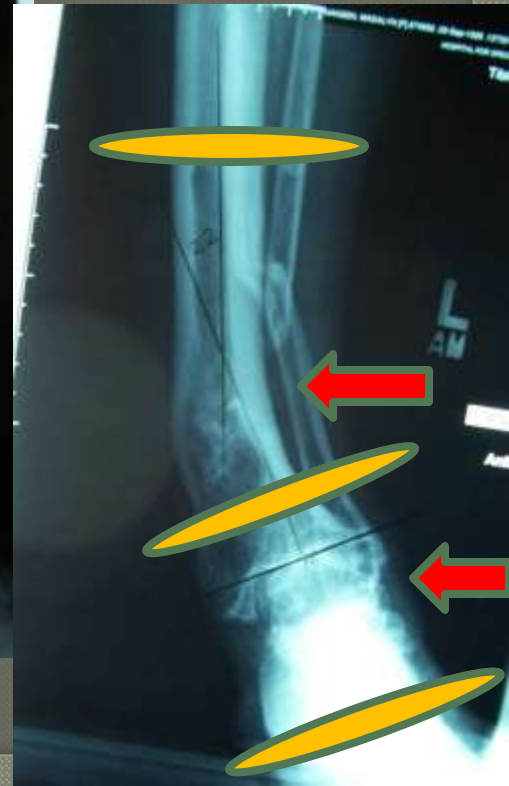
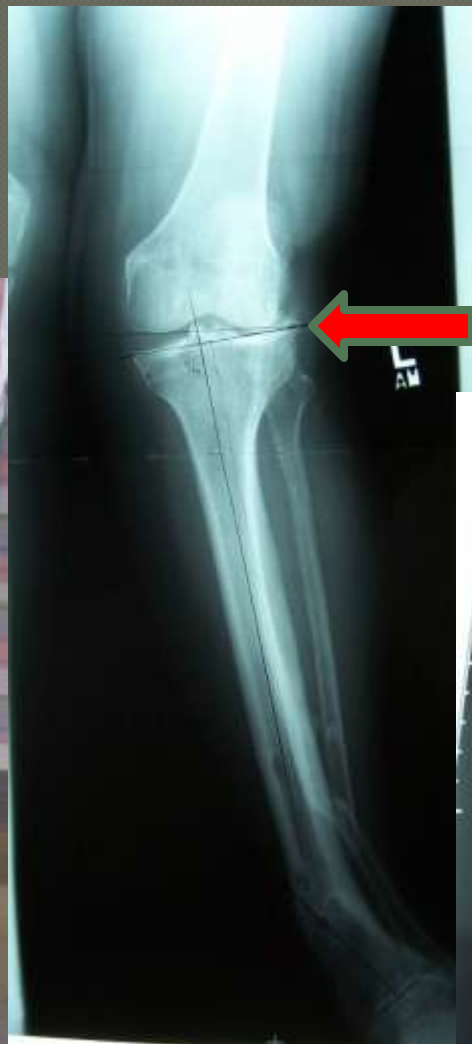
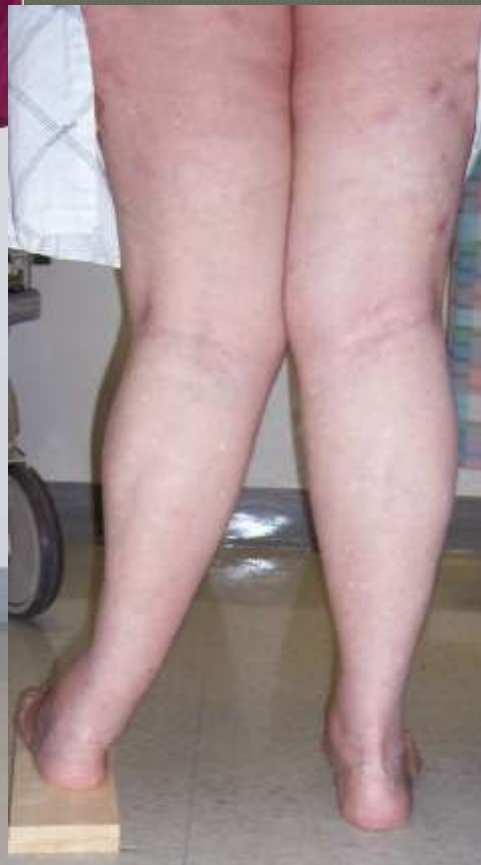
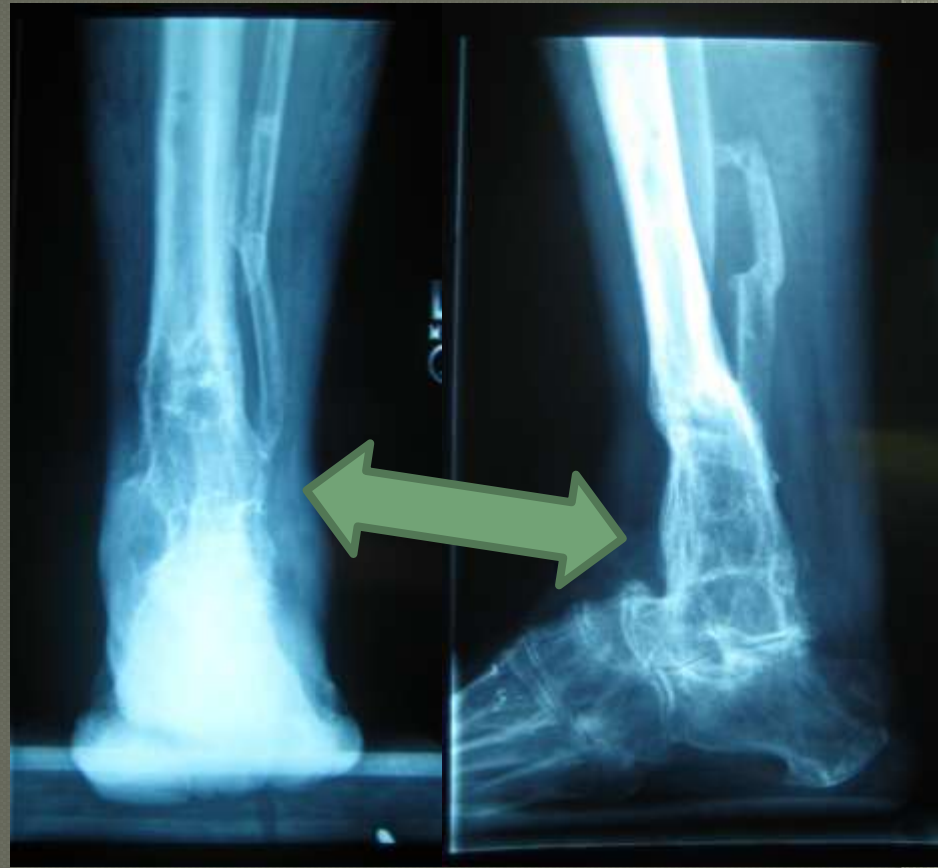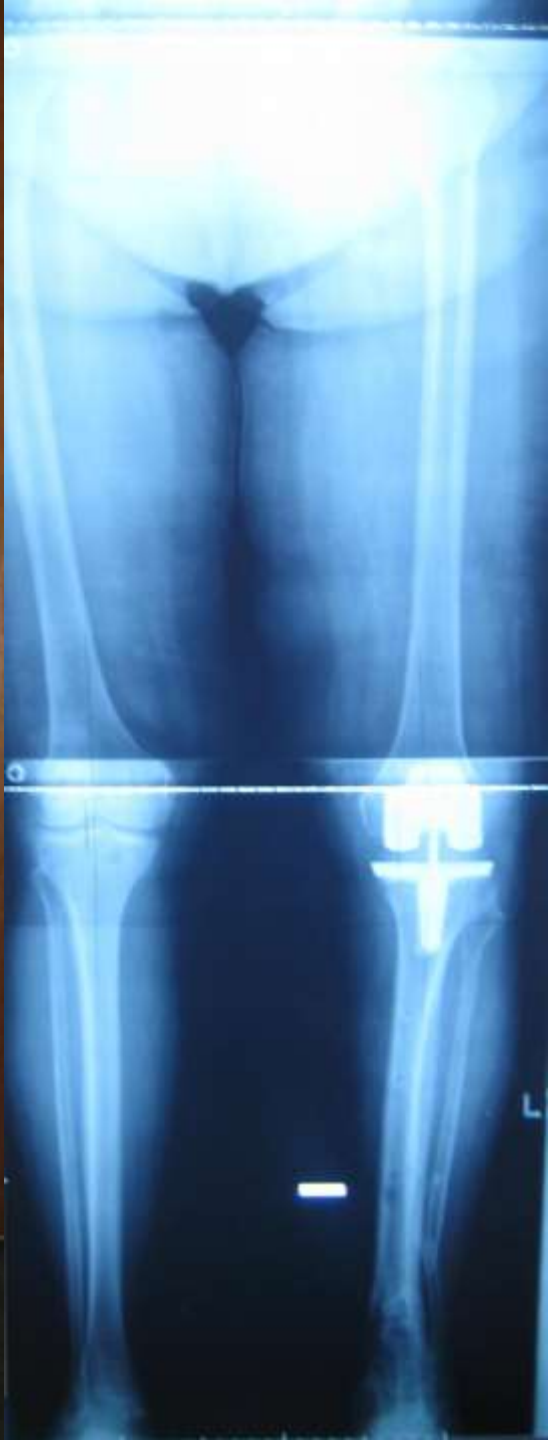Tibia recurvatum
Ankle equinus, varus, ant. Trans, arthrosis



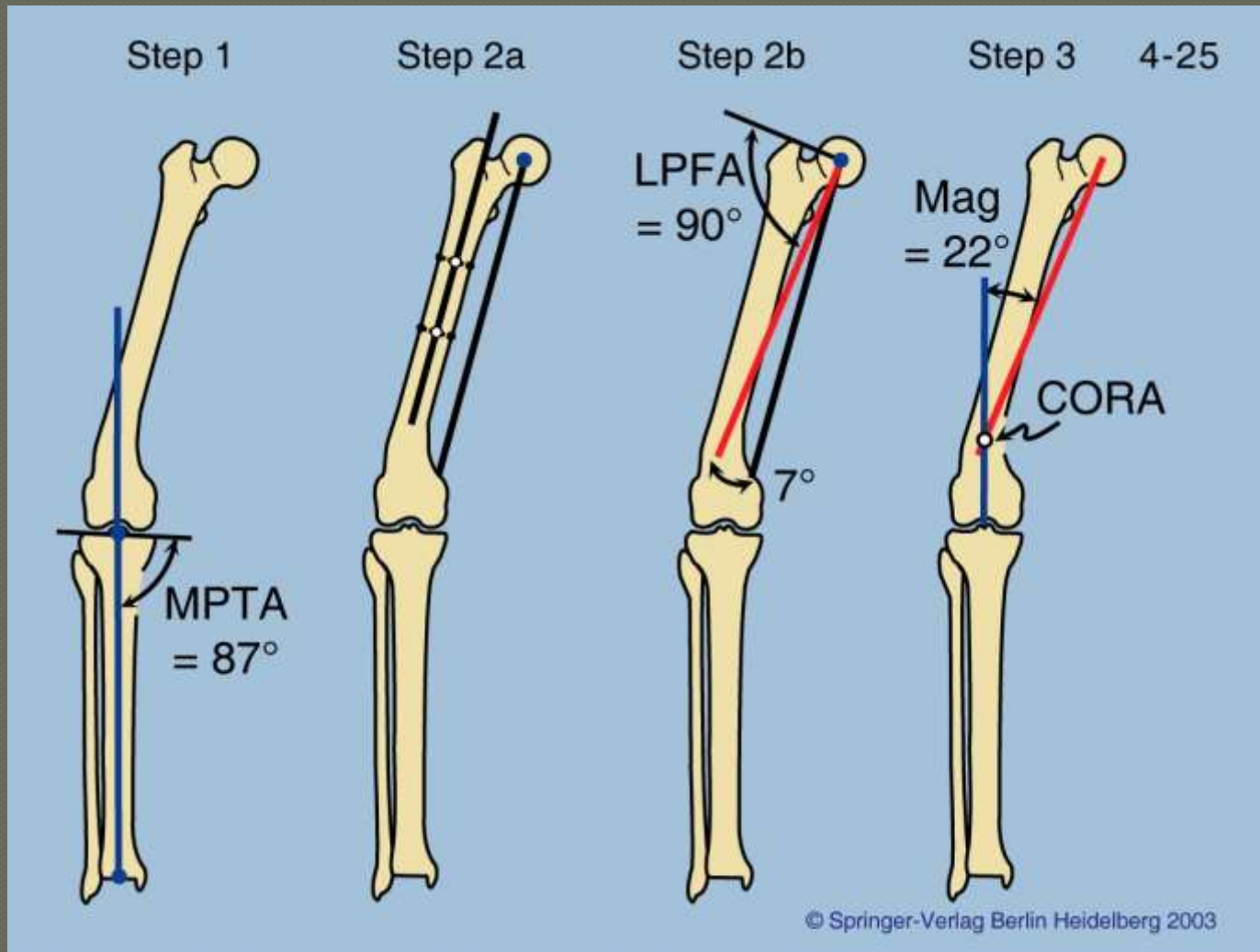




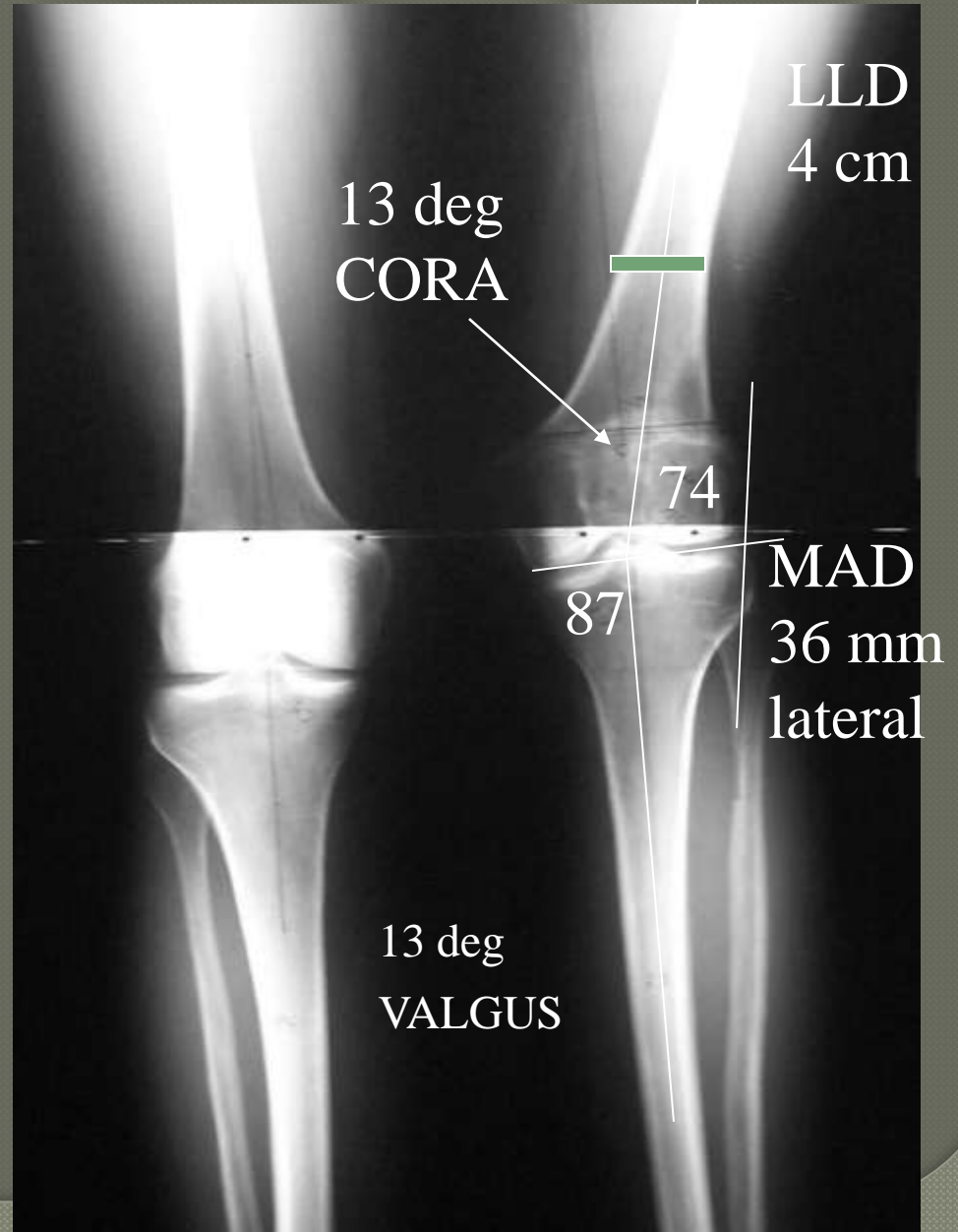
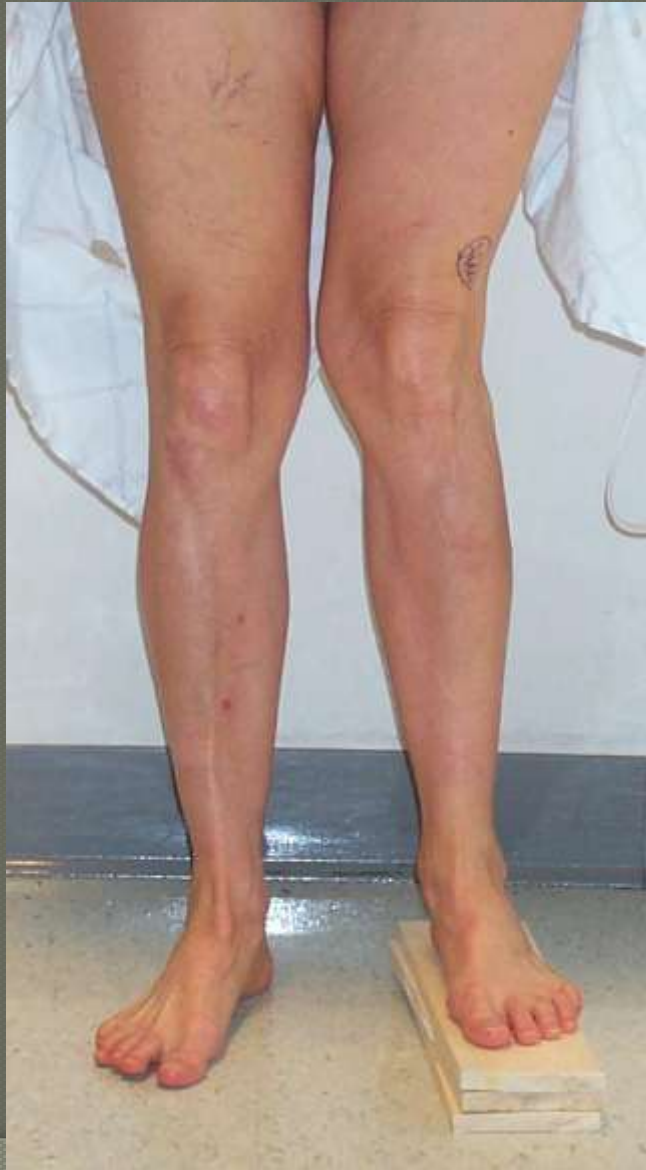


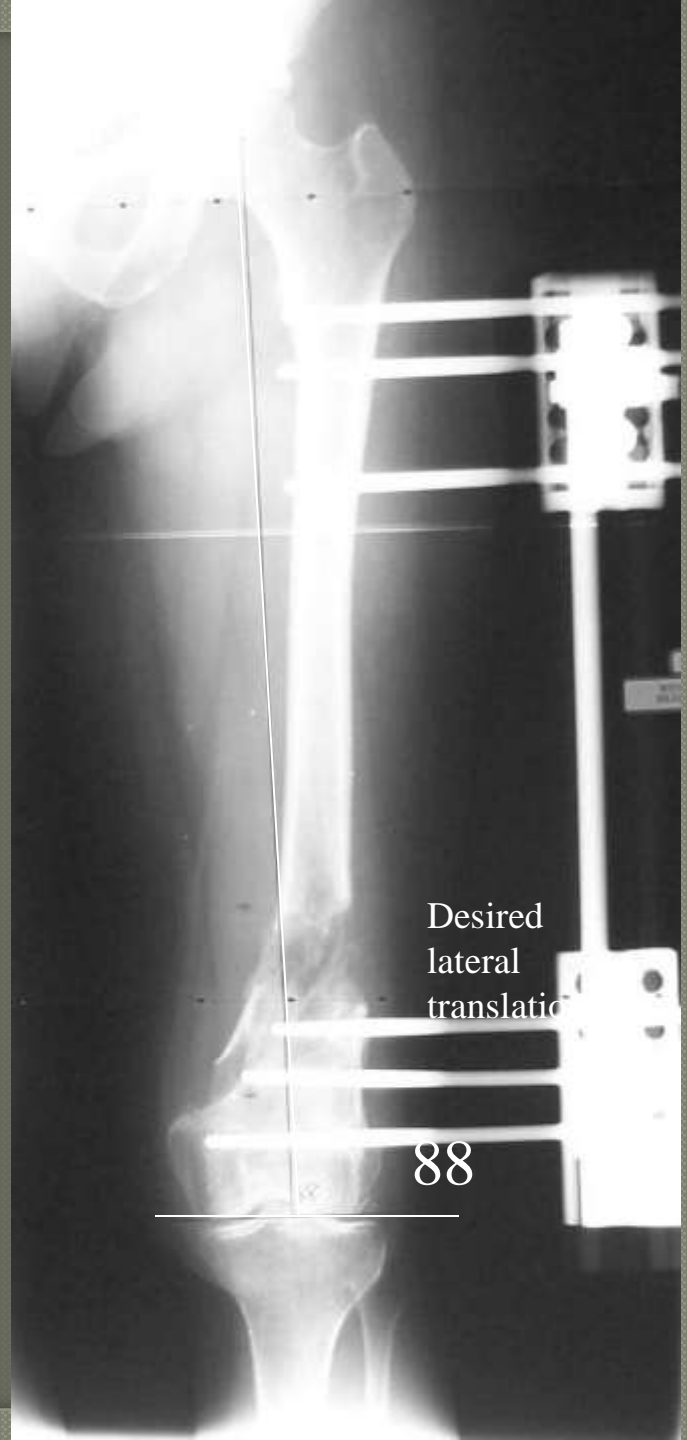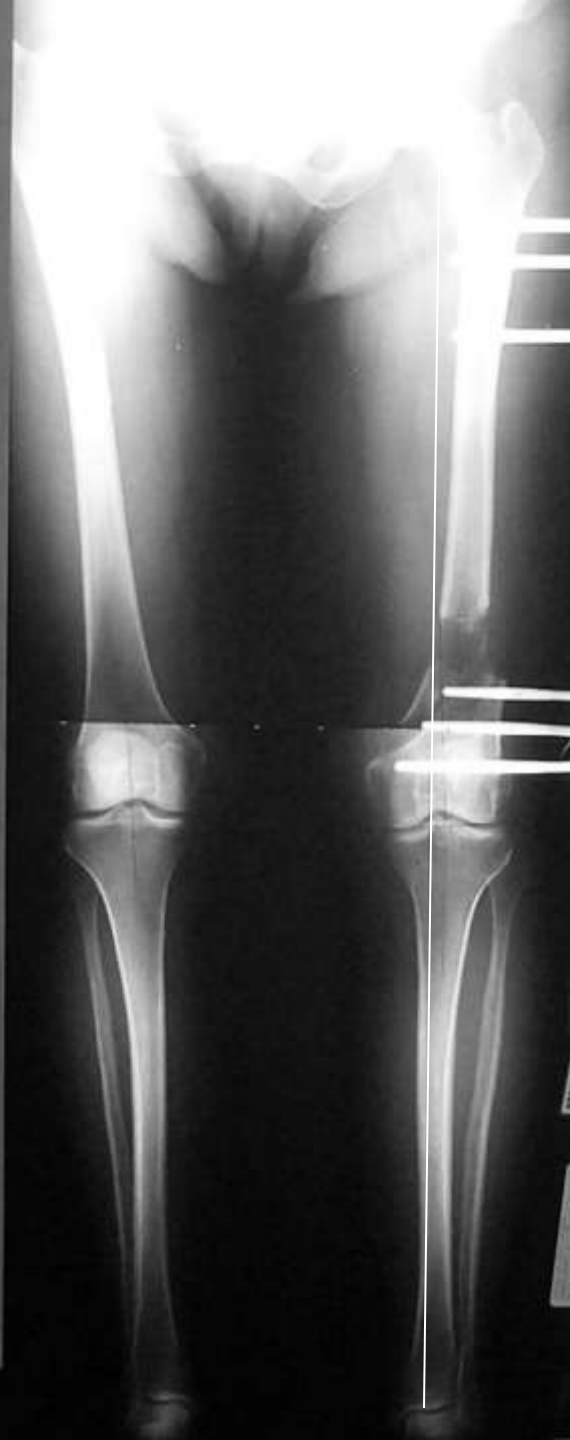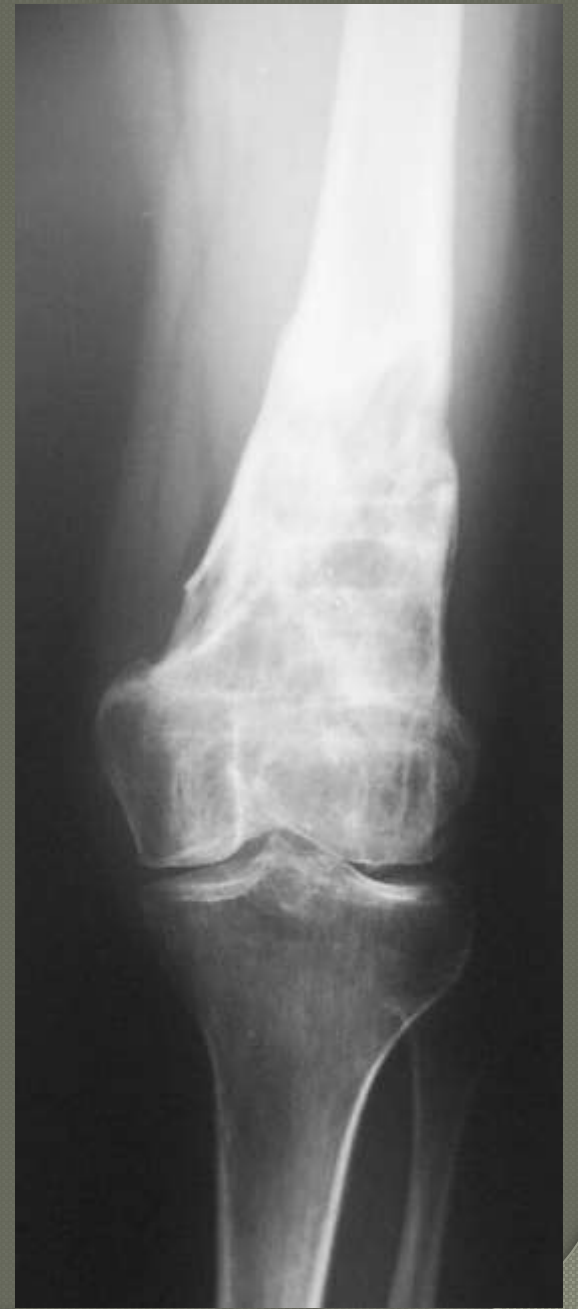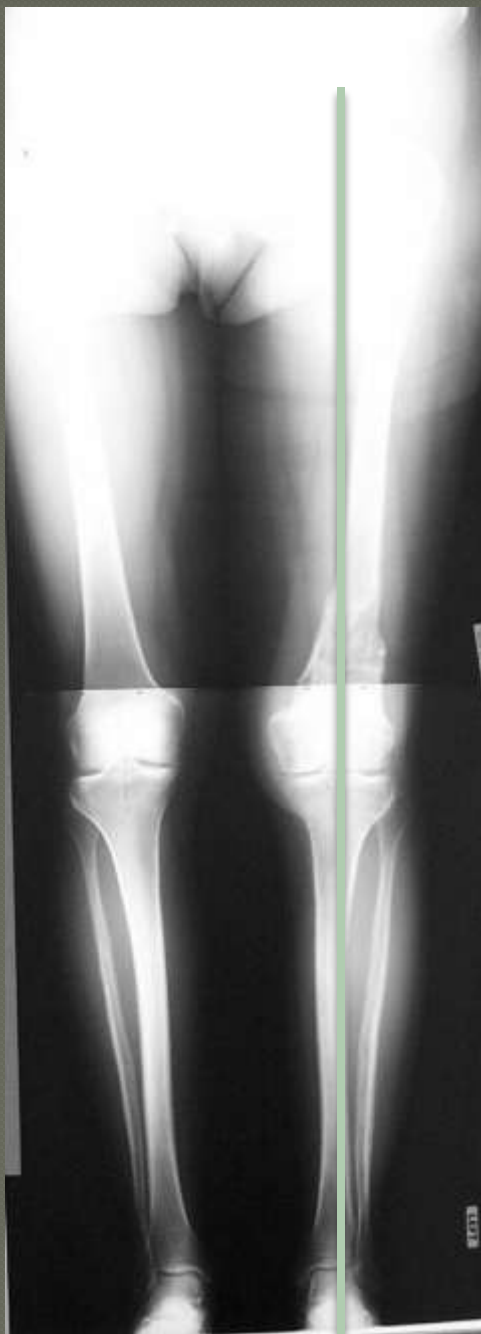Normal tibia and Varus femur



Normal tibia, valgus femur







Limb Lengthening and Then Insertion of an Intramedullary Nail

A Case-matched Comparison

S. Robert Rozbruch MD, Dawn Kleinman BA,
Austin T. Fragomen MD, Svetlana Ilizarov MD

Published online: 18 September 2008

© The Association of Bone and Joint Surgeons 2008


Abstract Distraction osteogenesis is an effective method for lengthening, deformity correction, and treatment of nonunions and bone defects. The classic method uses an external fixator for both distraction and consolidation leading to lengthy times in frames and there is a risk of refracture after frame removal. We suggest a new technique: lengthening and then nailing (LATN) technique in which the frame is used for gradual distraction and then a

Level of Evidence: Level III, therapeutic study. See the Guidelines for Authors for a complete description of levels of evidence.

Introduction

Distraction osteogenesis by the Ilizarov method is a widely


LATN

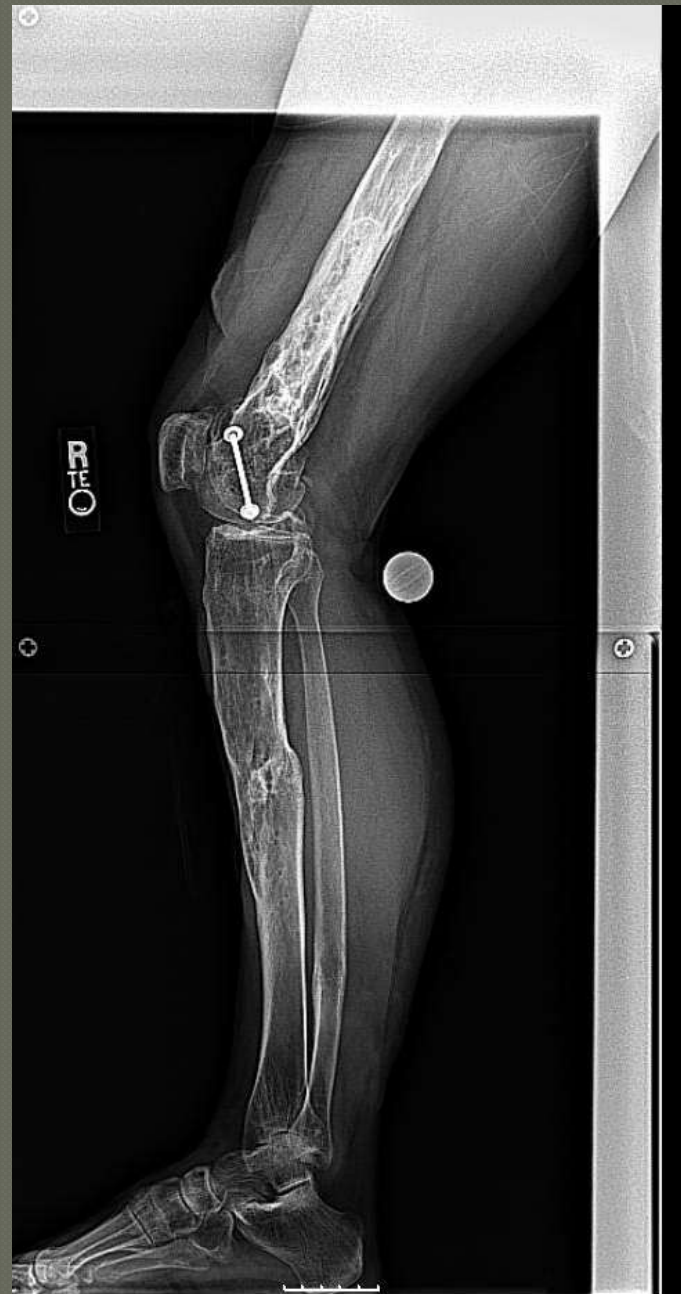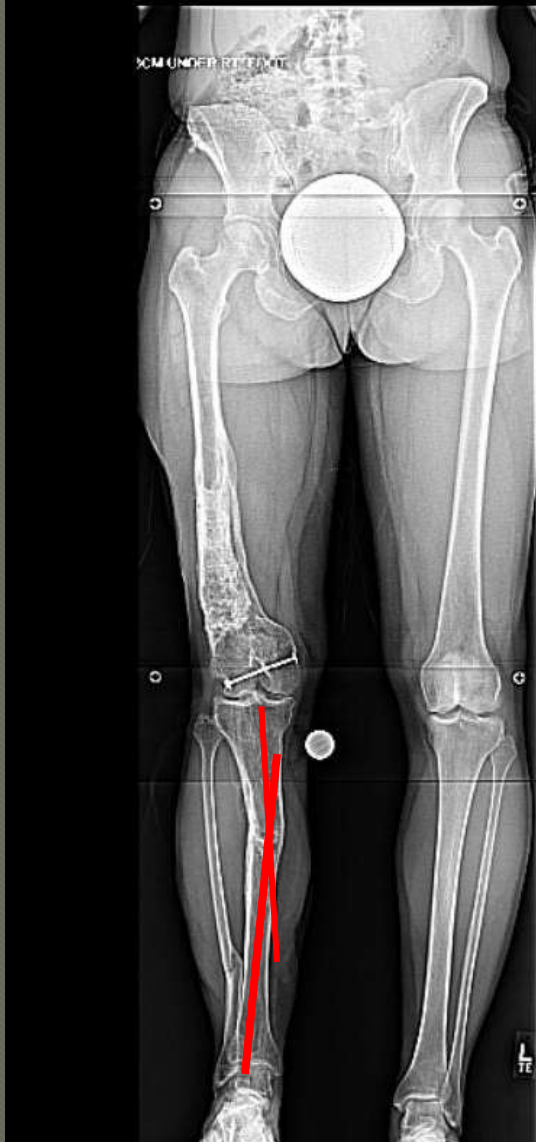



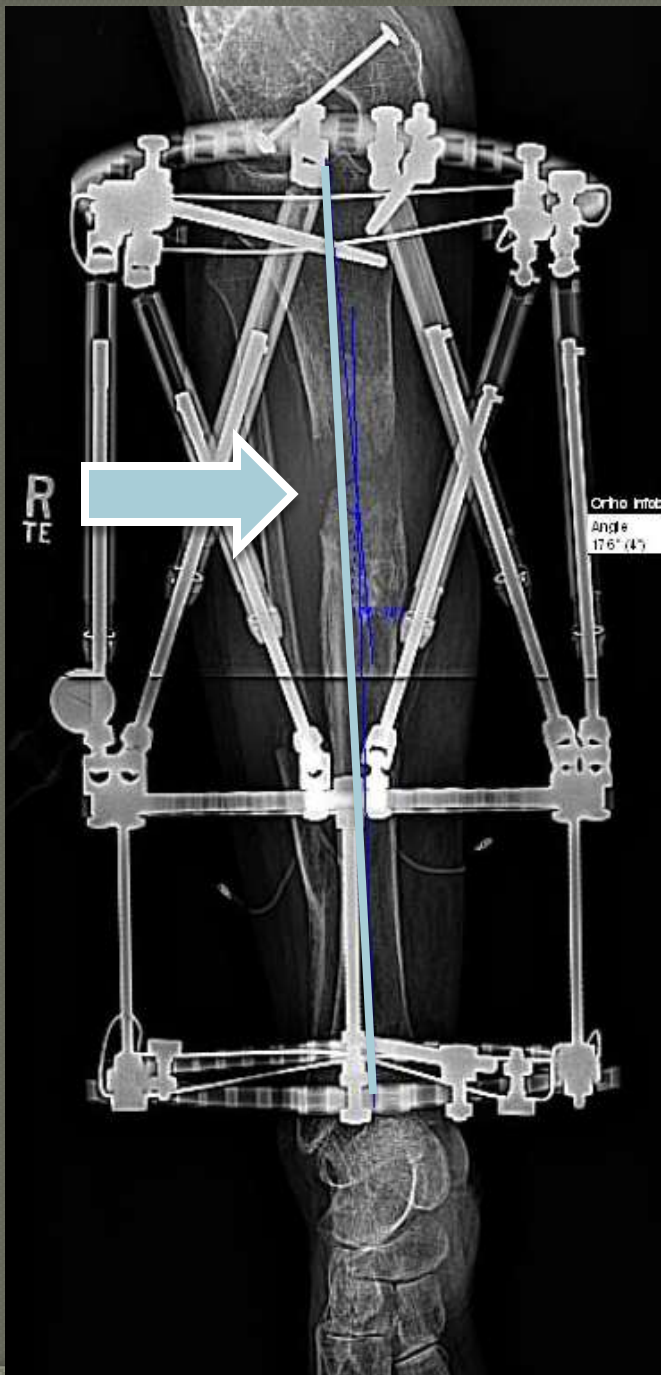


**EBI, Biomet Nail
Custom LATN
Targeting Device**

No contact between IM nail
And External Fixation


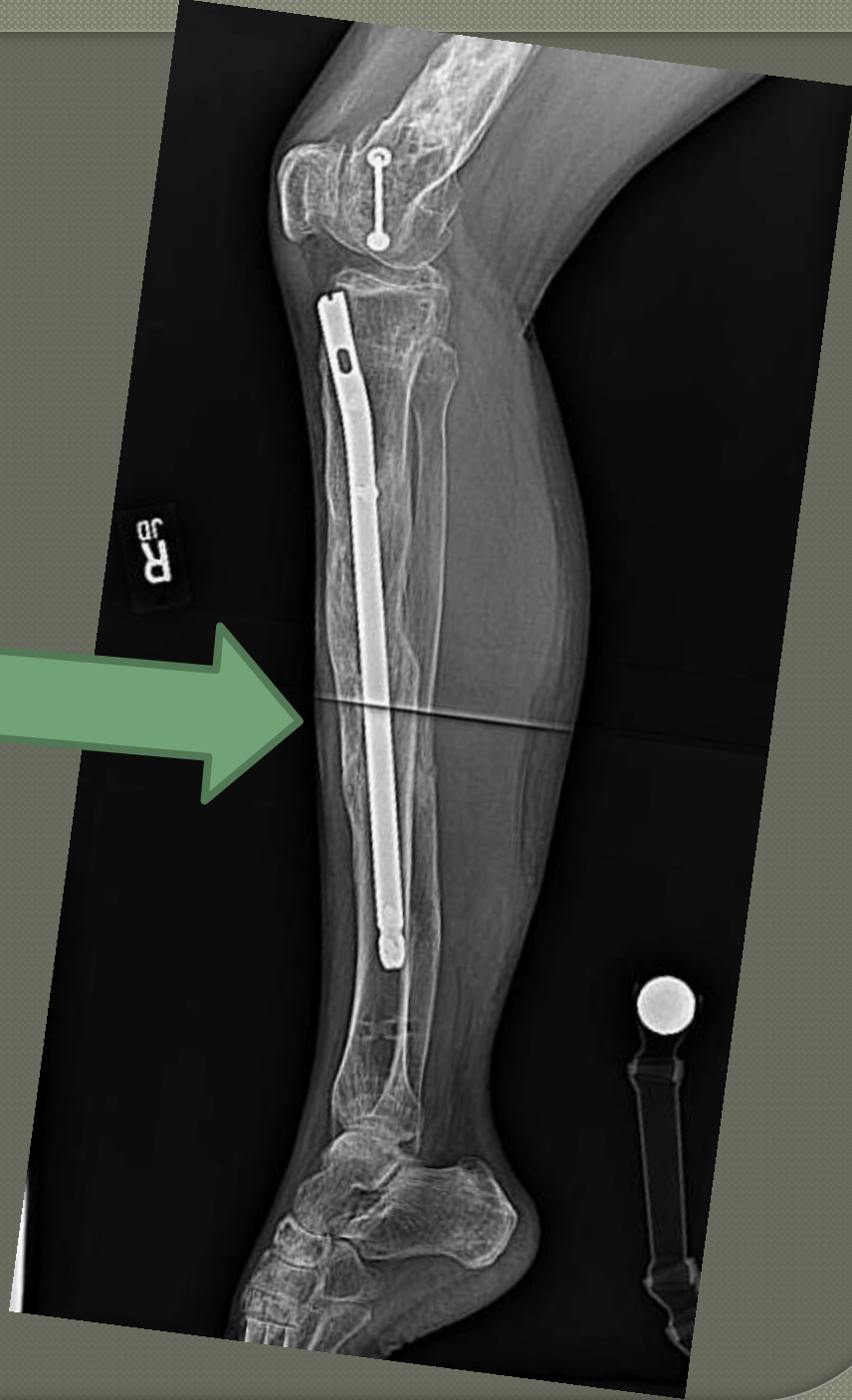
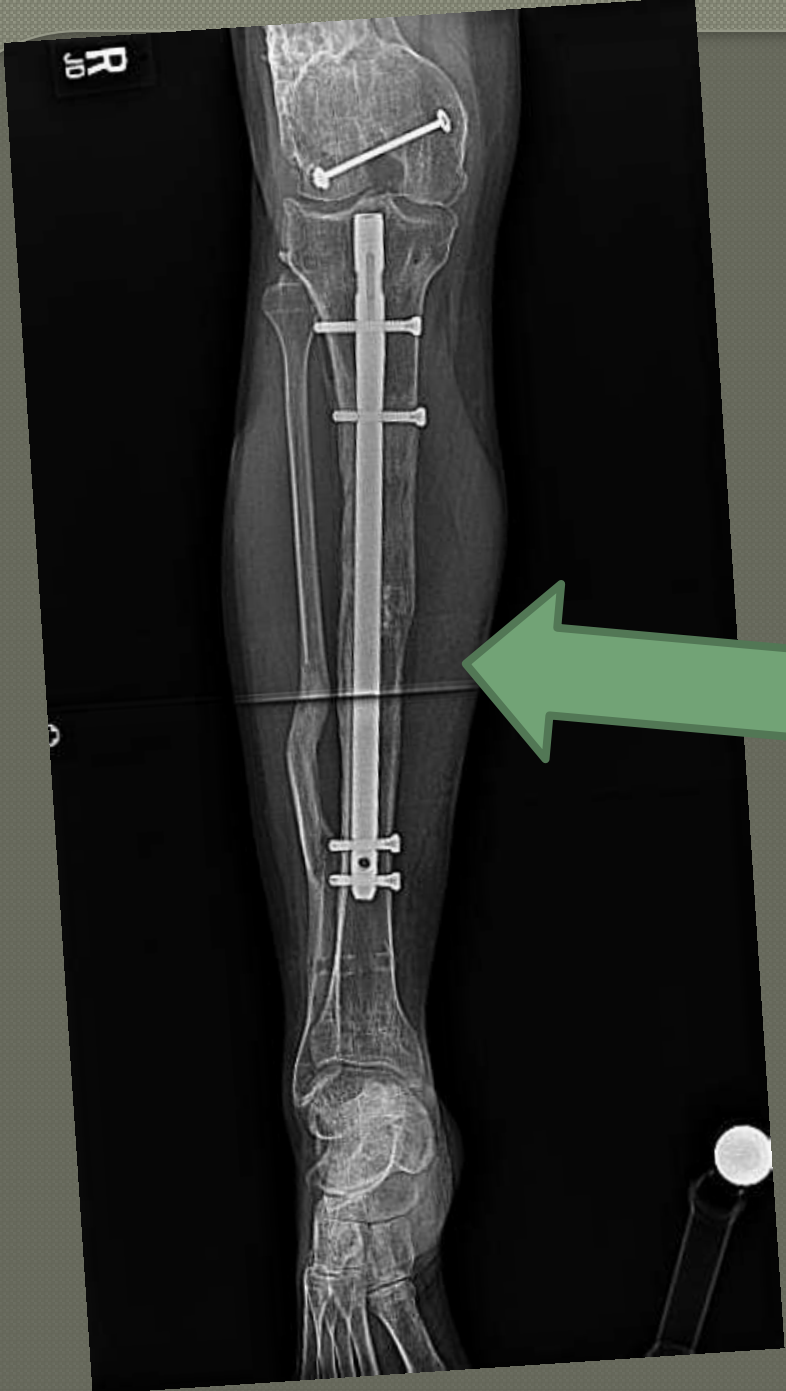






No more old ugly shoes

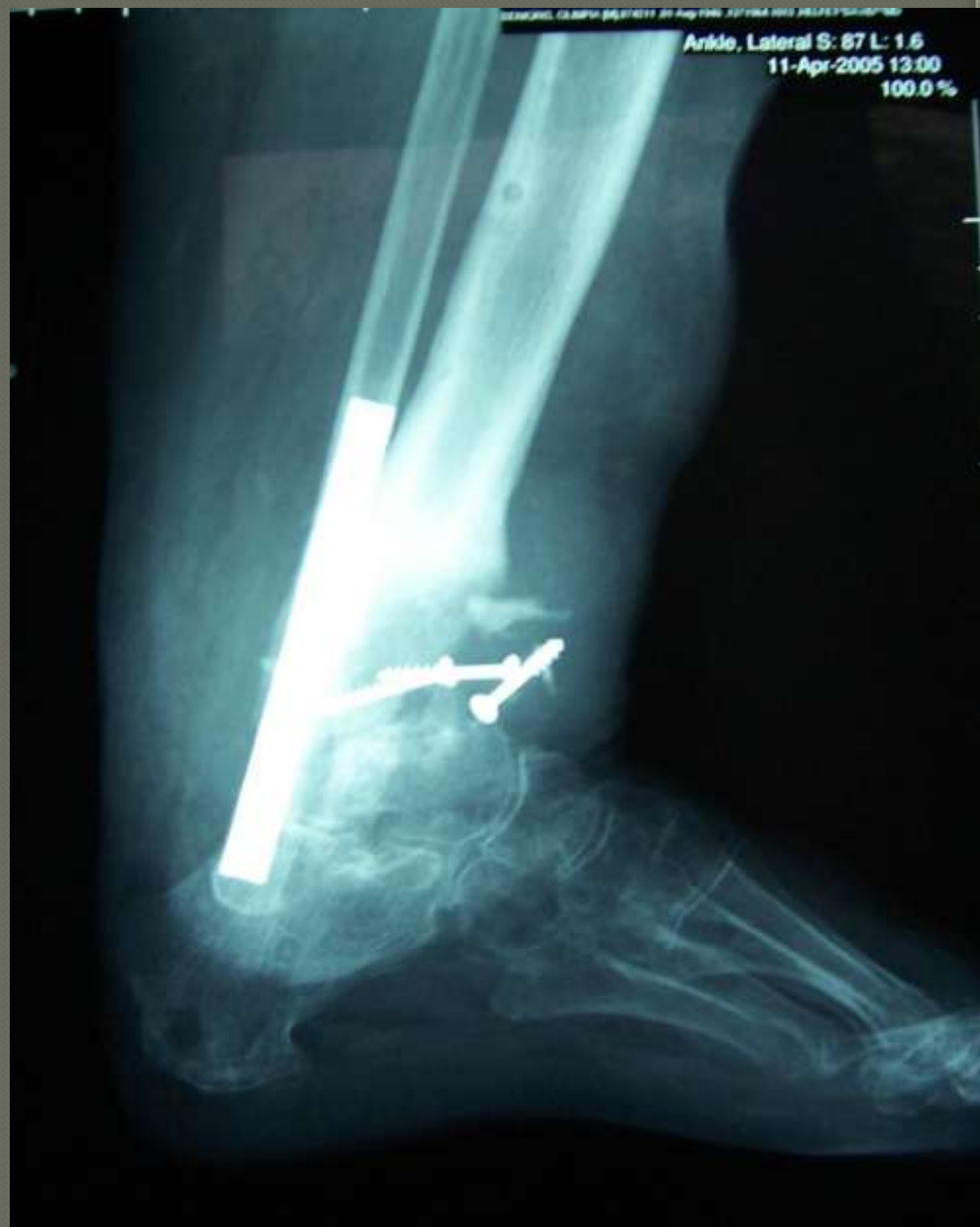
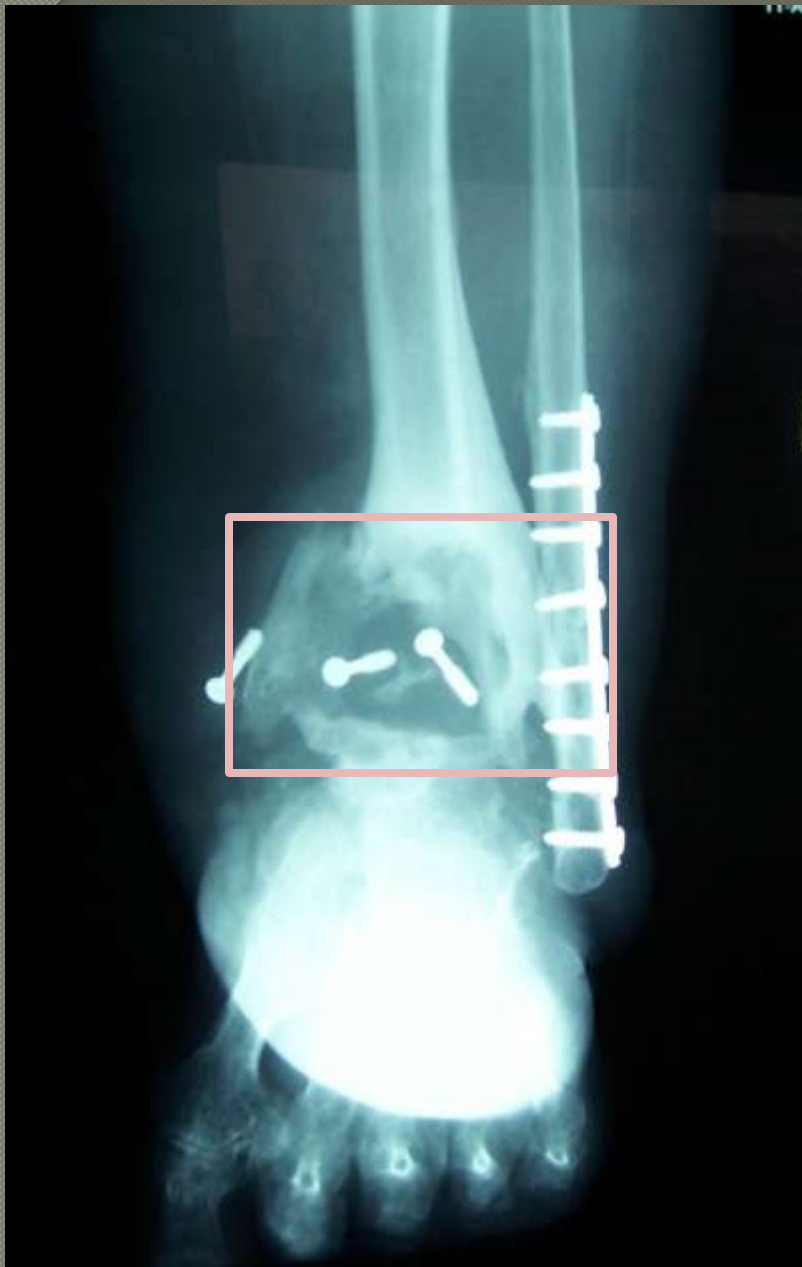




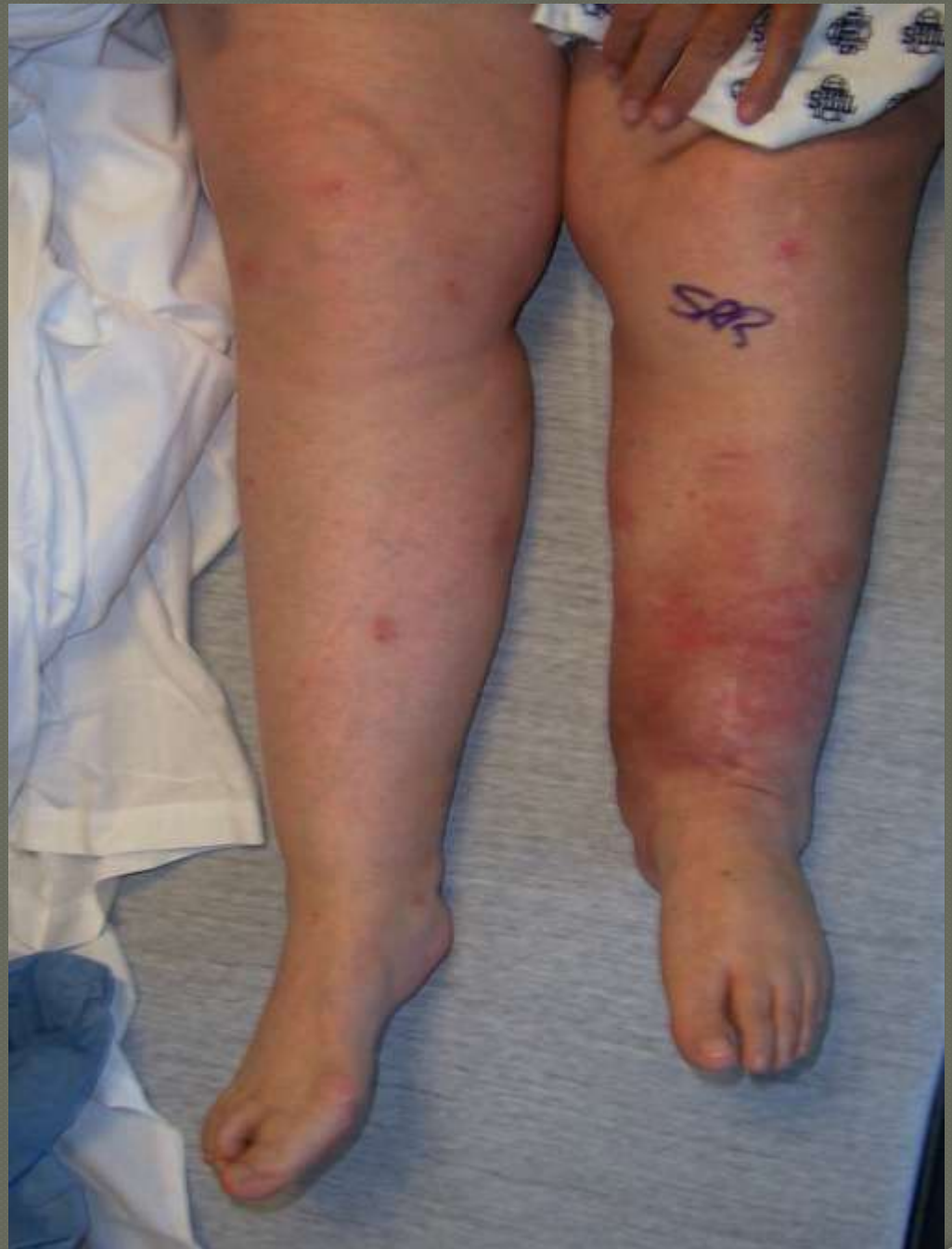
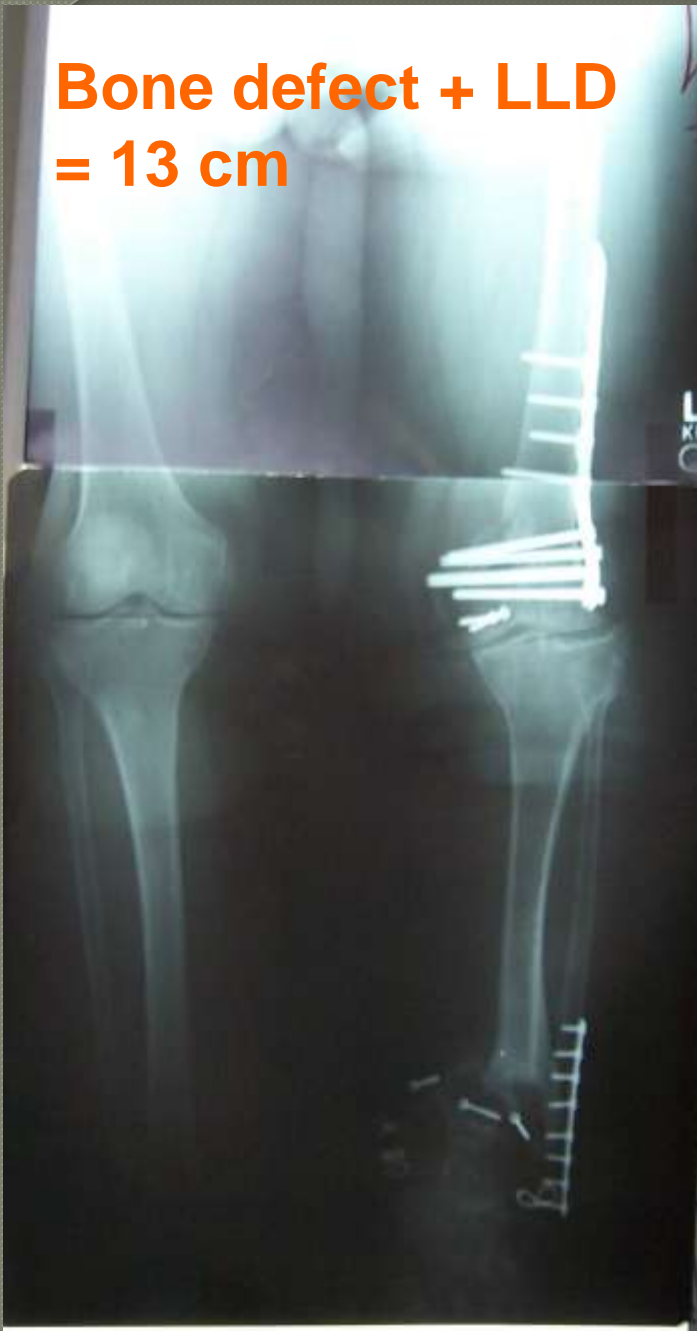
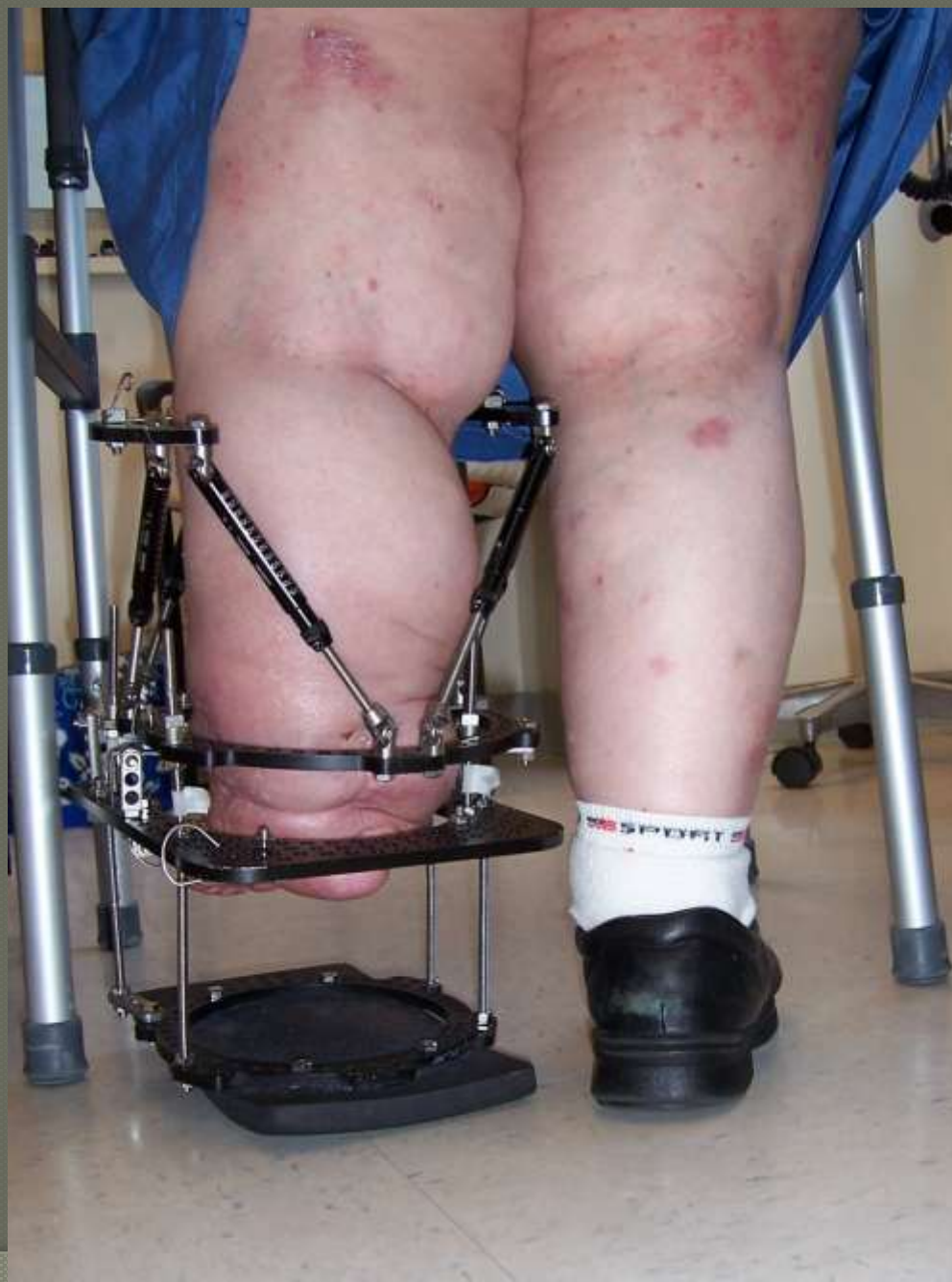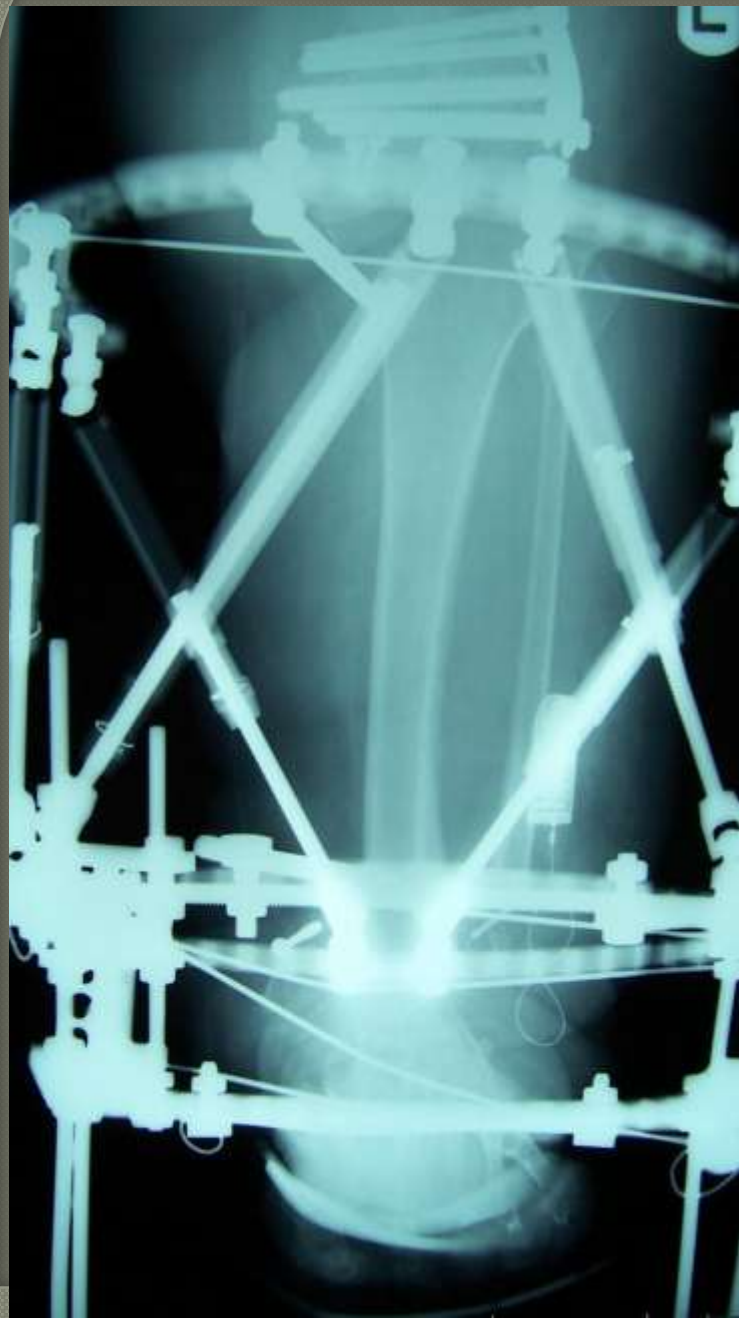
60 y/o woman, failed pilon fx, osteomyelitis, bone defect

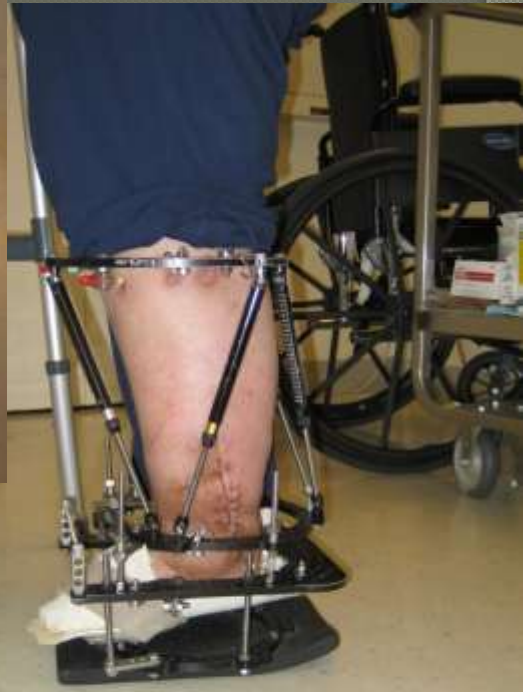
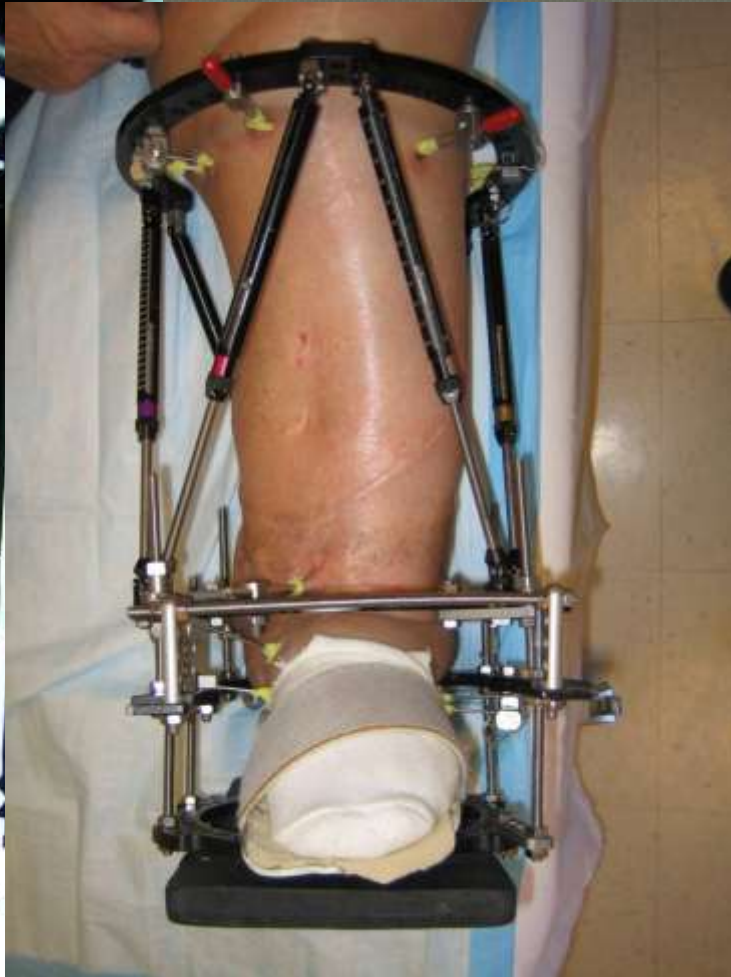

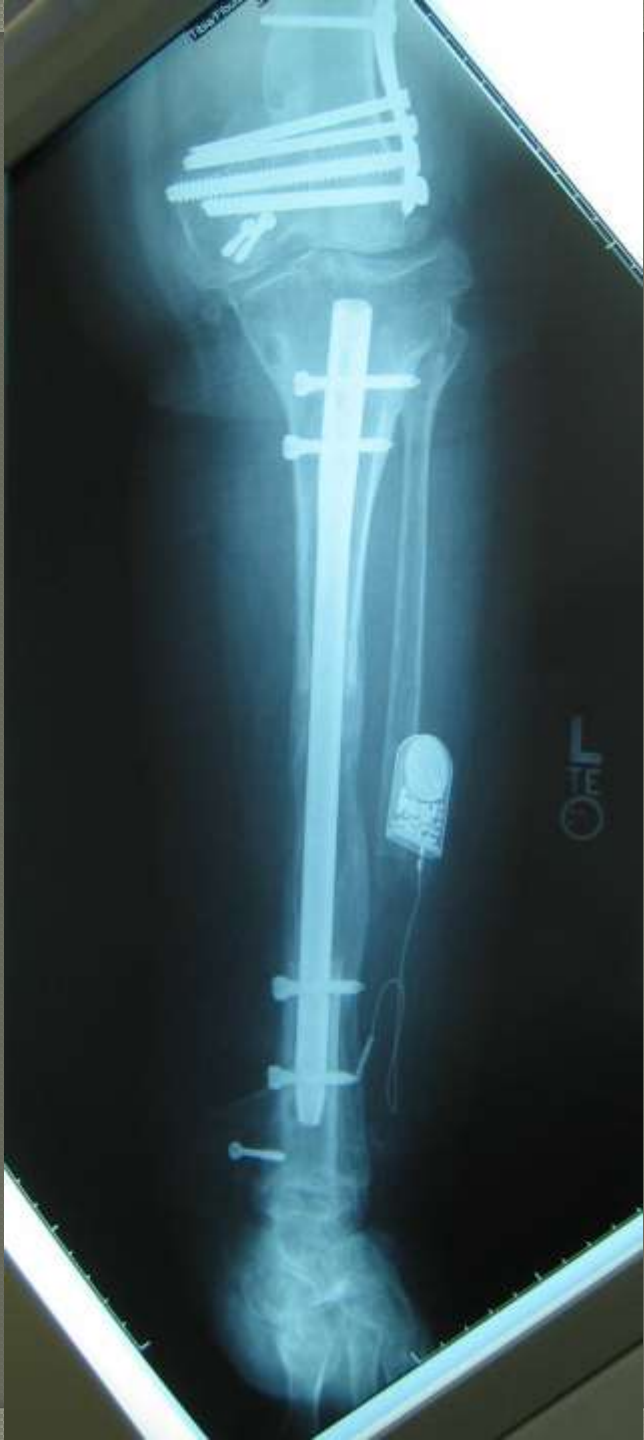**Bone defect + LLD
= 13 cm**



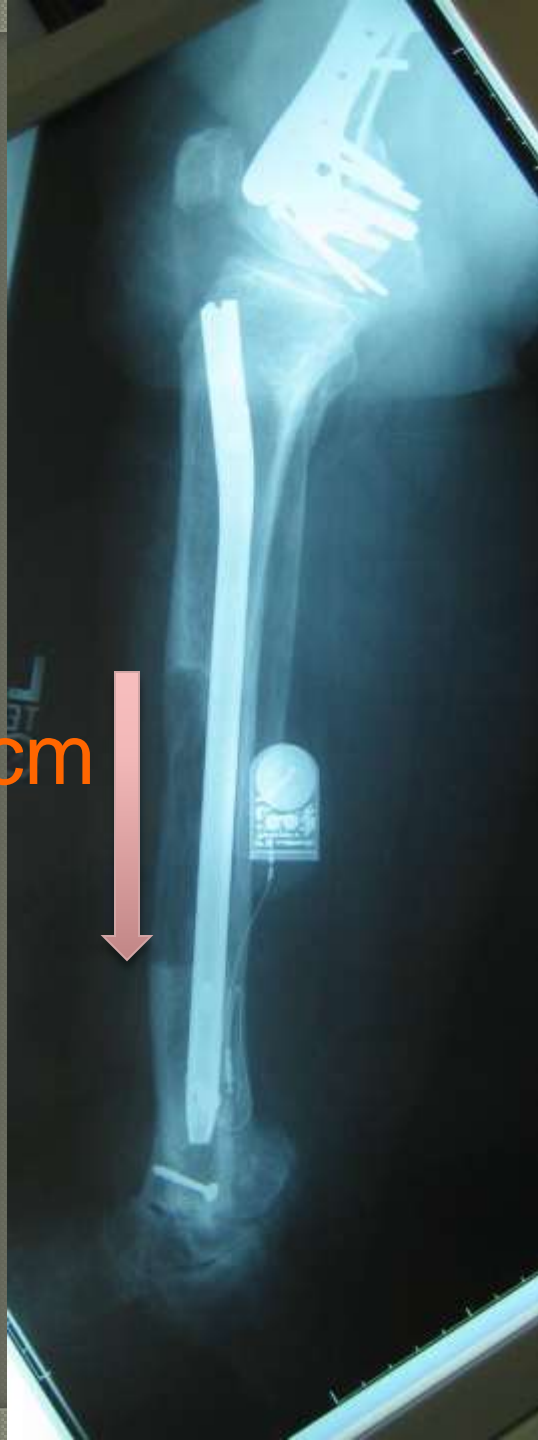Ankle fusion, gradual shortening, IV antibiotics, planned staged LATN



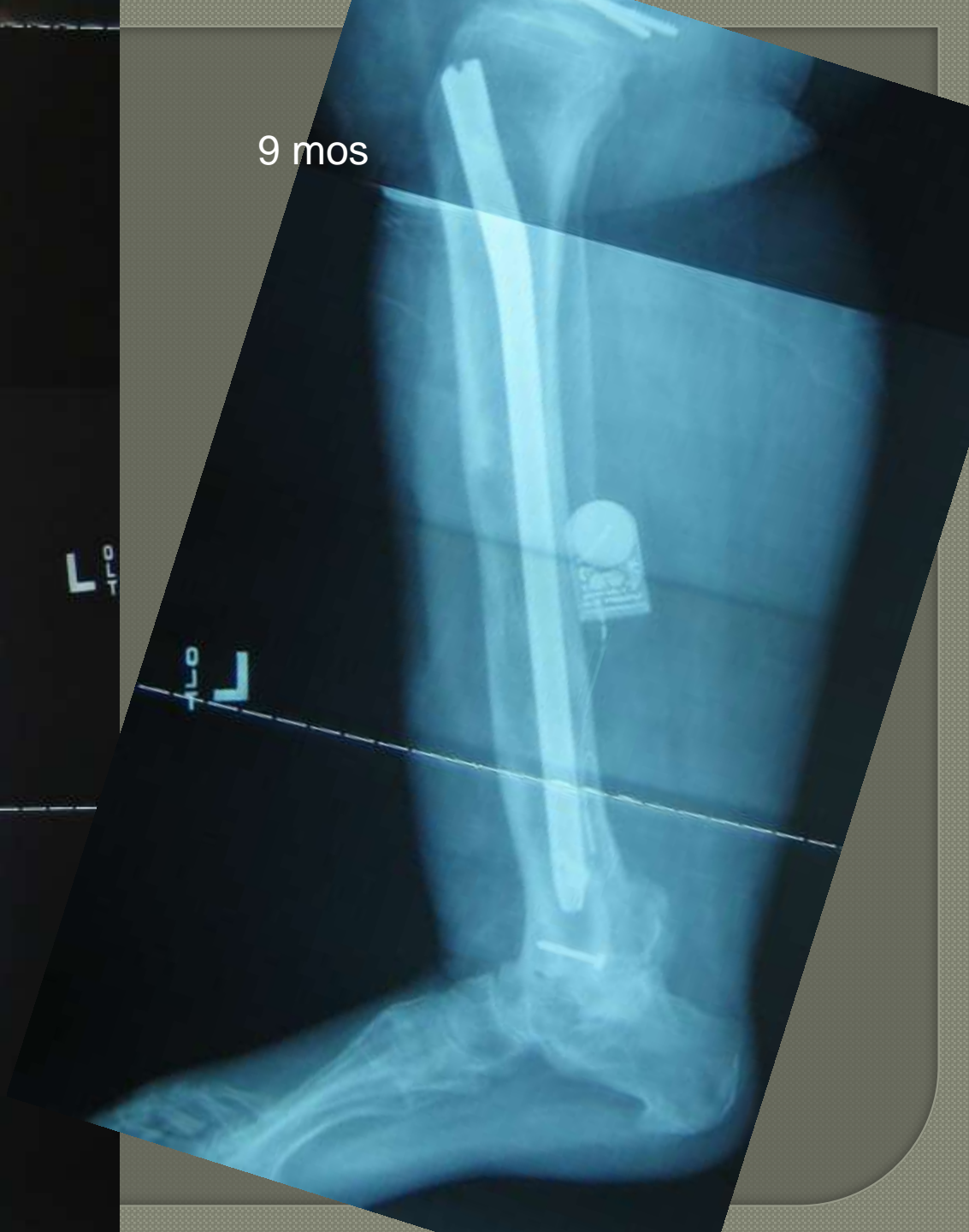
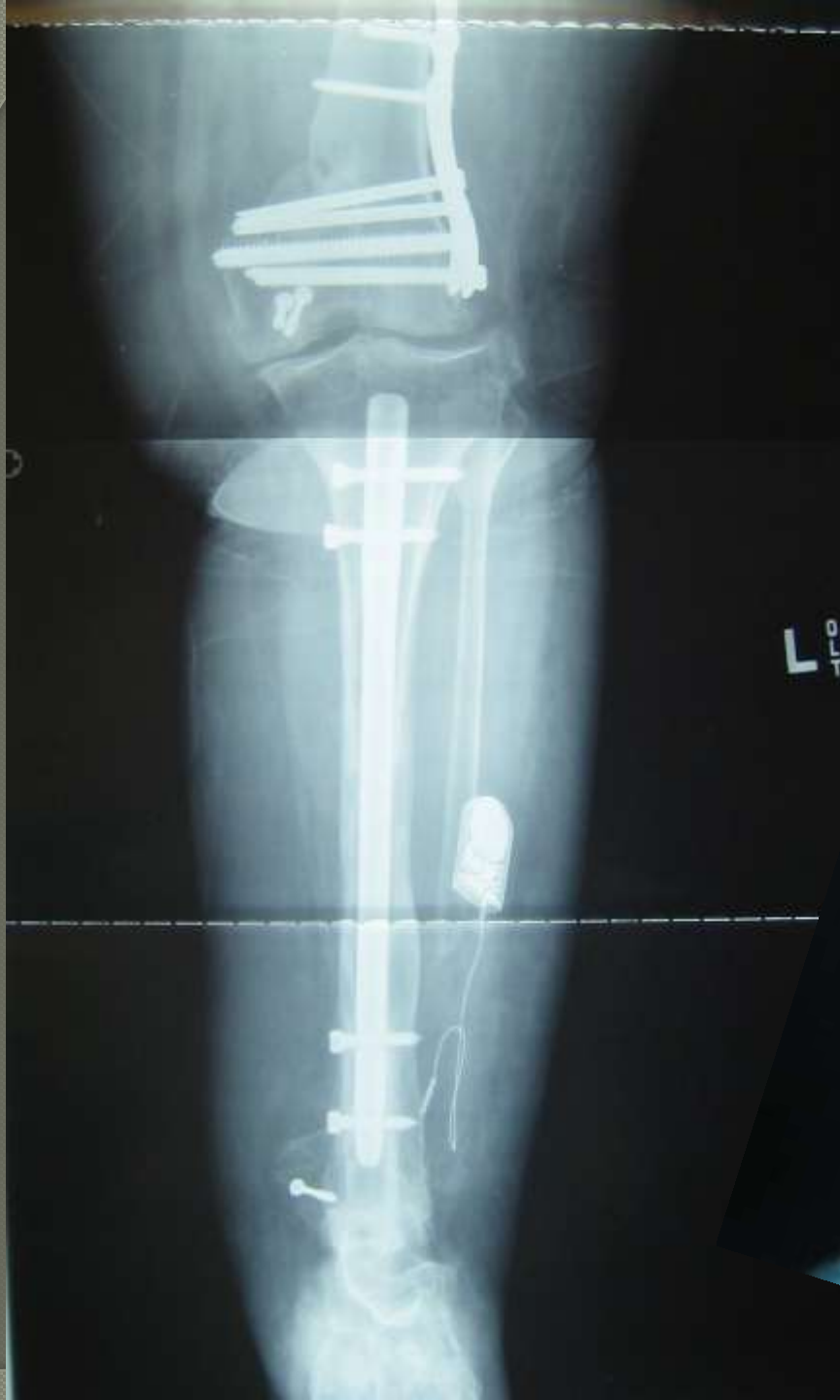


10 cm

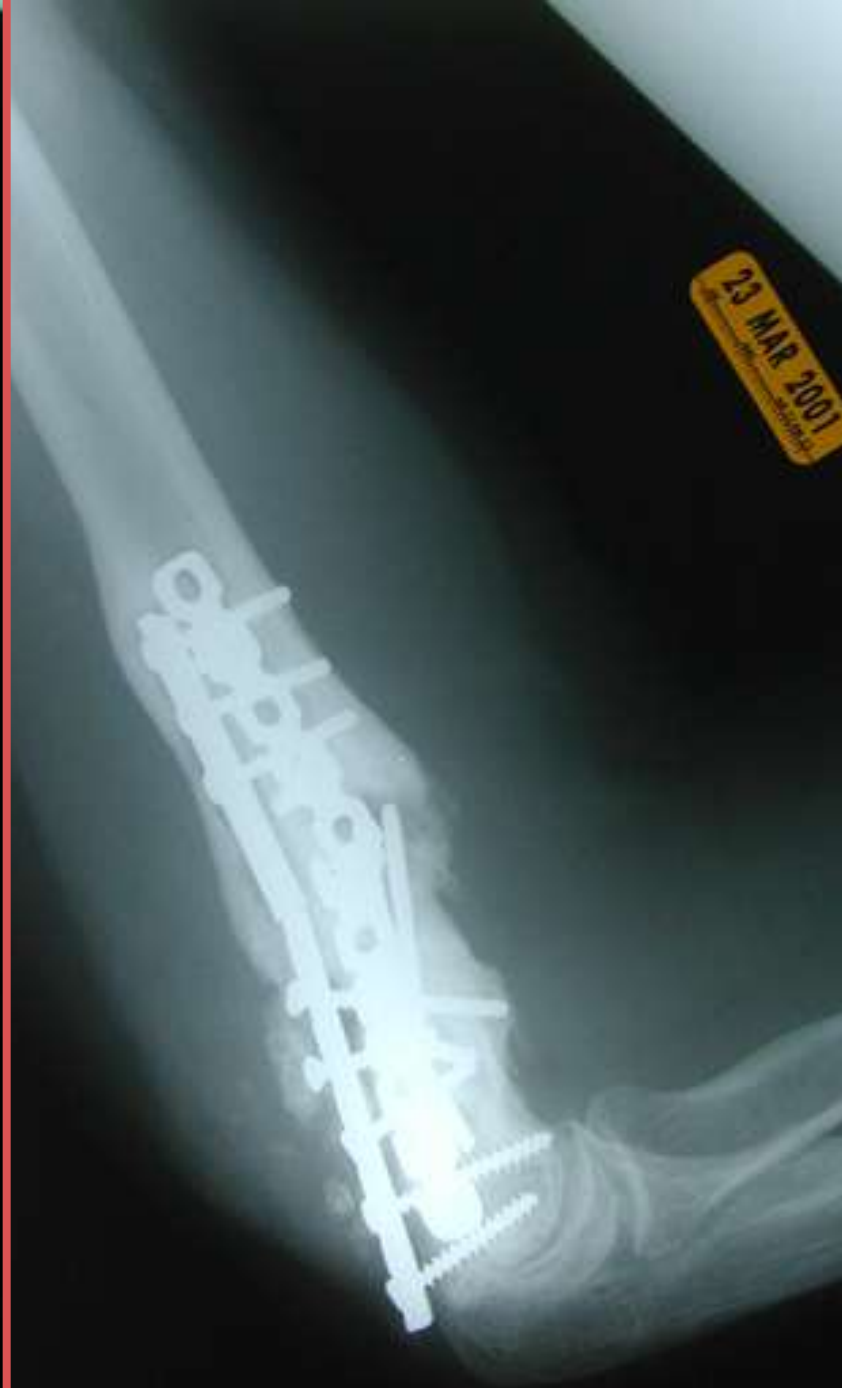
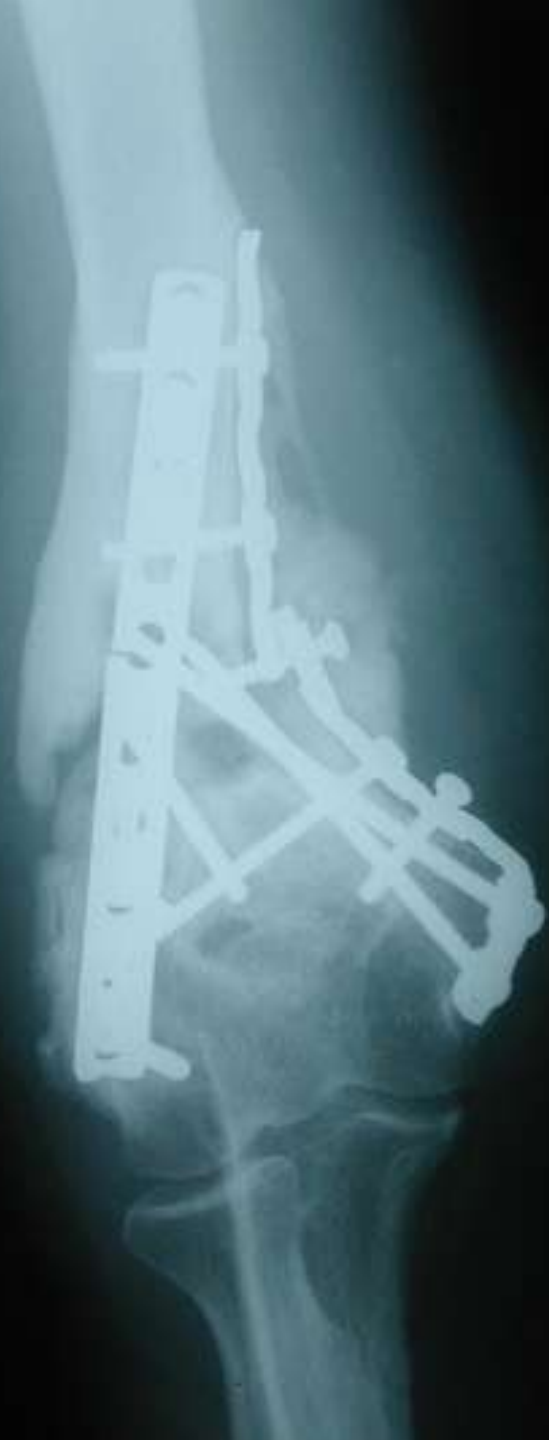




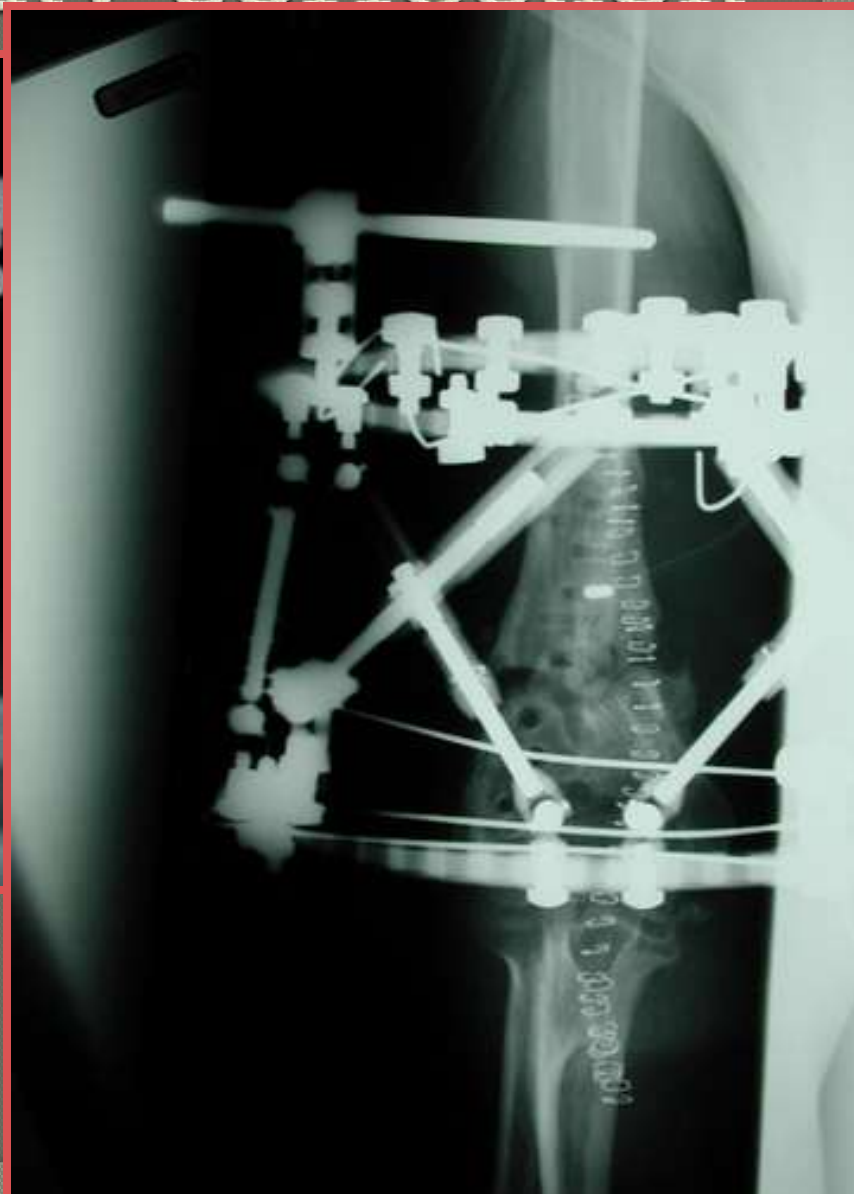


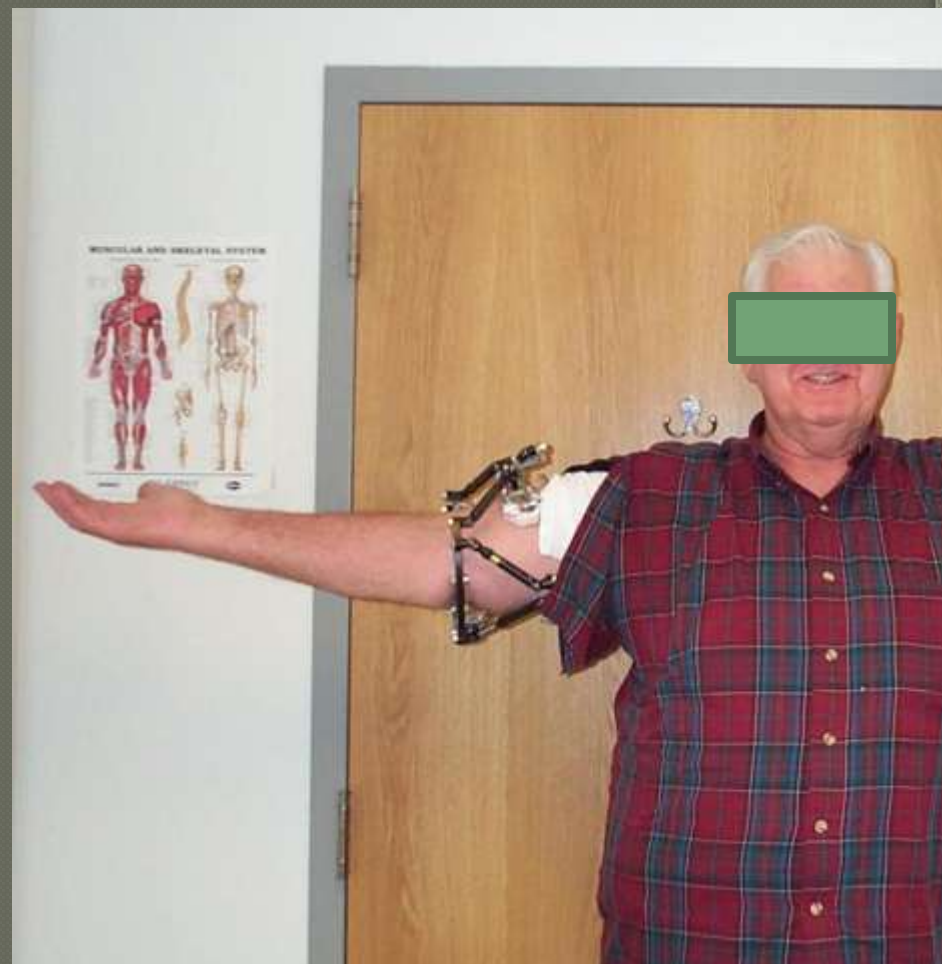PK PK

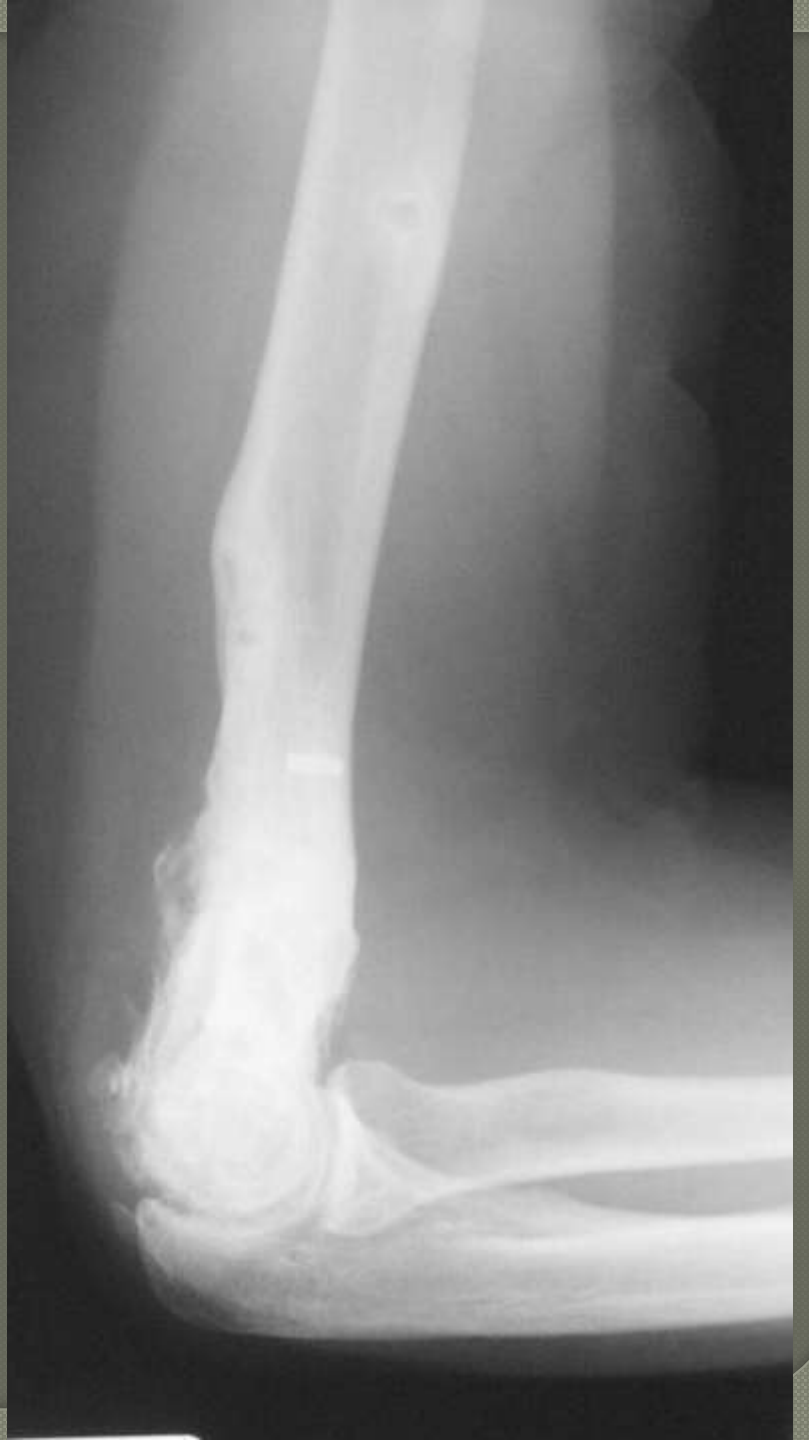
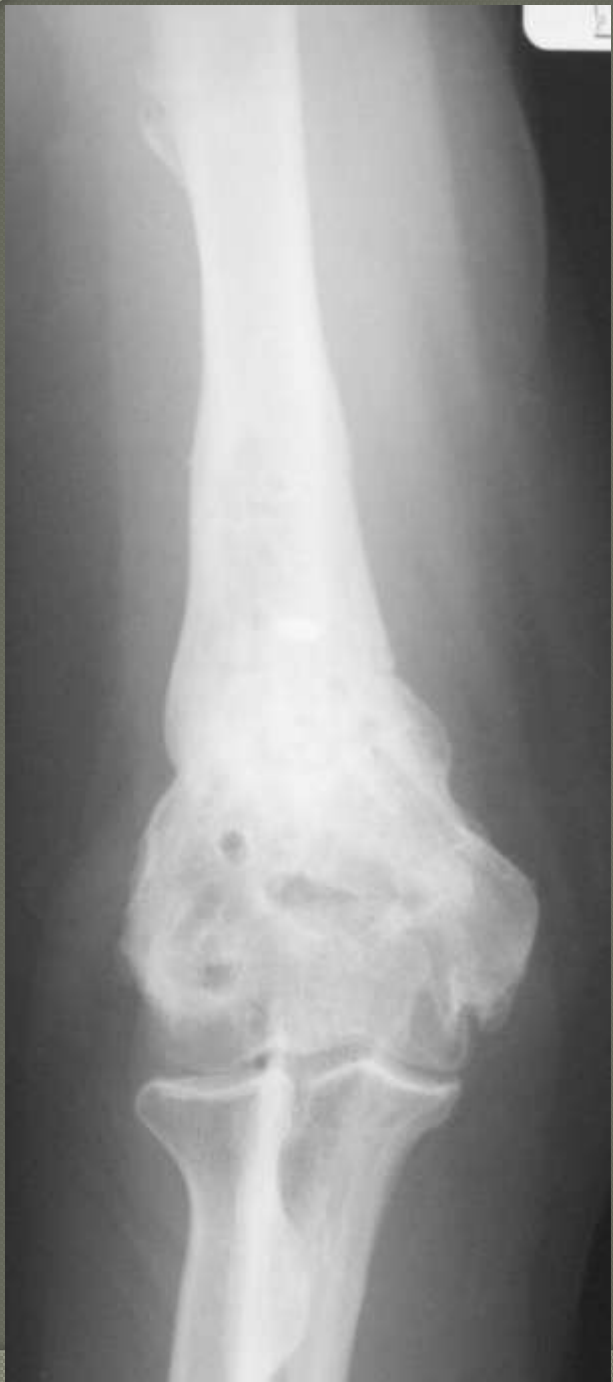
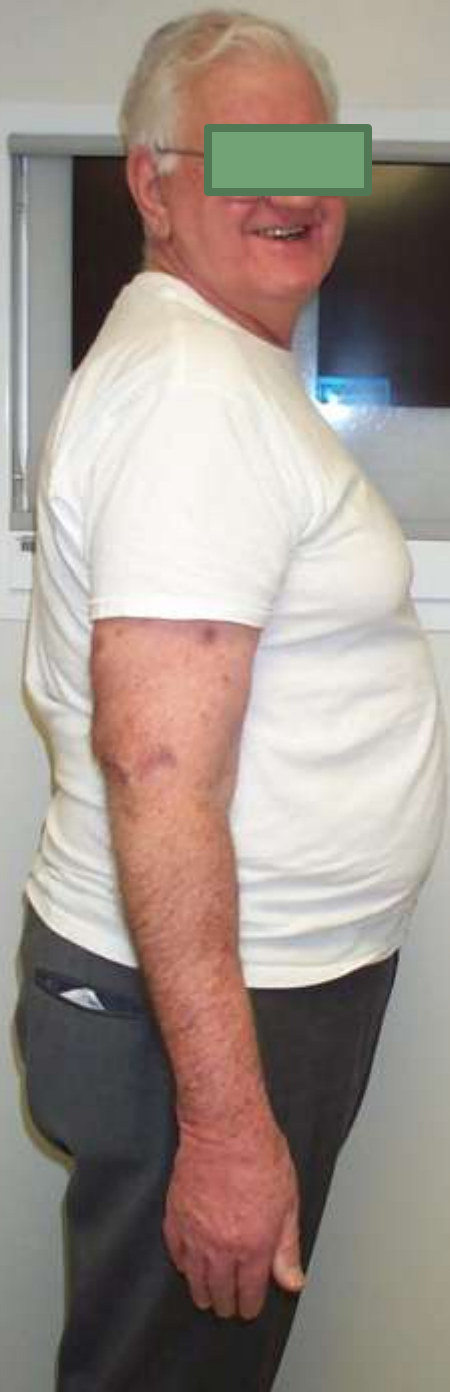Residual deformity correction



4 months







8 m



Limb Salvage Reconstruction of the Ankle with Fusion and Simultaneous Tibial Lengthening Using the Ilizarov/Taylor Spatial Frame

Nazzar Tellisi, MD • Austin T. Fragomen, MD • Svetlana Ilizarov, MD • S. Robert Rozbruch, MD

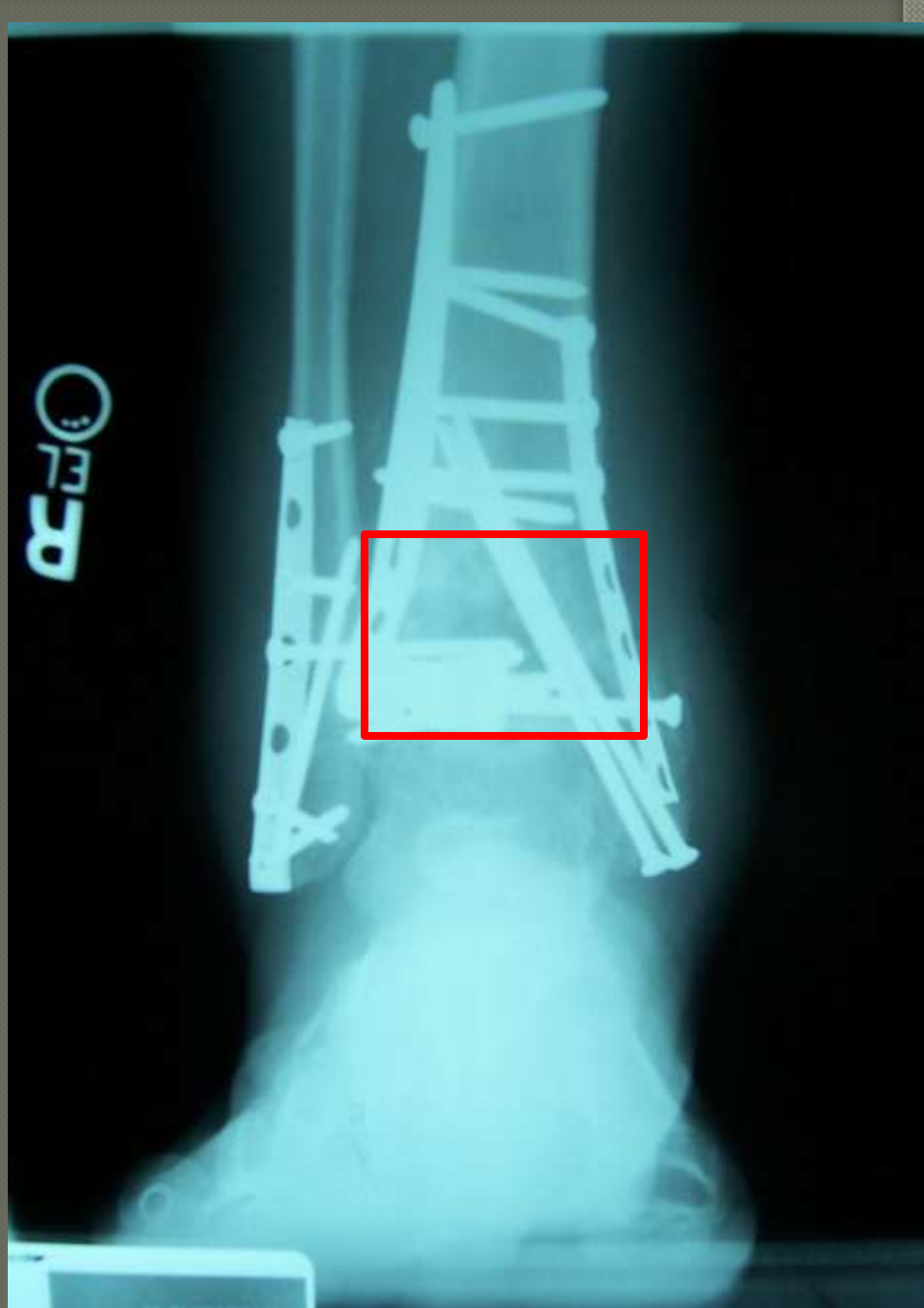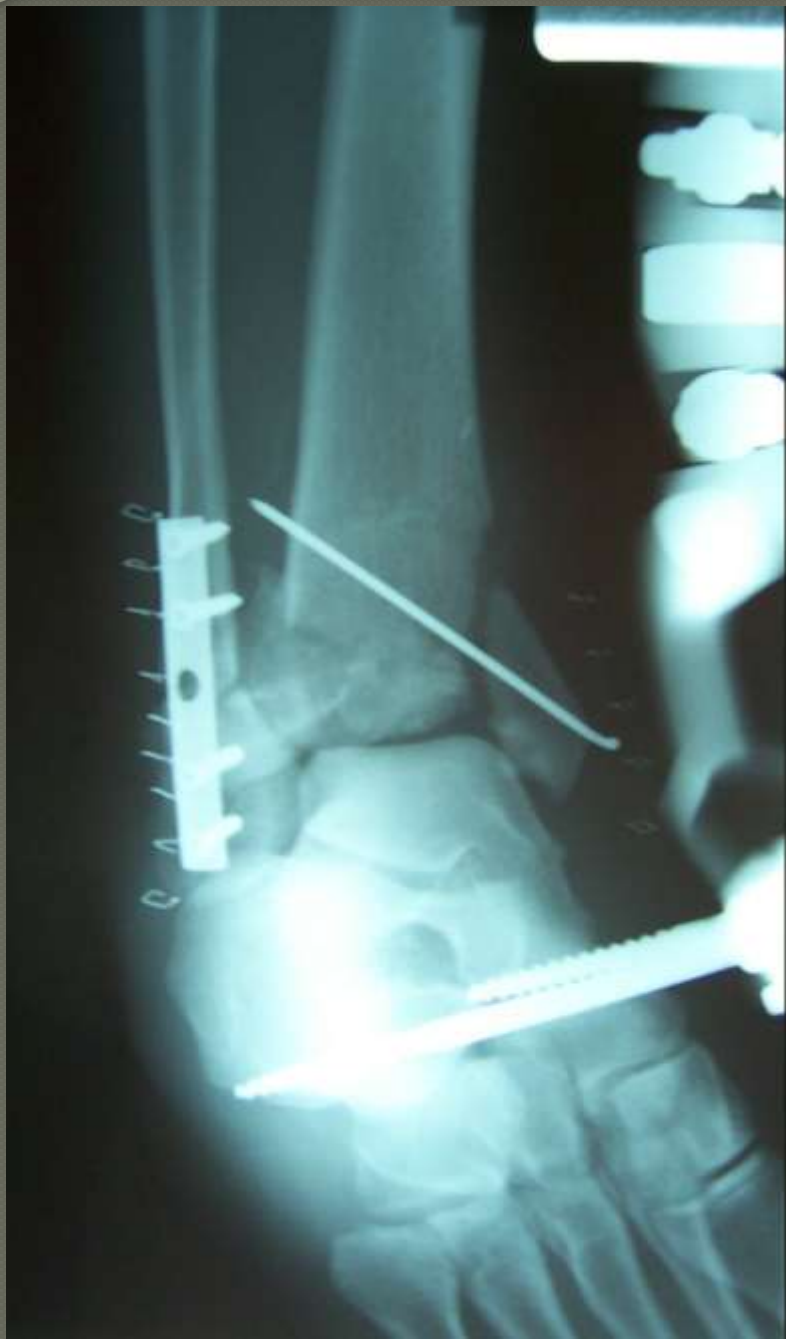Received: 19 November 2007/Accepted: 21 November 2007/Published online: 8 December 2007
© Hospital for Special Surgery 2007

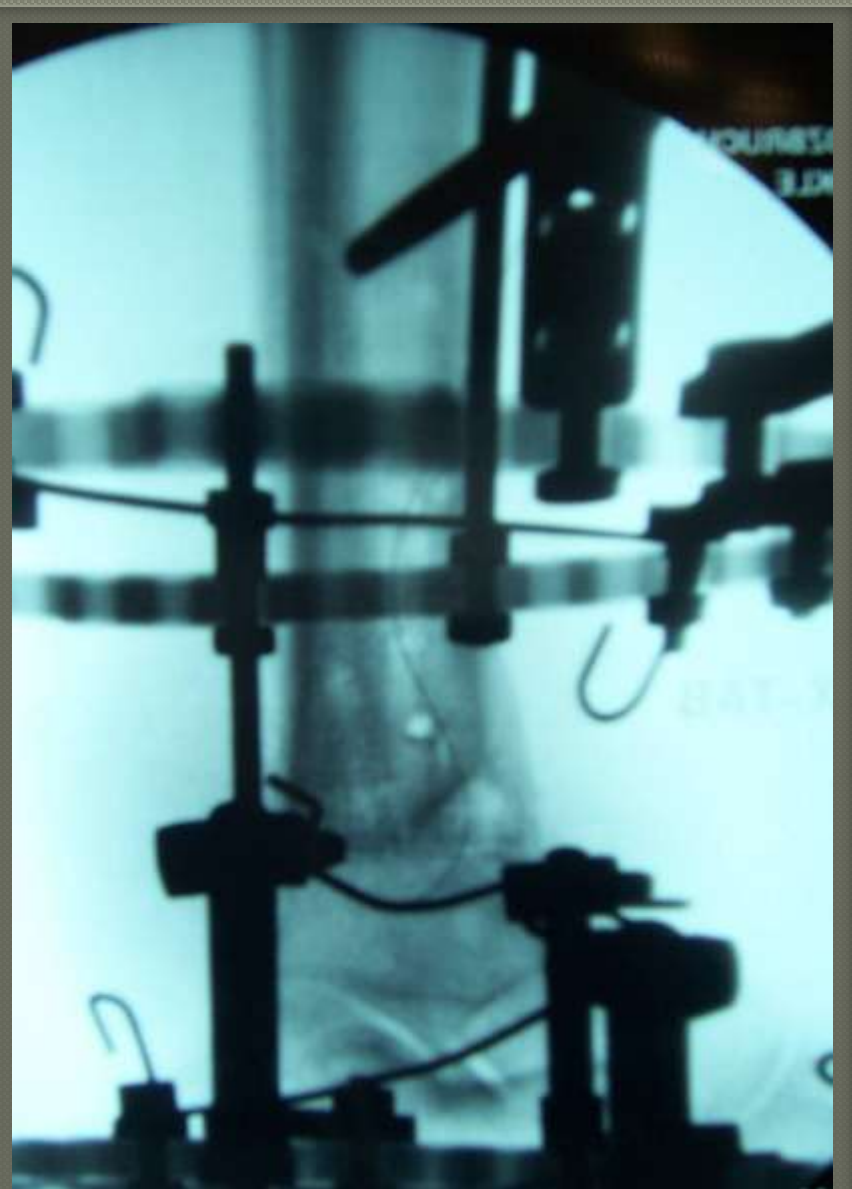
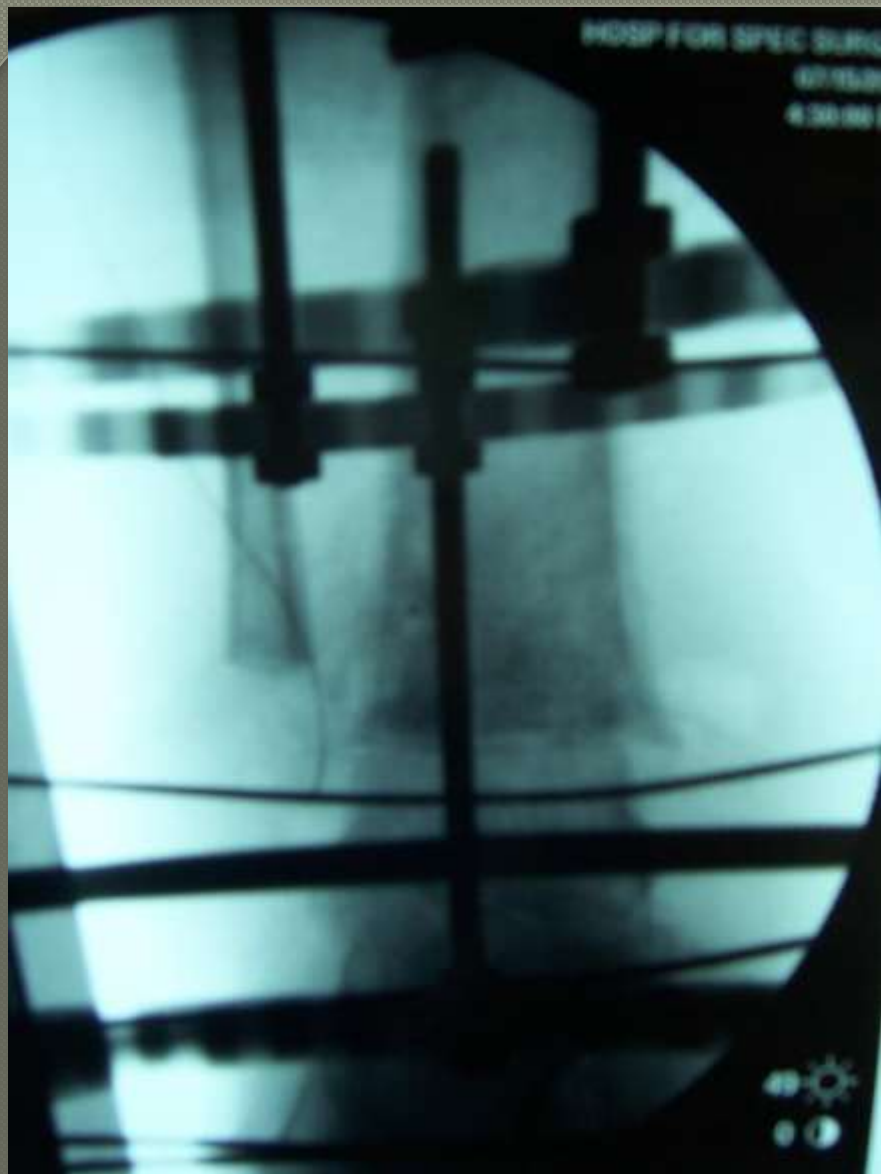
Key words ankle fusion · lengthening · Taylor spatial frame · TSF · limb salvage · ankle arthodesis

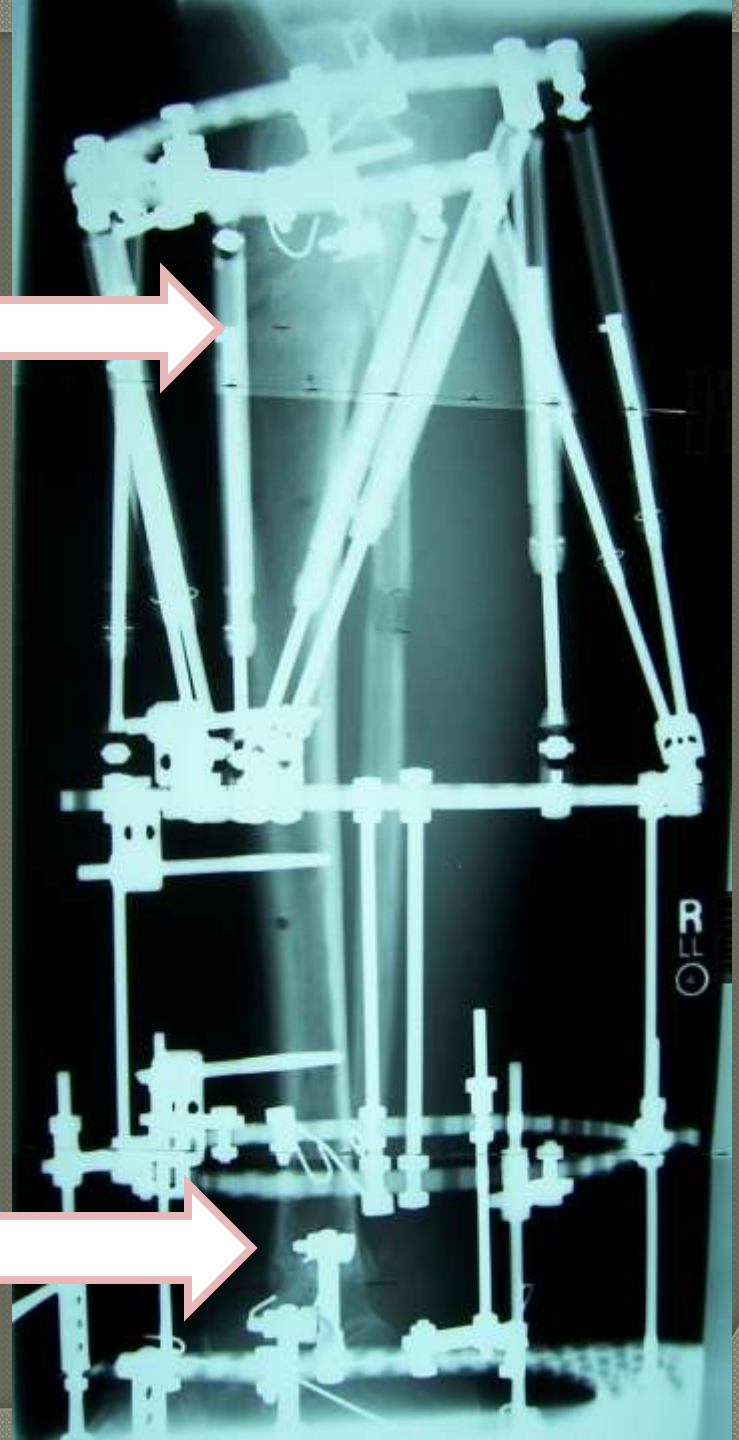
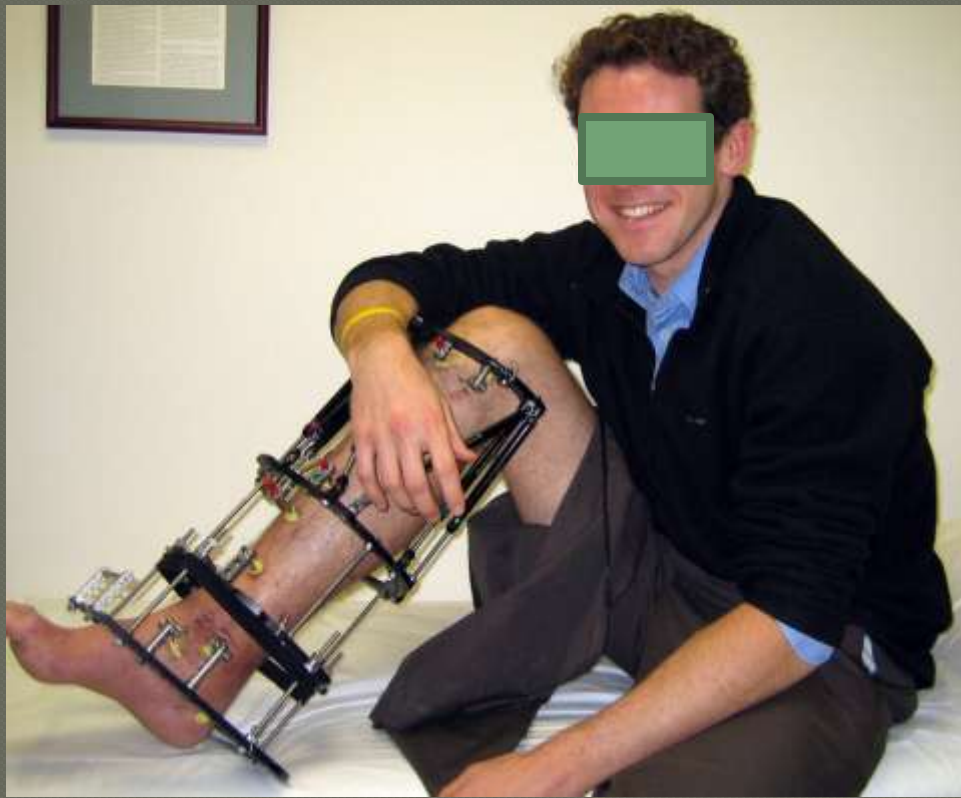
Introduction

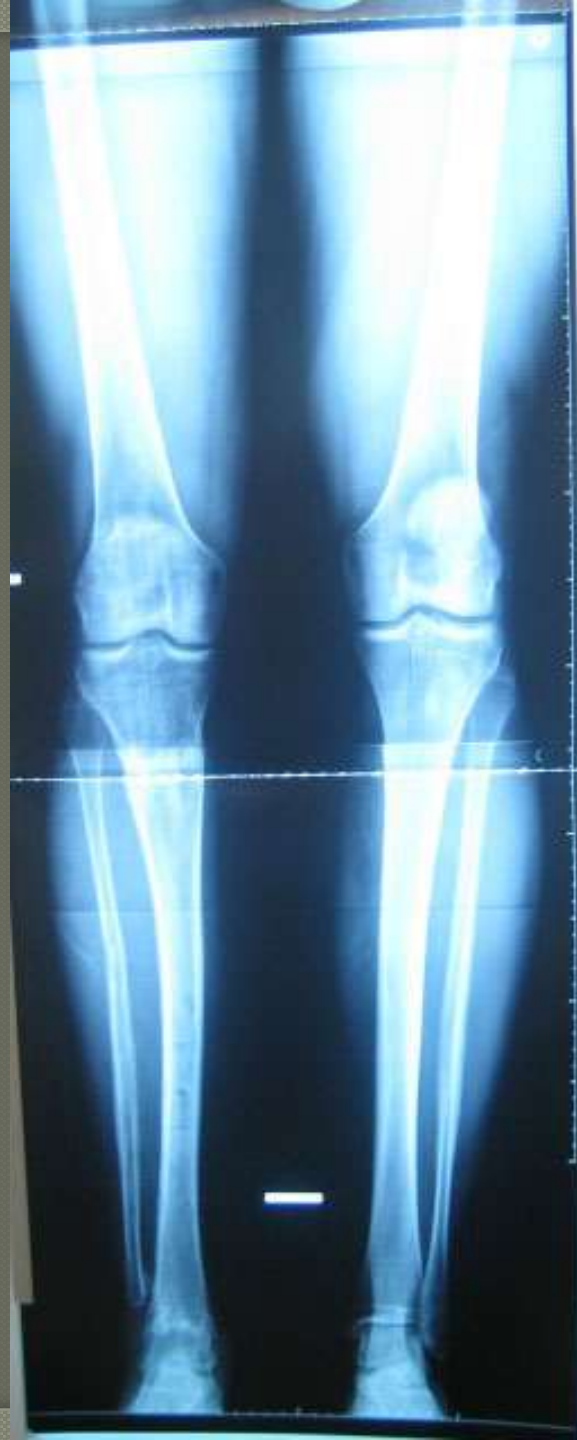Despite early appropriate treatment with modern orthopedic trauma surgery protocols, distal tibia and ankle injuries do not uncommonly result in posttraumatic ankle arthritis. Ankle fusion offers reliable pain relief and improved

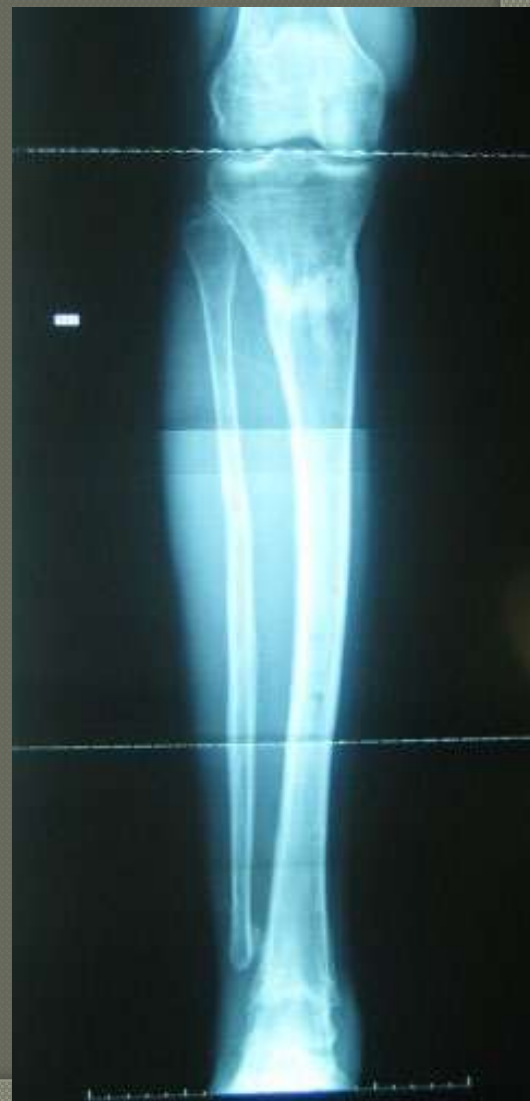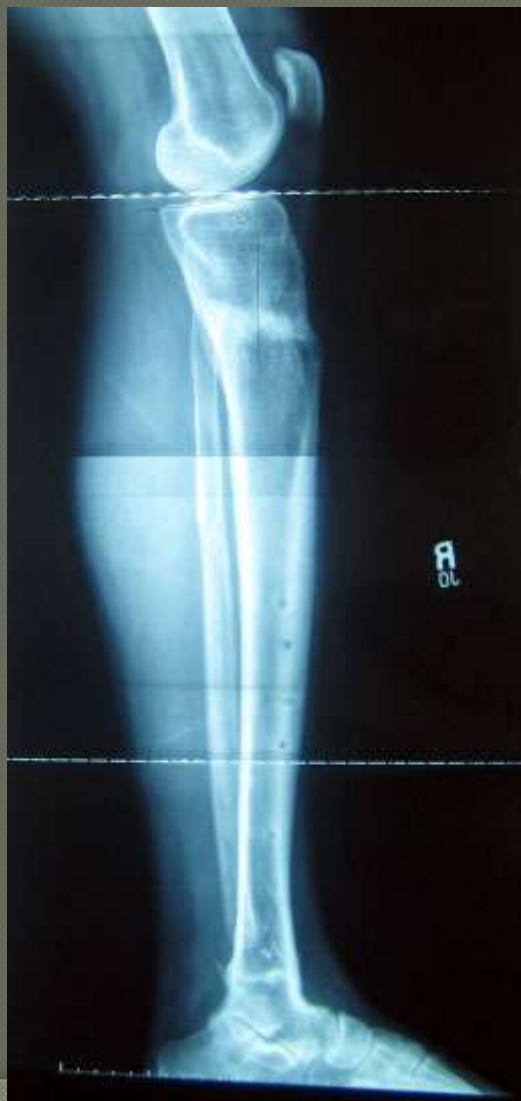and compliance is low. The use of structural allografts with internal or external fixation has been advocated to reestablish length [17–19]. Problems with graft collapse, infection, and nonunion accompany this technique. Proximal tibial lengthening provides an alternative means of equalizing leg lengths and improving function and self-perception. The need to implant large devitalized bone graft at a compromised healing site is obviated by the use of the patients own bony regenerate at a separate lengthening site. This





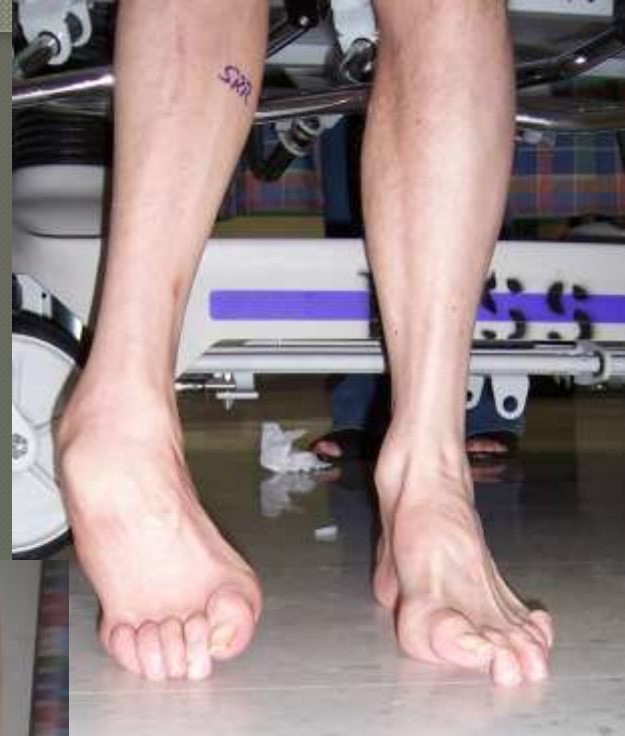
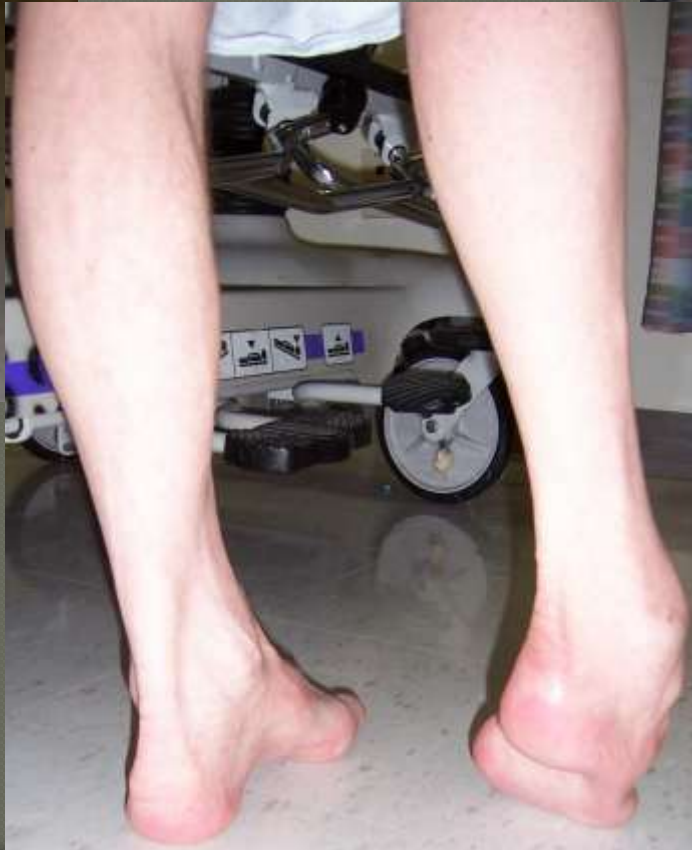
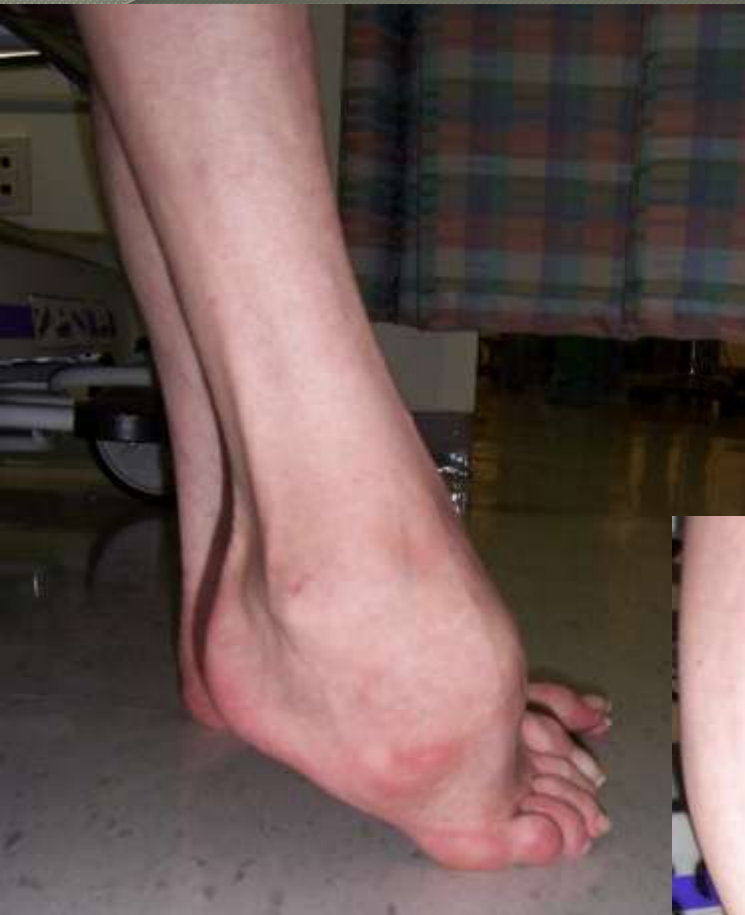

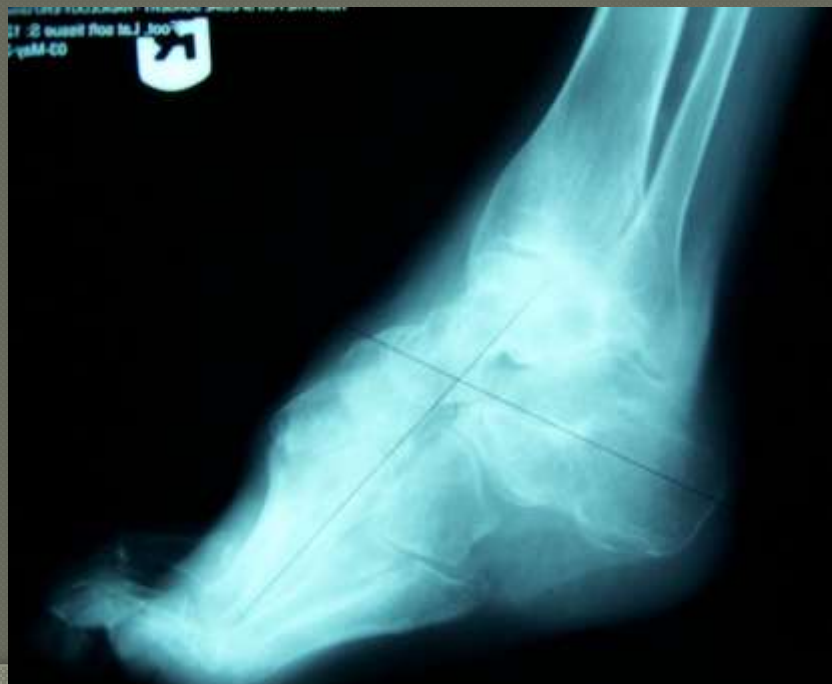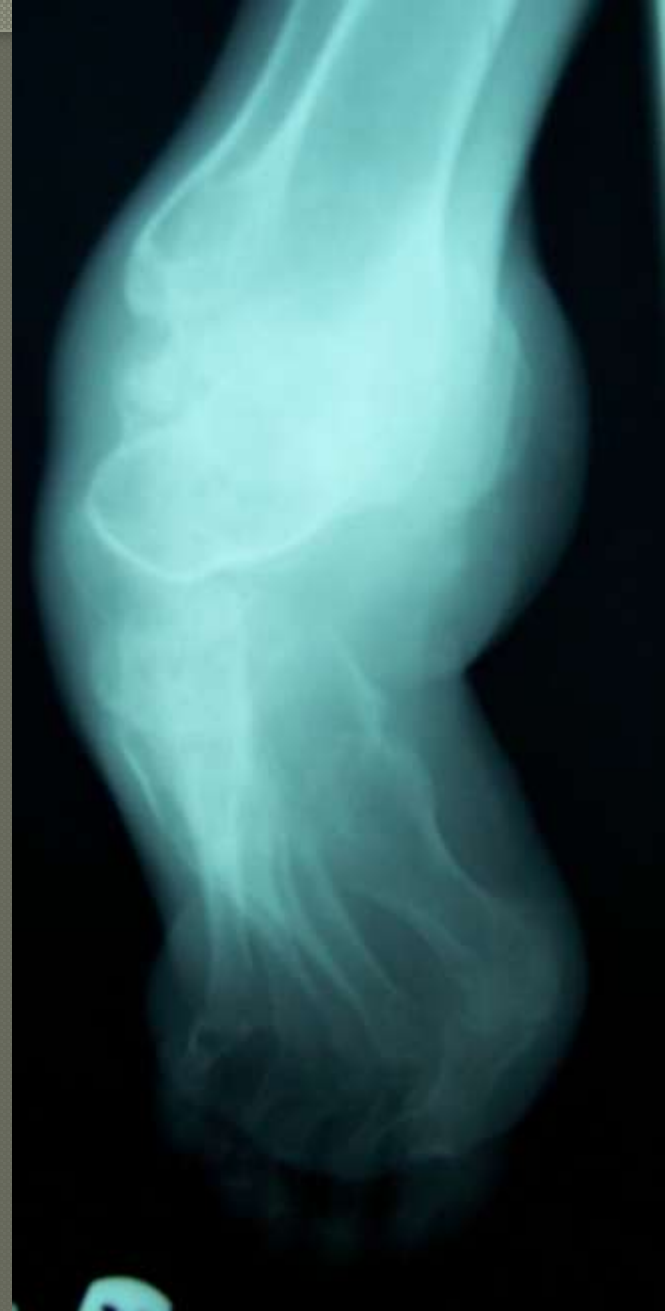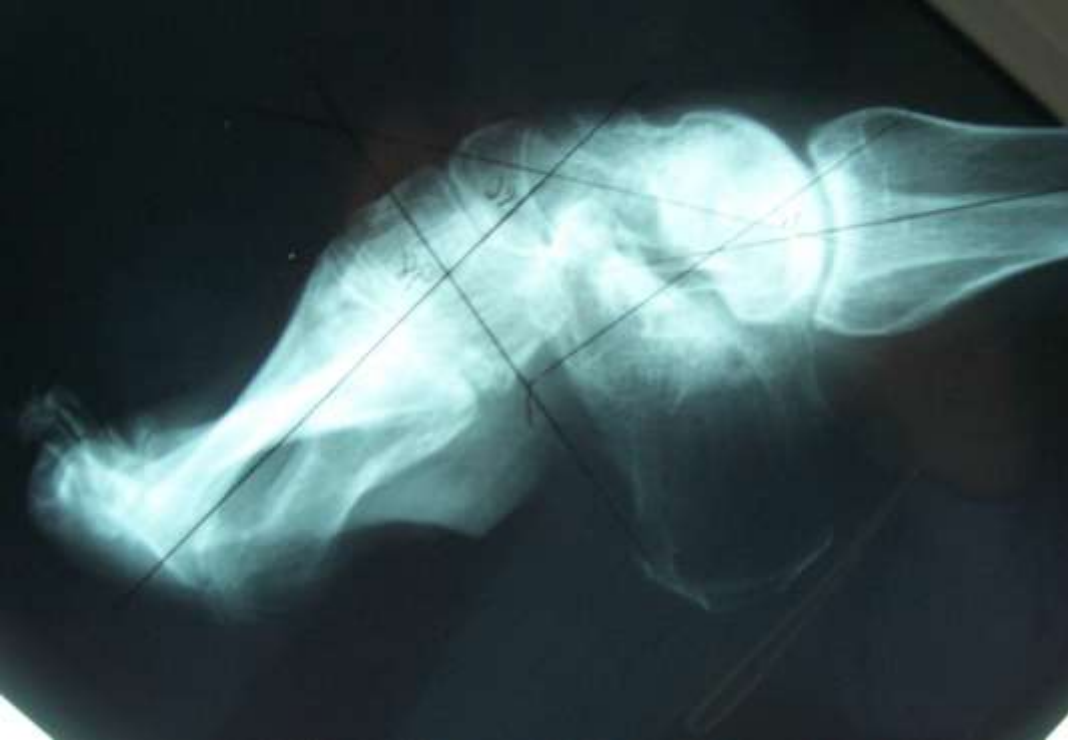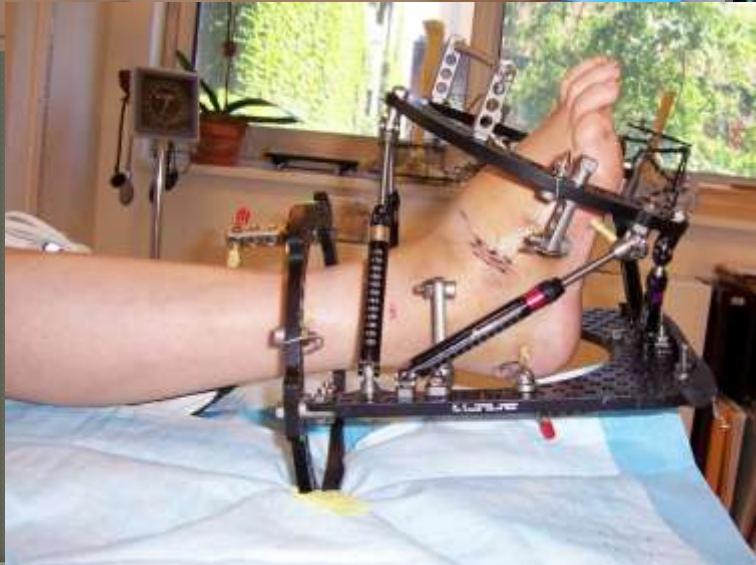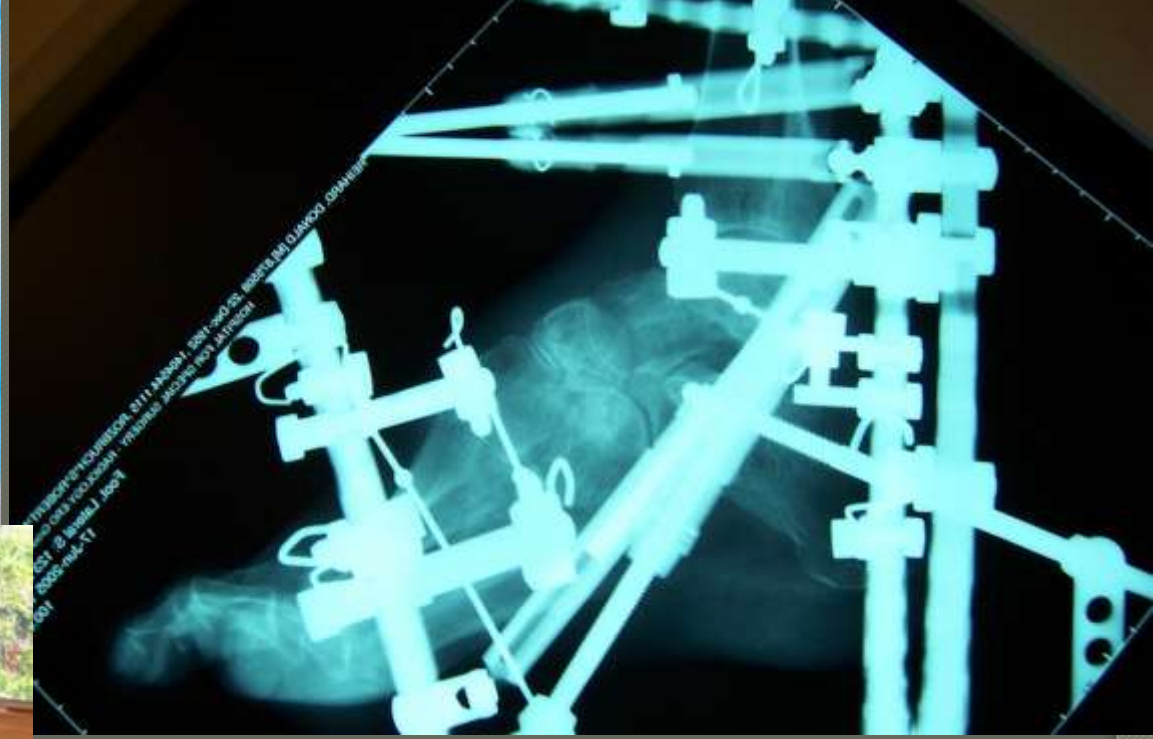







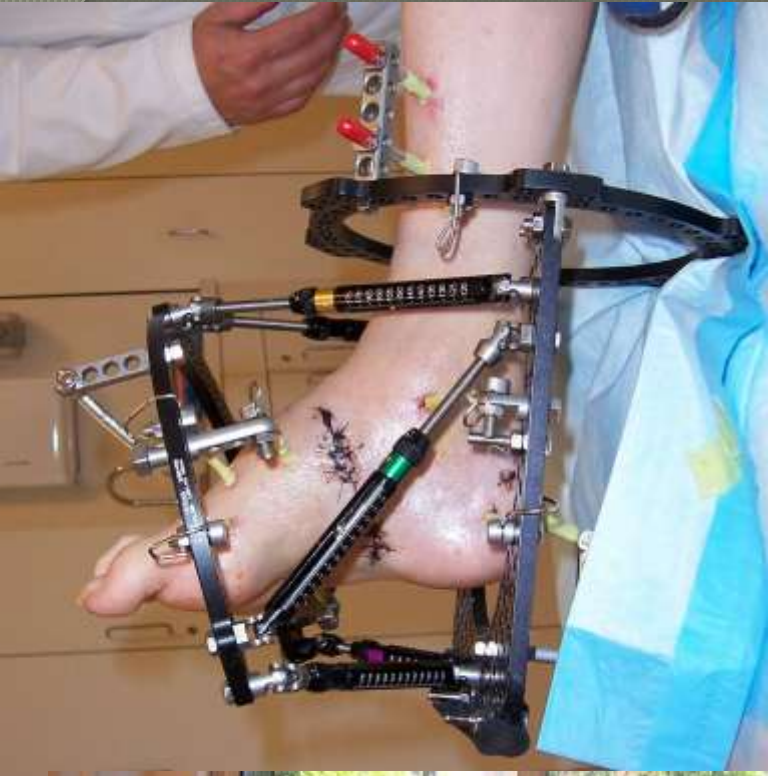


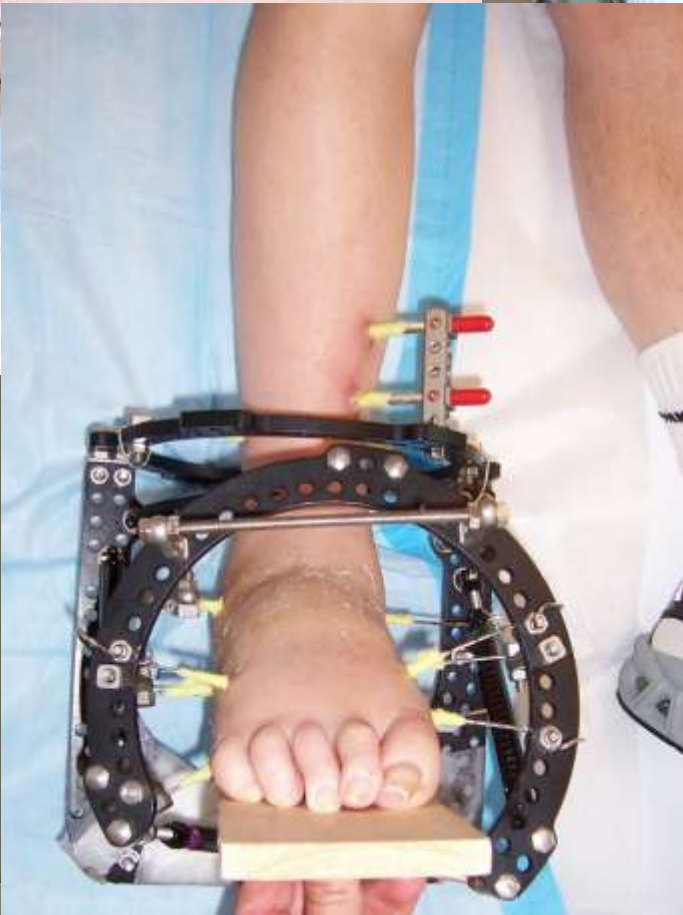
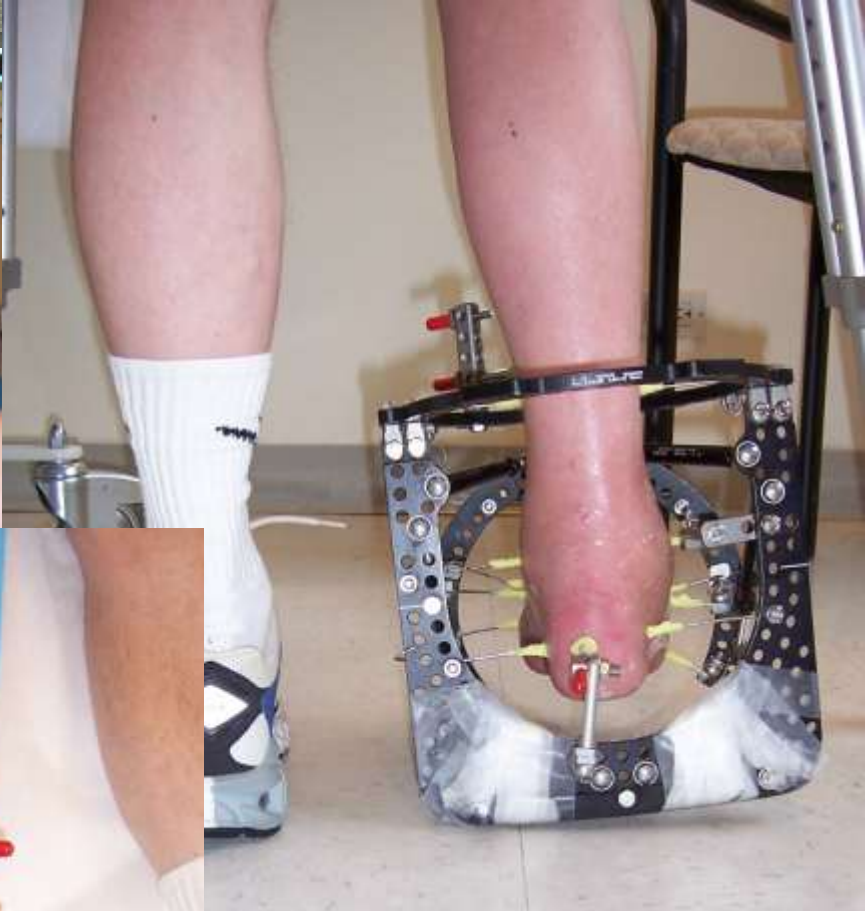
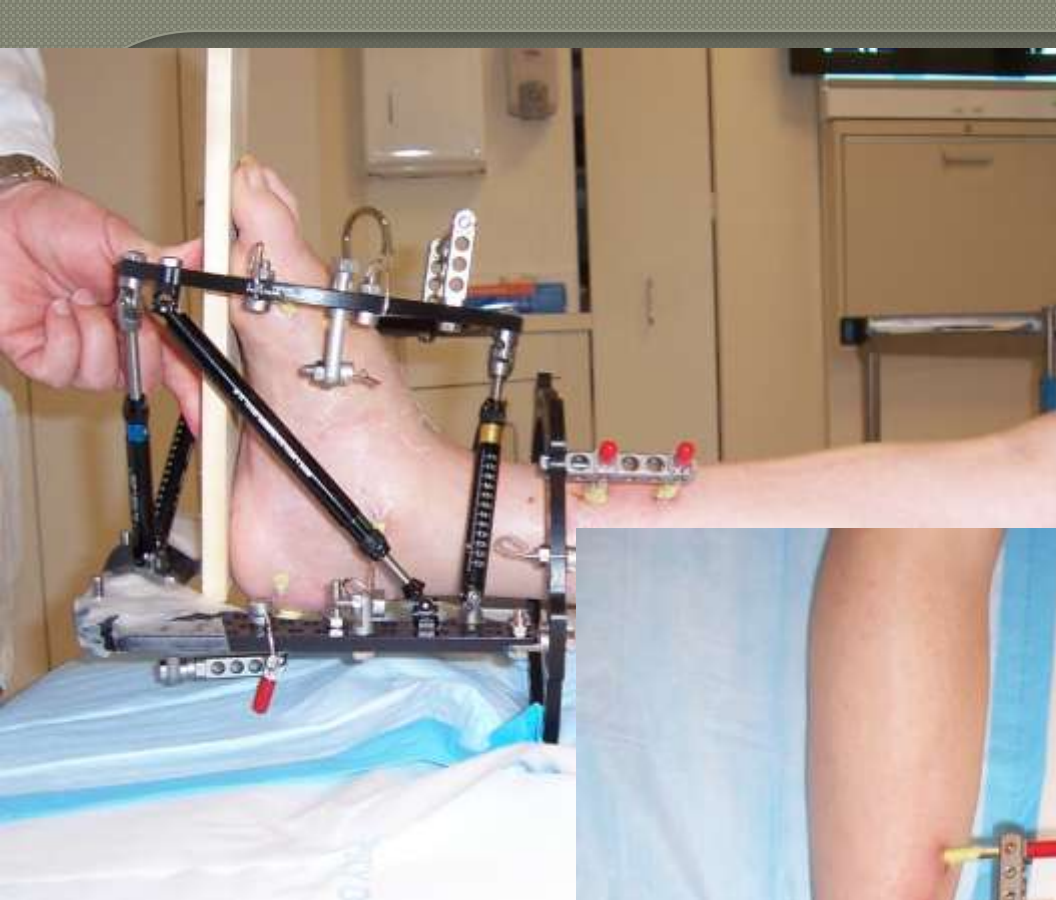


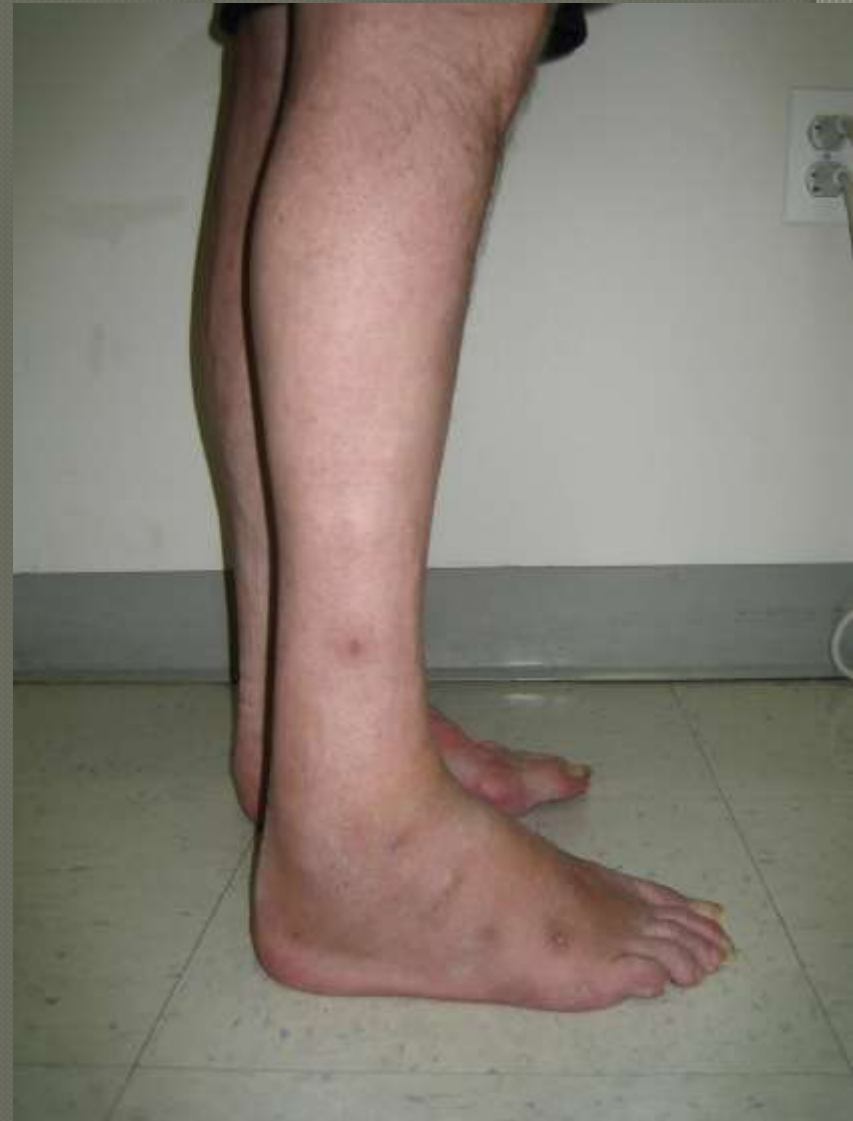
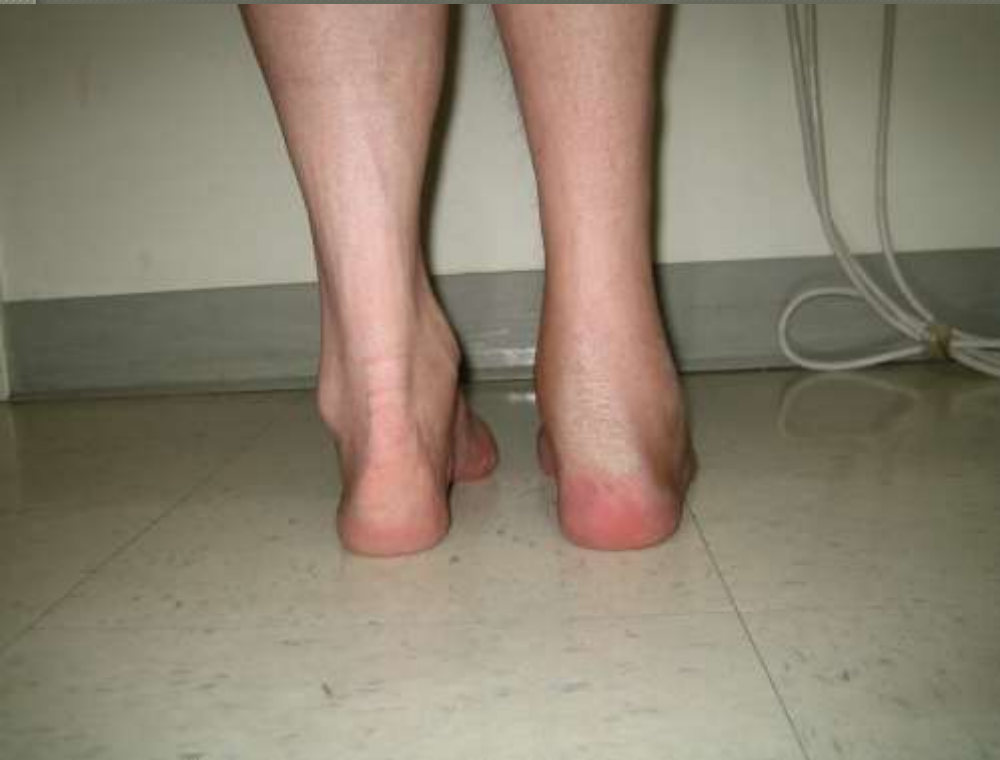

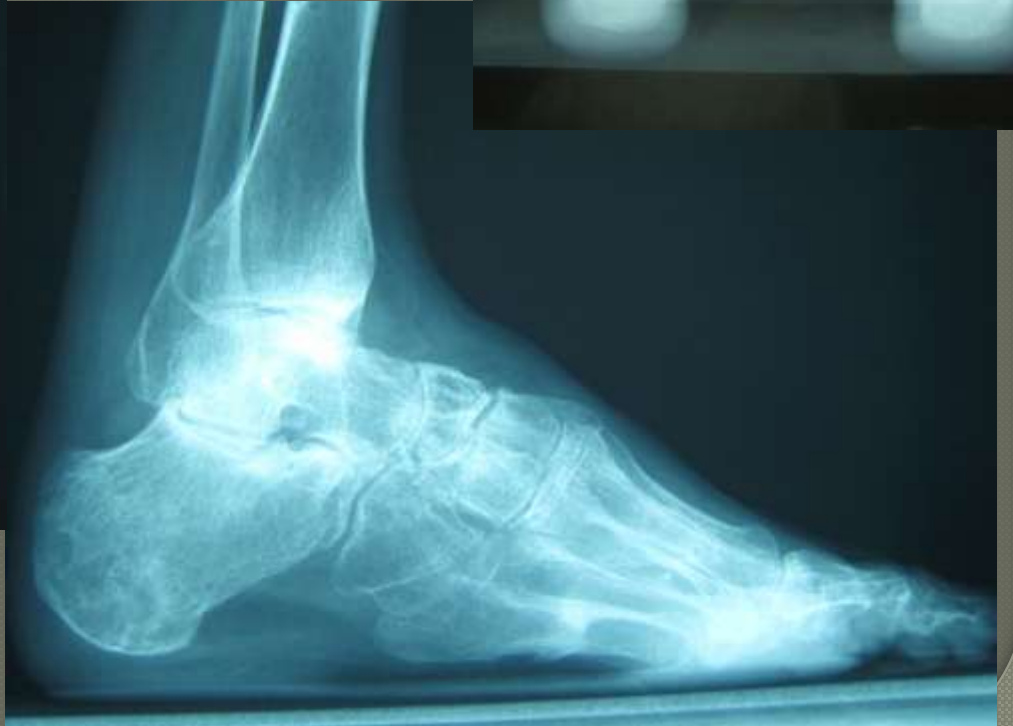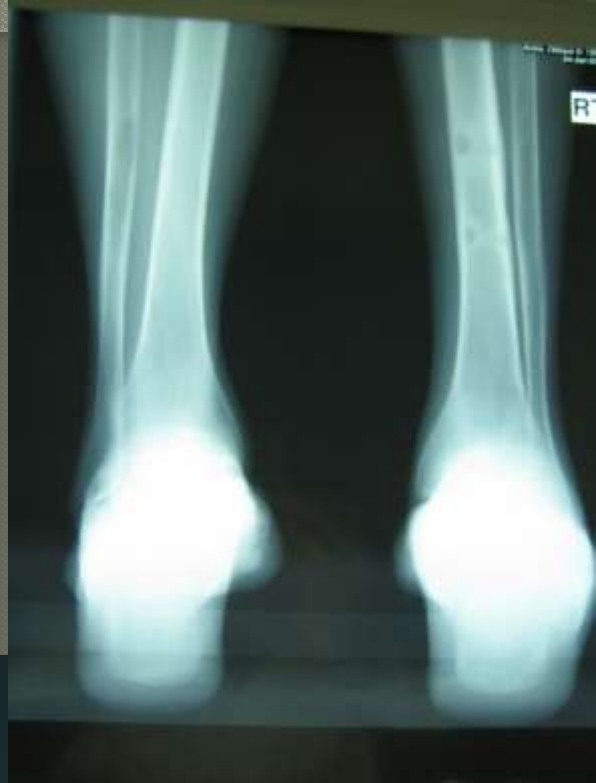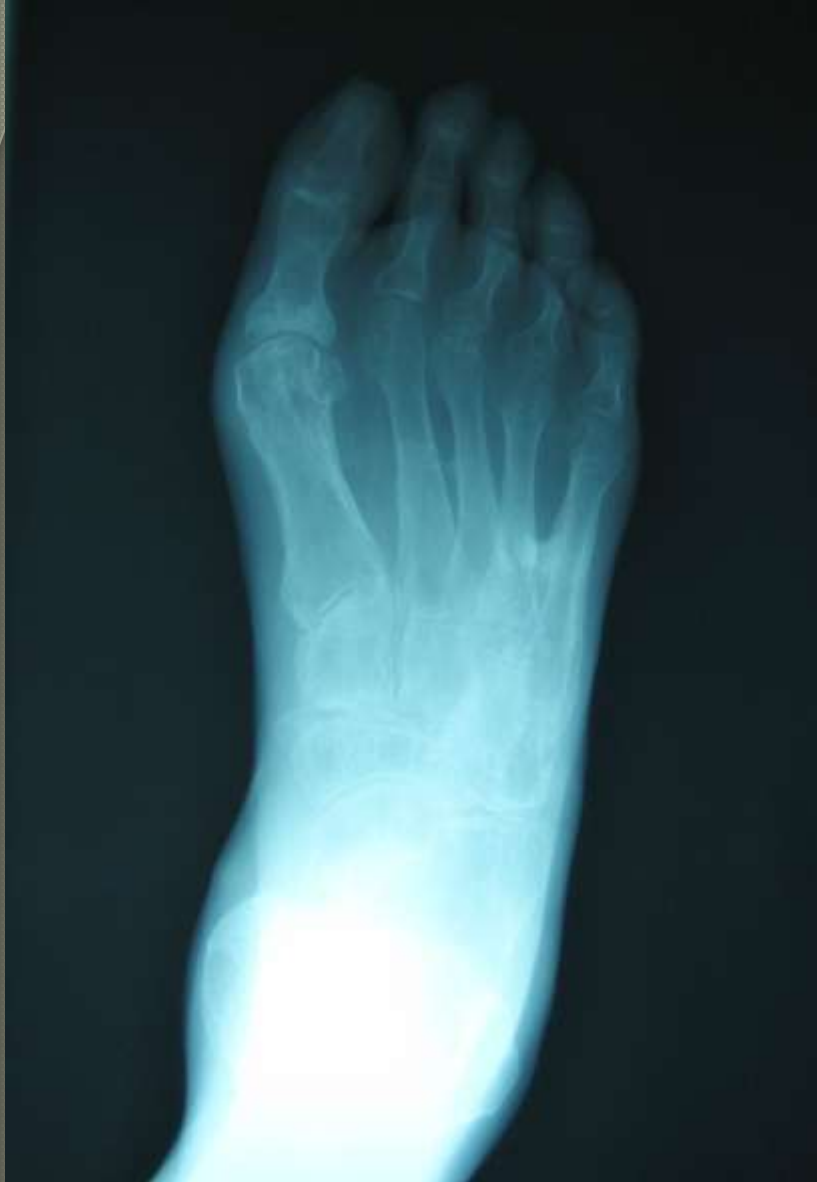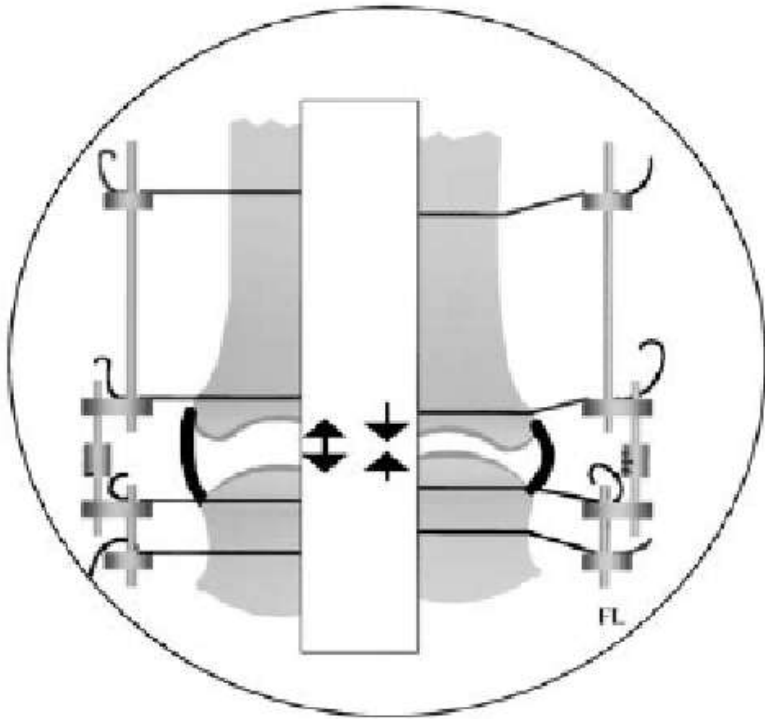


Ankle Distraction

- ◉ Alternative
- ◉ Does not burn bridges
- ◉ Minimally invasive
- ◉ Biological approach
- ◉ Joint preservation



Ankle Distraction



Mechanical unloading of the joint

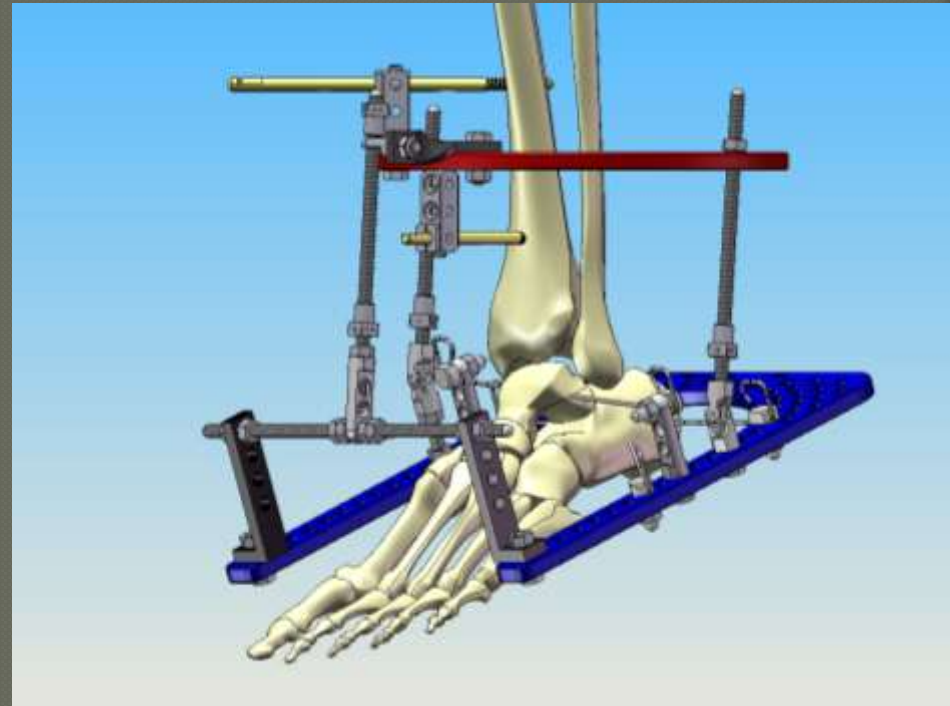
- Cartilage reparative process

Intermittent flow of joint fluid and changes in hydrostatic pressure

- Weight bearing and ankle movement in frame

Ankle Distraction

- AD works well
- AD preserves motion
- AD does not burn bridges



Joint Preservation of the Osteoarthritic Ankle Using Distraction Arthroplasty

Nazzar Tellisi, MD; Austin T. Fragomen, MD; Dawn Kleinman, BS; Martin J. O'Malley, MD; S. Robert Rozbruch, MD
New York, NY

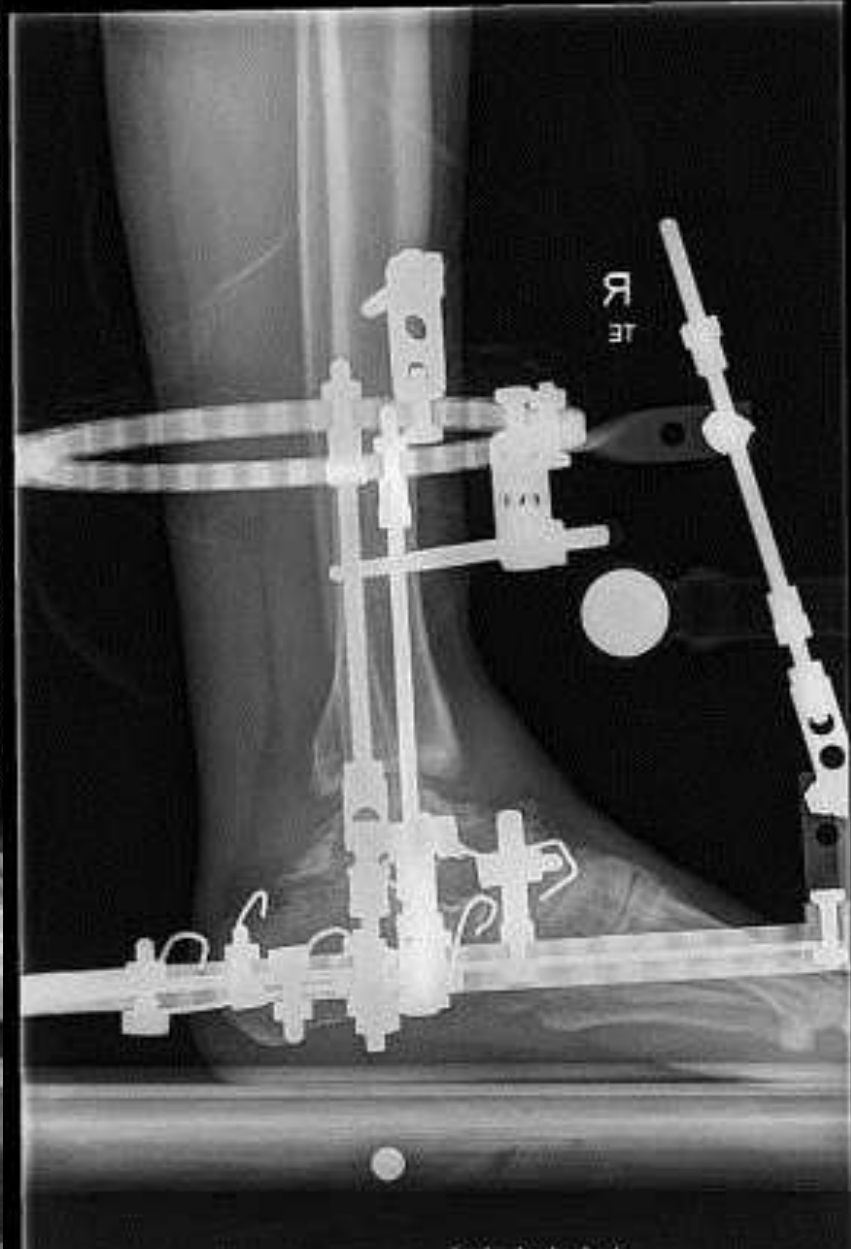
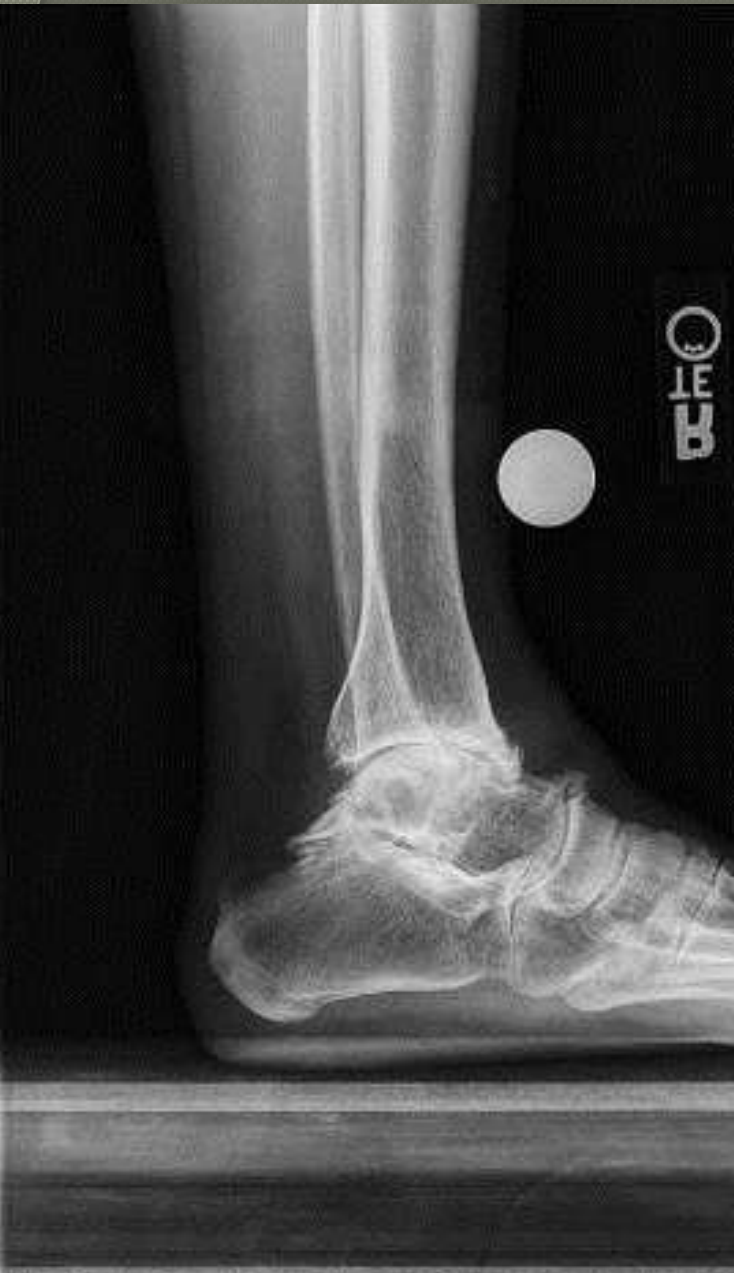ABSTRACT

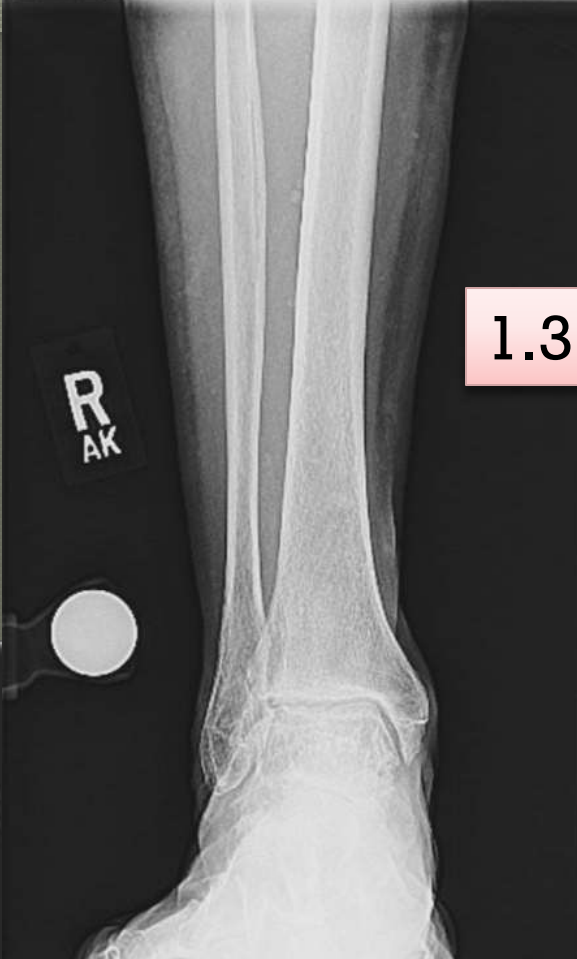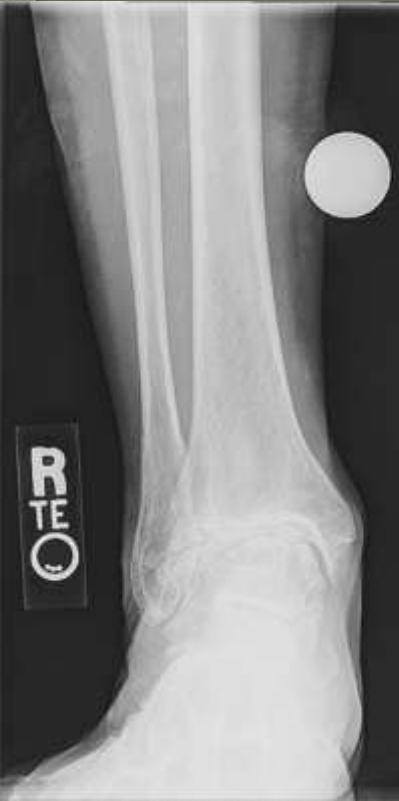Background: In recent years ankle distraction arthroplasty has gained popularity in the treatment of ankle arthritis as a means of both maintaining range of motion and avoiding fusion. We present a retrospective review of 25 patients who have undergone ankle distraction from 1999 to 2006. **Materials and Methods:** The mean age was 43 years; 16 were male, and 7 were female. Followup was 30 months after frame removal (range, 12 to 60 months). We were able to obtain followup on 23 of 25 patients. Adjuvant procedures were performed in some cases including Achilles tendon lengthening (5), ankle arthroscopy (4), open arthrotomy (1), and supramalleolar tibial and distal fibular osteotomy to correct distal tibial deformity (6). **Results:** Twenty-one patients (91%) reported improved pain with those furthest post-op experiencing the best results. The average preoperative AOFAS score was 55 (range, 29 to 82), and the average postoperative score was 74 (range, 47 to 96). The difference between pre- and postoperative scores was significant ($p = 0.005$). SF-36 scores showed modest improvement in all components. Only two of the patients in the study underwent fusion after ankle distraction. Total ankle motion was maintained in all patients with improvement in the

INTRODUCTION

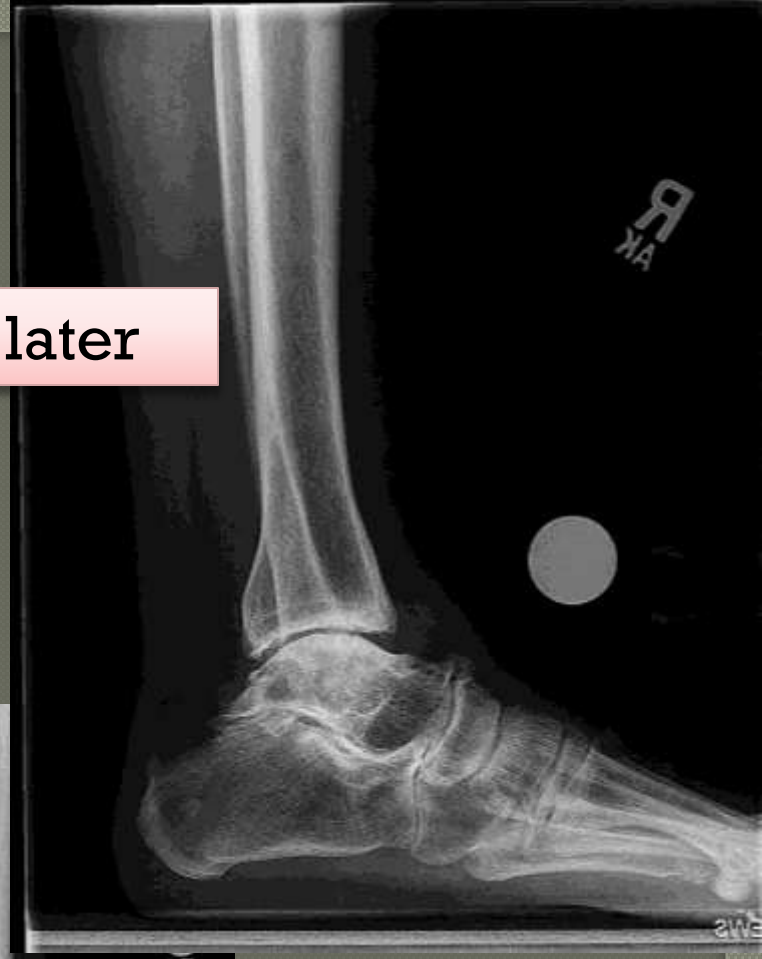Ankle arthritis and its management remain a challenge. Ankle fusion continues to be a mainstay of treatment for ankle arthritis. However, fusion is not an optimal solution due to the loss of joint motion and subsequent development of degenerative arthritis of adjacent joints. Other disadvantages of arthrodesis include a substantial rate of malunion, nonunion, wound healing problems, loss of function, abnormal gait, and increased energy expenditures with ambulation.⁹ Ankle arthritis is most commonly seen in patients as a post-traumatic sequelae.⁸ Many patients were highly functional prior to their injuries and are reluctant to sacrifice the ankle motion following ankle arthrodesis. With the lack of encouraging long-term results from prosthetic ankle arthroplasty, other treatment modalities are sought.

Joint distraction arthroplasty, using a circular external fixator, is not a new approach in the treatment of arthrosis. Distraction arthroplasty was first implemented in the management of hip arthritis by Judet.² Van Valburg, et al.¹¹⁻¹³ later applied this concept to the arthritic ankle joint. The theory

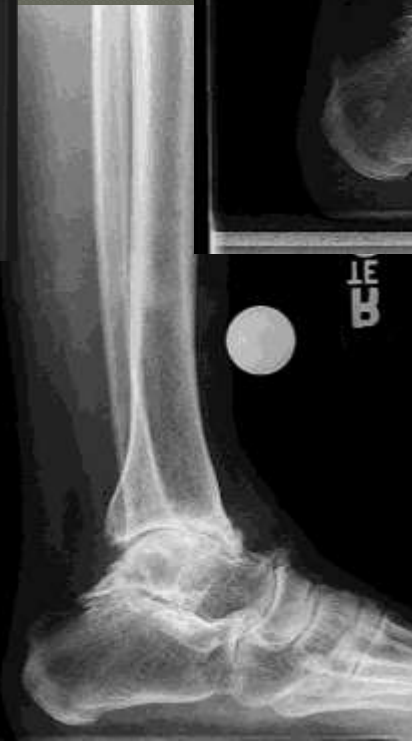



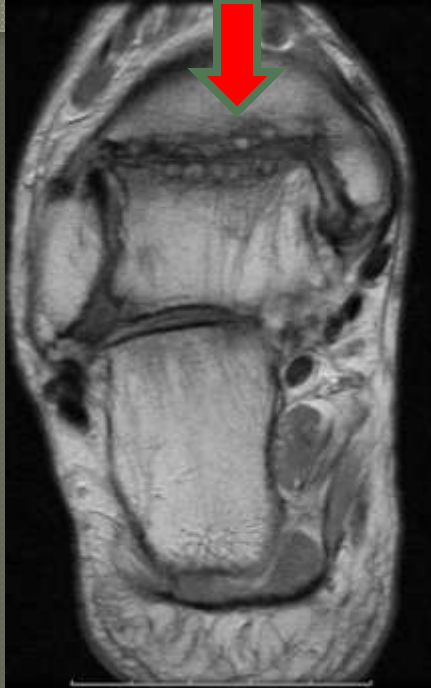1.3 years later



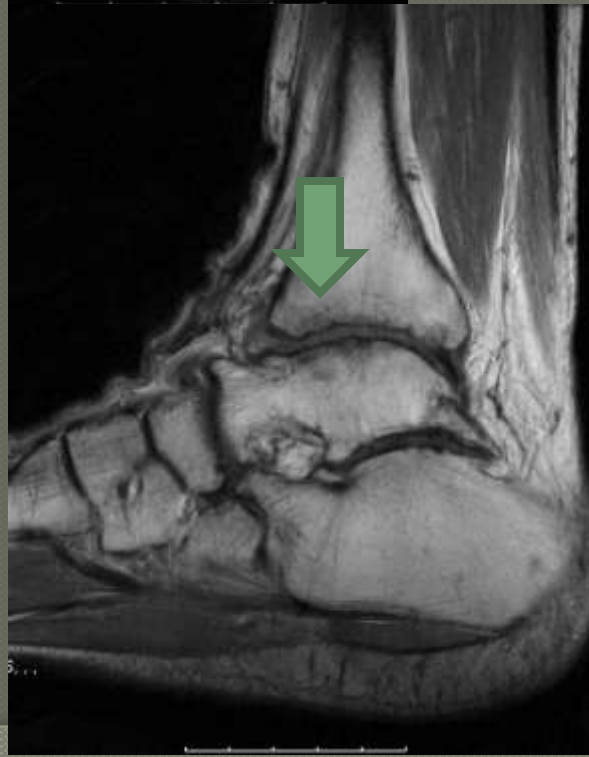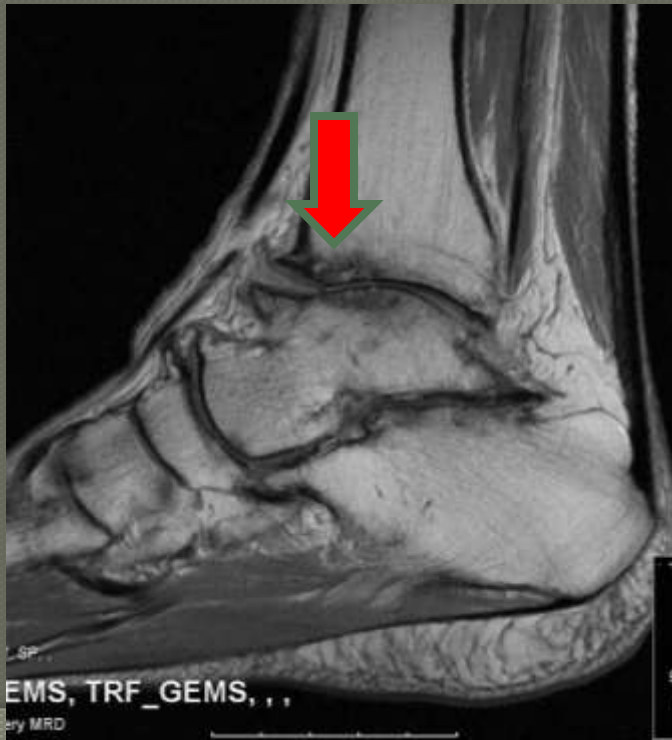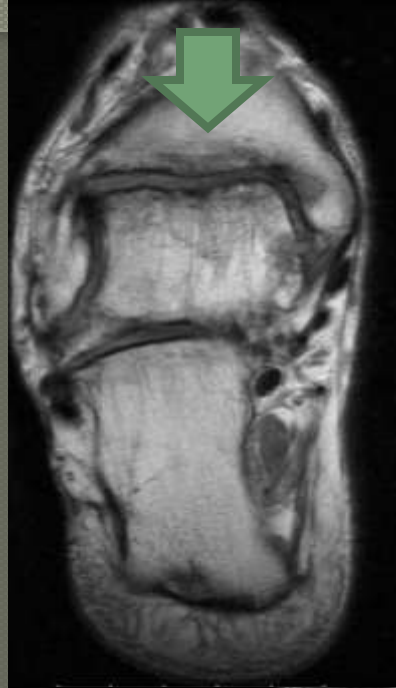preop



preop

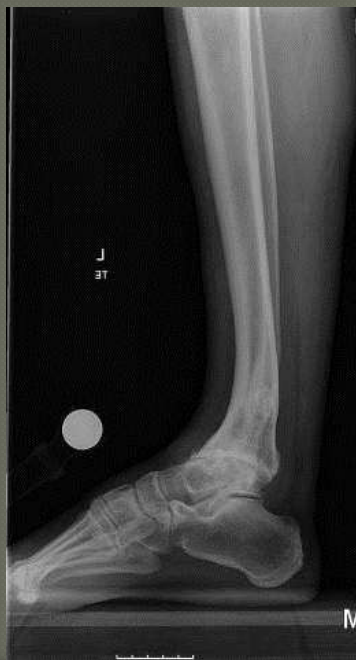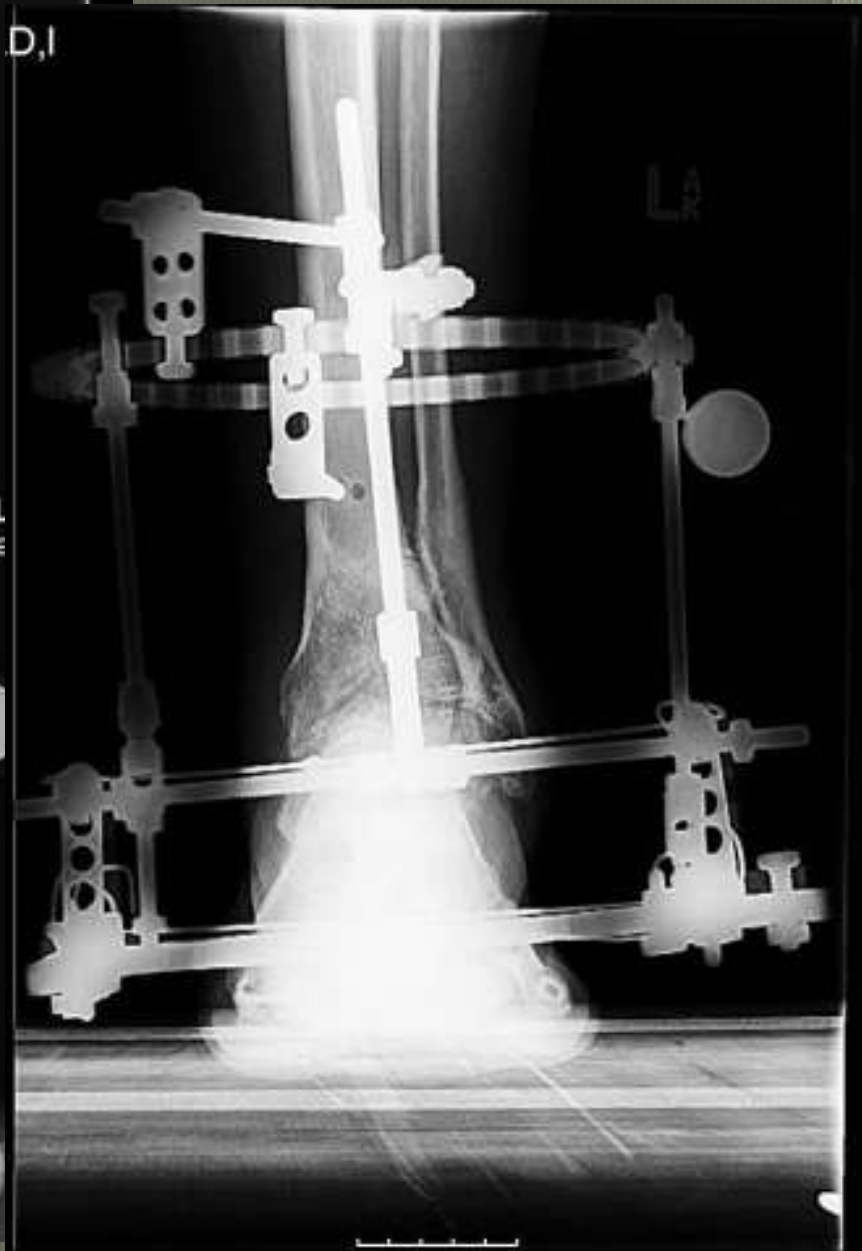

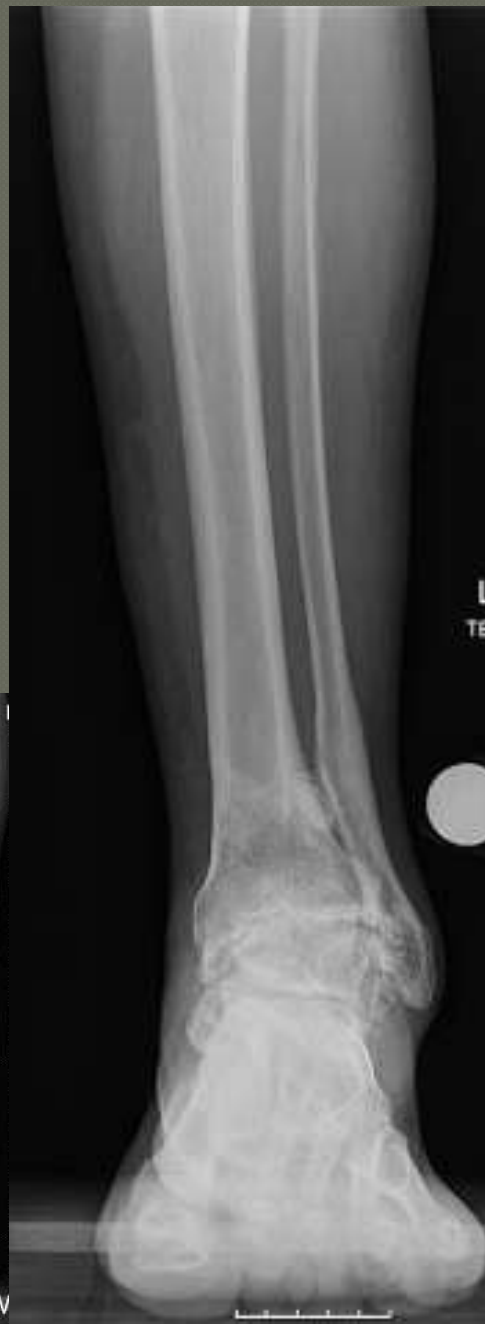
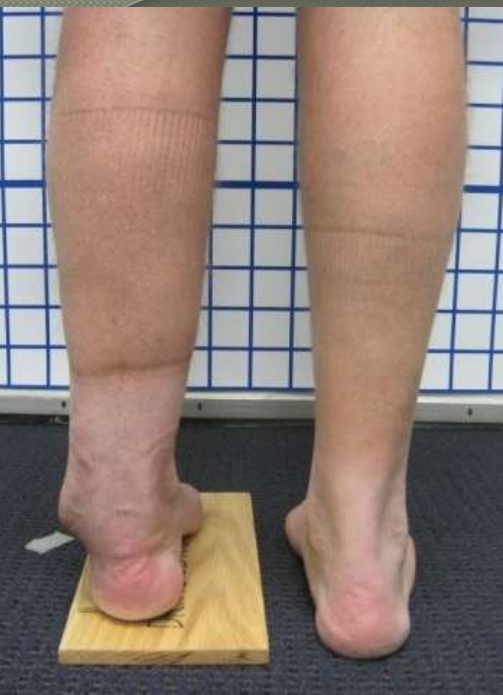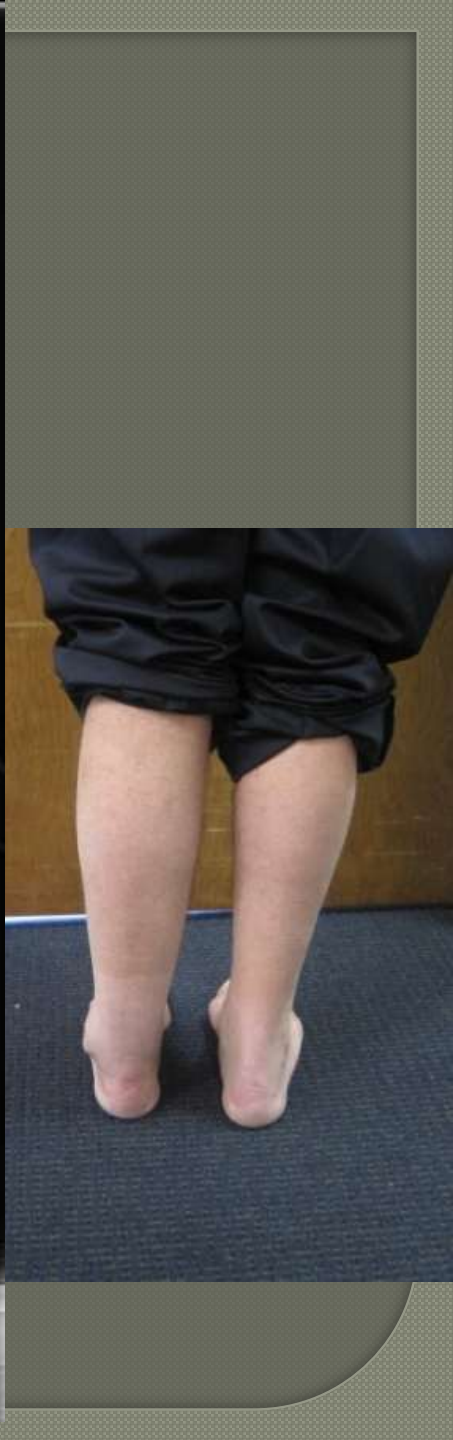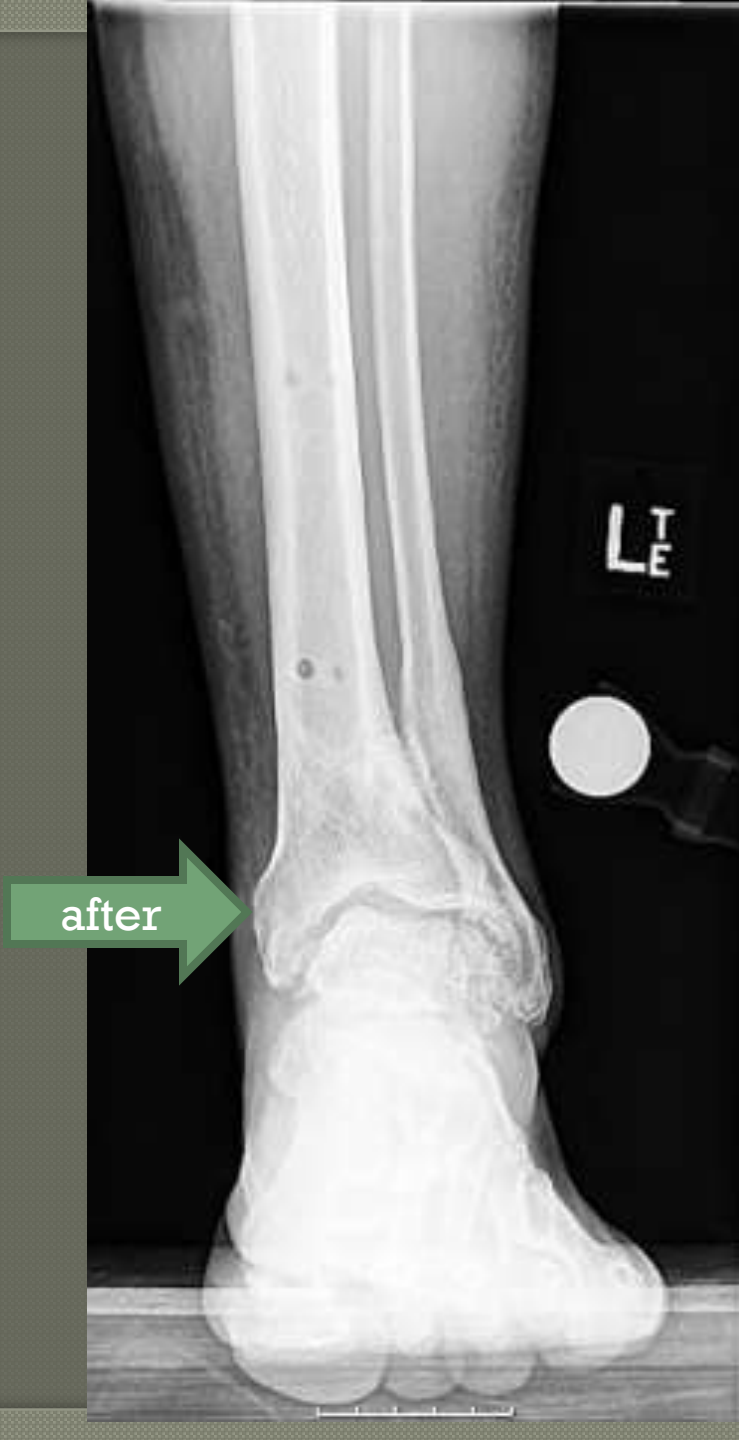
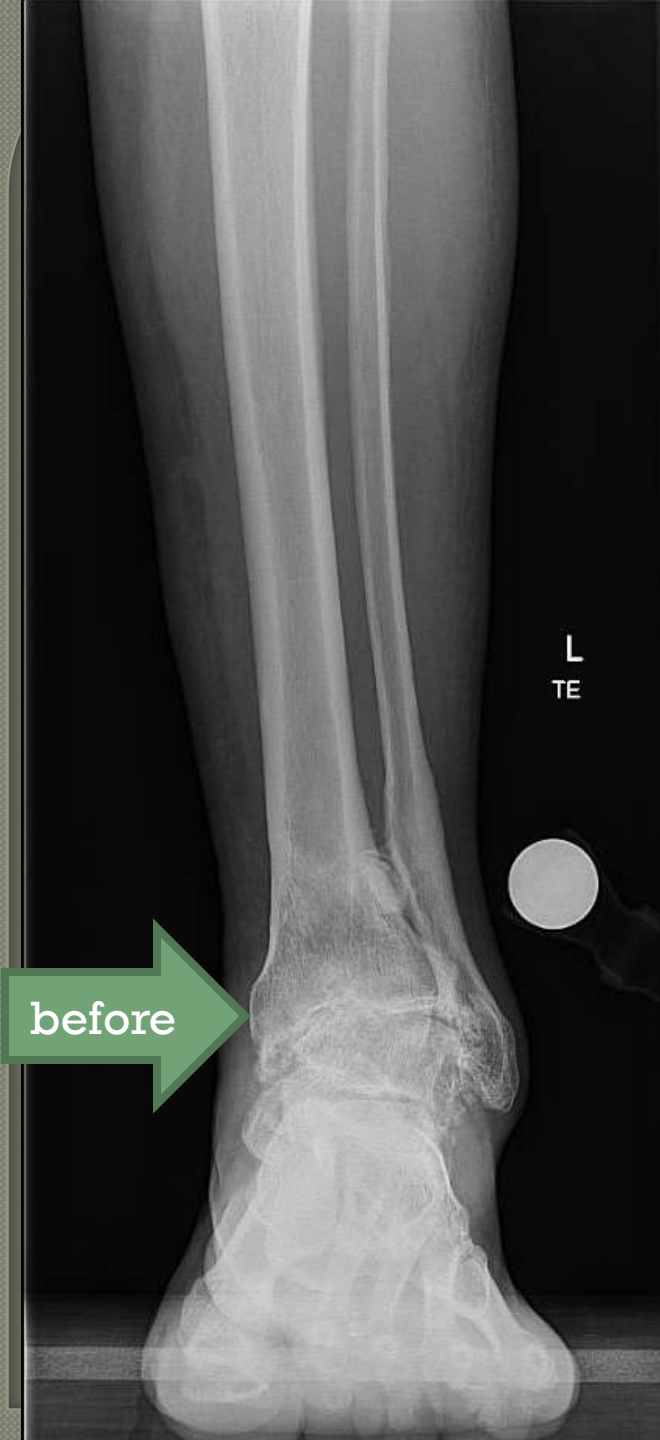1.3 years later

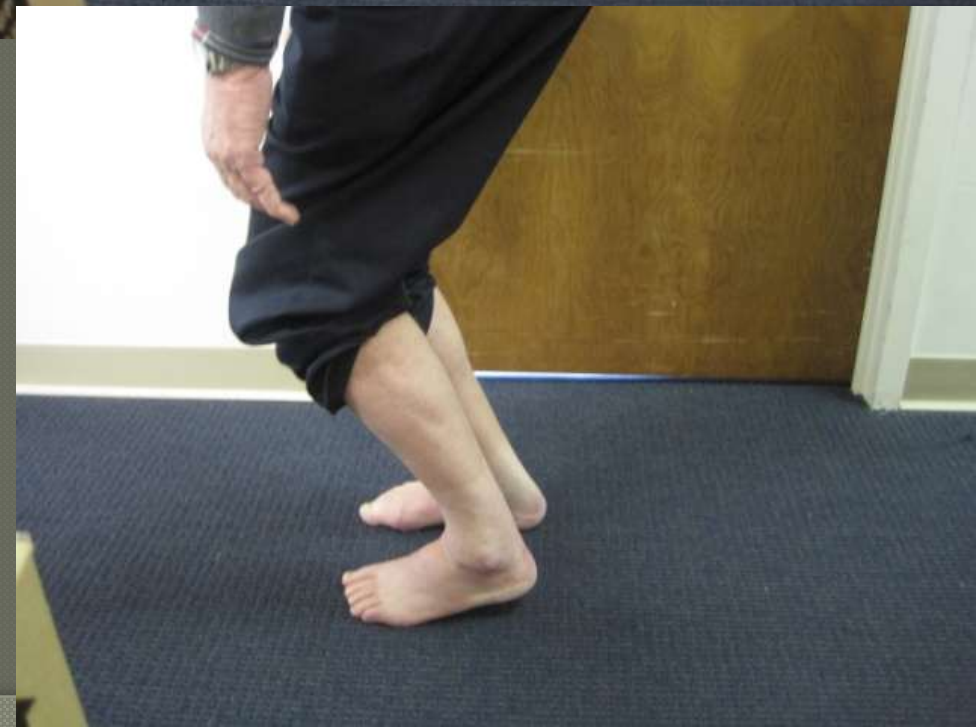
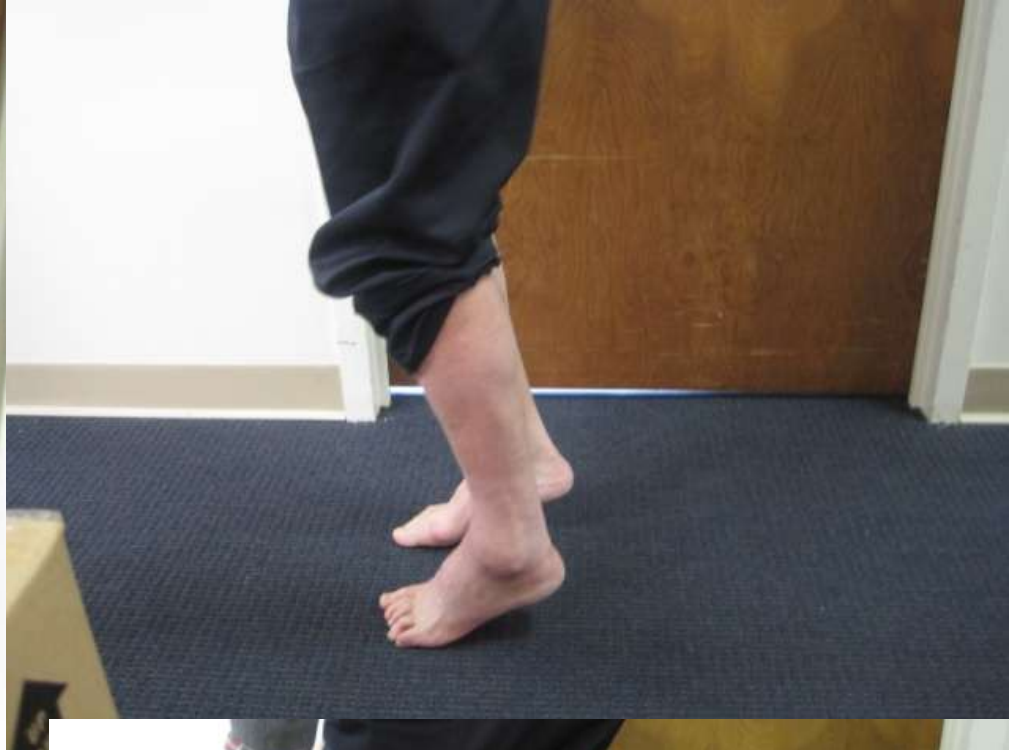
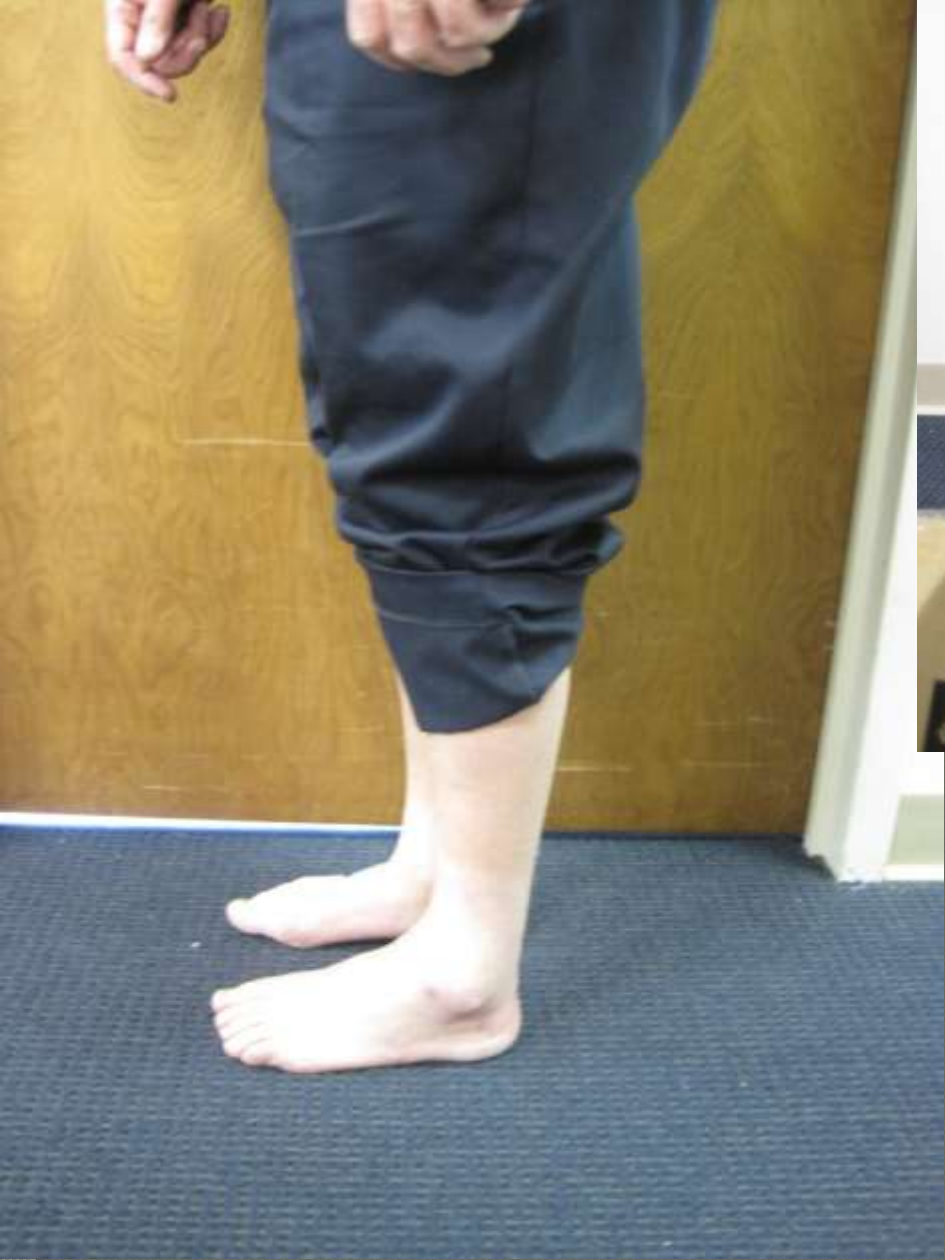EMS, TRF_GEMS, , ,
ery MRD

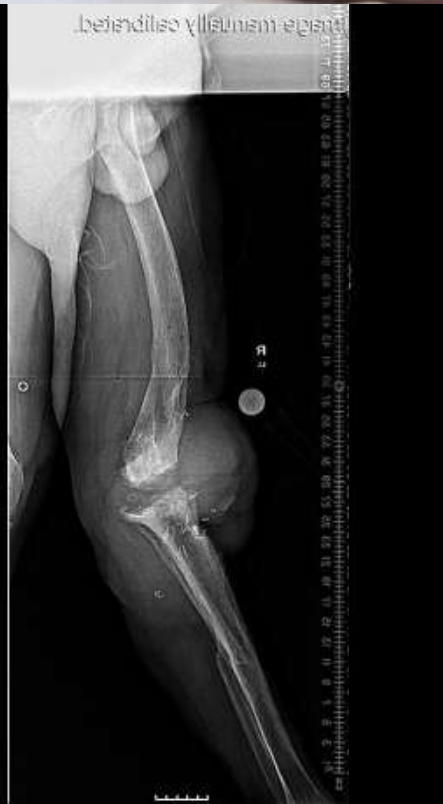
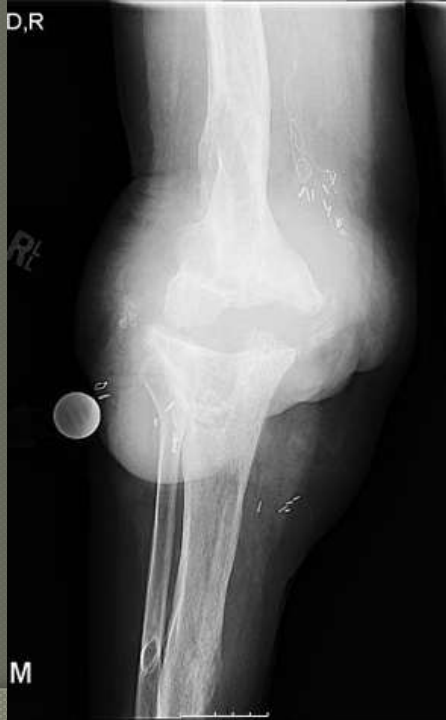
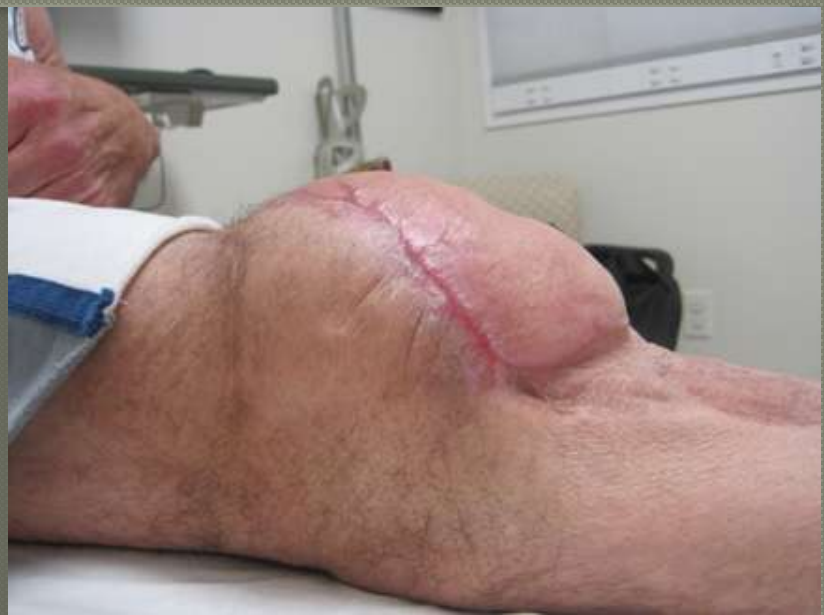
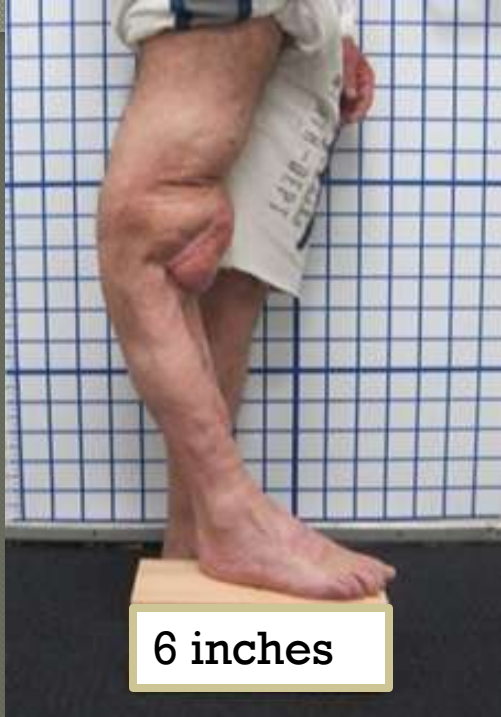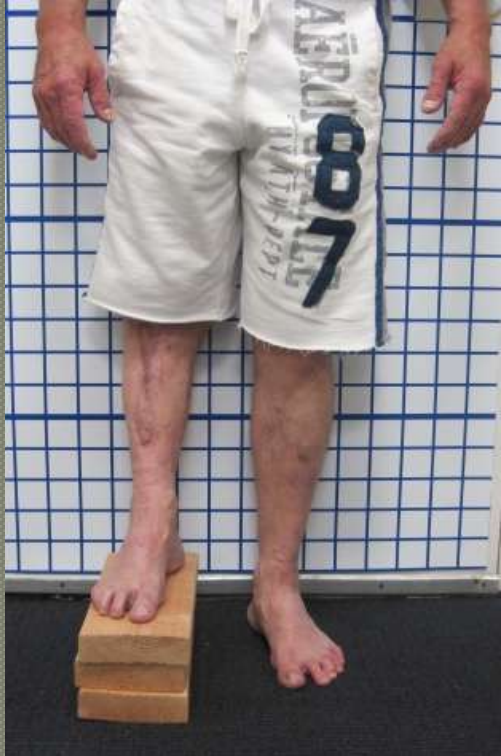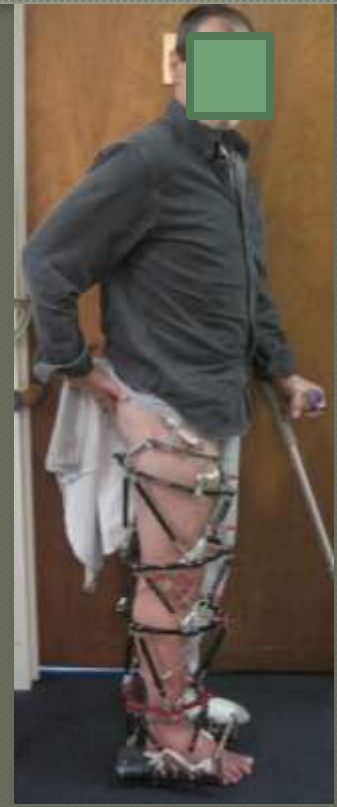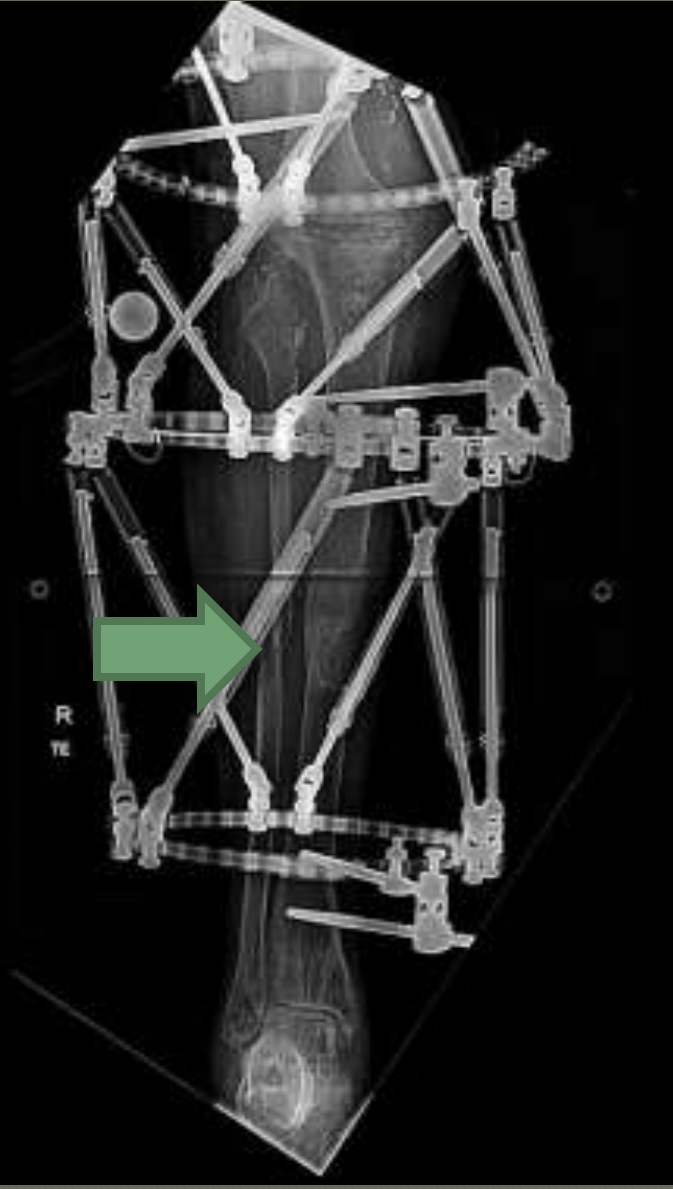
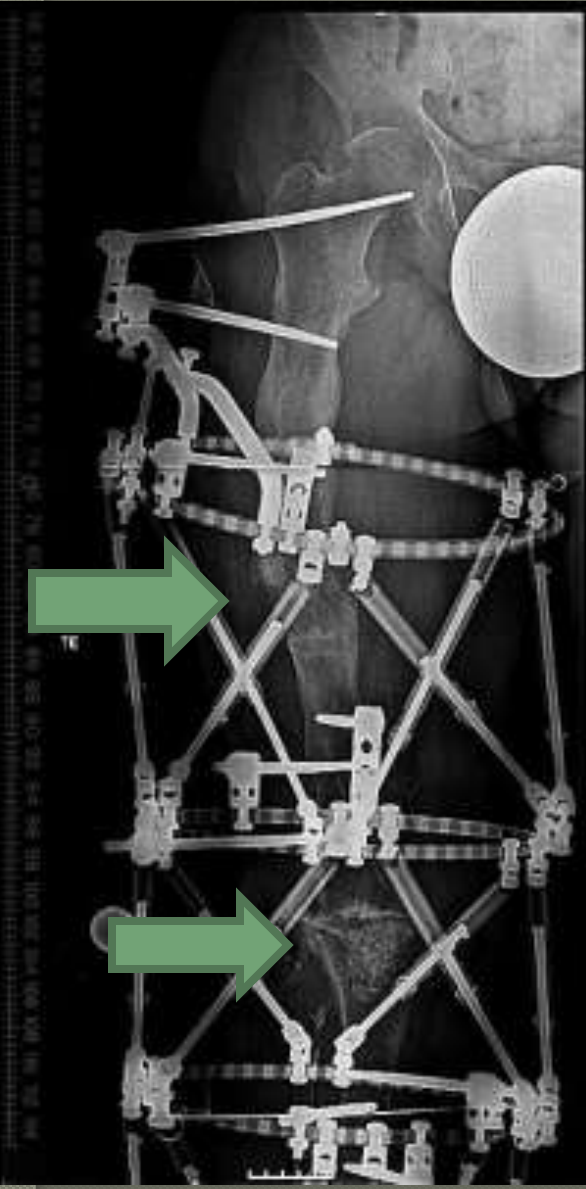







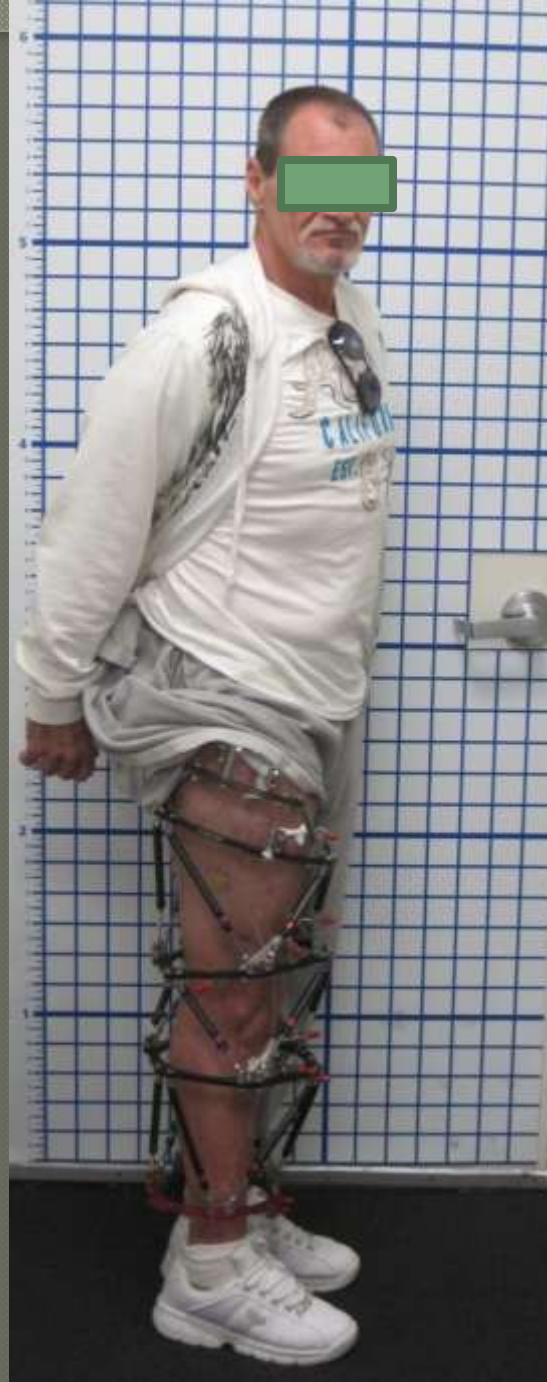
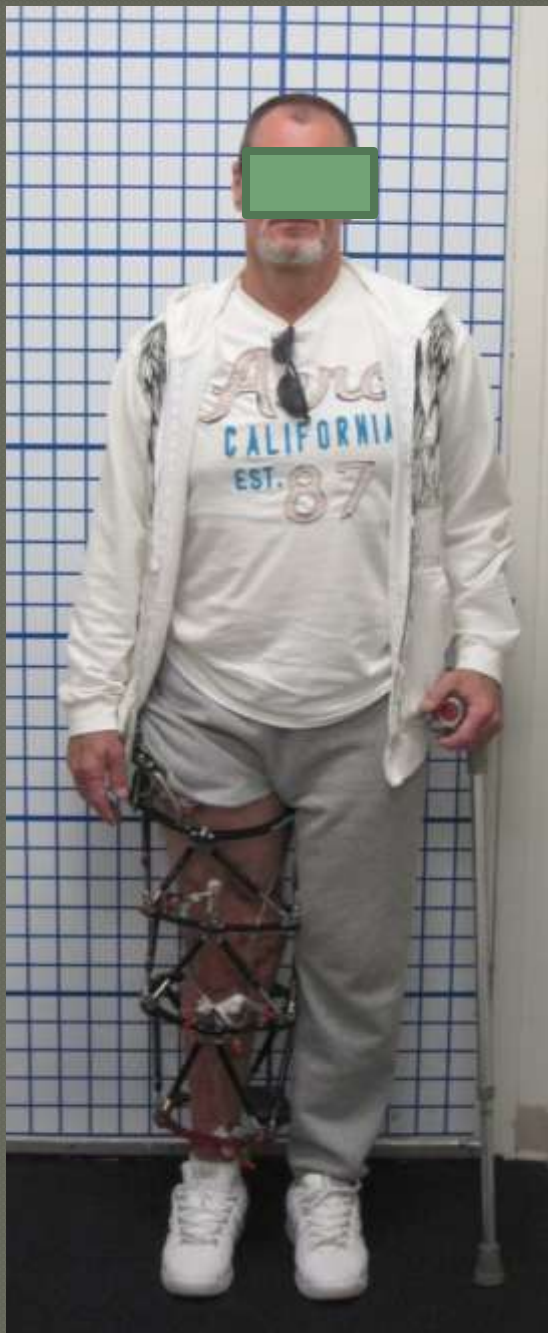


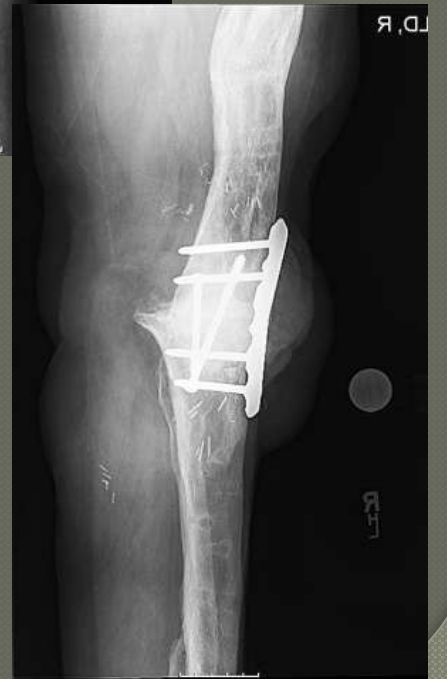
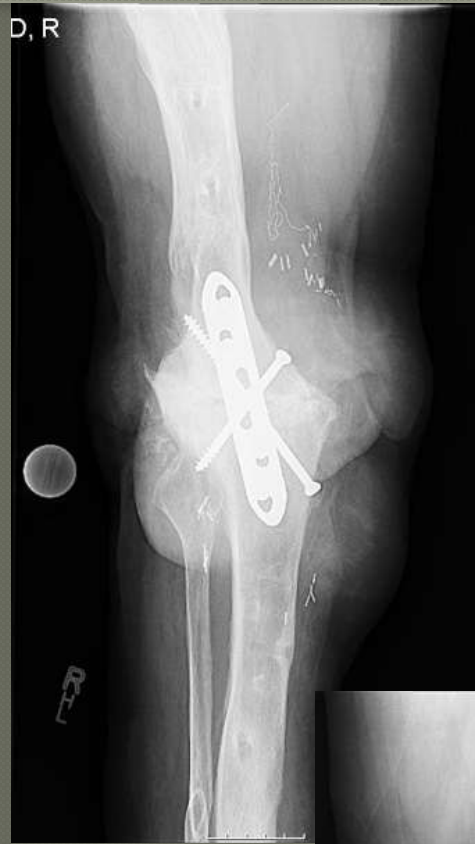
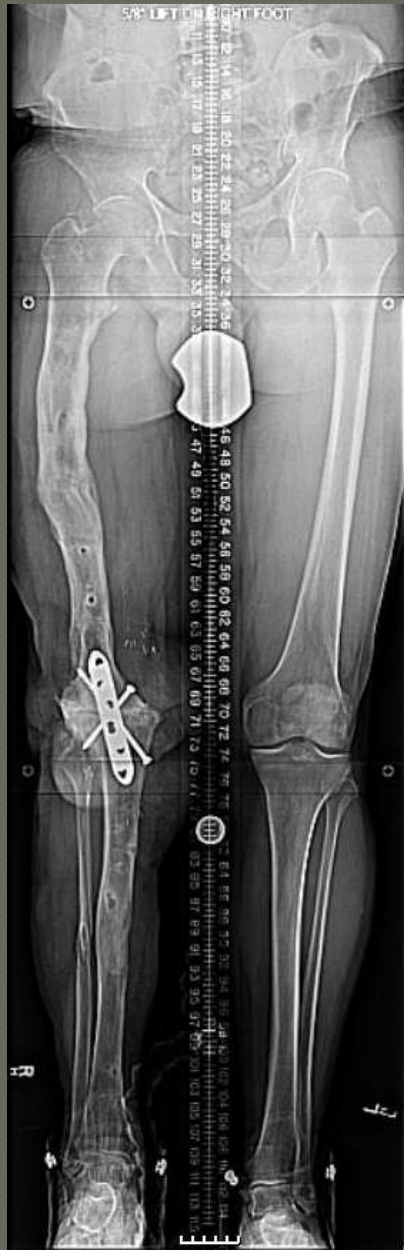
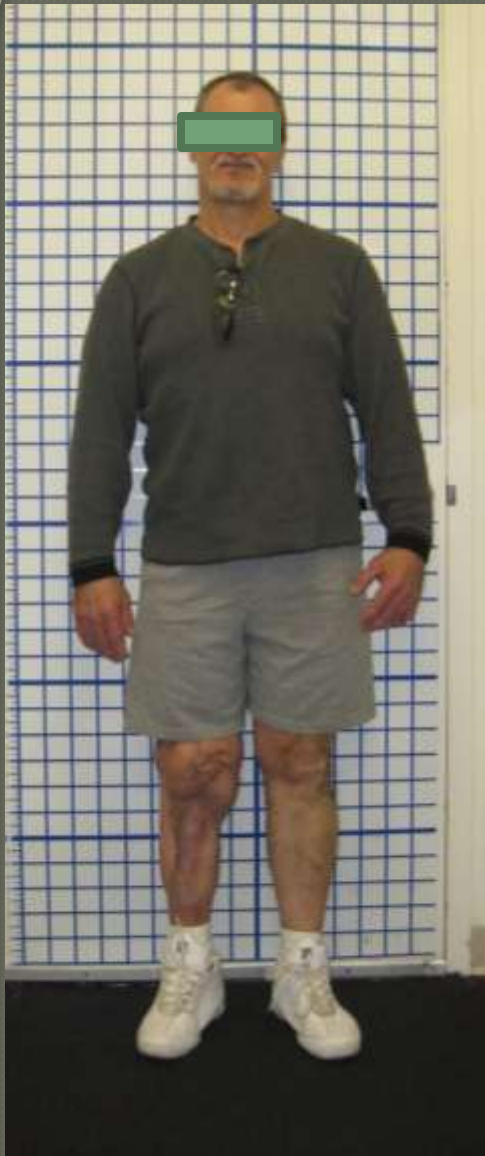

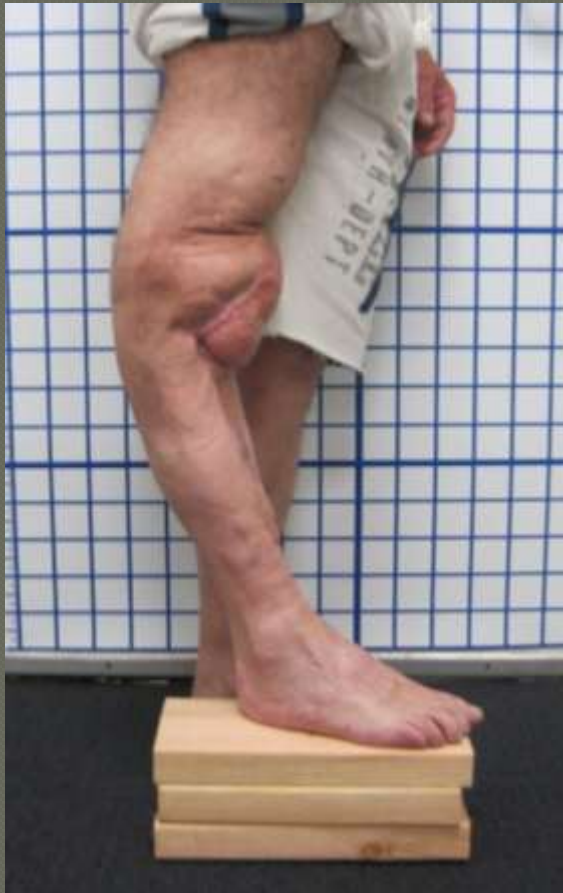preop

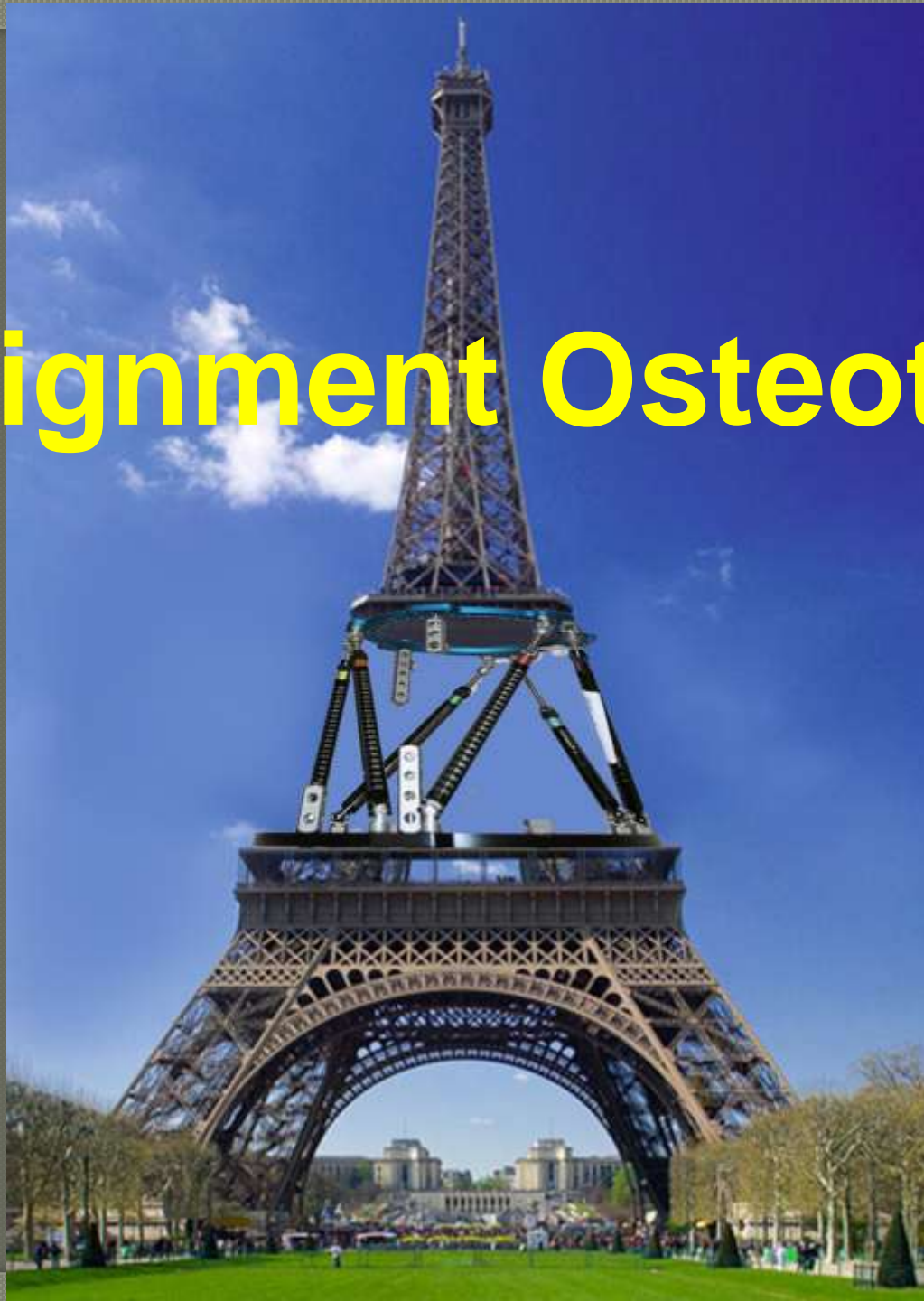

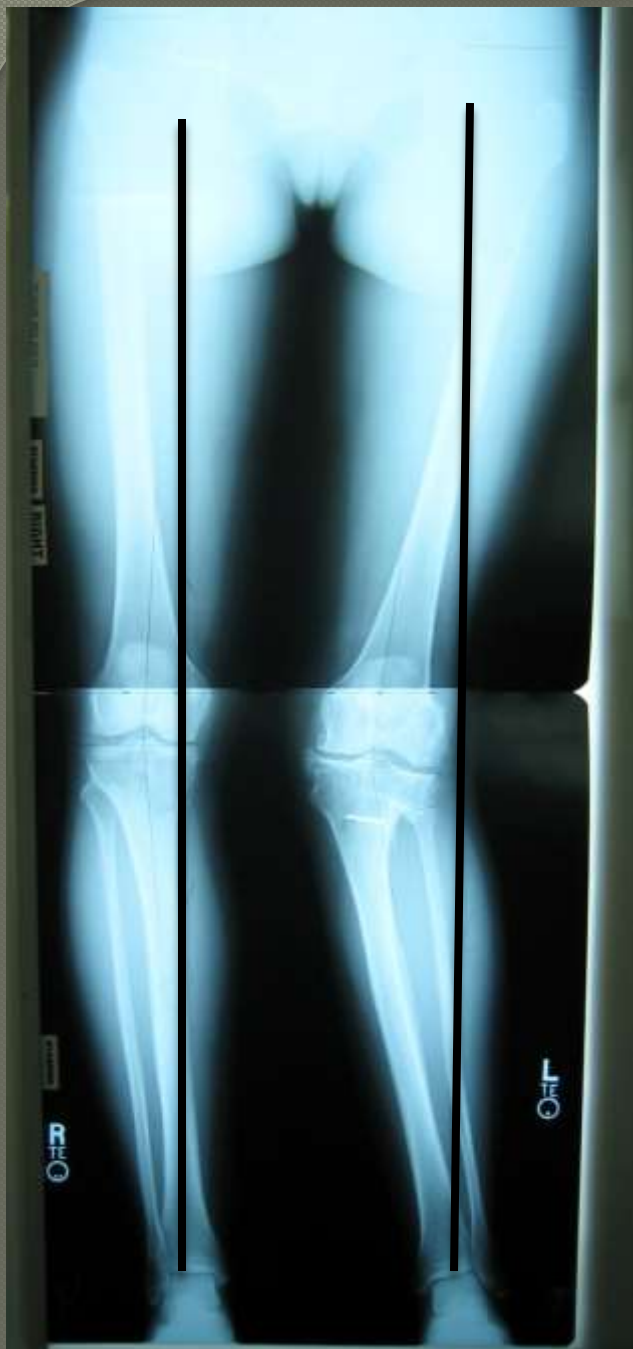The Ilizarov Method

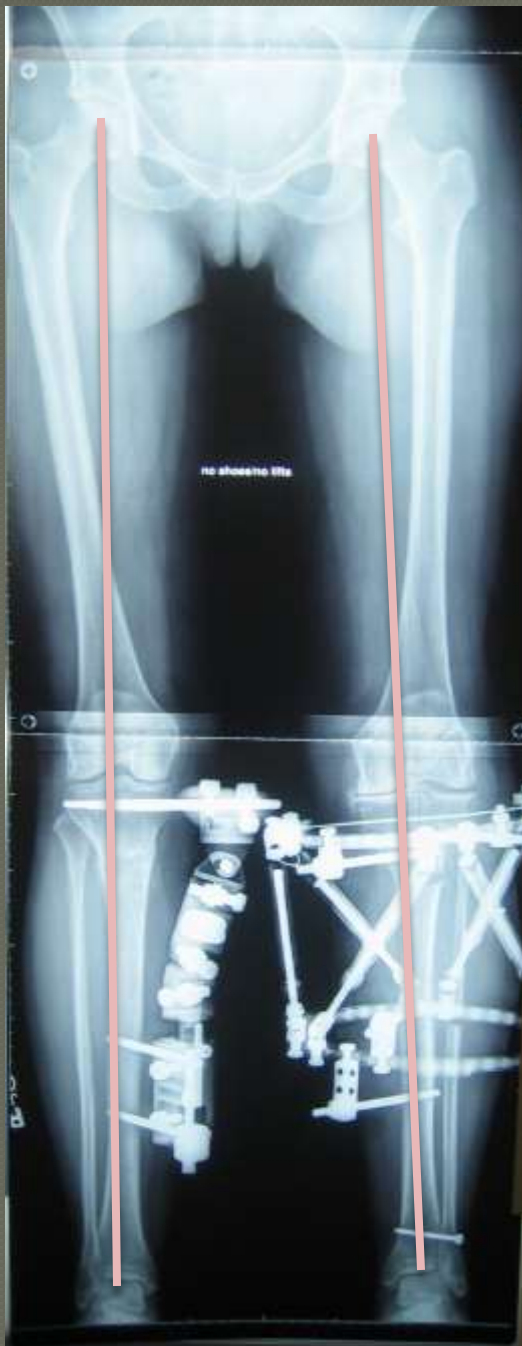- Address all facets of deformity including length
 - Multi-level treatments
- **Comprehensive treatment of tibial nonunion and malunion**
- Gradual correction
 - Less traumatic
 - Patient feedback for position
 - Less risk of NV insult
- **Minimally invasive exposure**
- Weight bearing is allowed
- **Infection- no internal hardware**

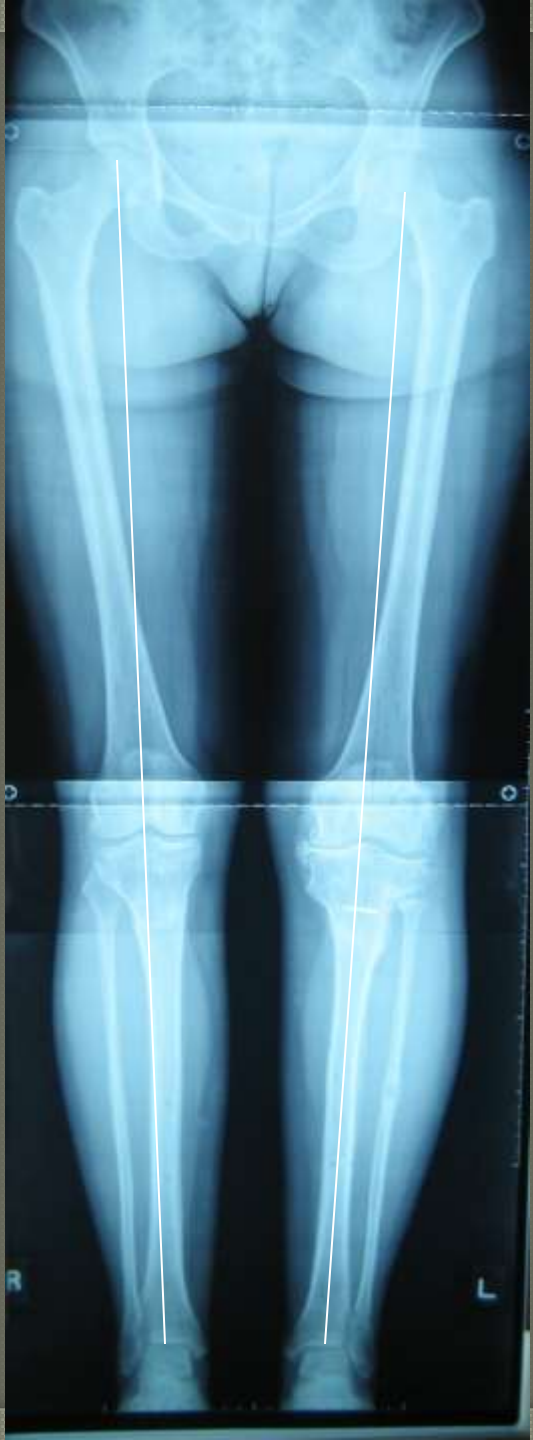

Realignment Osteotomy



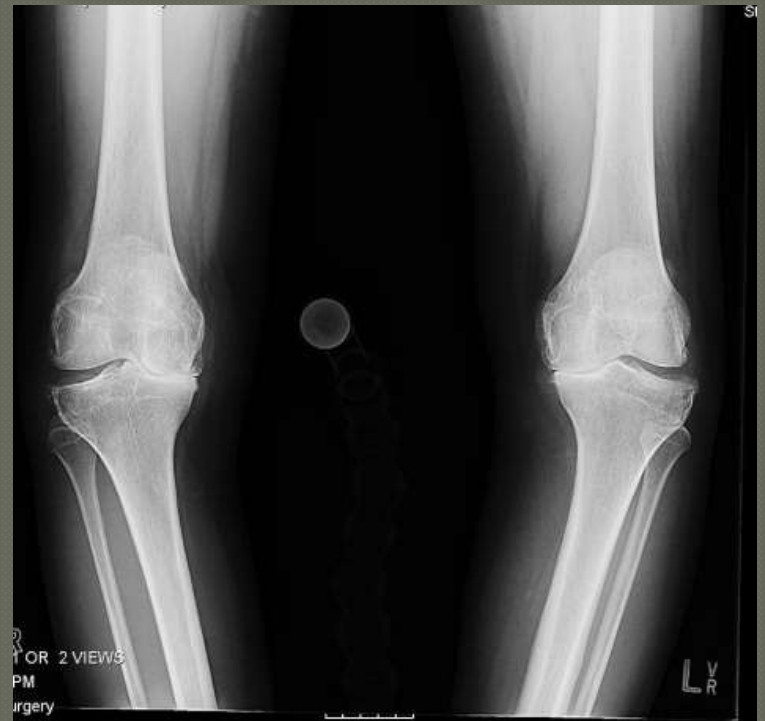
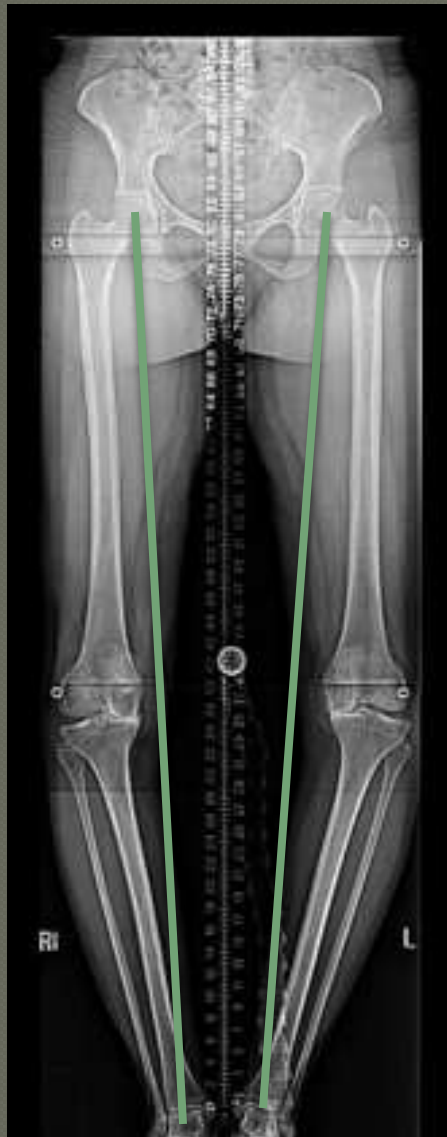
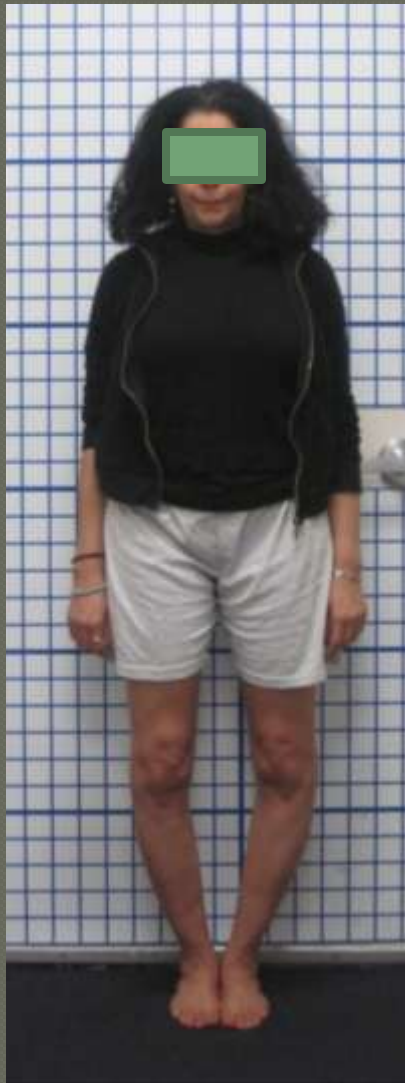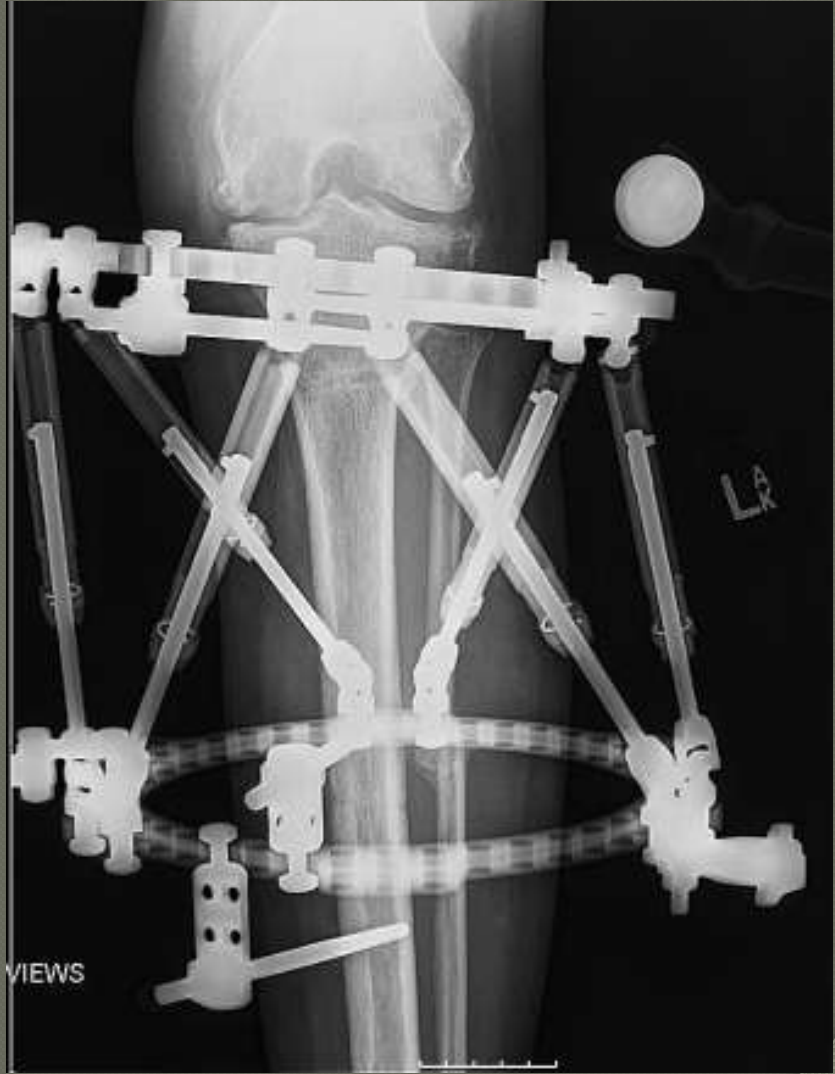



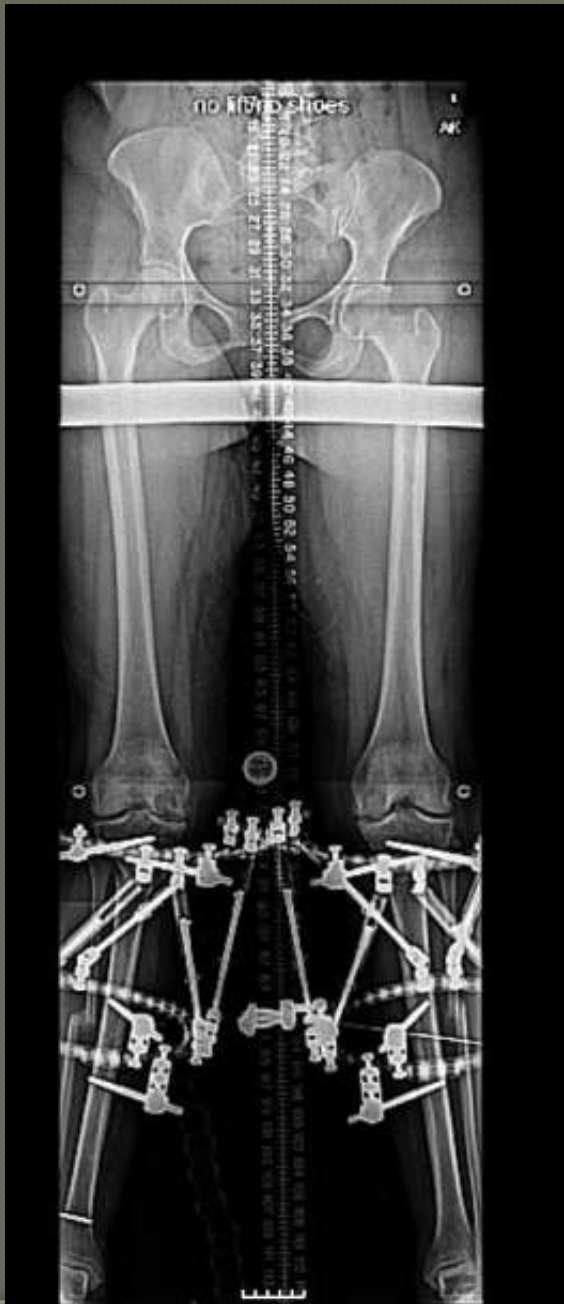


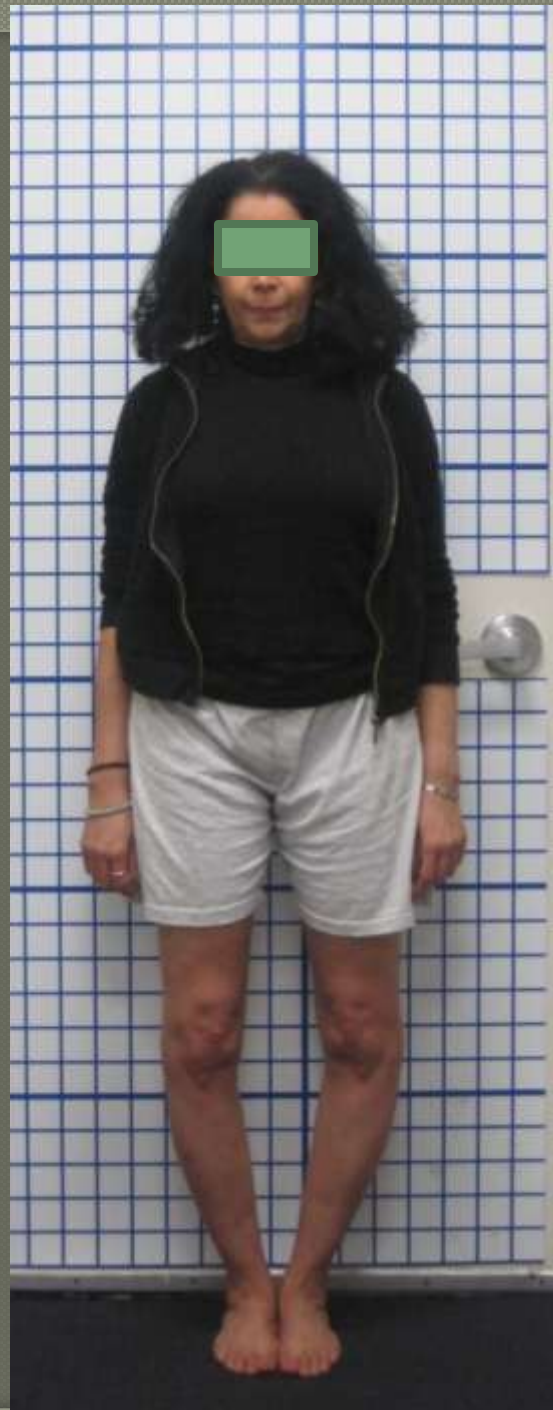


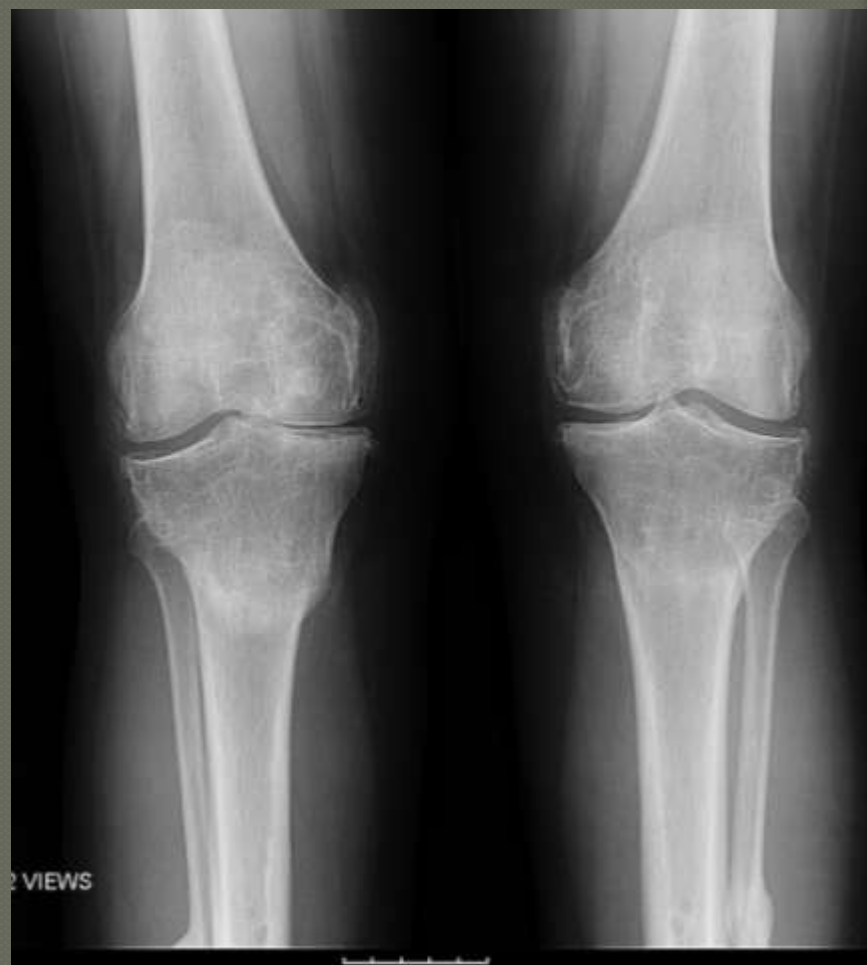
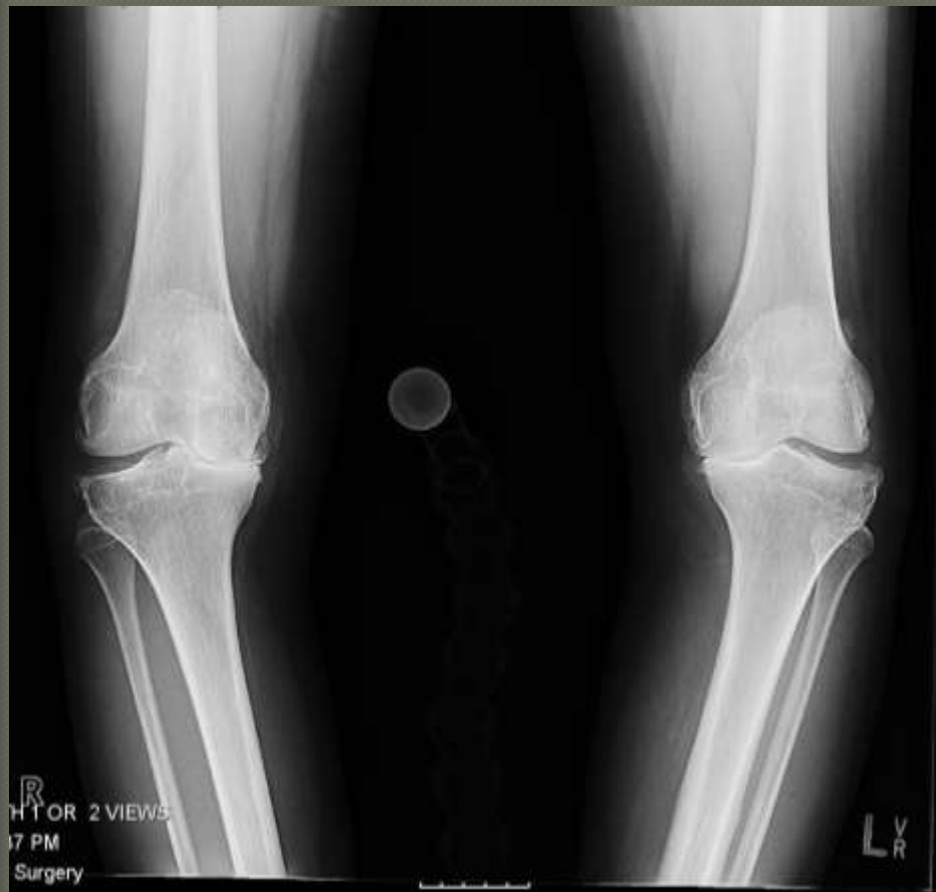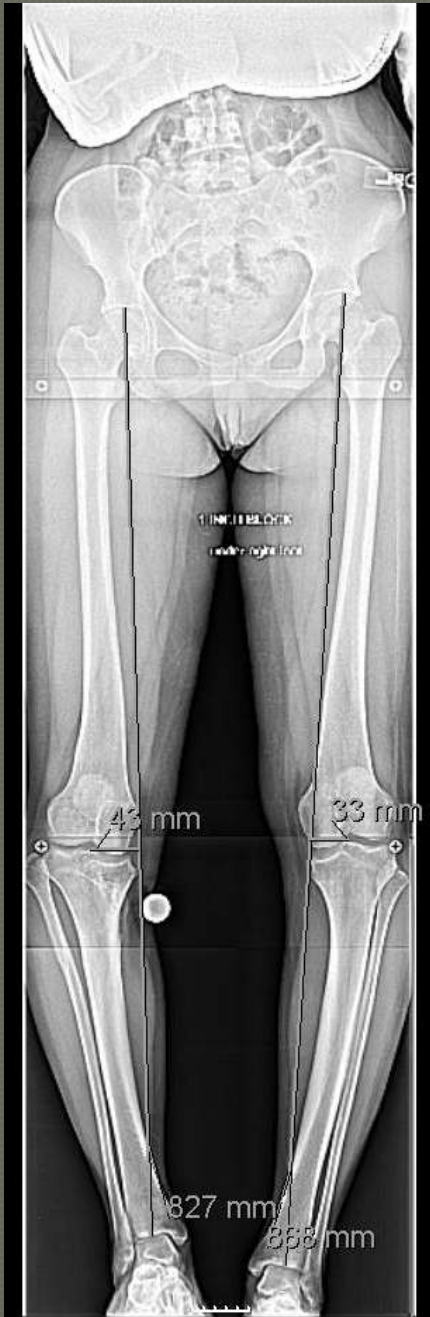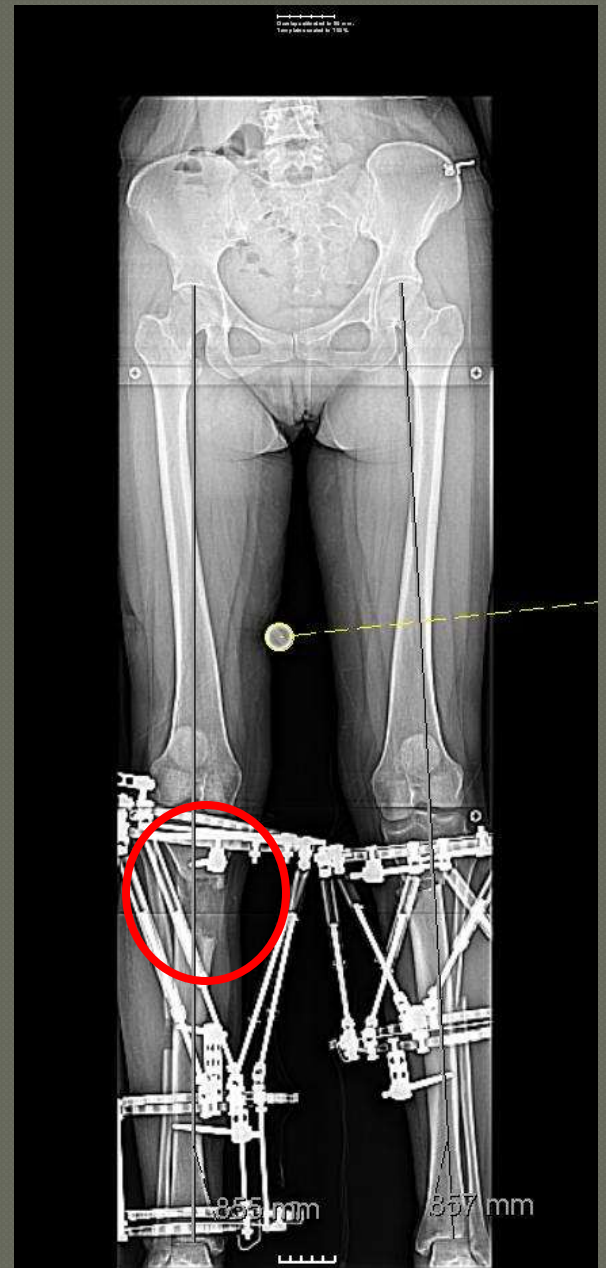








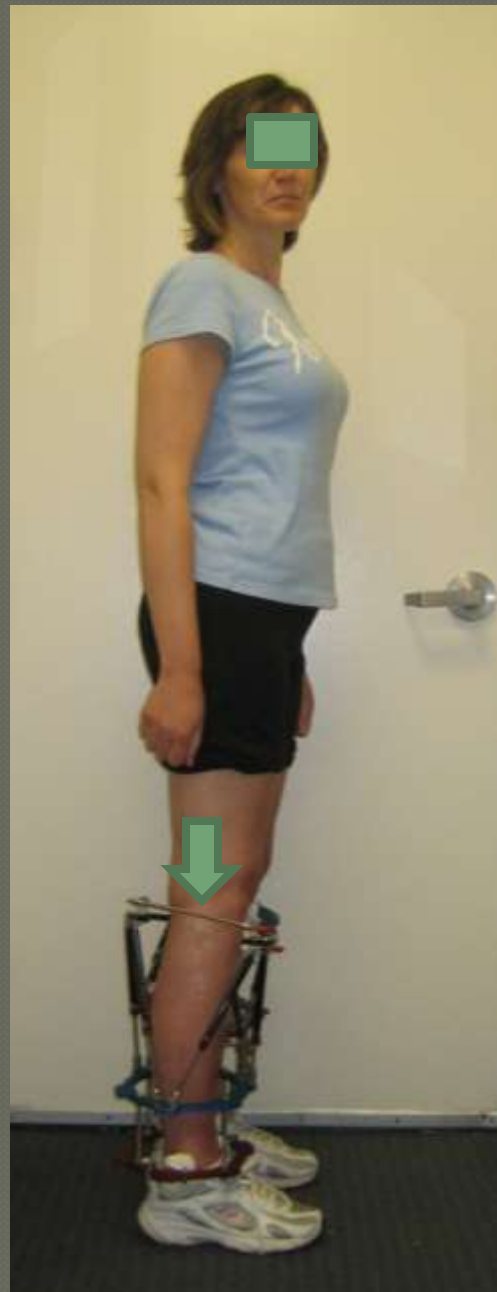
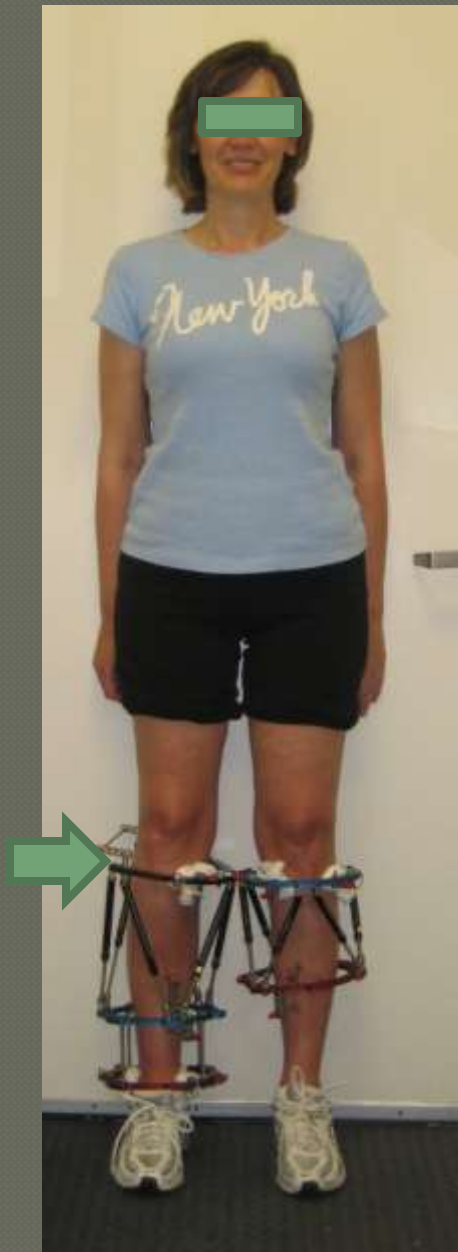


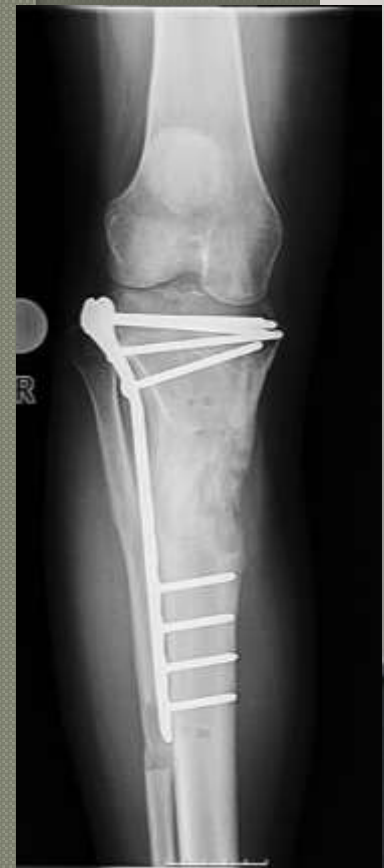
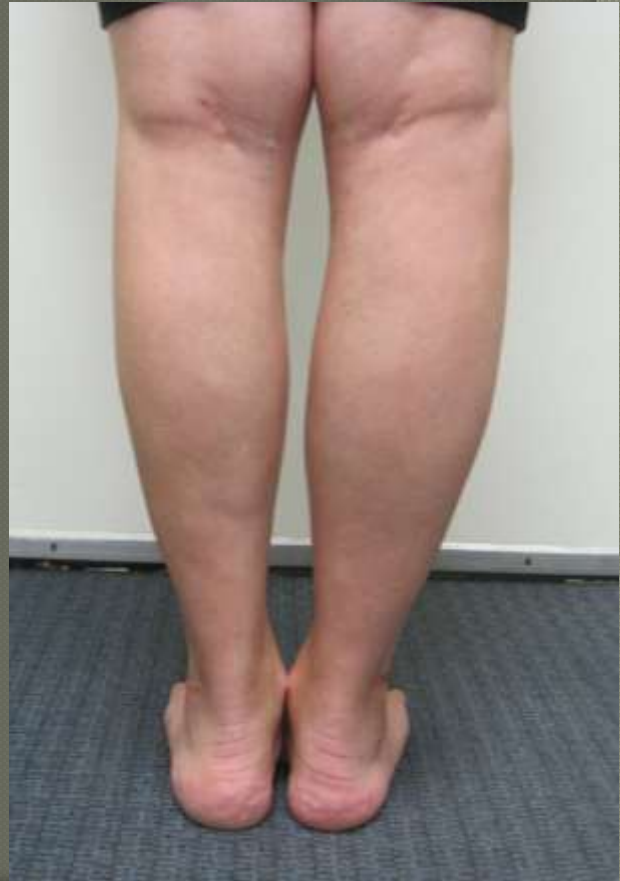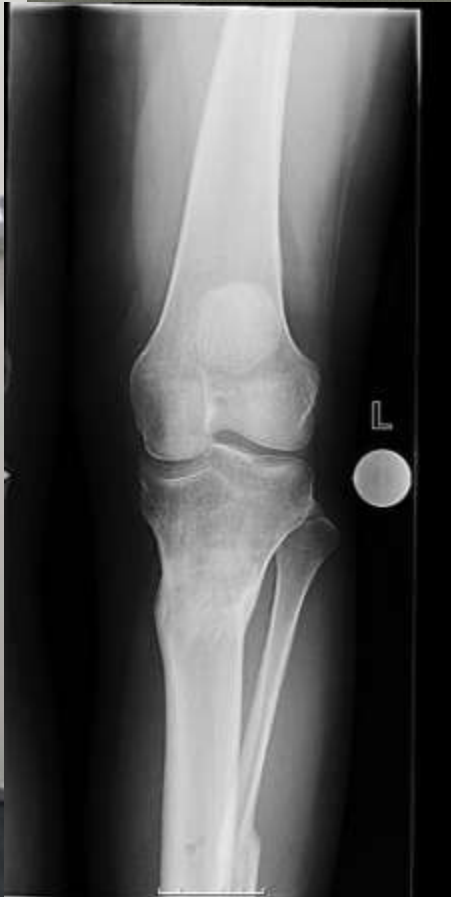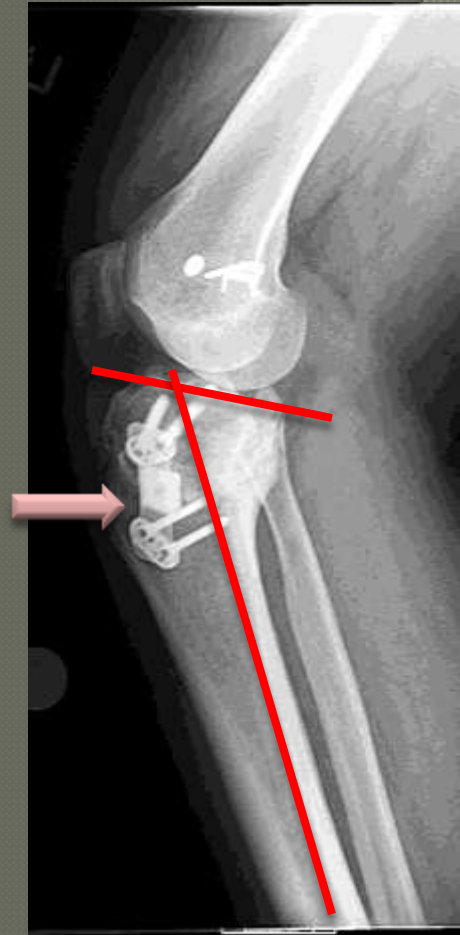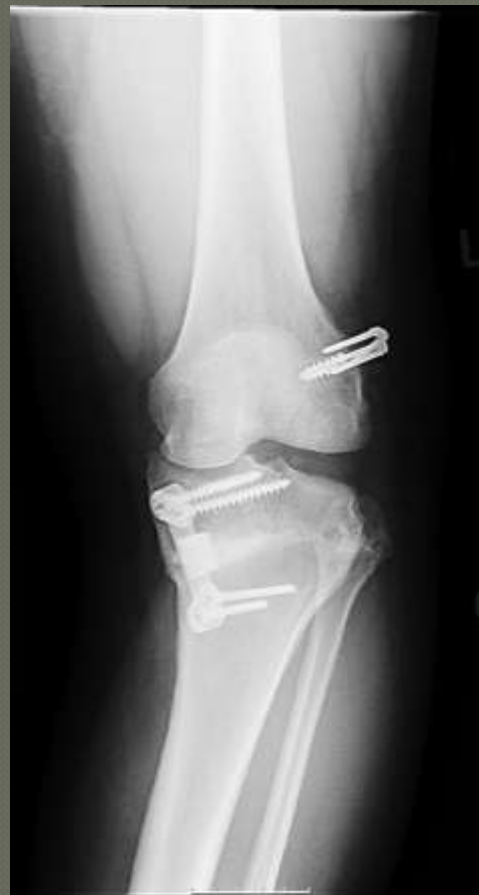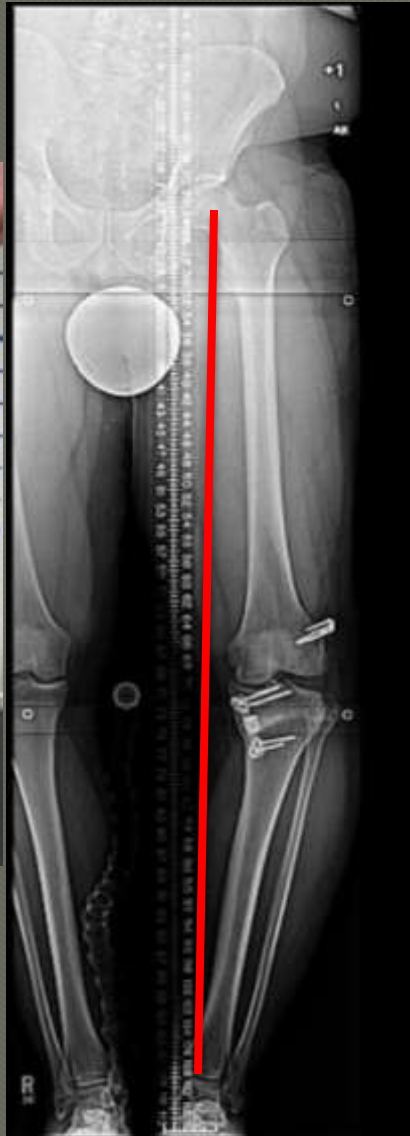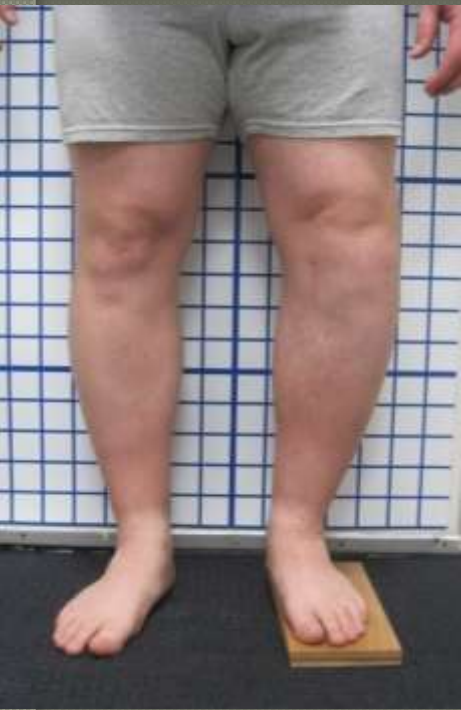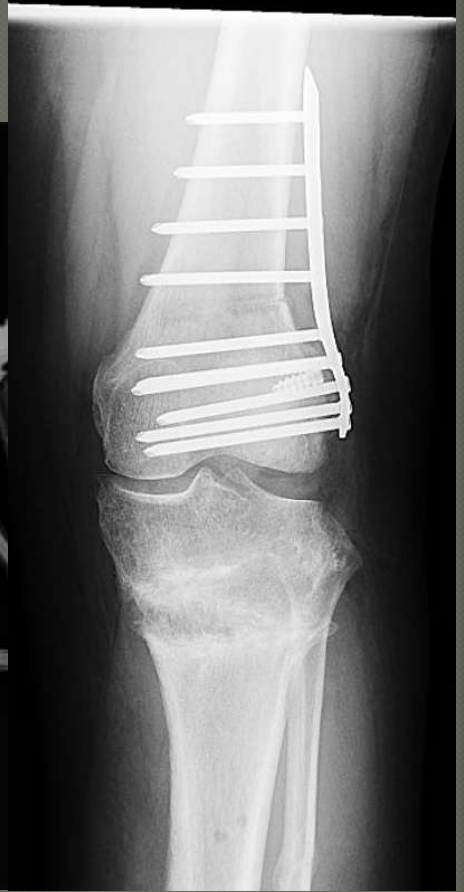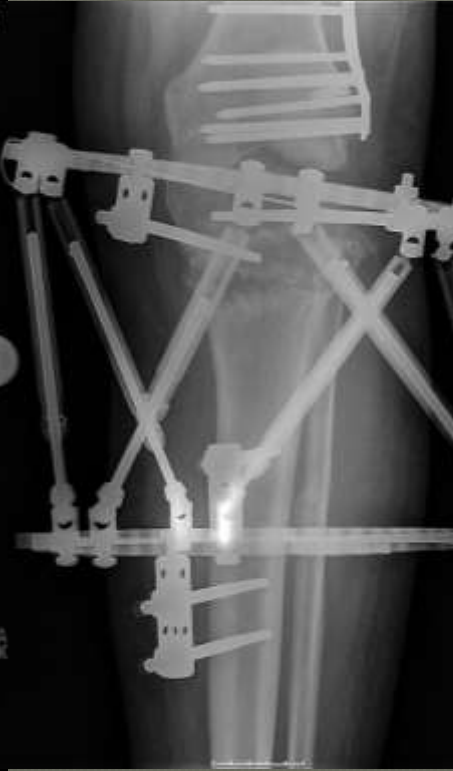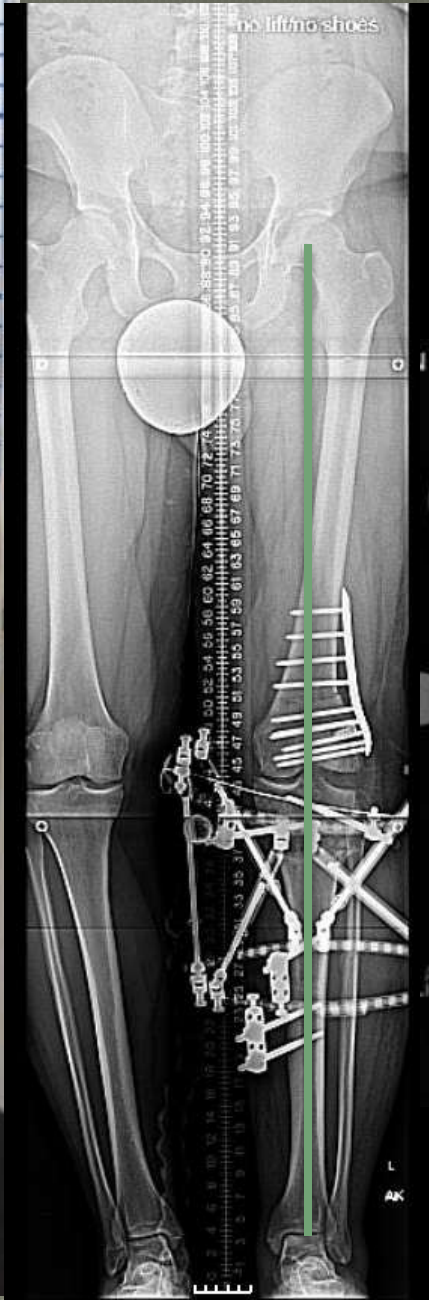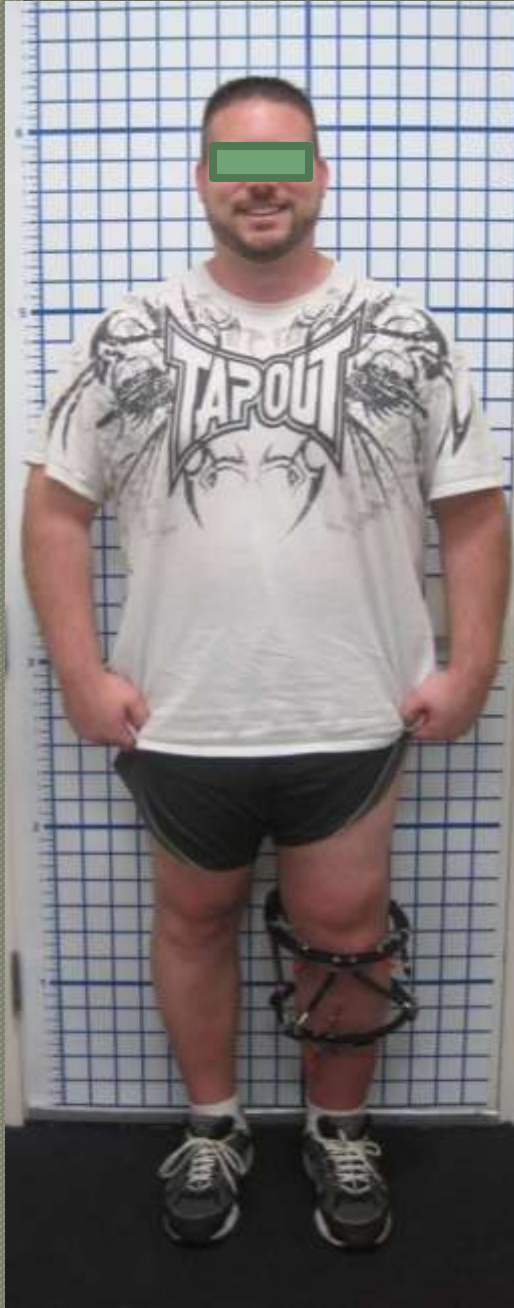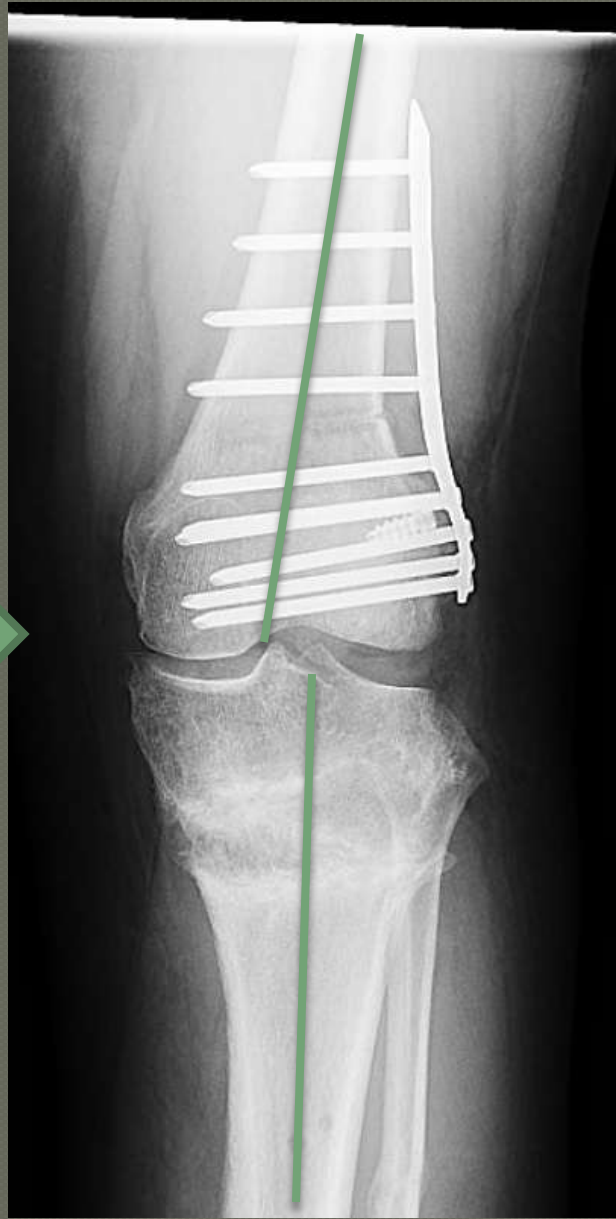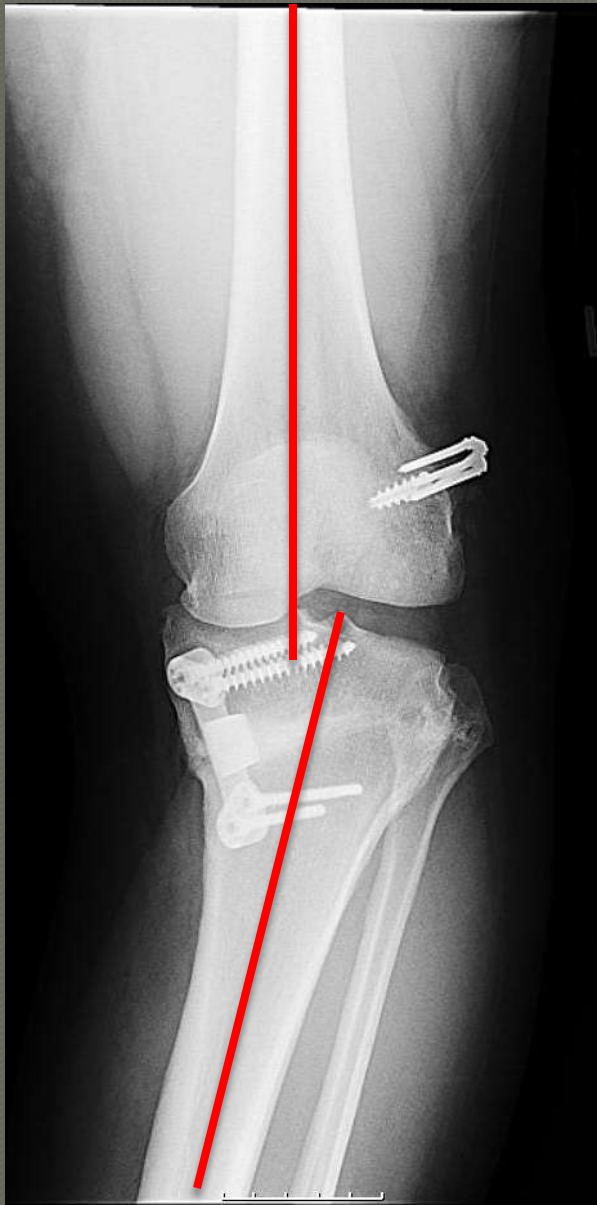




35 year old, femur + tibial deformity, LCL laxity, LLD, ACL laxity

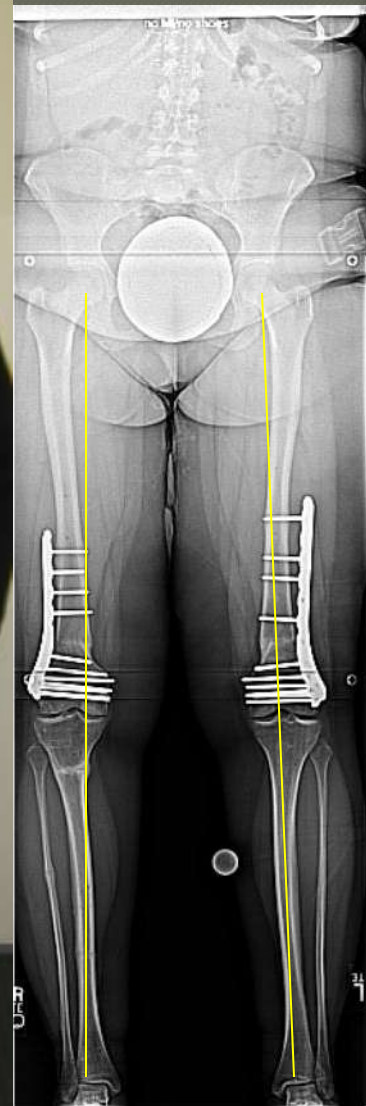
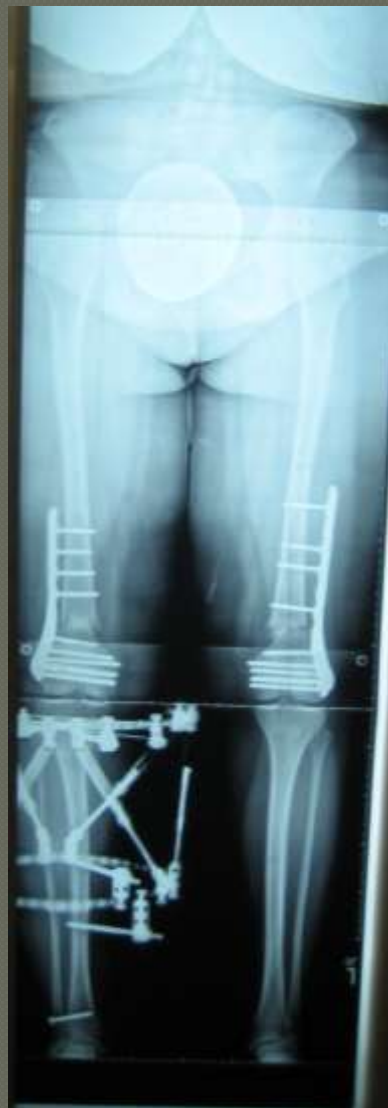
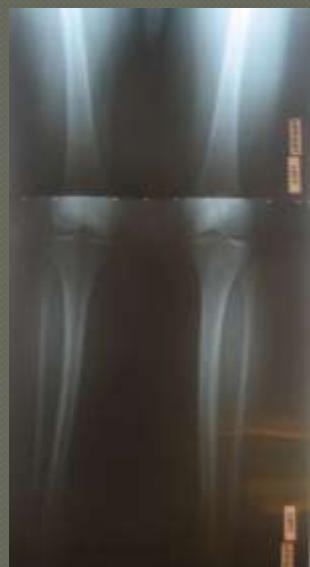






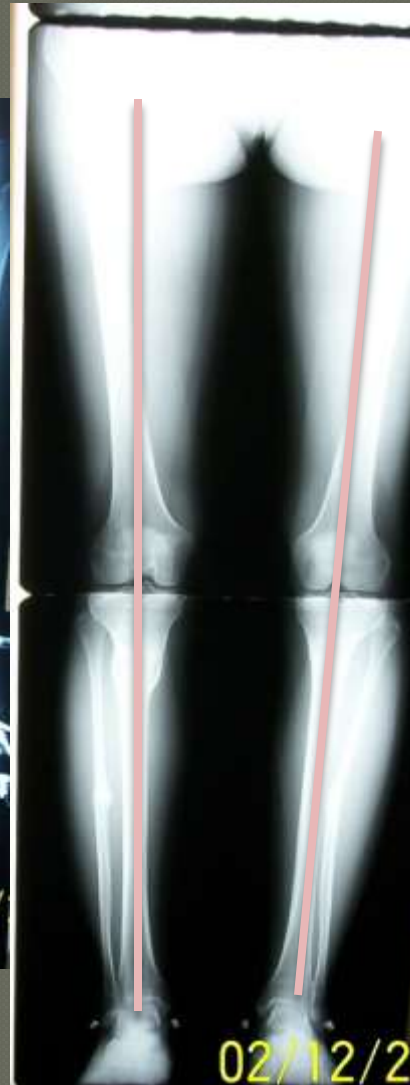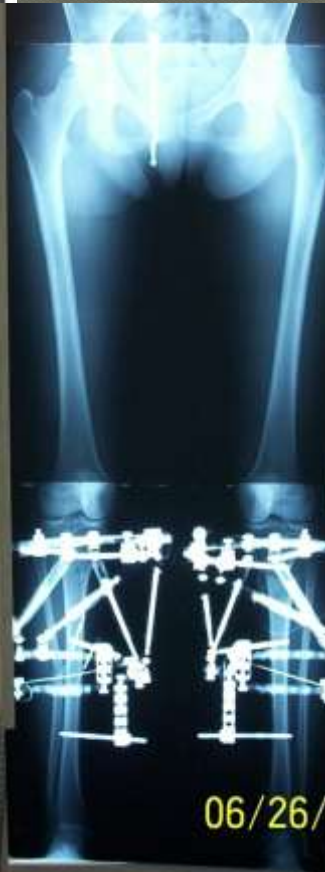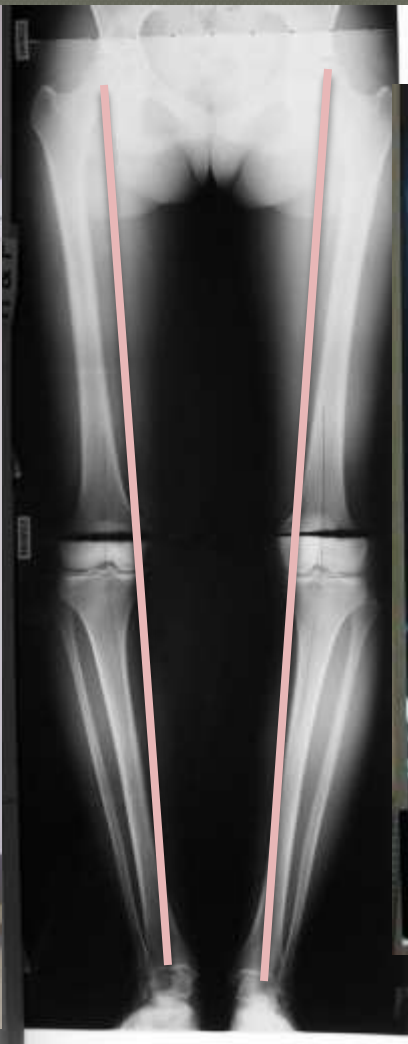25 y/o, valgus, knee pain, lat compt DJD on scope, femur +tibia



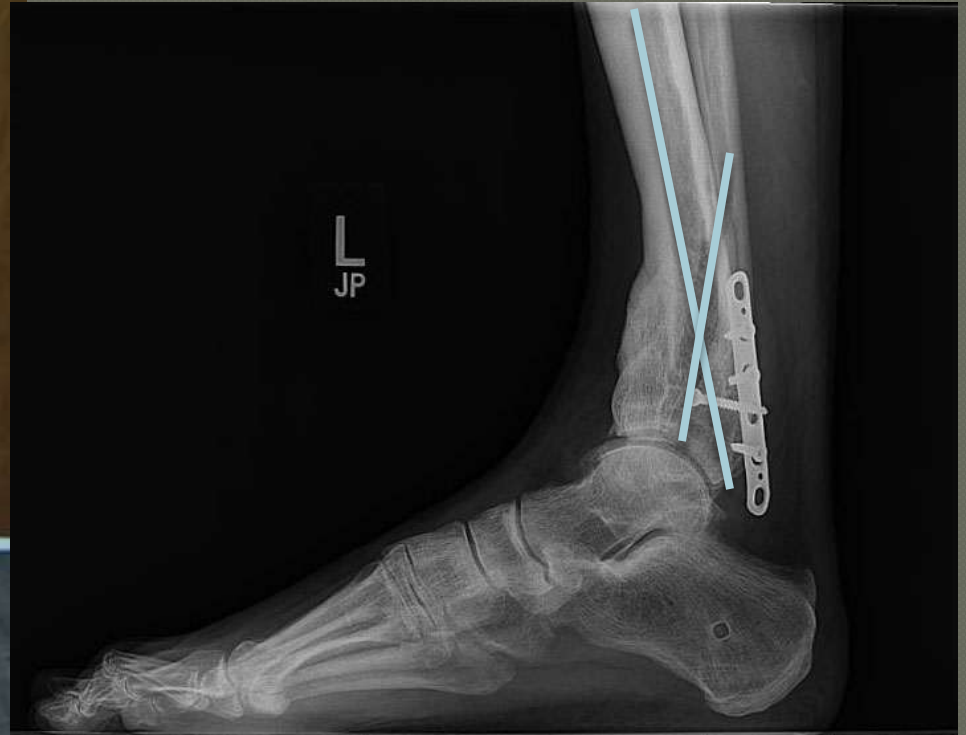
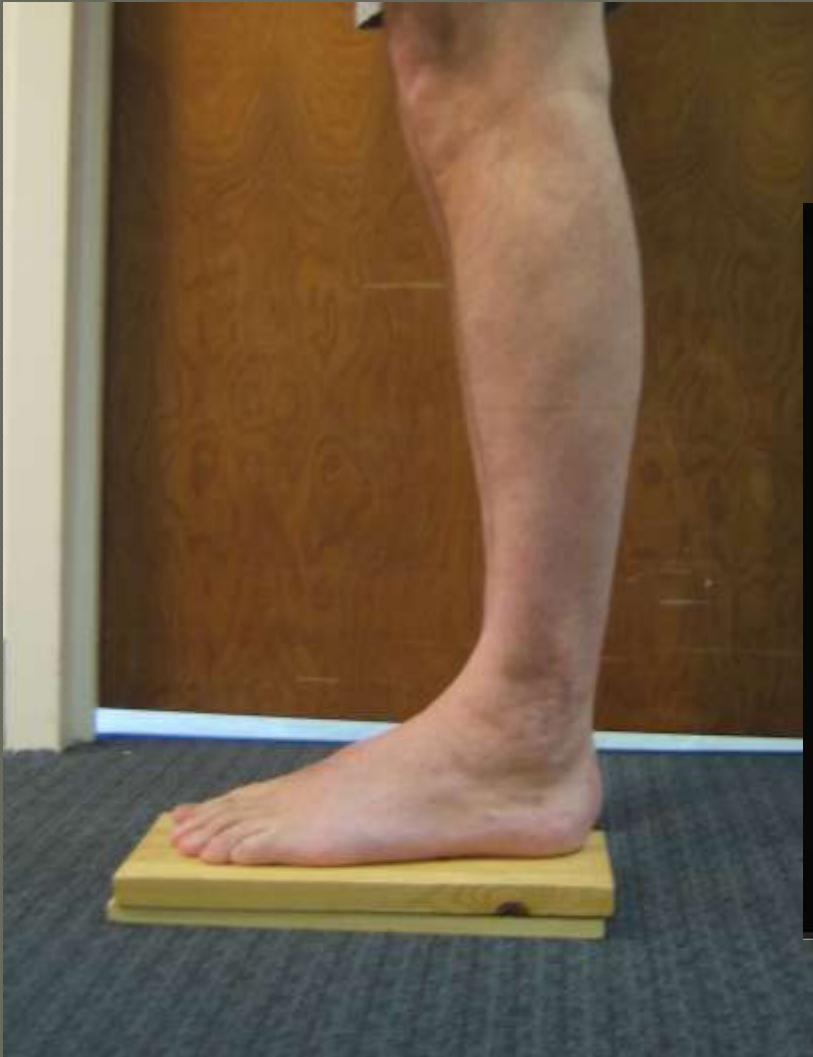
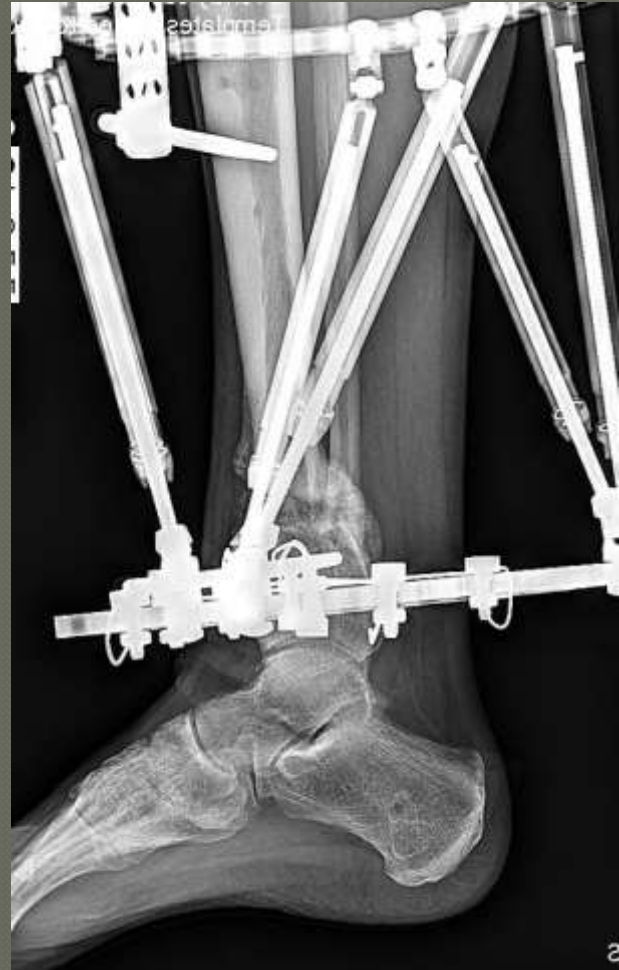
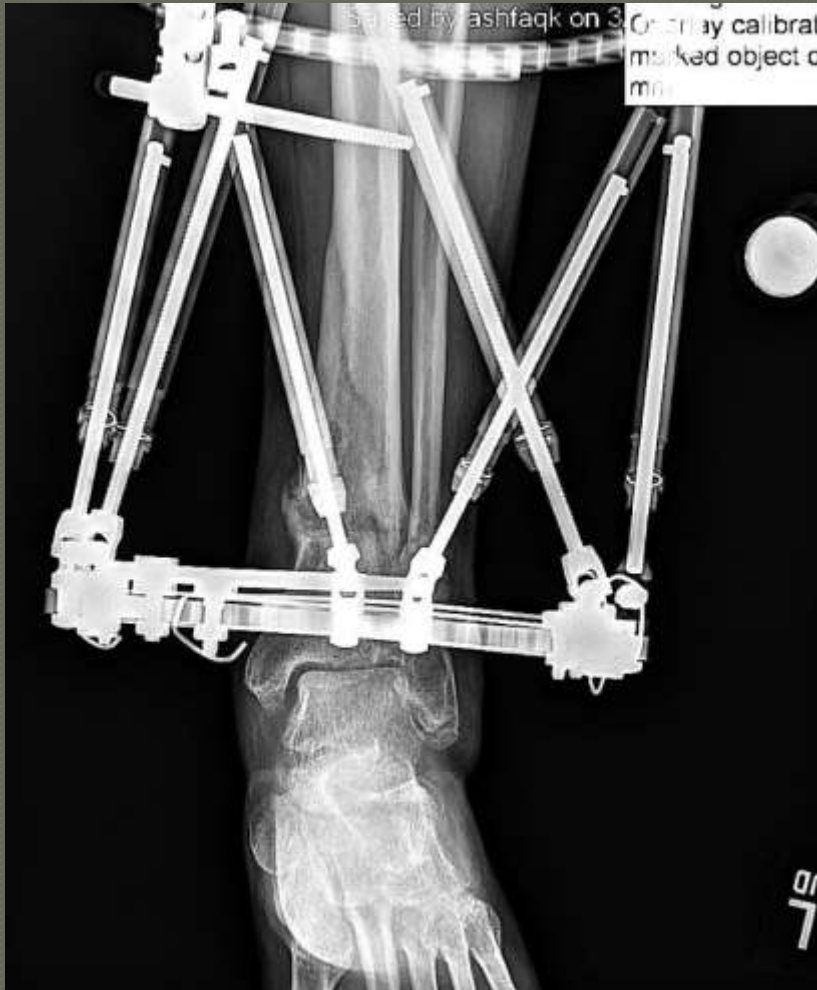25 year old: This should last forever too!!!!?????

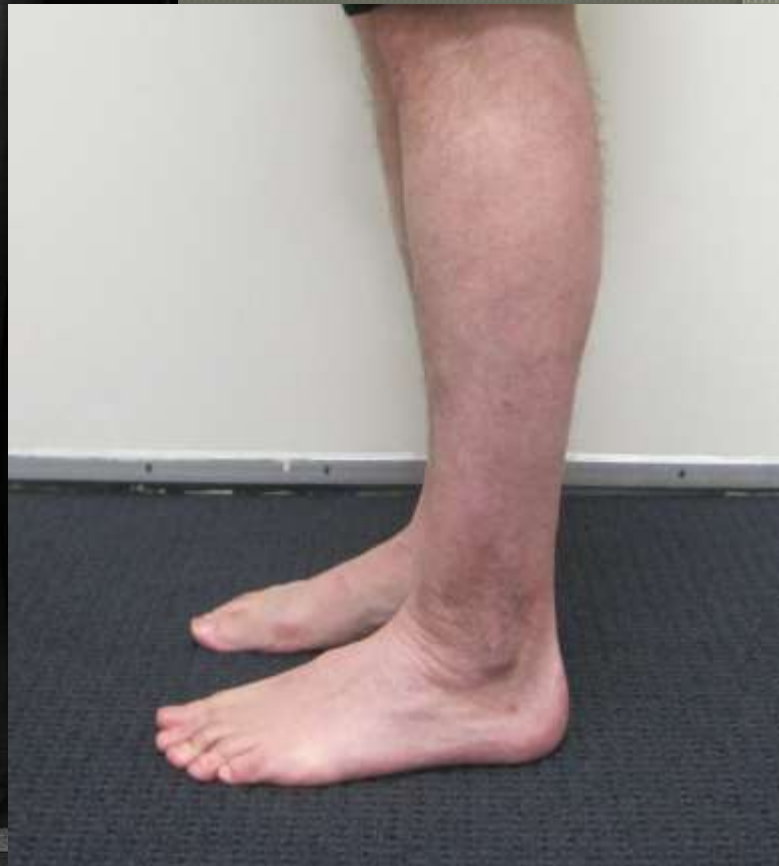
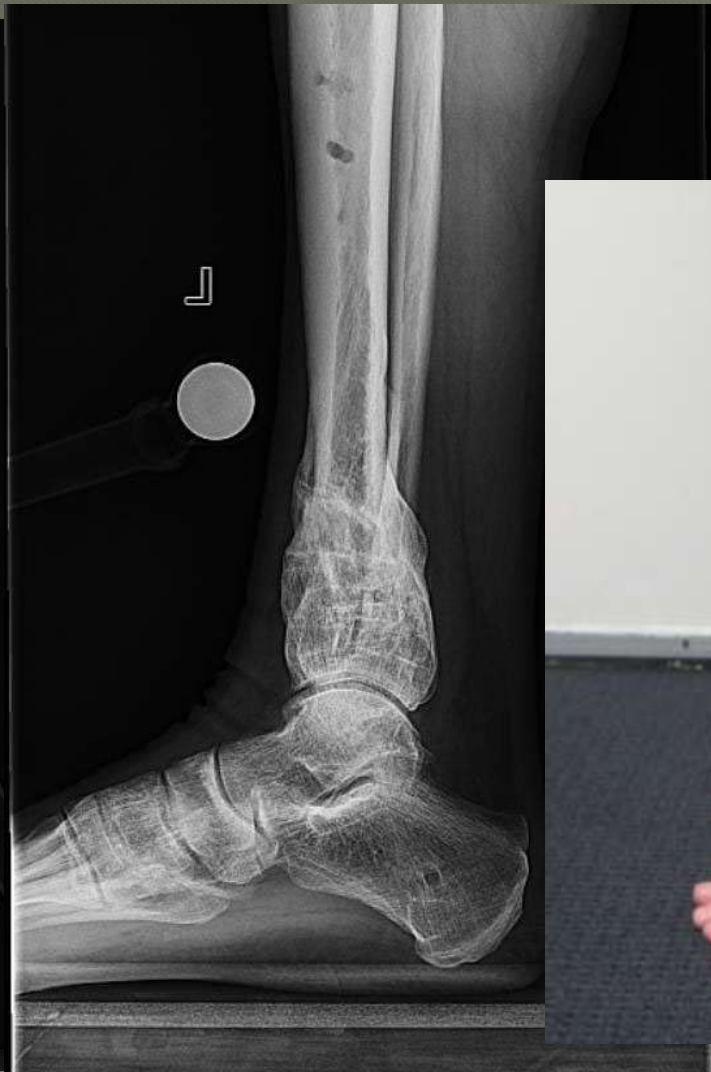
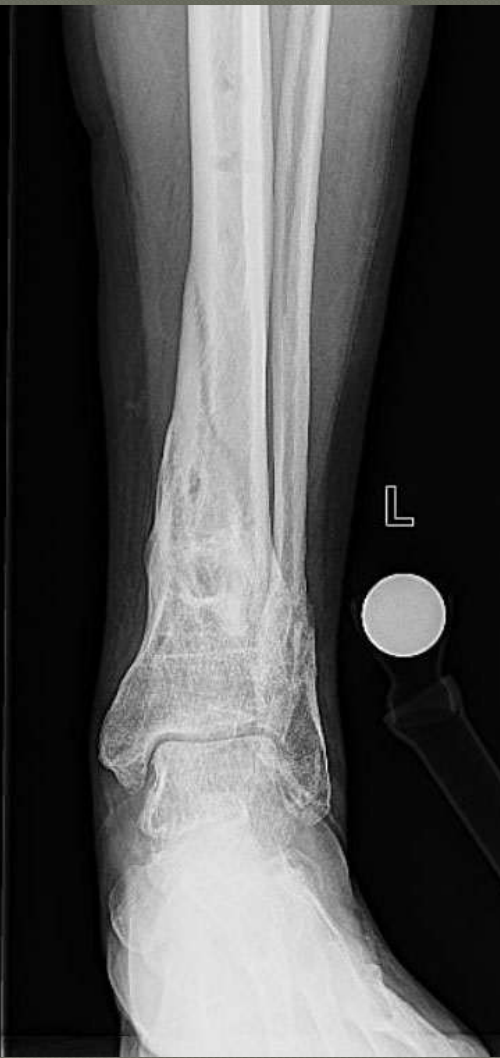

Recurvatum







Future of joint reconstruction and joint preservation

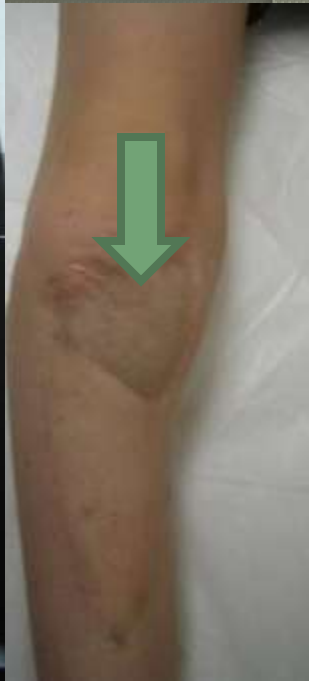
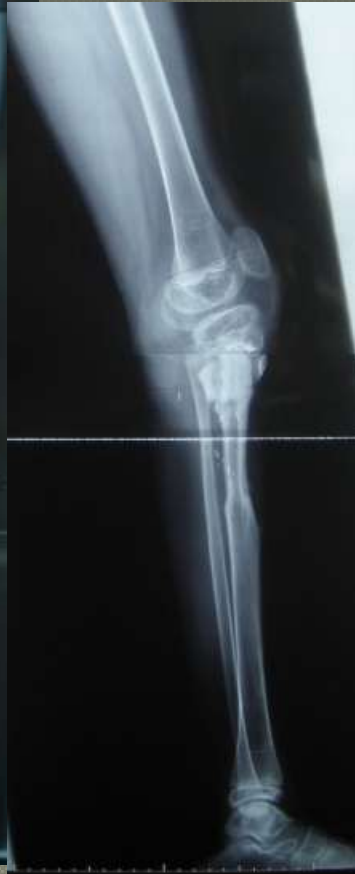
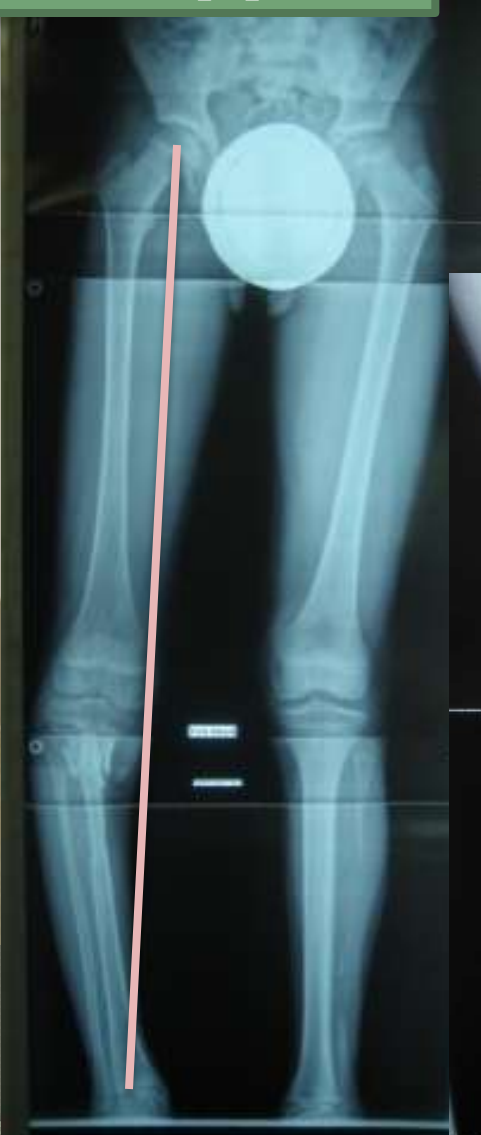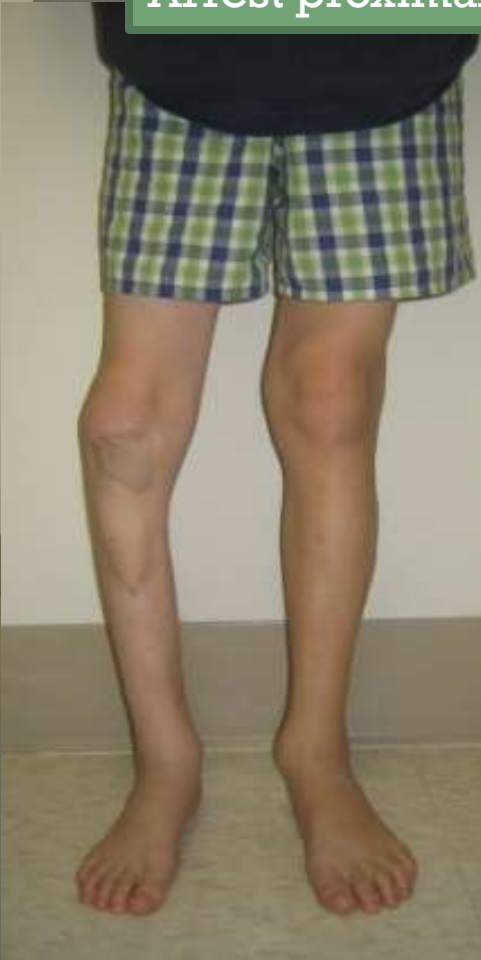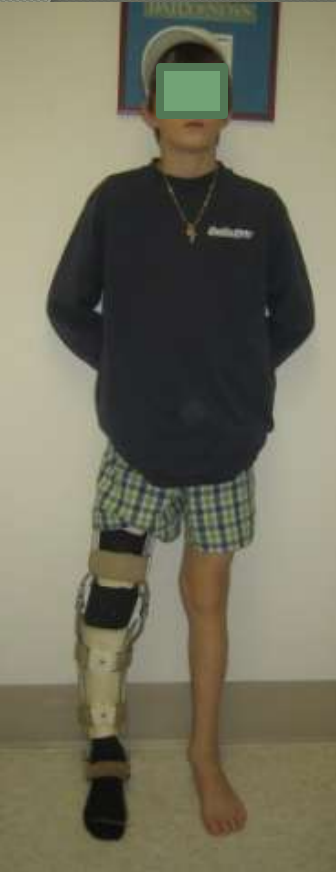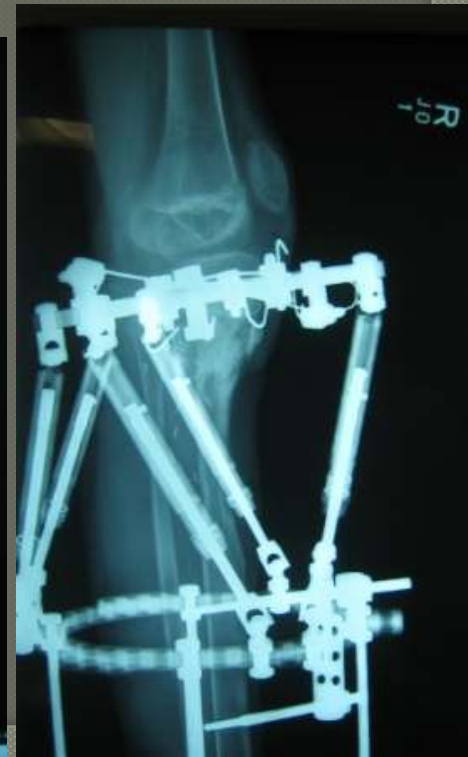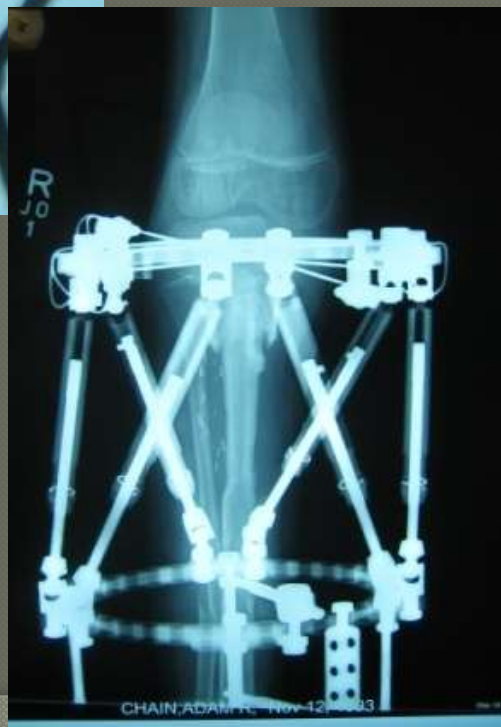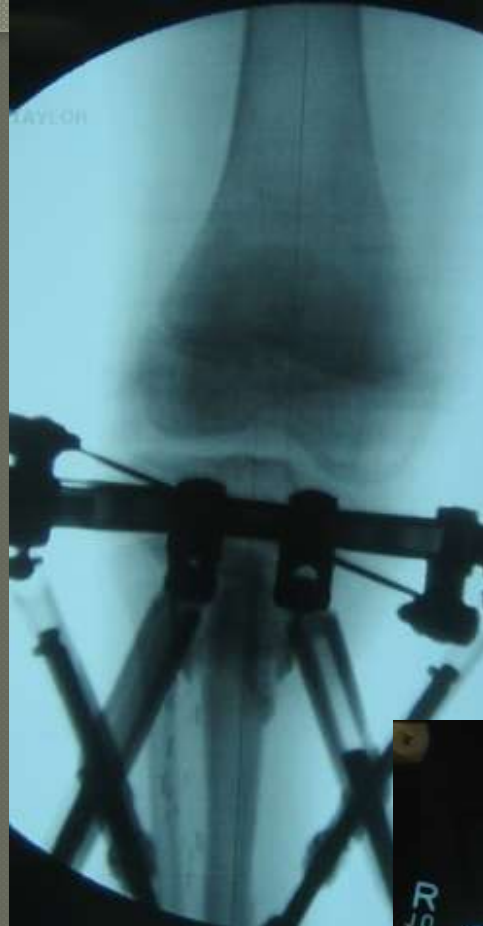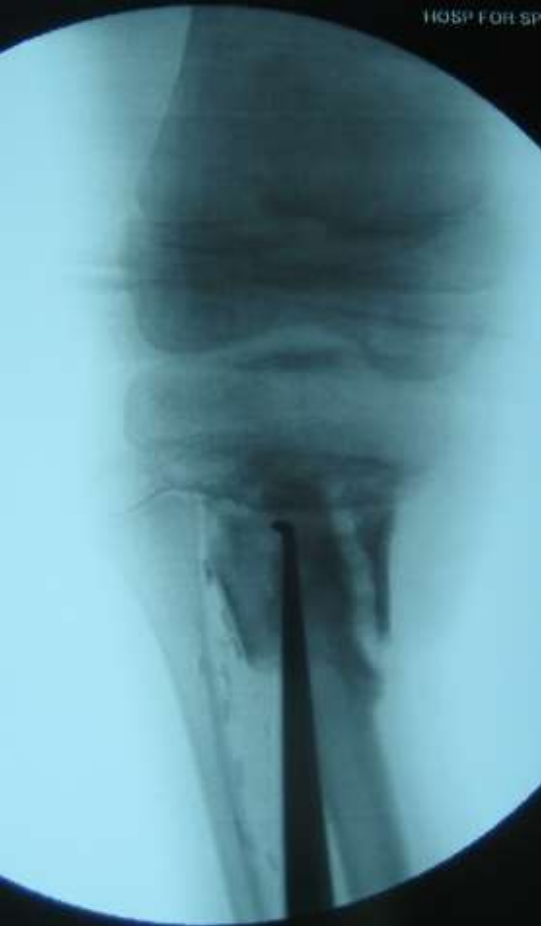- ◎ Biological solutions
- ◎ Mechanical principles

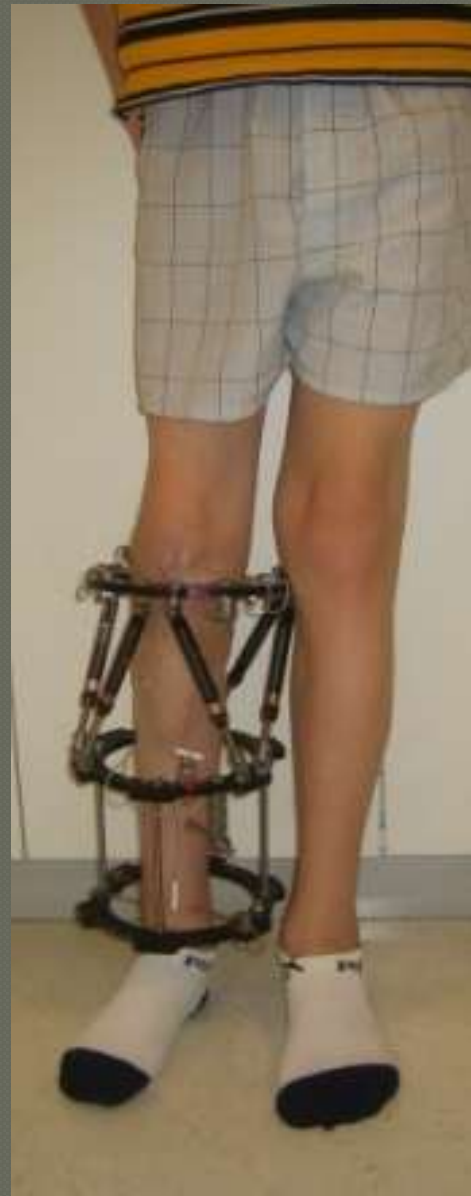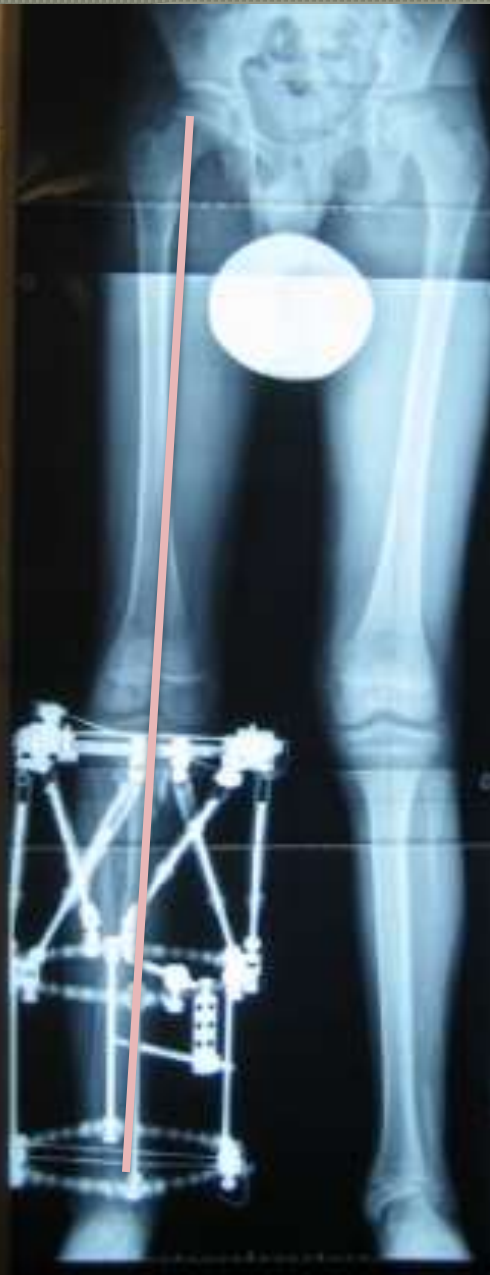- *“You can’t cheat the laws of physics”*

12 y/o, sarcoma excision prox tibia
Reconstructed with free fibula.
Nonunion, varus deformity, growth
Arrest proximal tibia, flap-poor skin

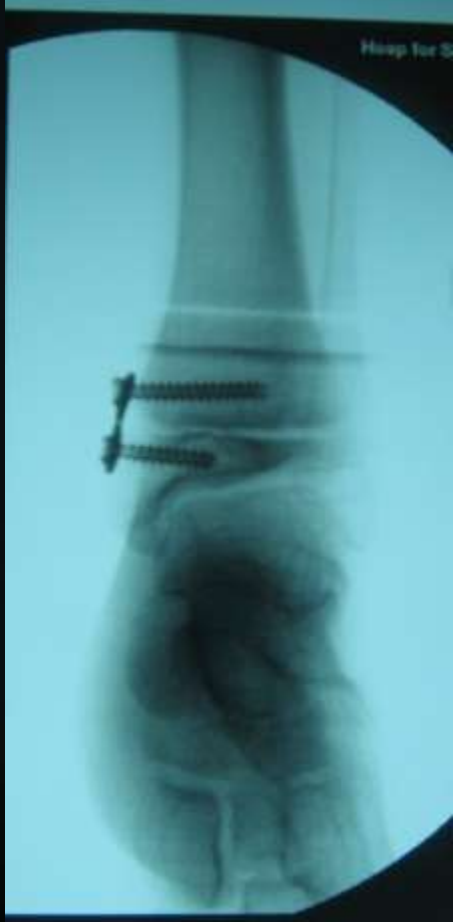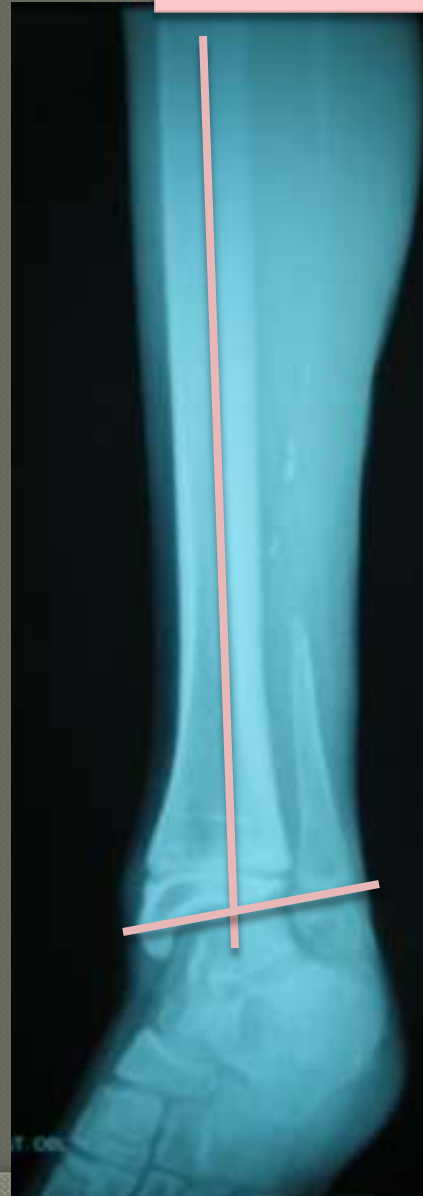R, L tibia 300mm
M=1.18
 $300 \times 1.18 = 354$
 $354 - 300 = 54$ mm
 $54 \text{ mm} \times 60\% = 33$ mm

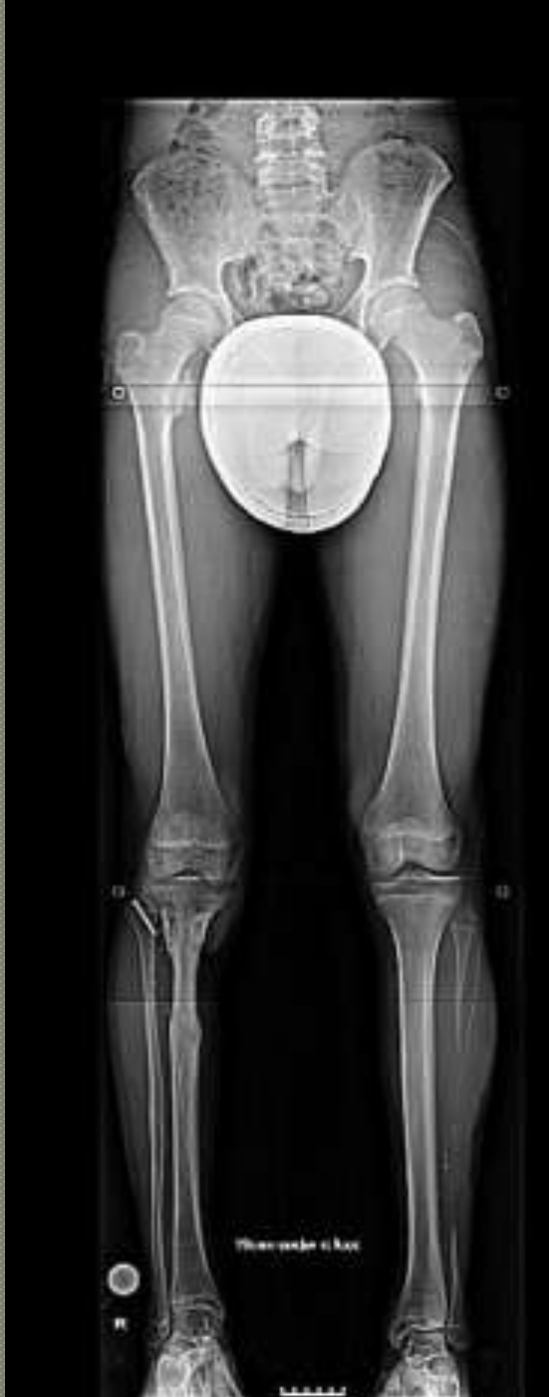





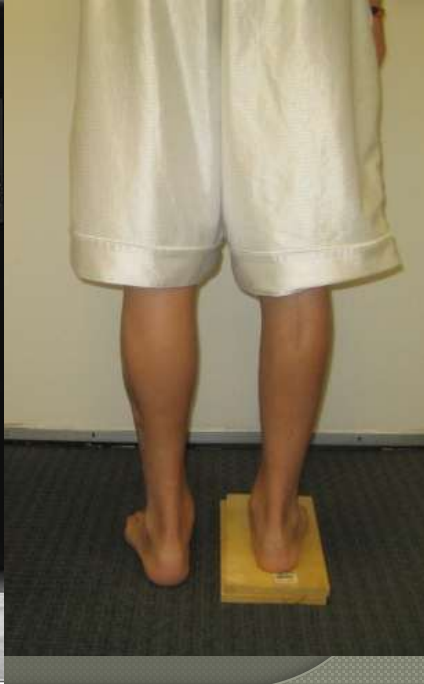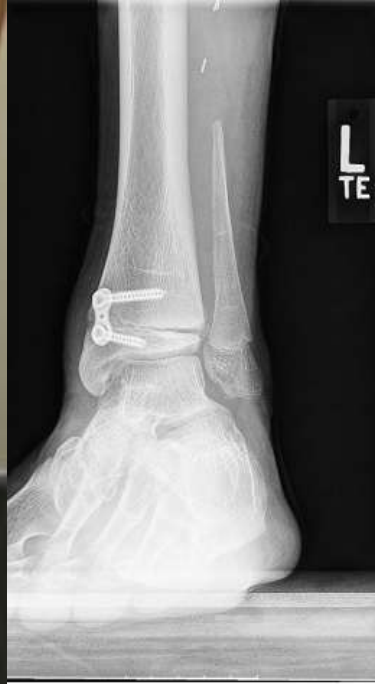L ankle valgus from free fibula
Donor site

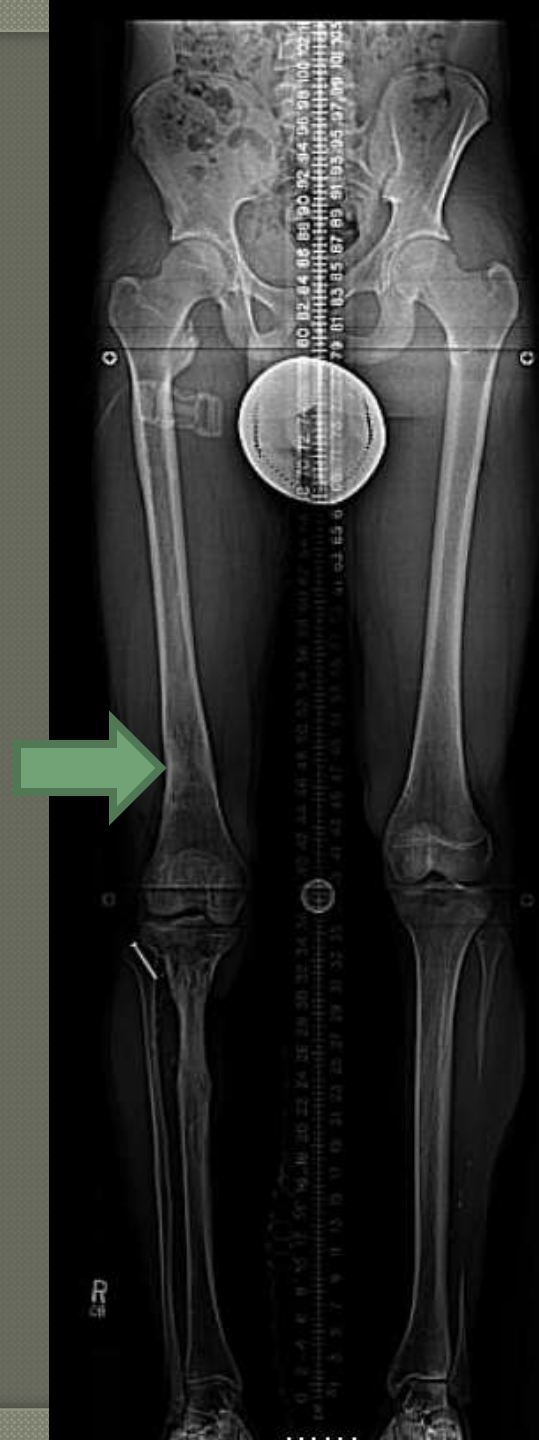
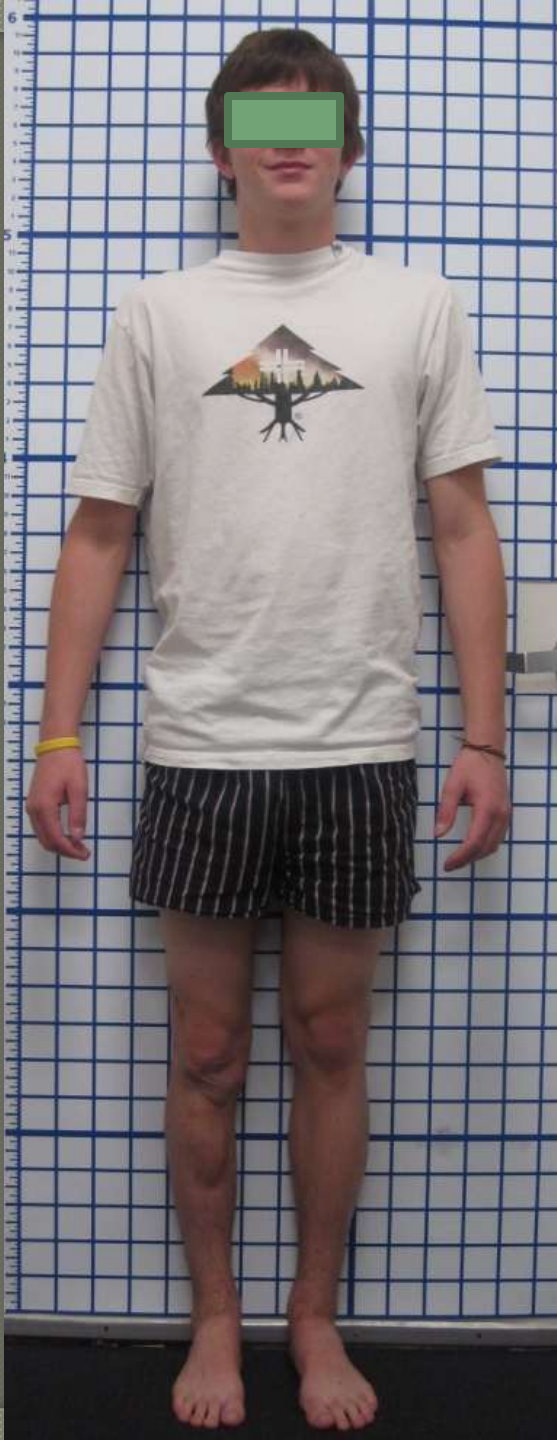



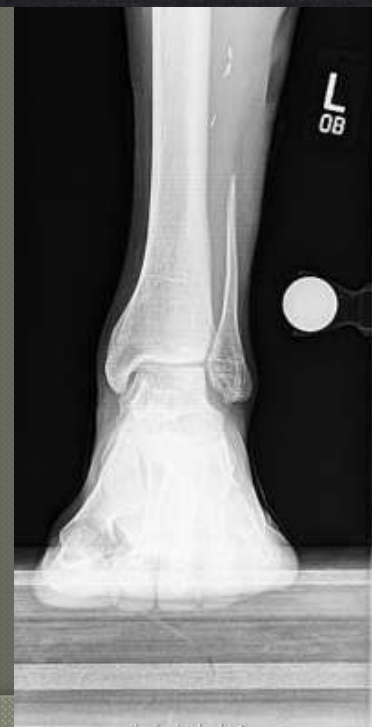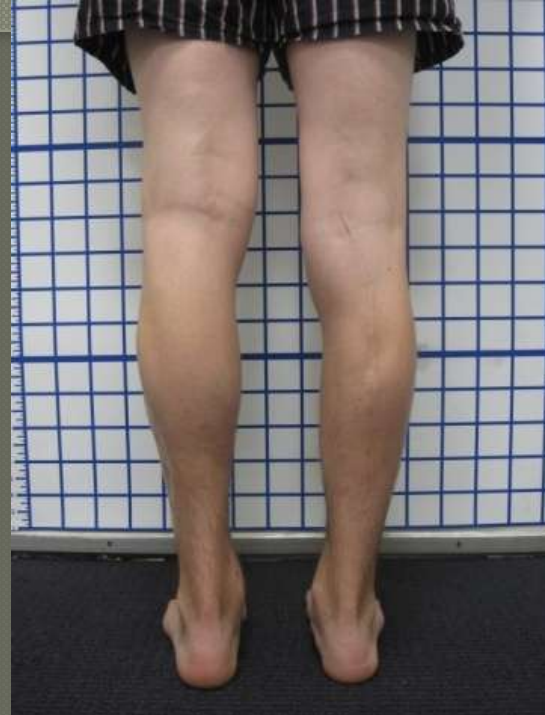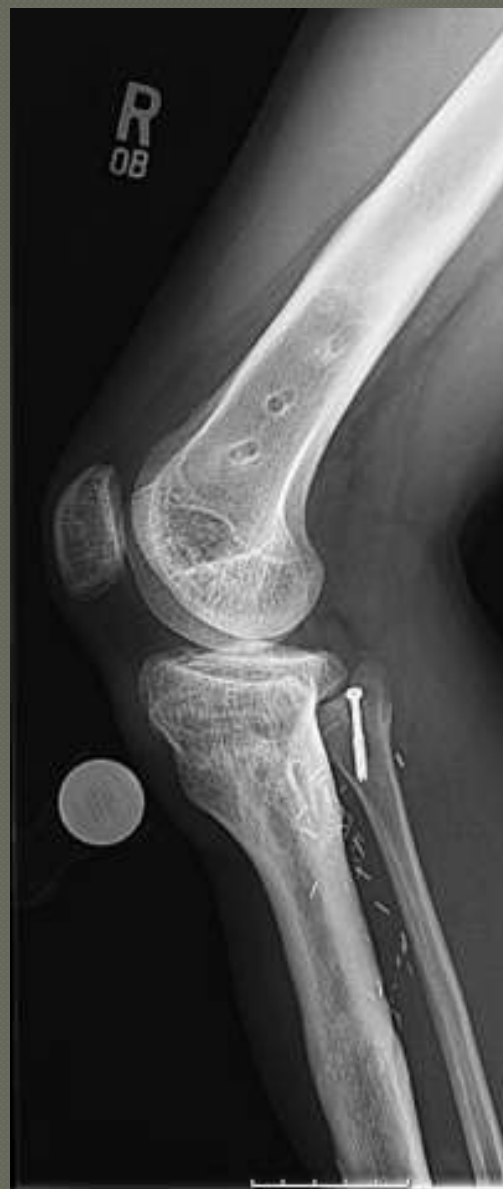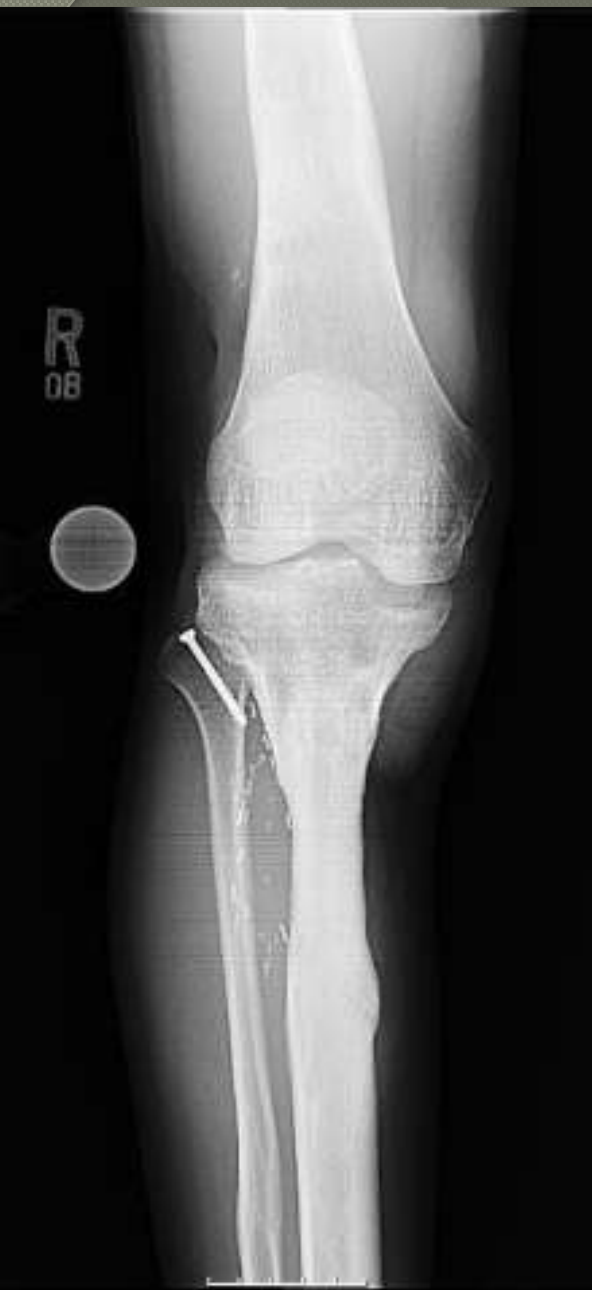Age 15.5
L ankle straight, R tibia healed.
LLD 3 cm as predicted.

Plan: lengthen femur.
Avoid tibia





Age
17

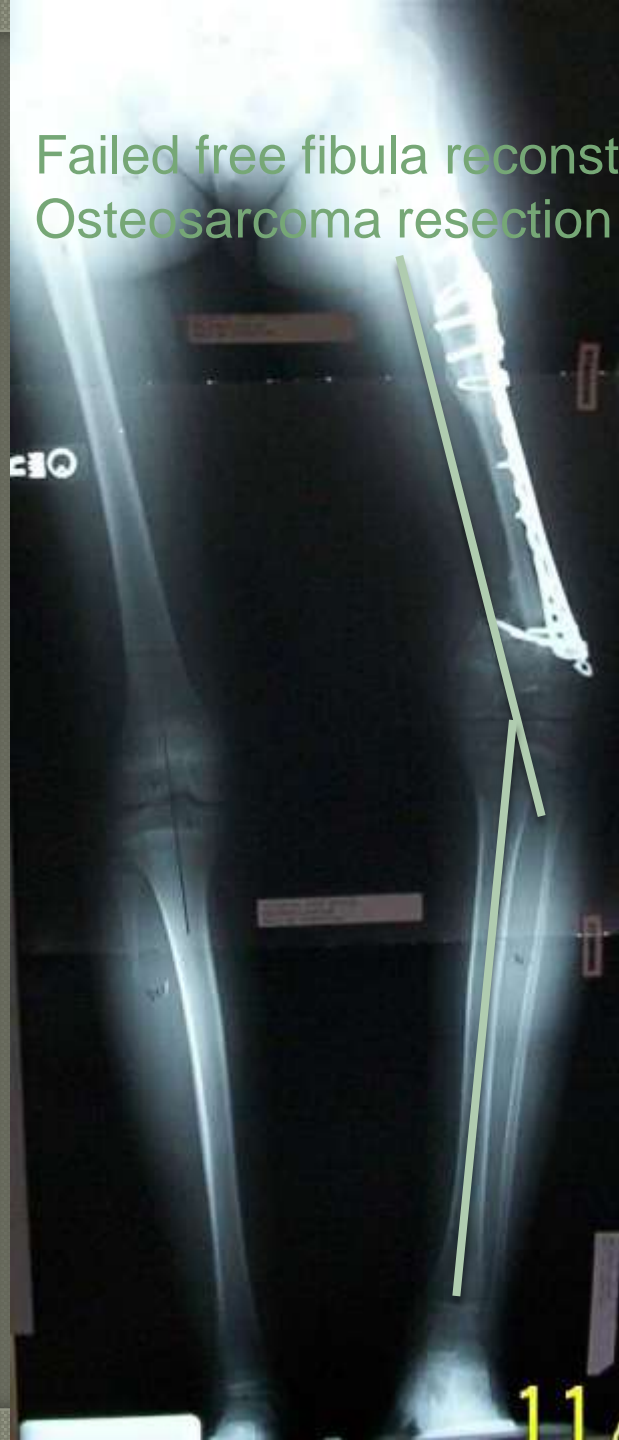


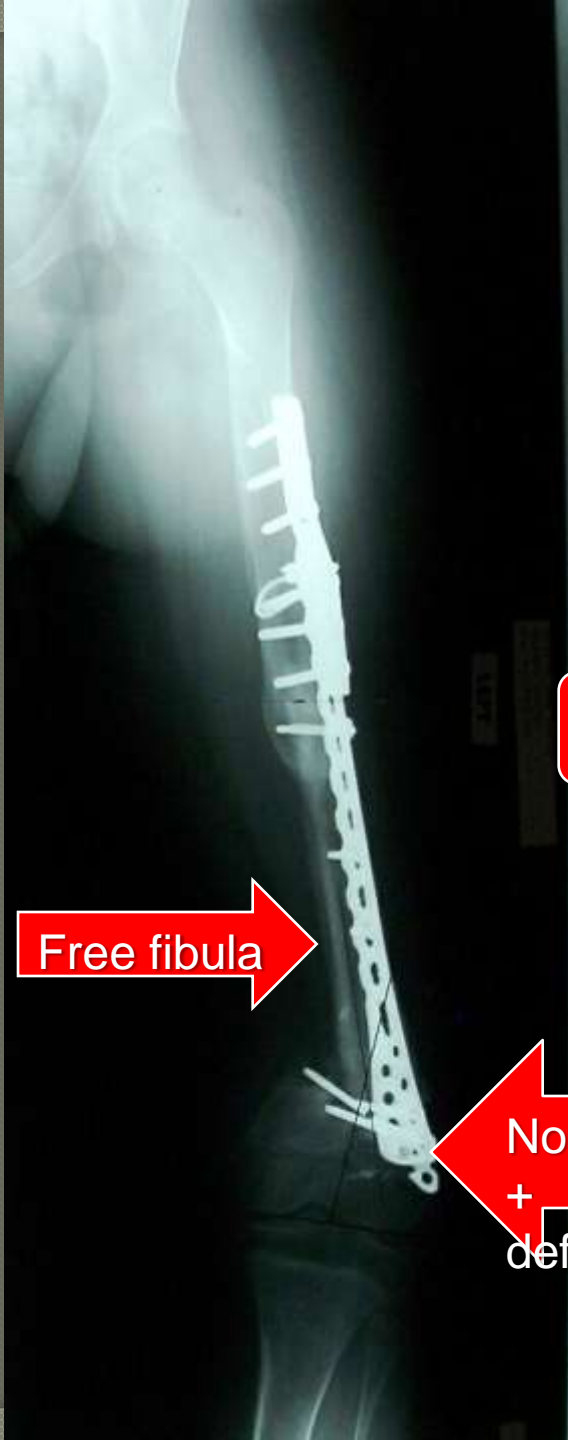


LLD=
6 cm

Failed free fibula reconstruction of
Osteosarcoma resection

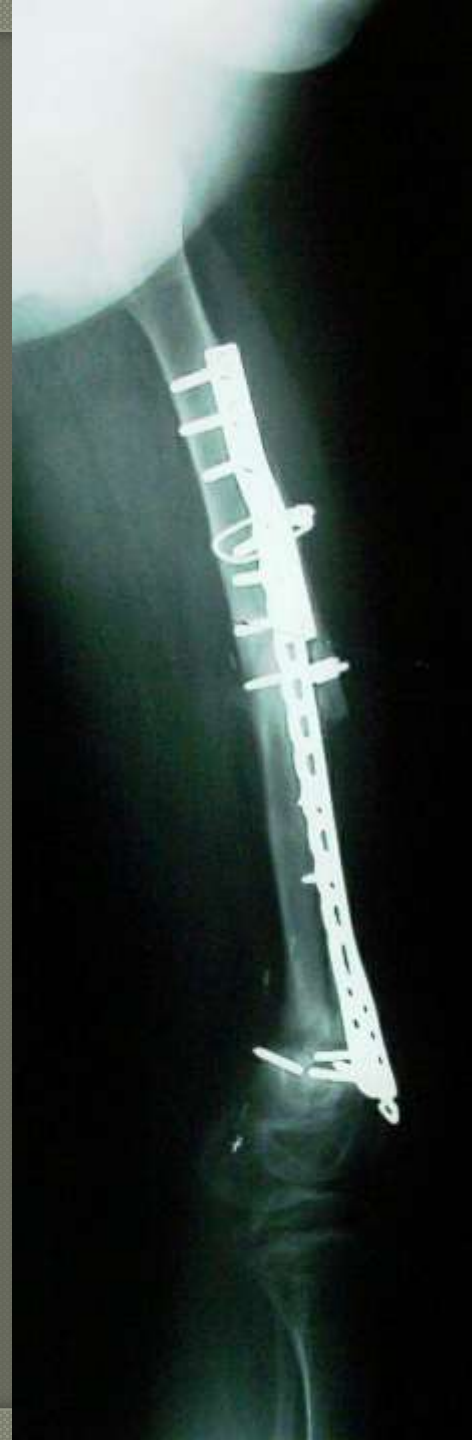




LLD

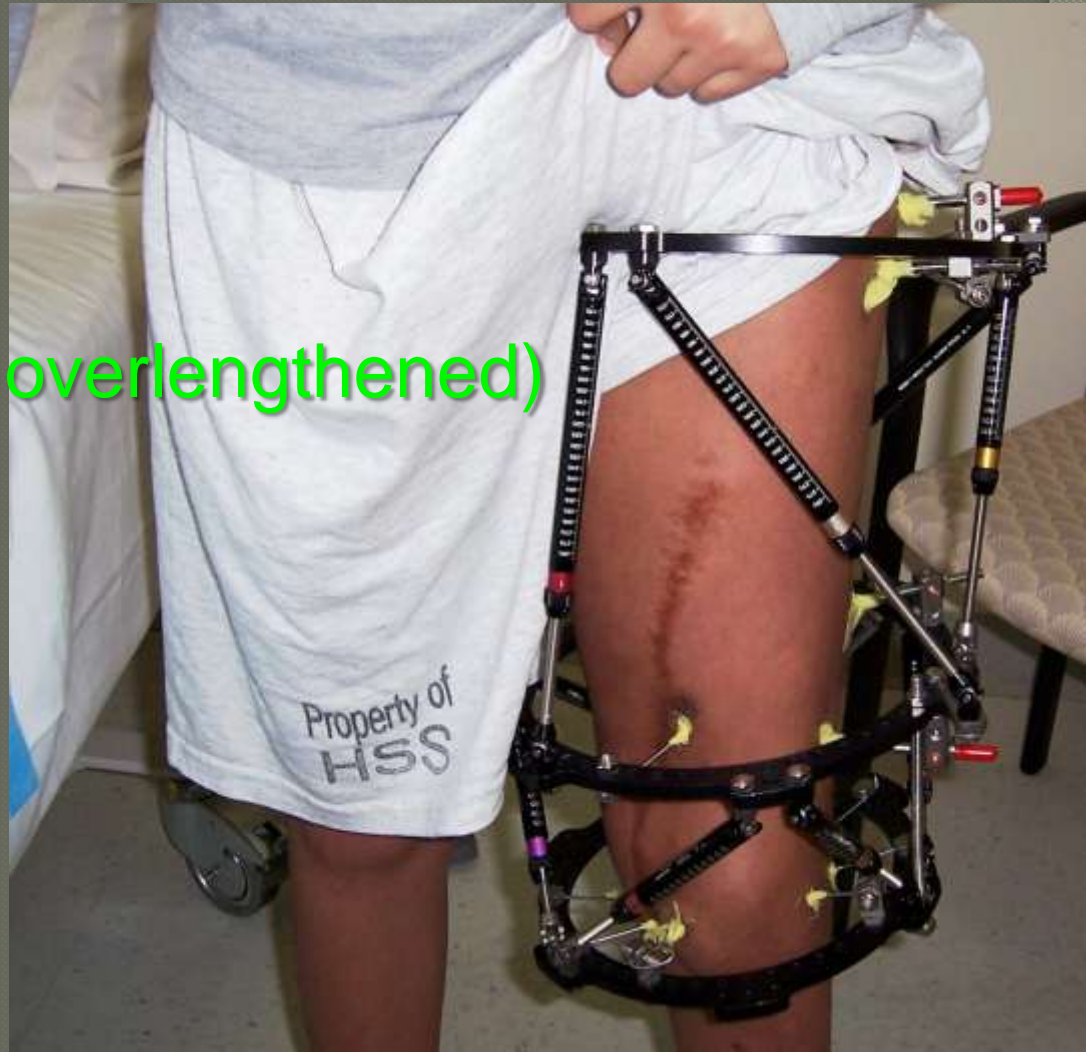Free fibula

Nonunion
+
deformity

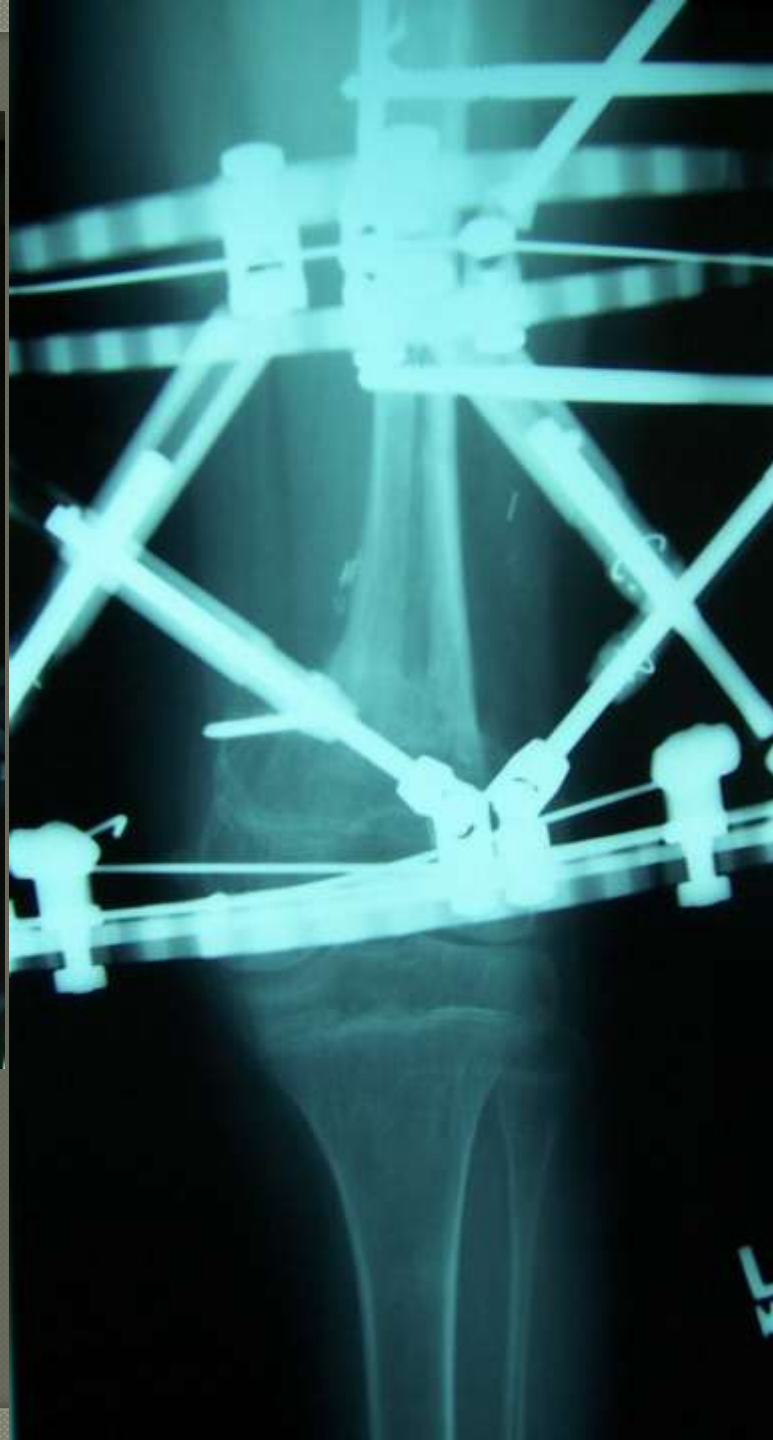
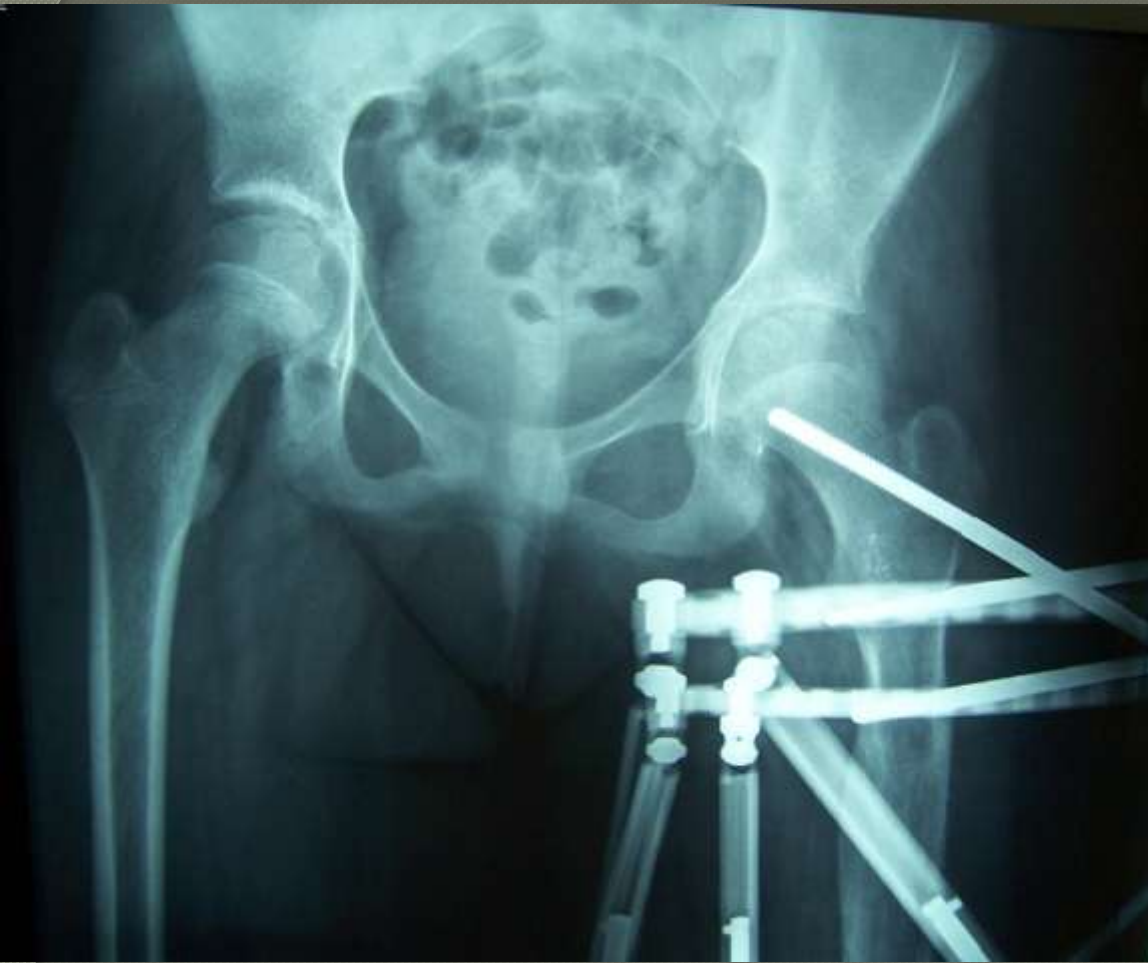


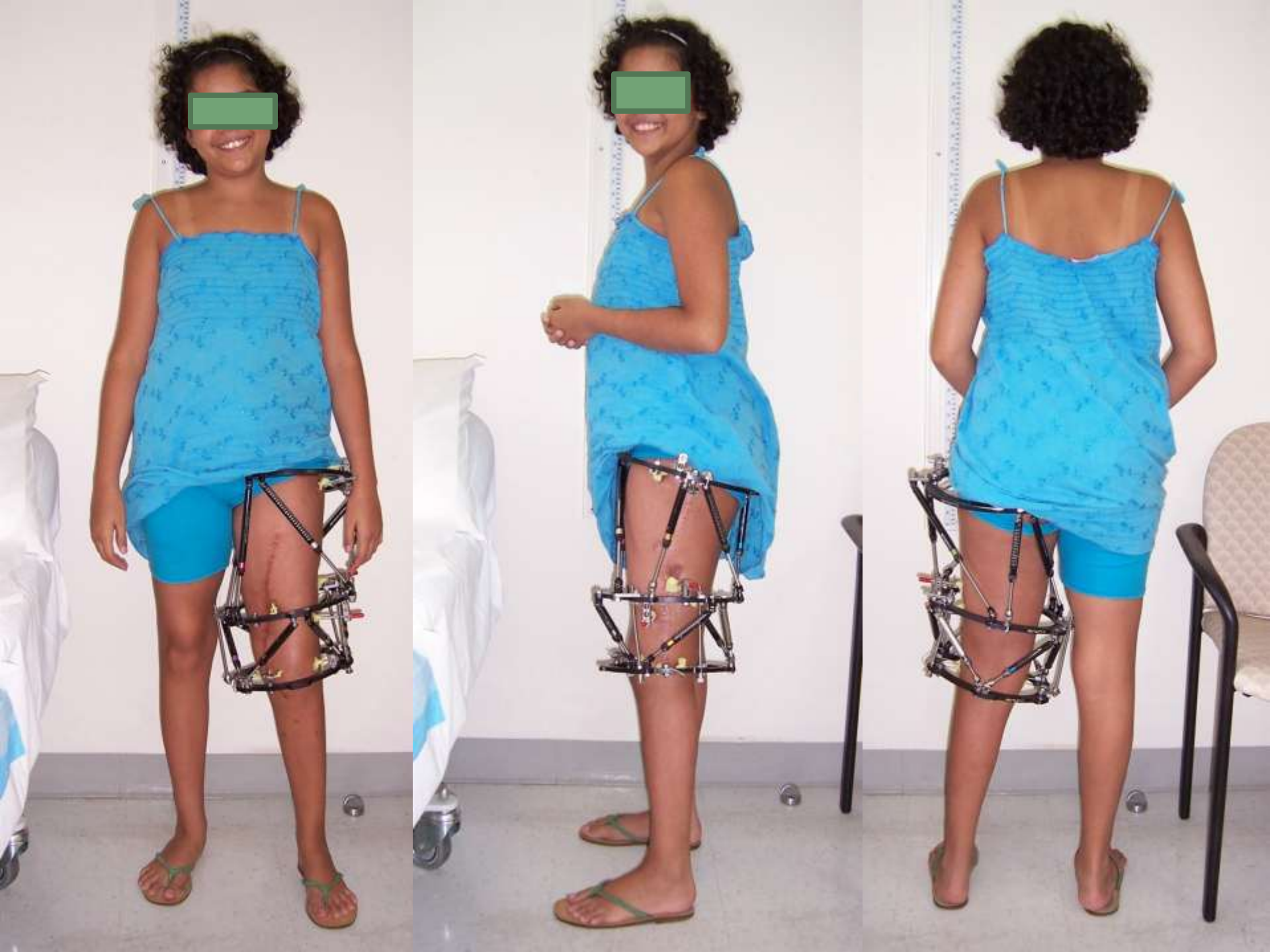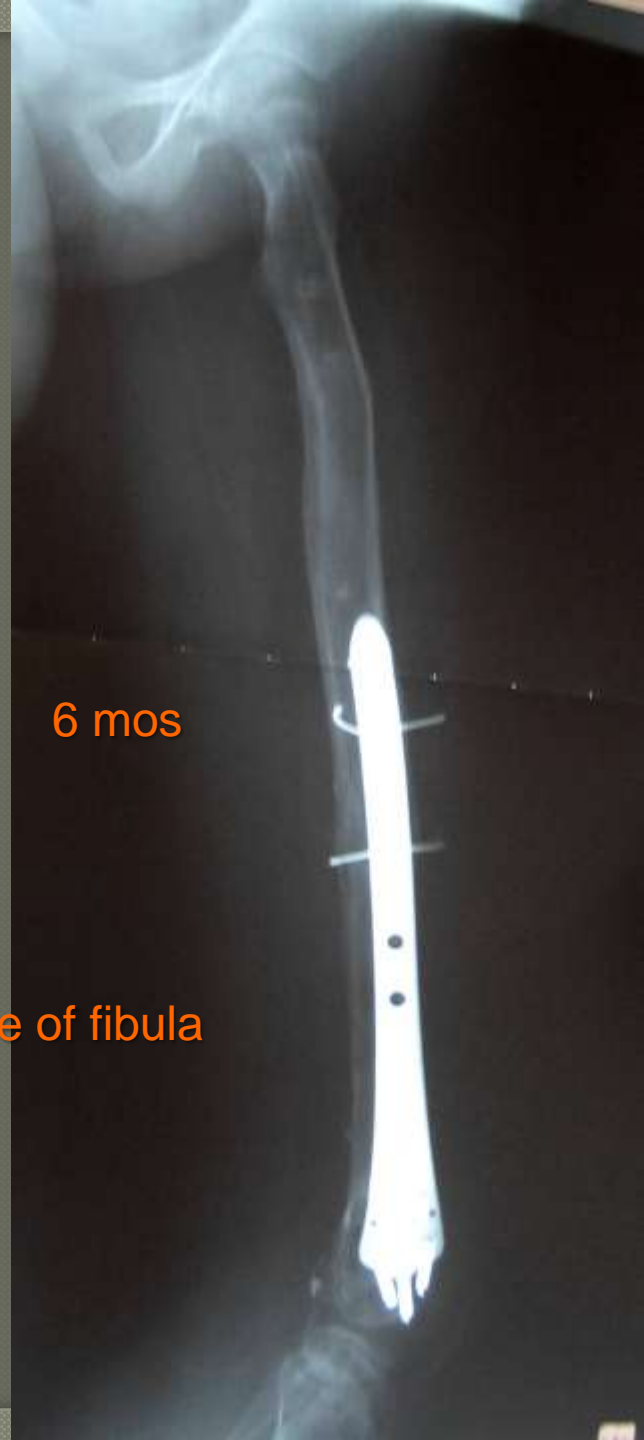
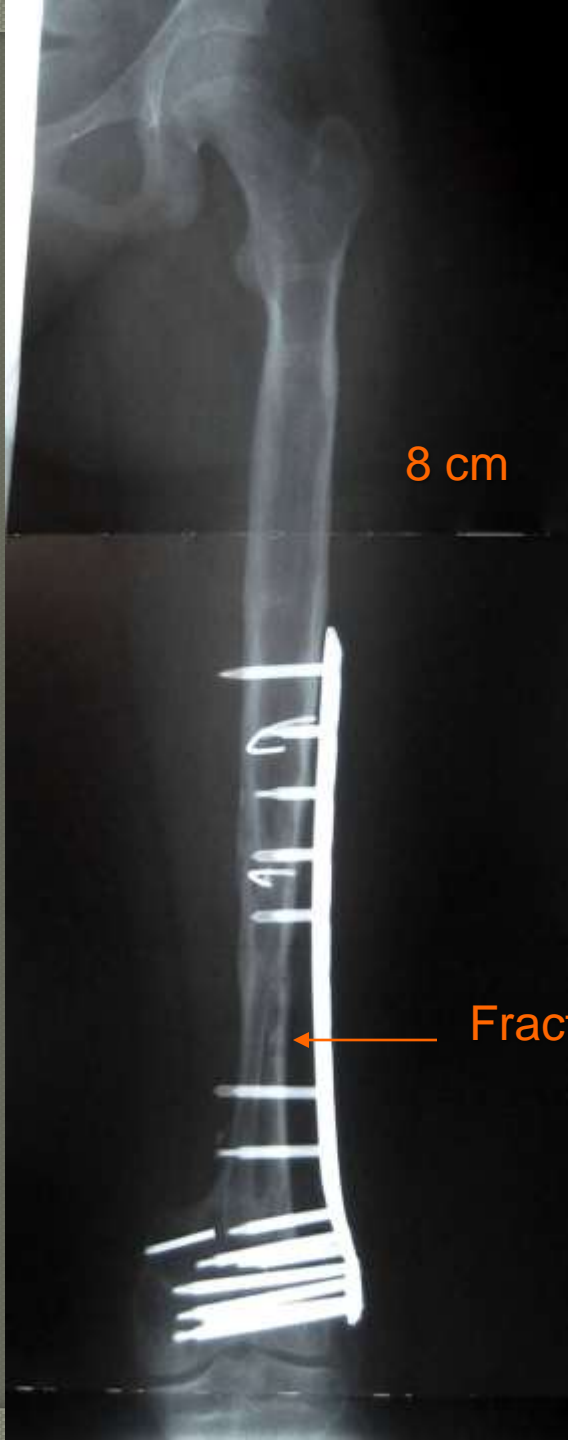8 cm (2 cm overlengthened)

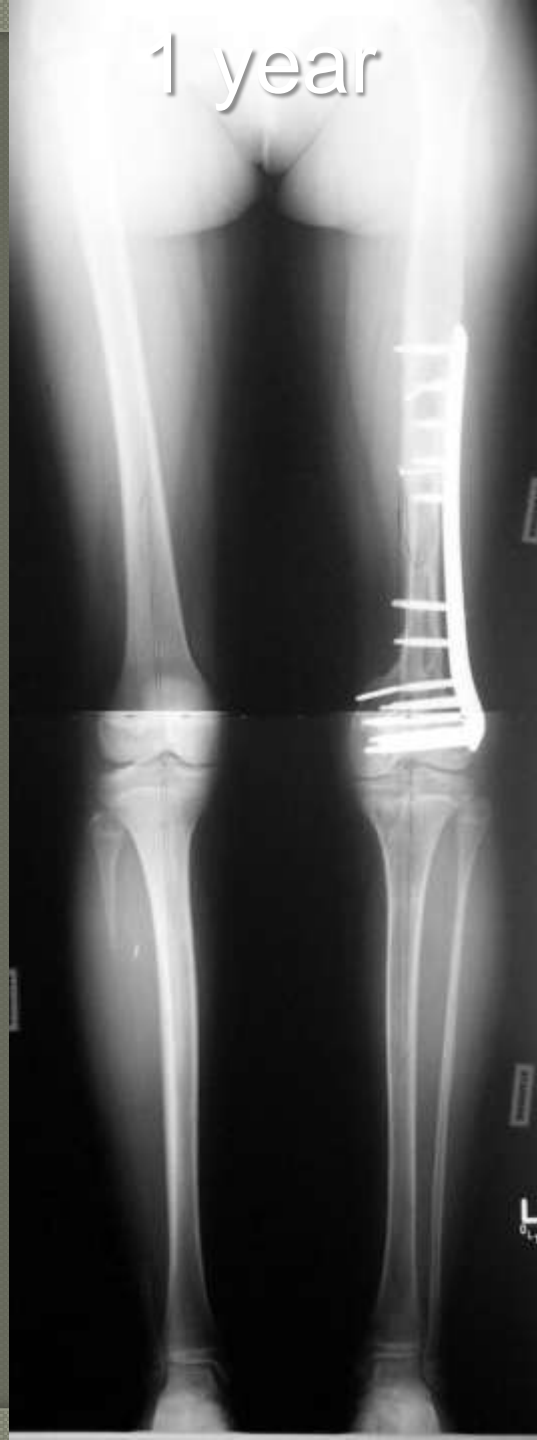
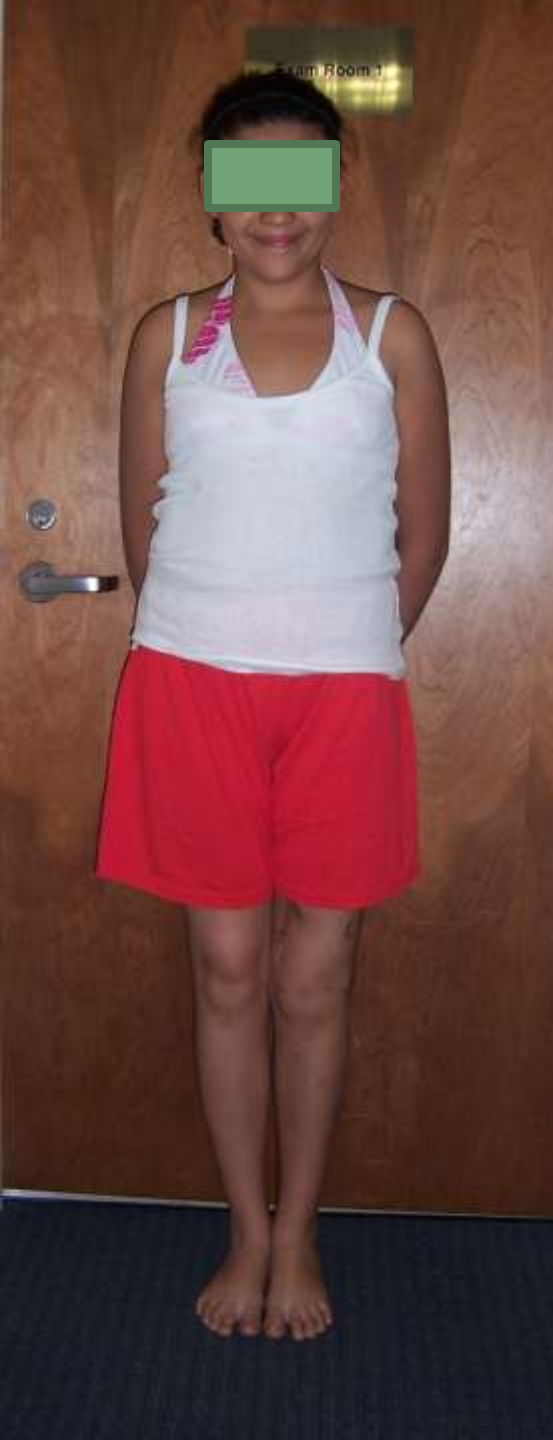
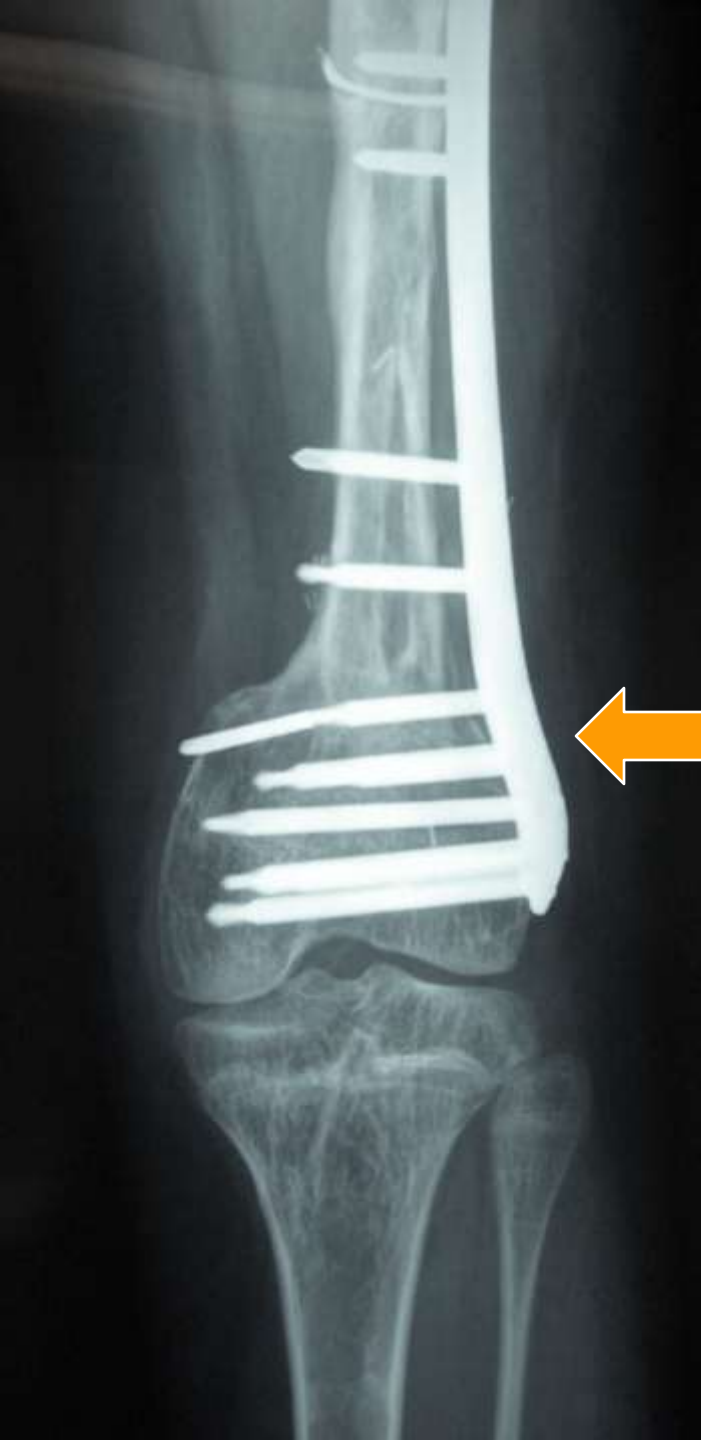Nonunion repair
Deformity correction



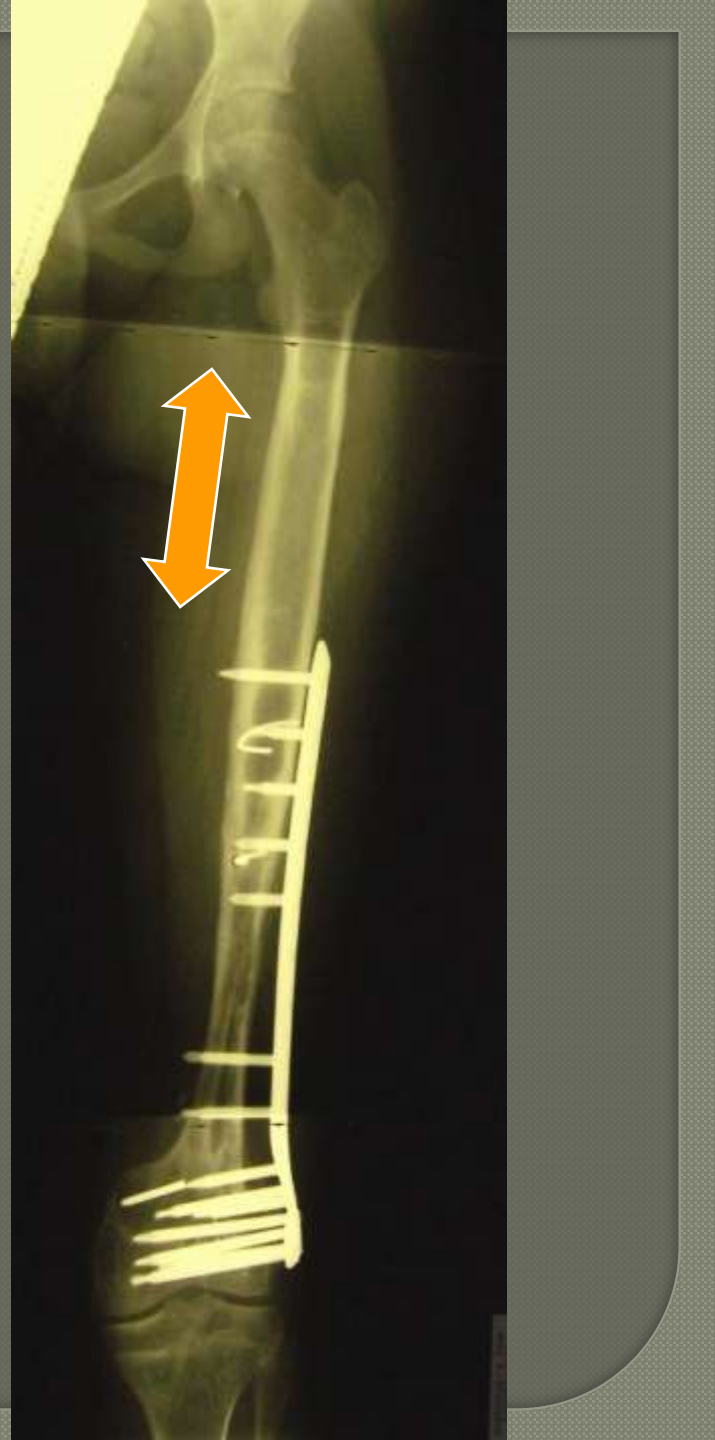



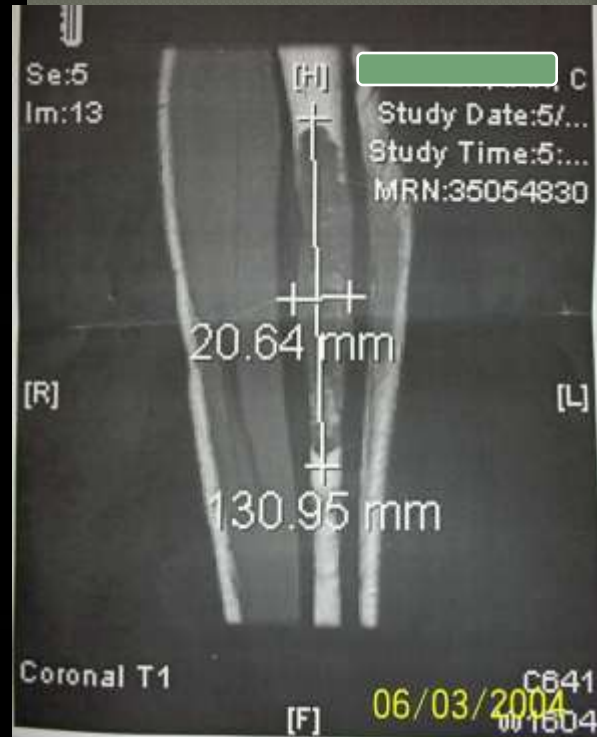

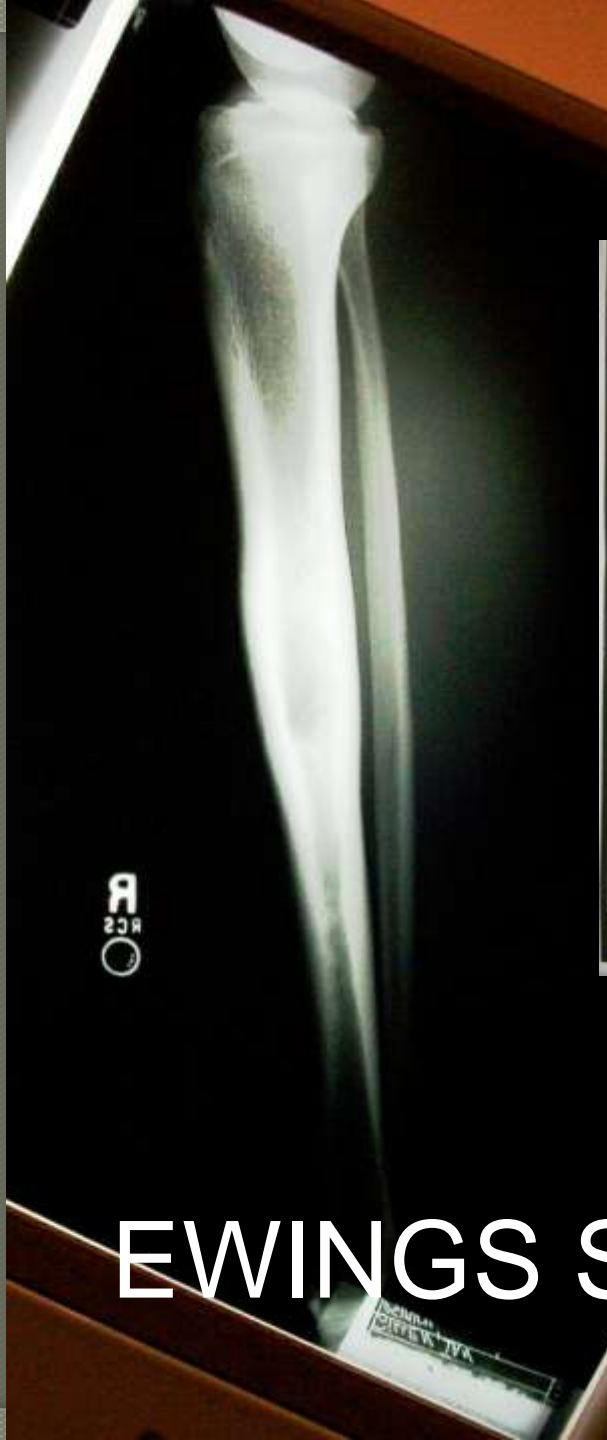
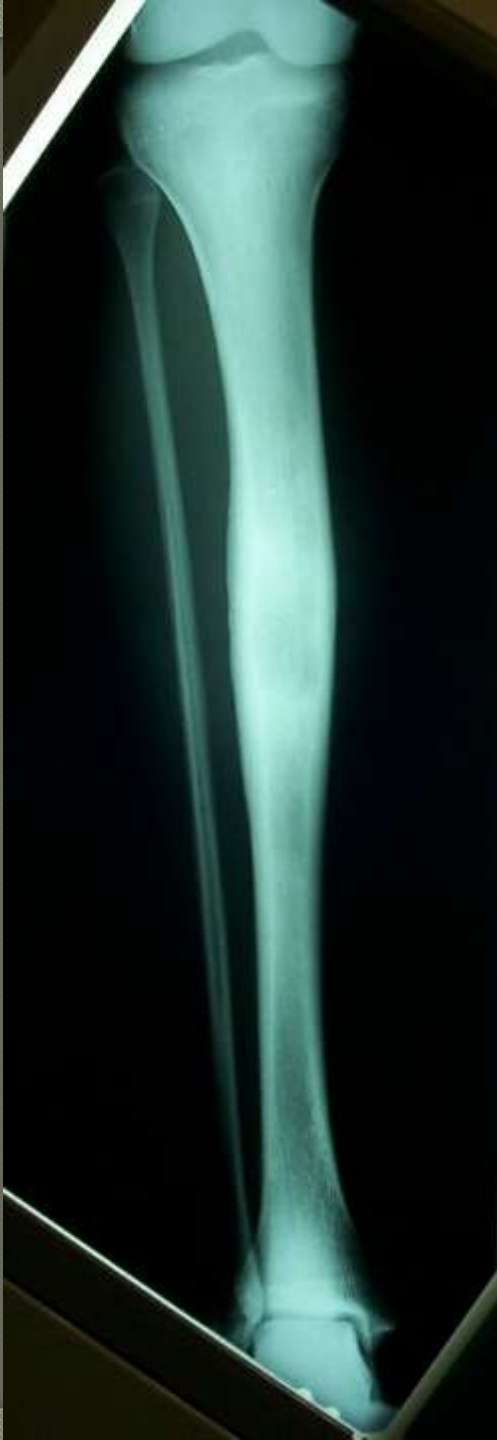

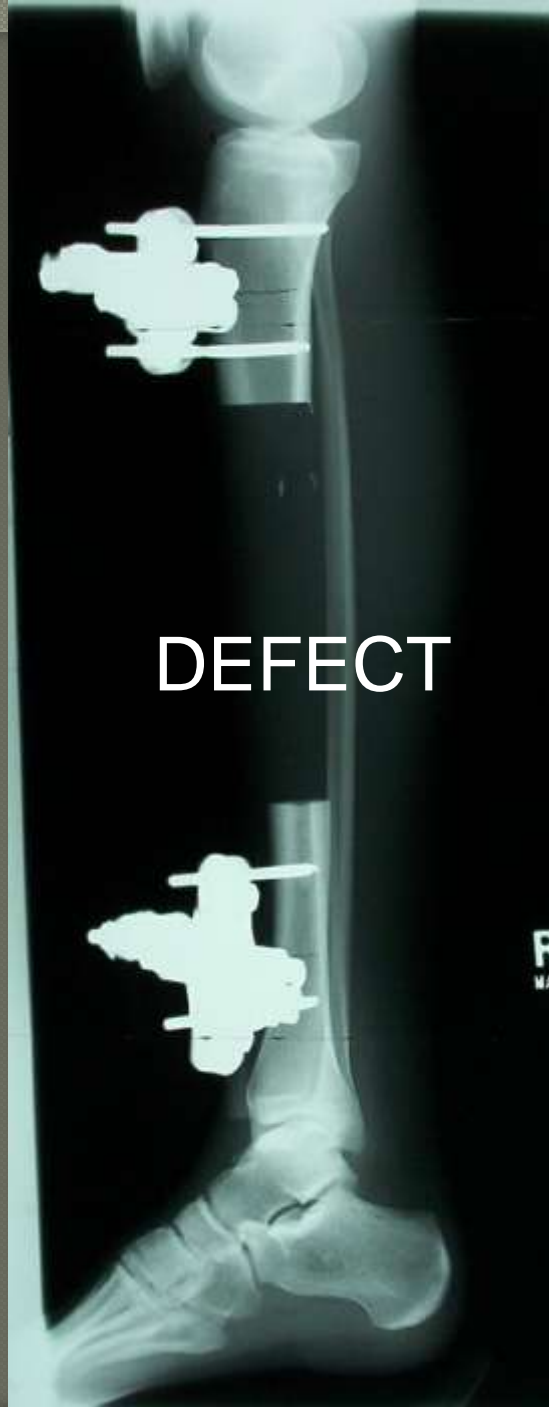1 year

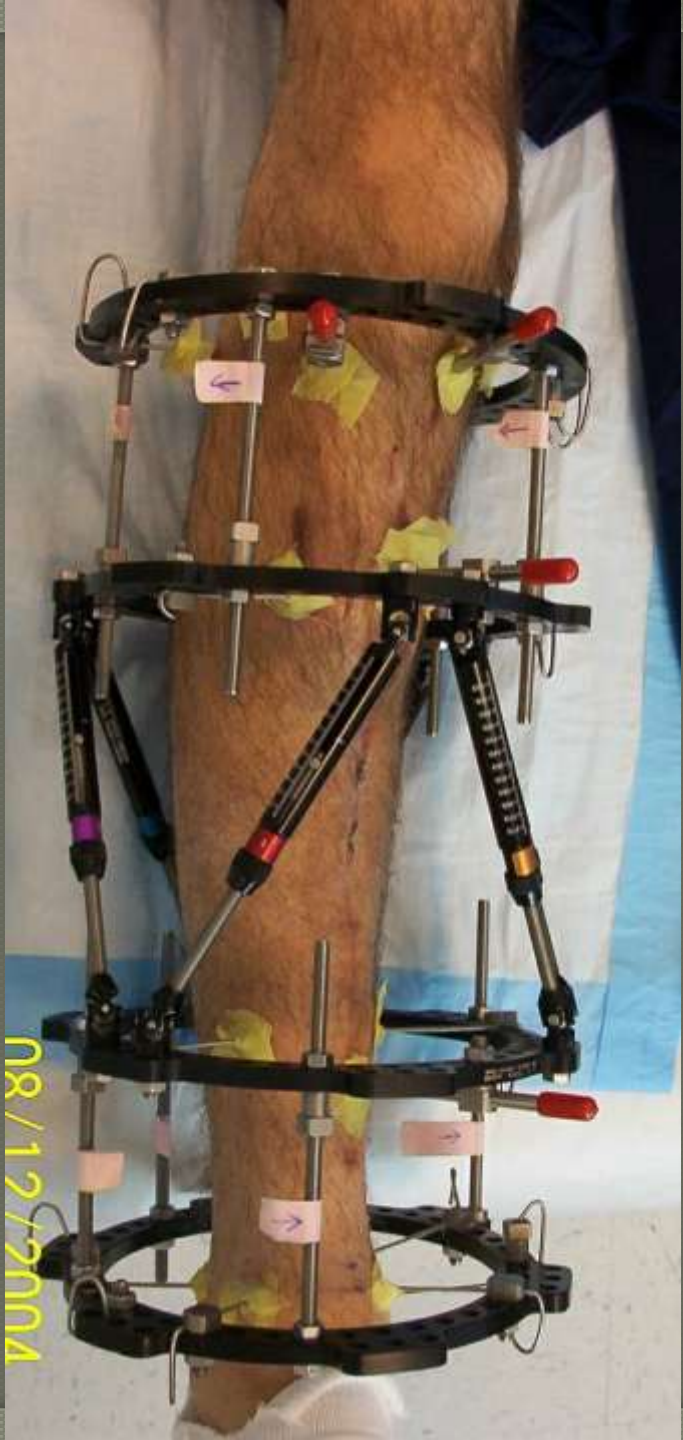


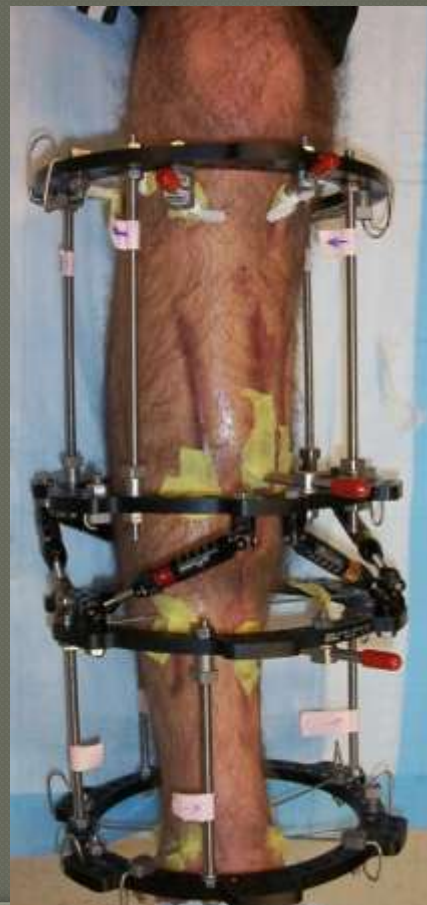
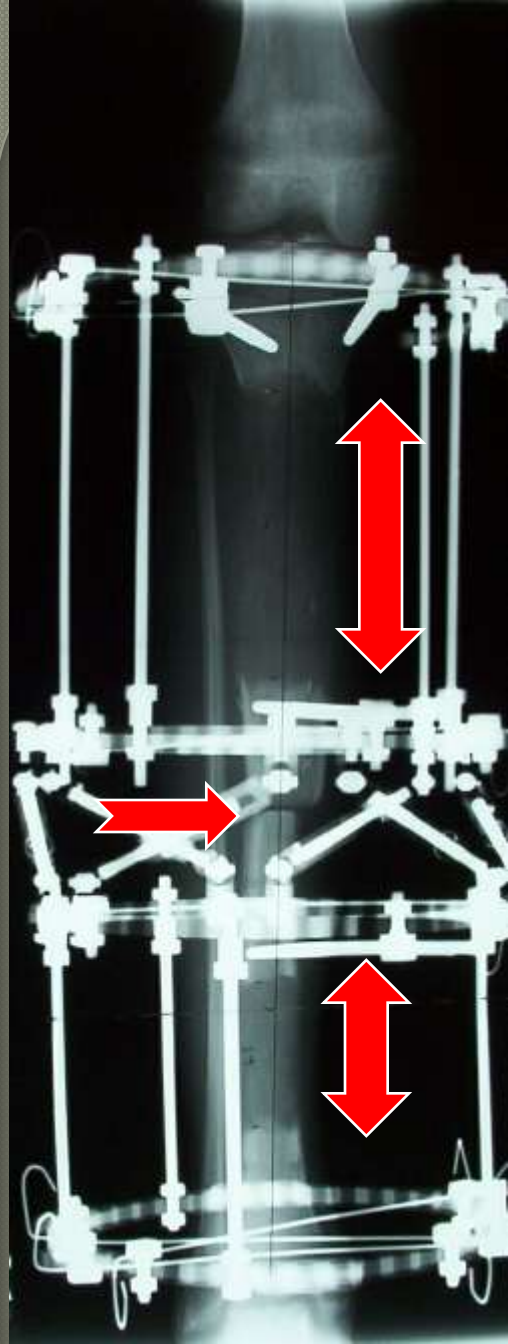


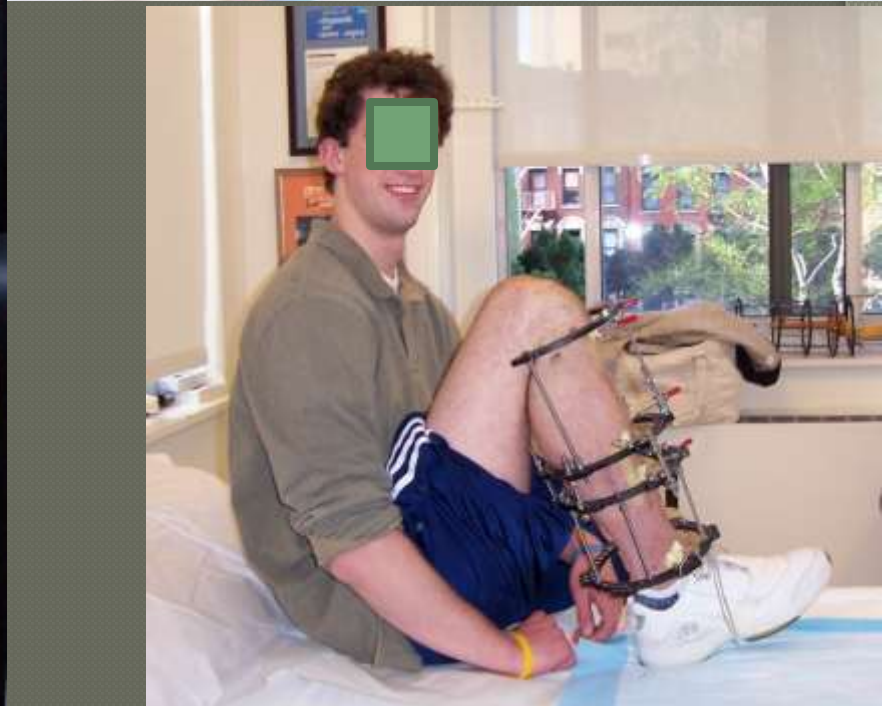
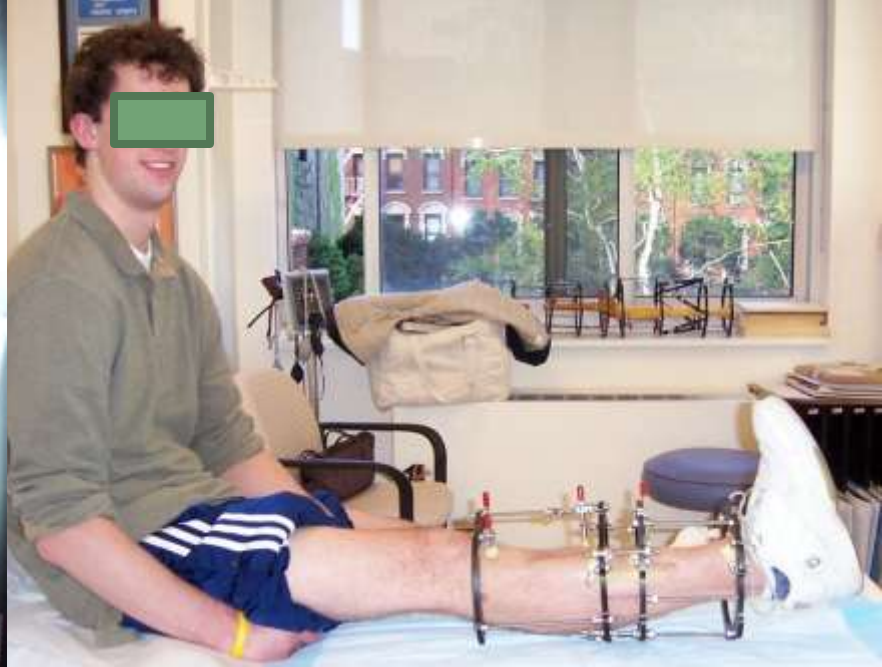
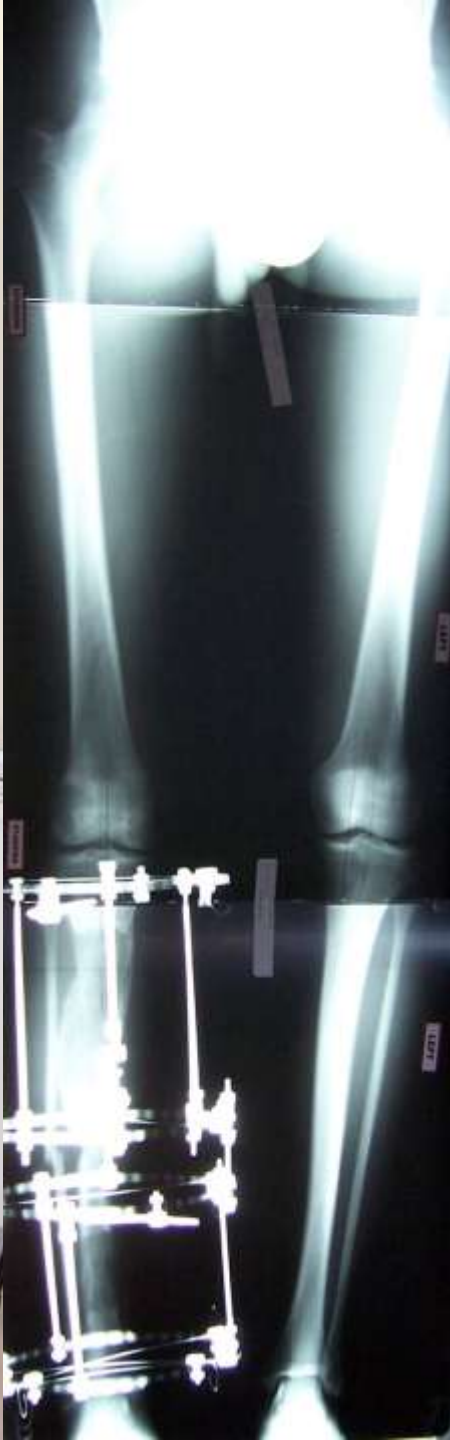

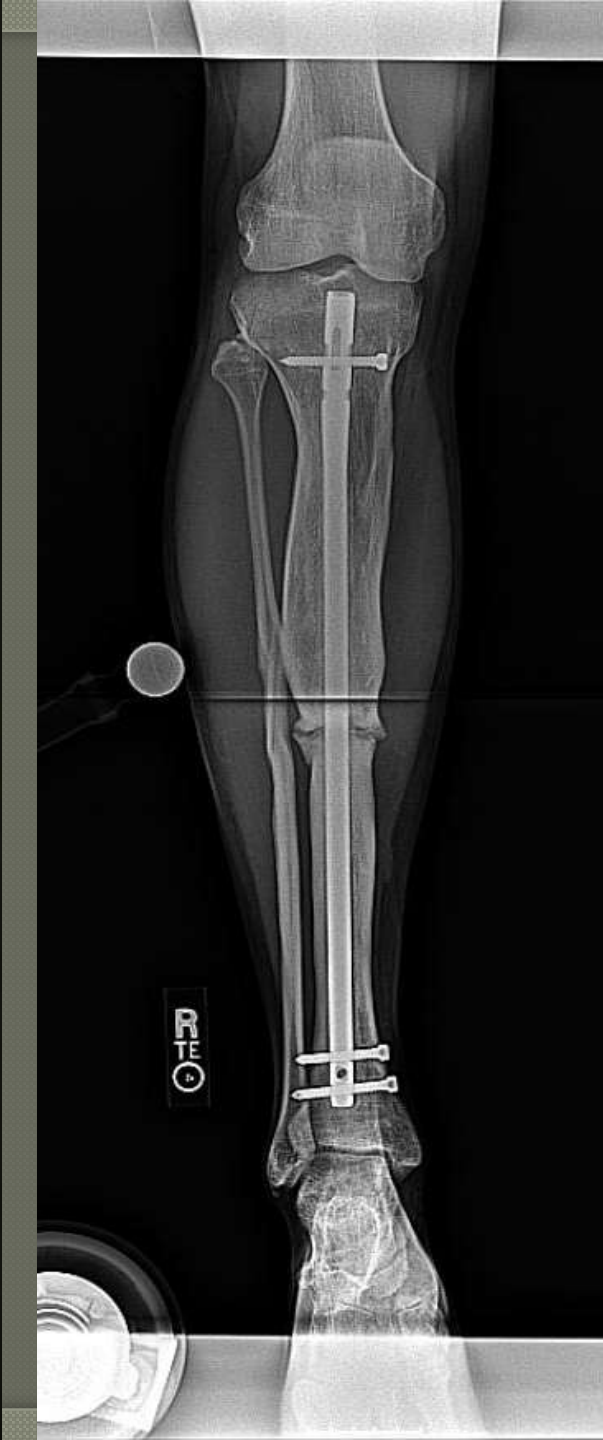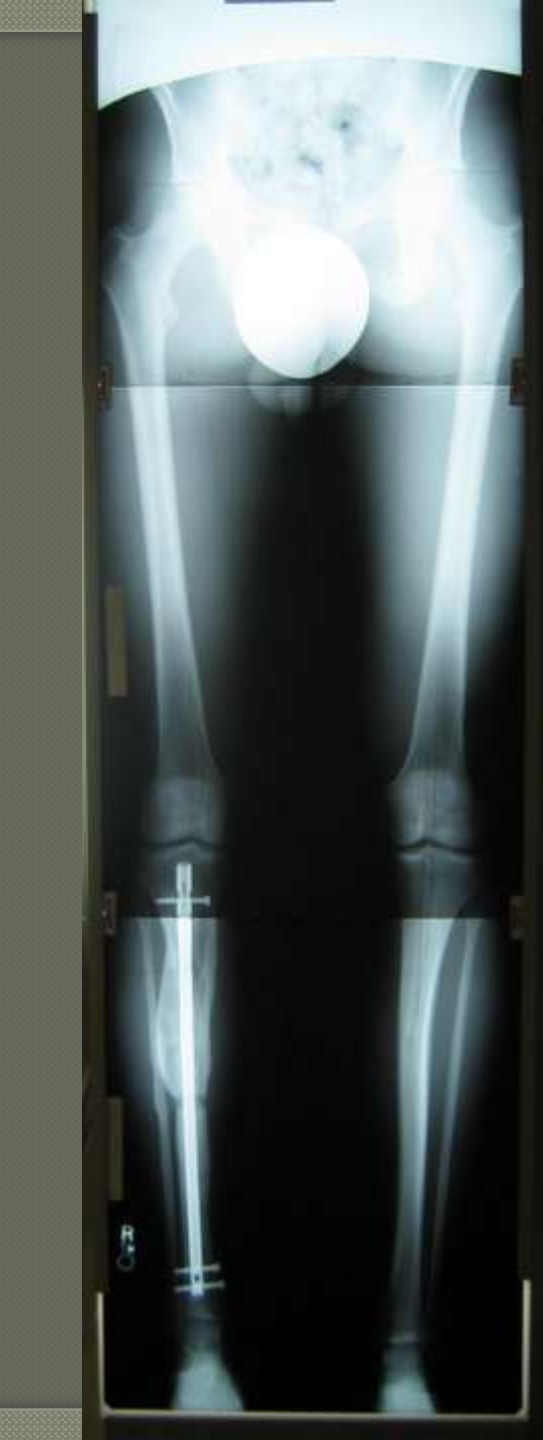EWINGS SARCOMA

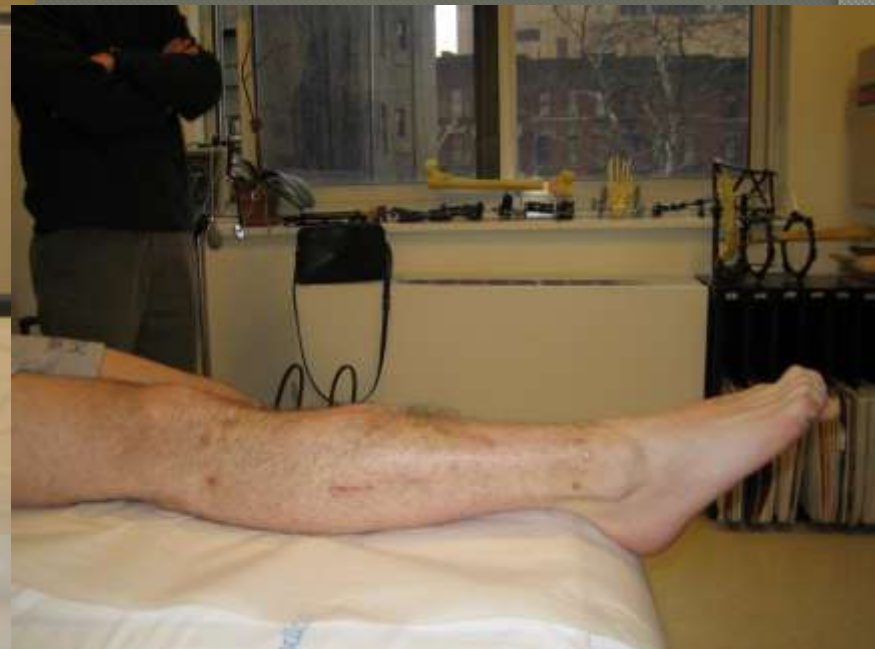
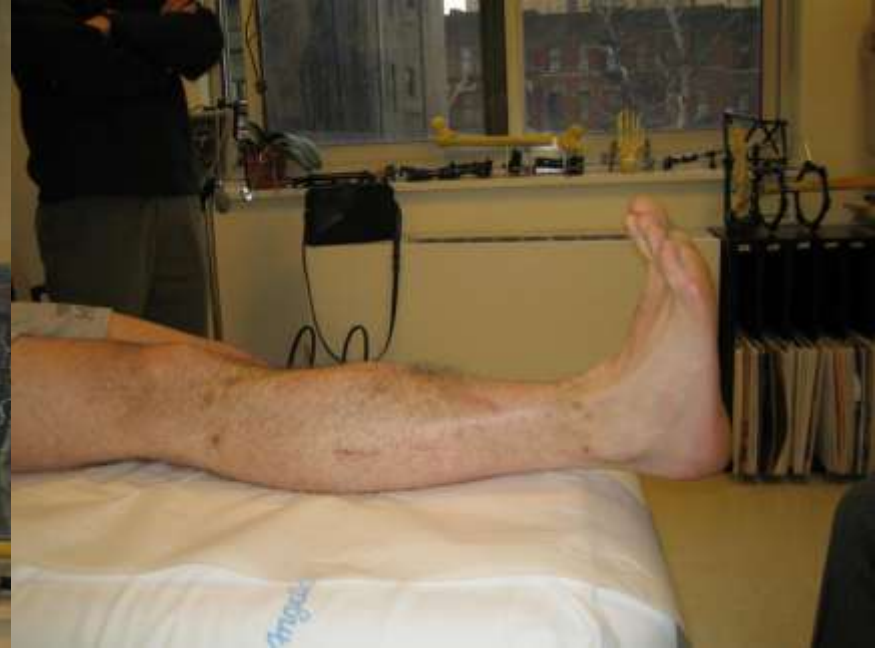
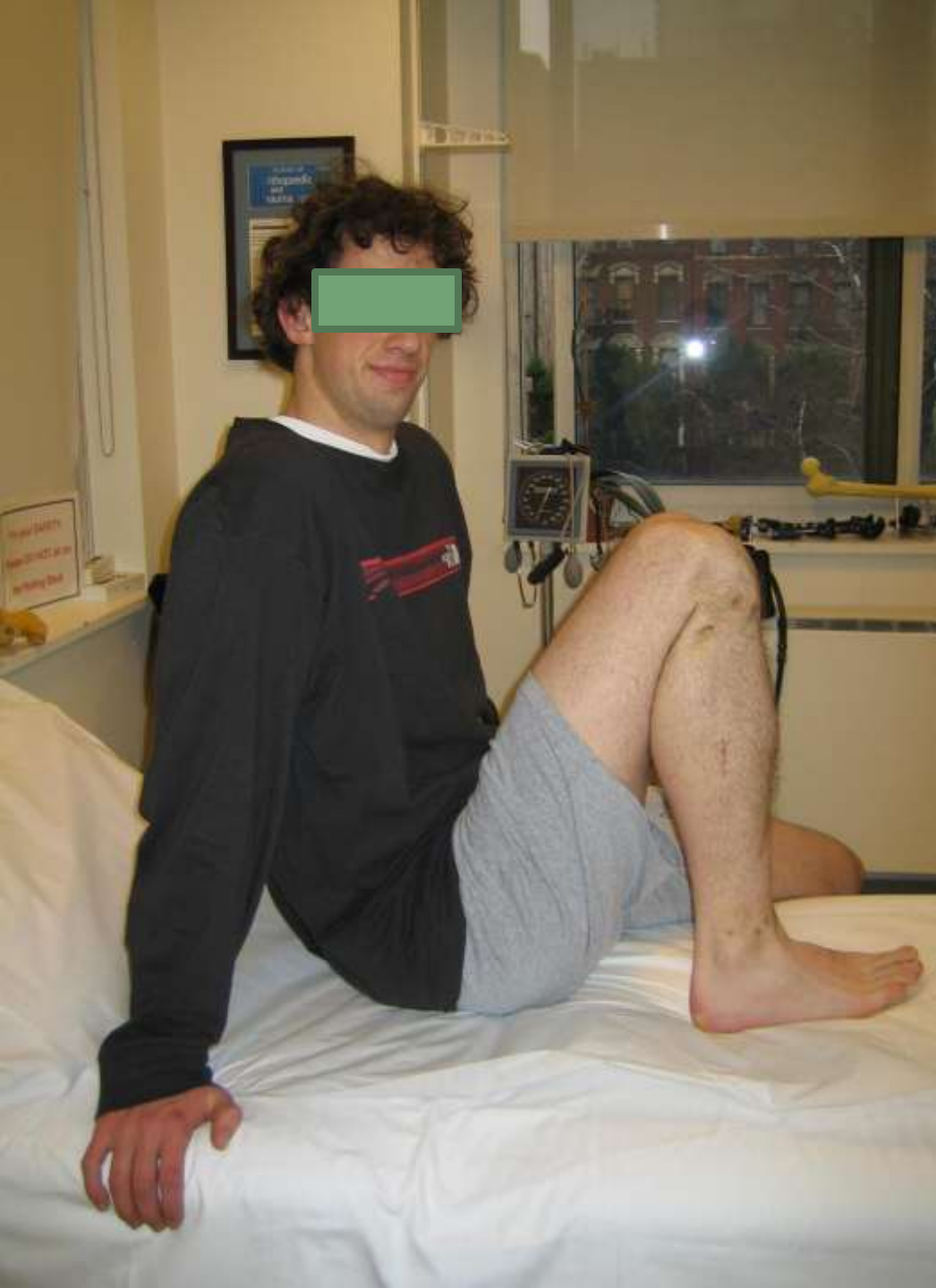

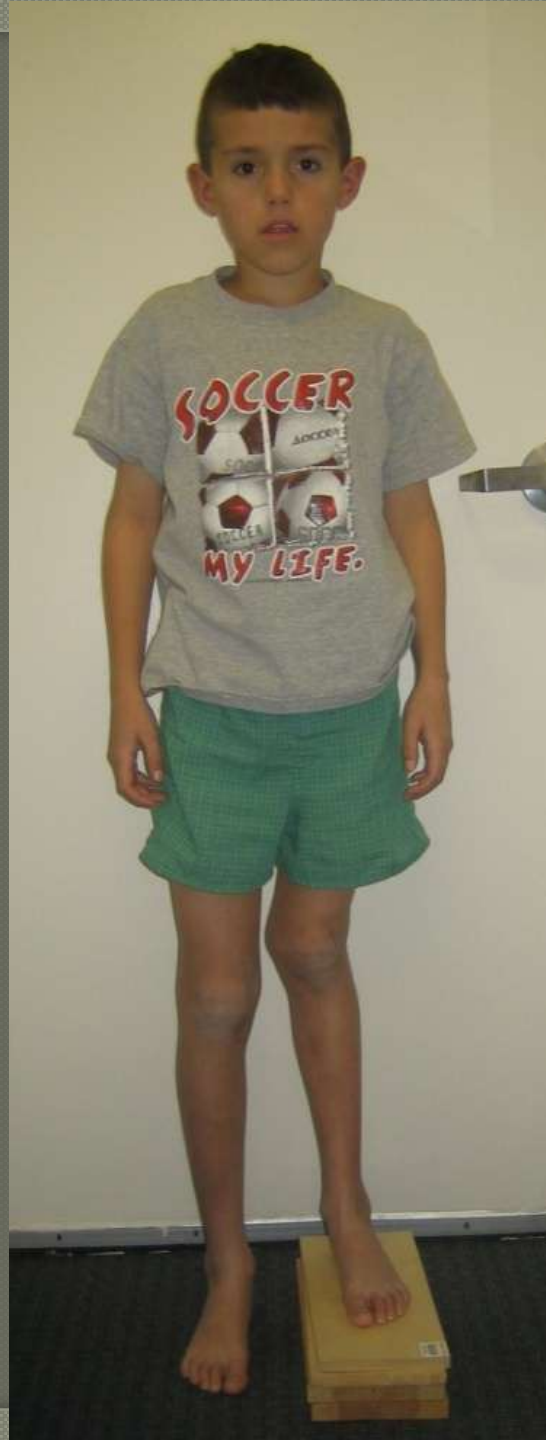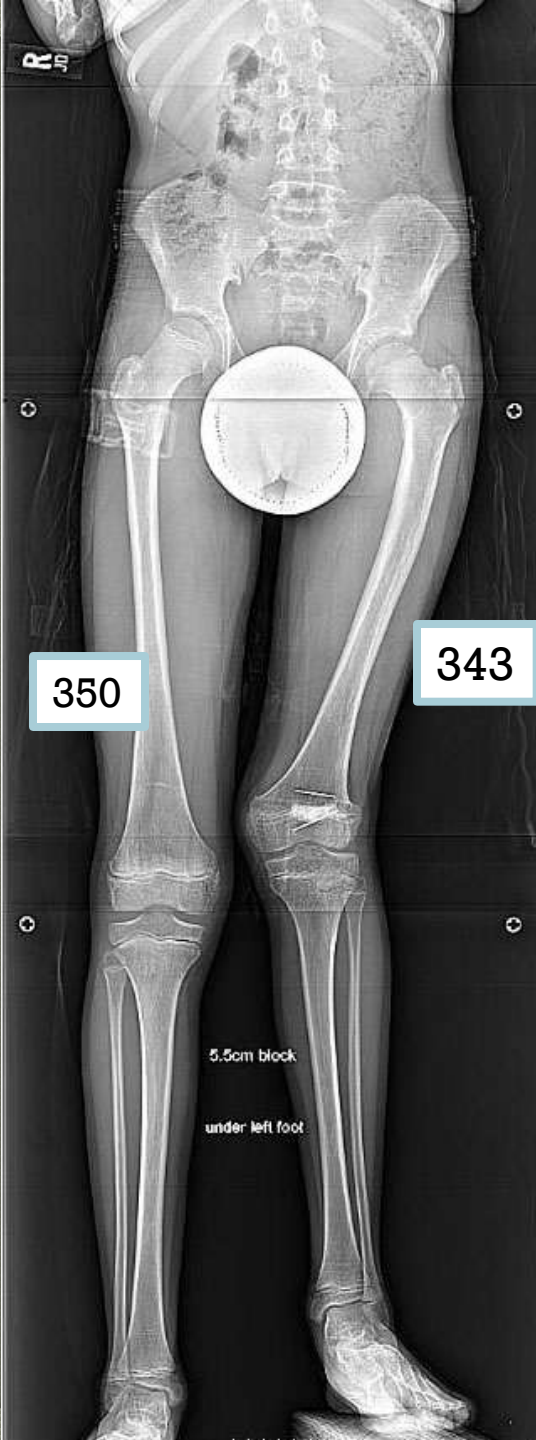












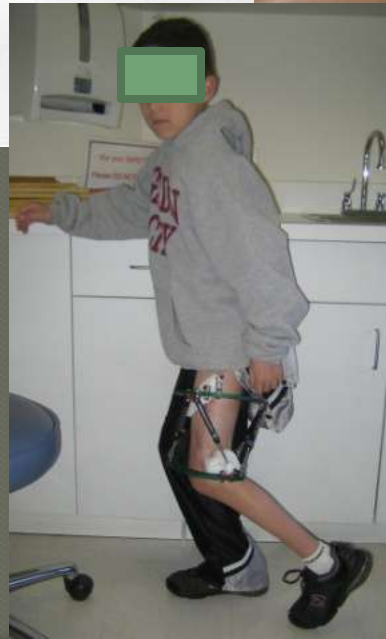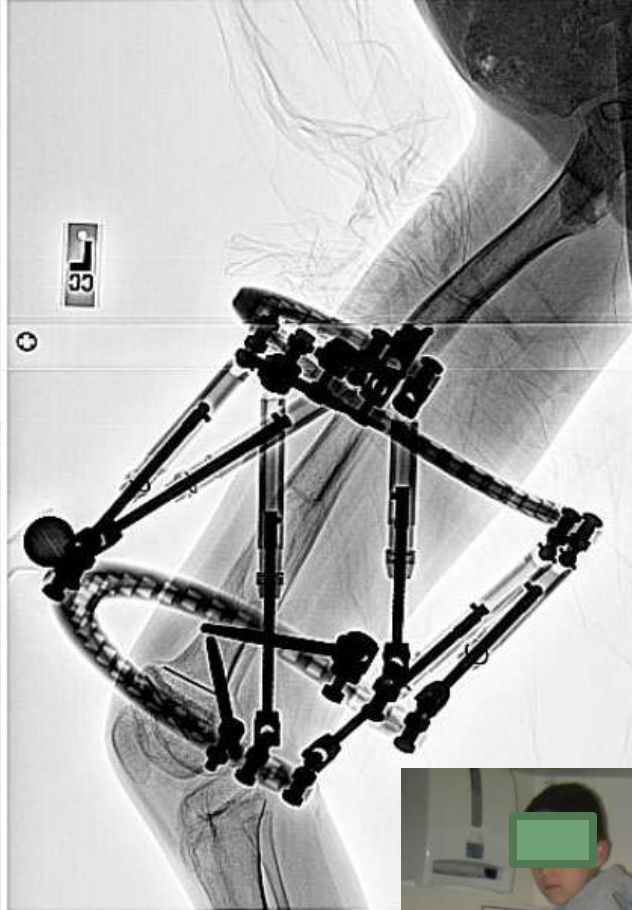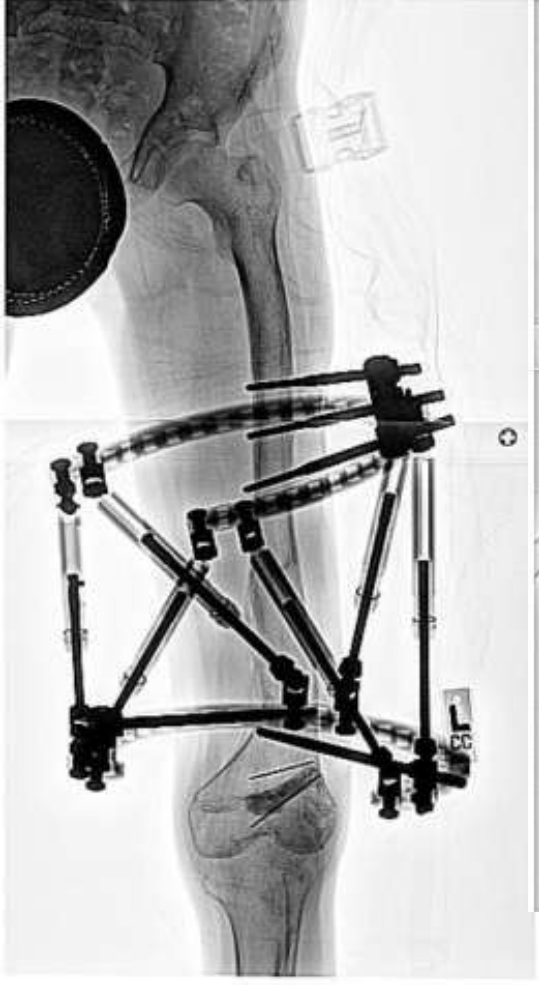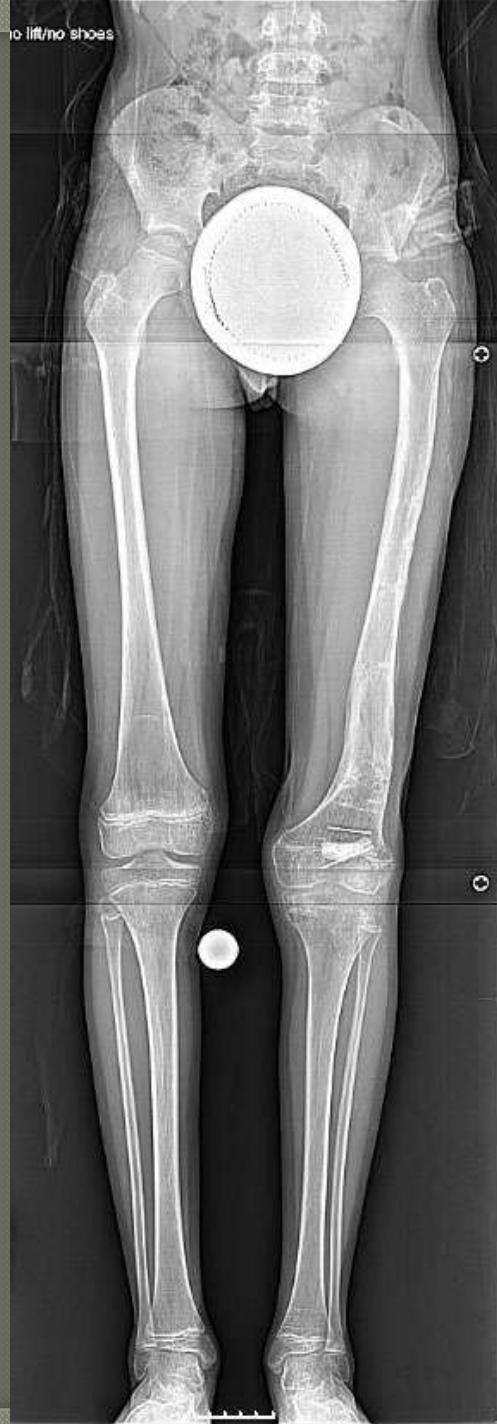Age 8
Distal femur growth arrest
Proximal tibial also
LLD 7 cm
Valgus deformity

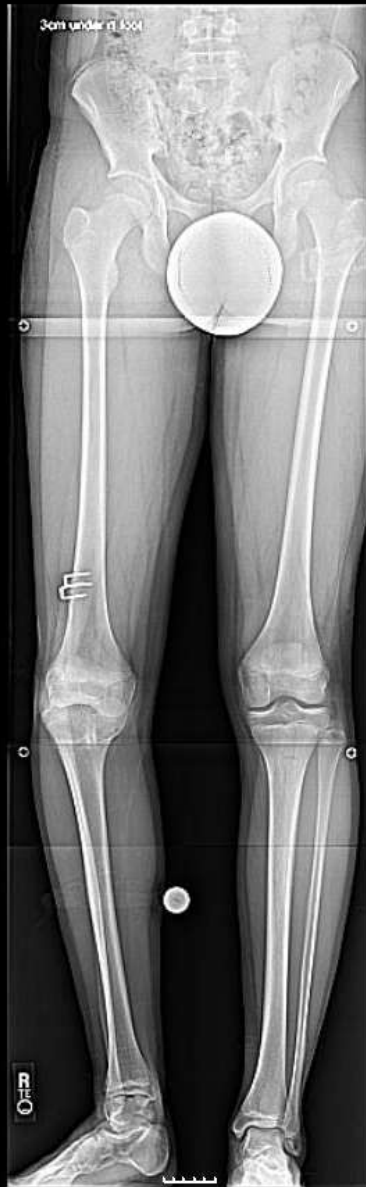PLLD
 $M = 1.47$
R femur = 350×1.47
R femur will be 515
 $515 - 350 = 165 \text{ mm}$
 $165 \times 70\% = 11.5 \text{ cm}$

Plan: lengthen femur
7 cm, correct valgus,
Close growth plate.
Additional lengthening
of about 11 cm. femur
and / or tibia



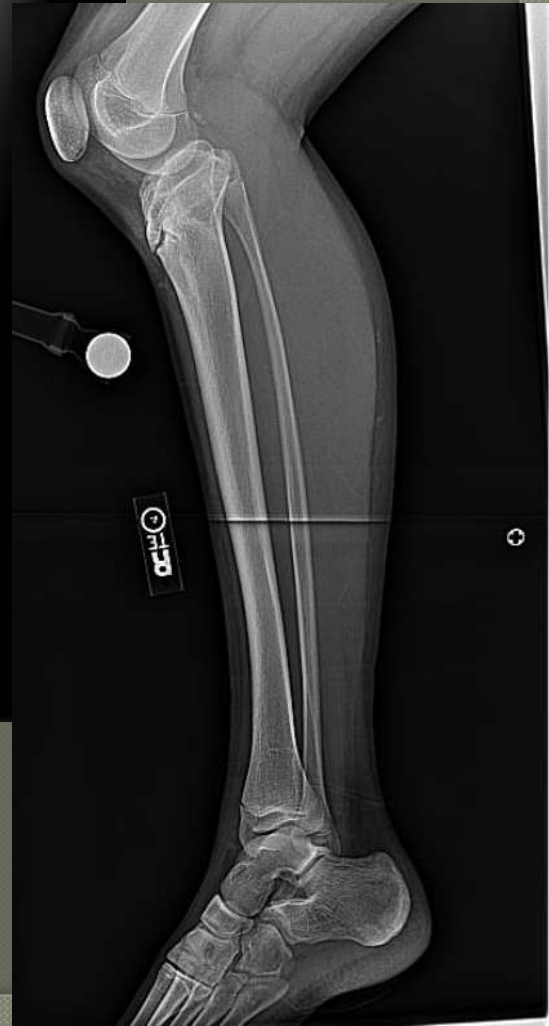


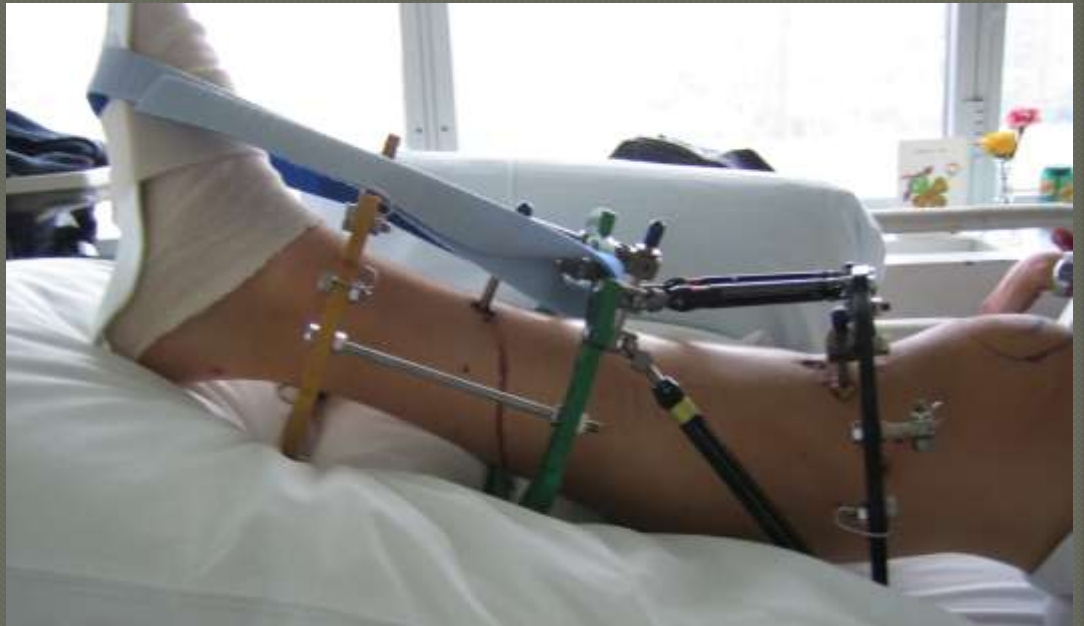

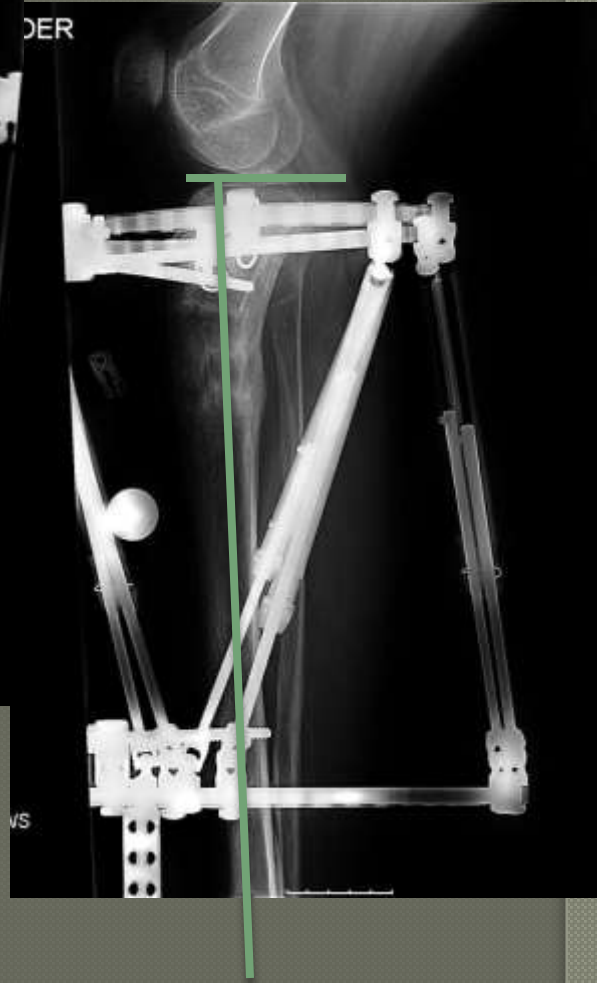
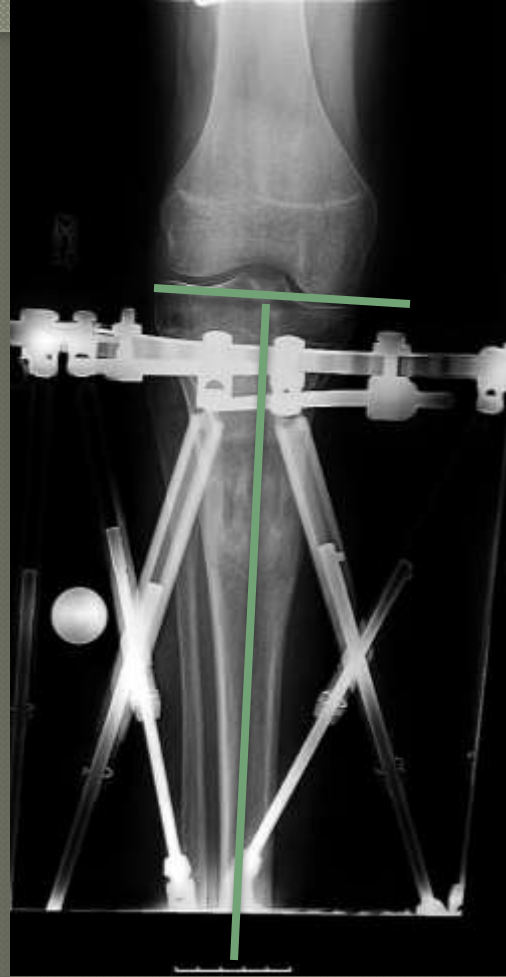

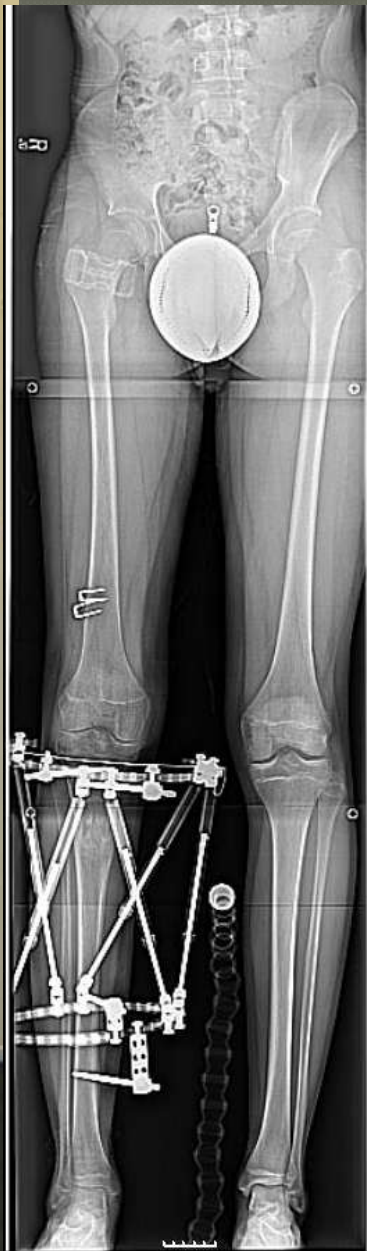
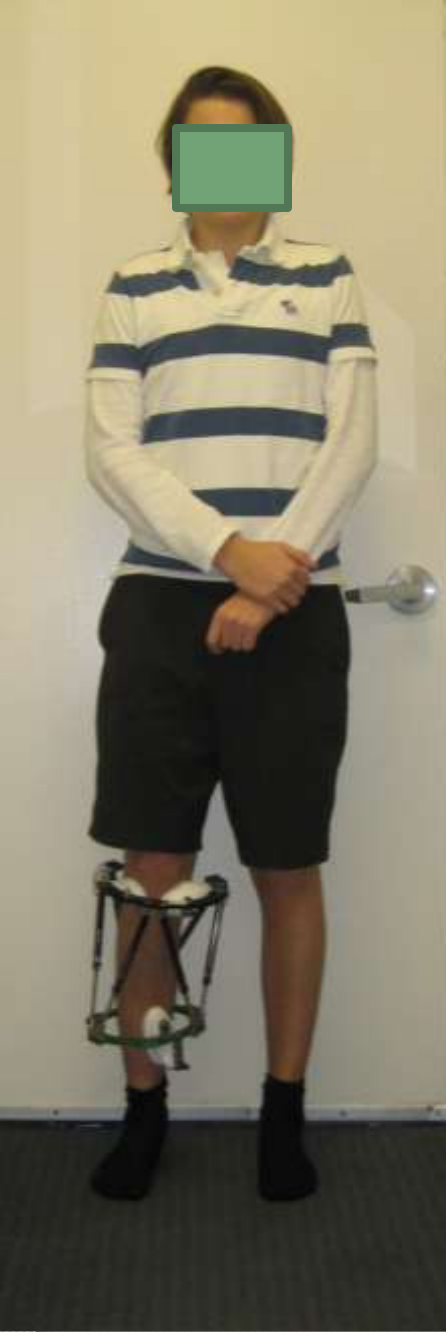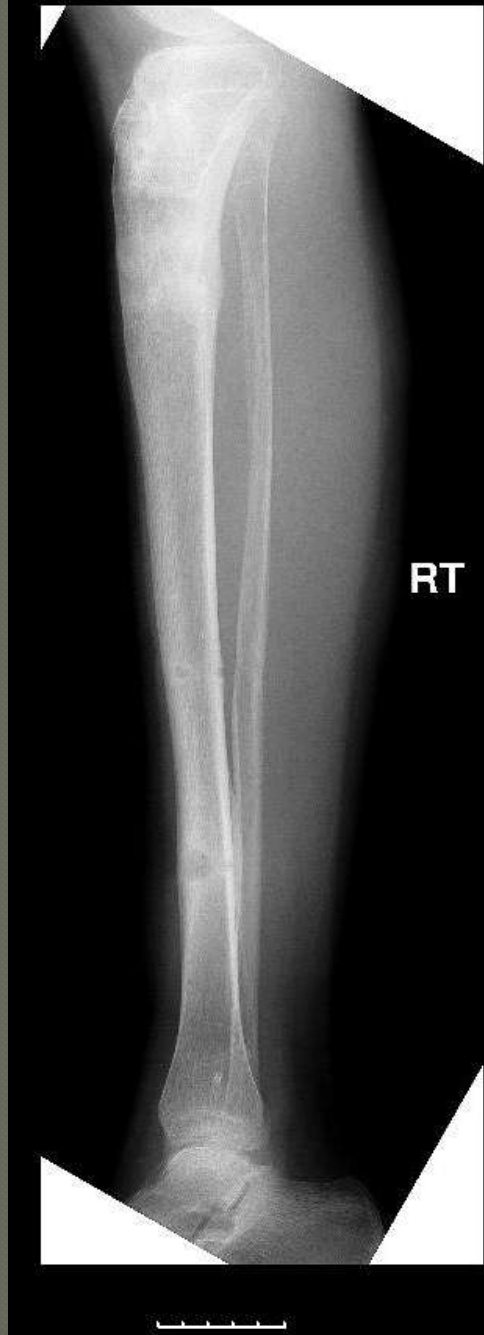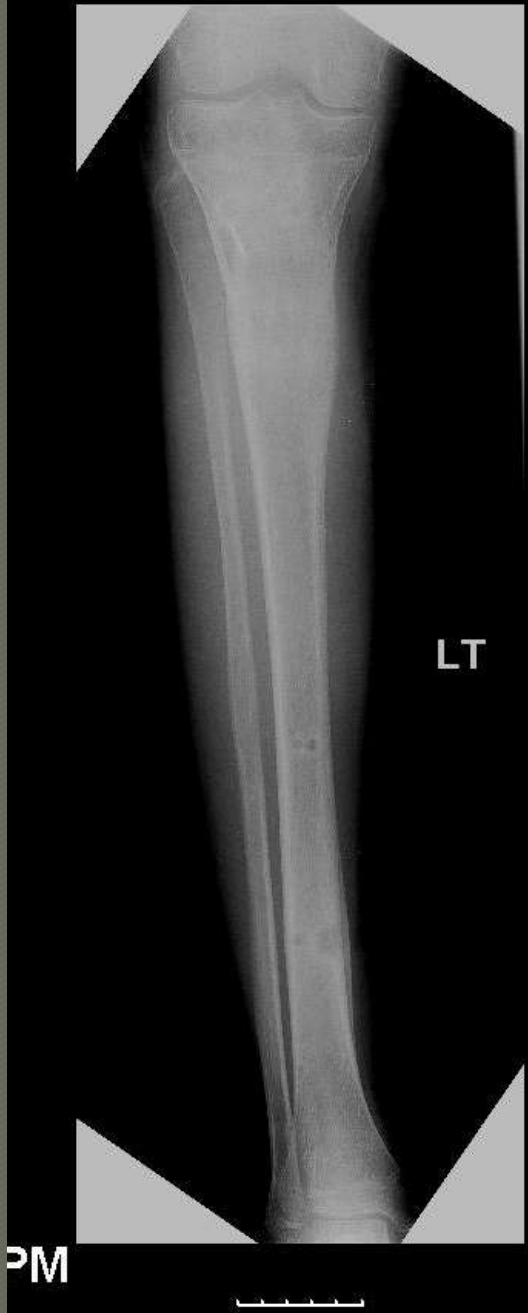egrees cephalad tilt

RTE

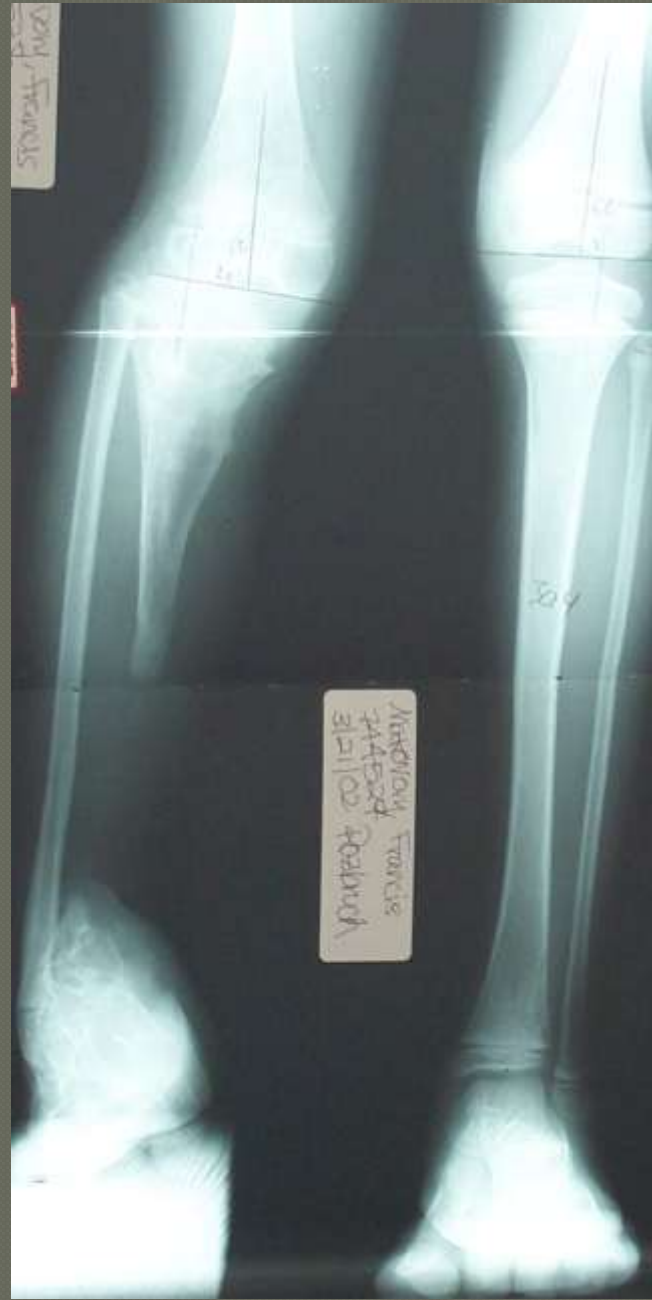
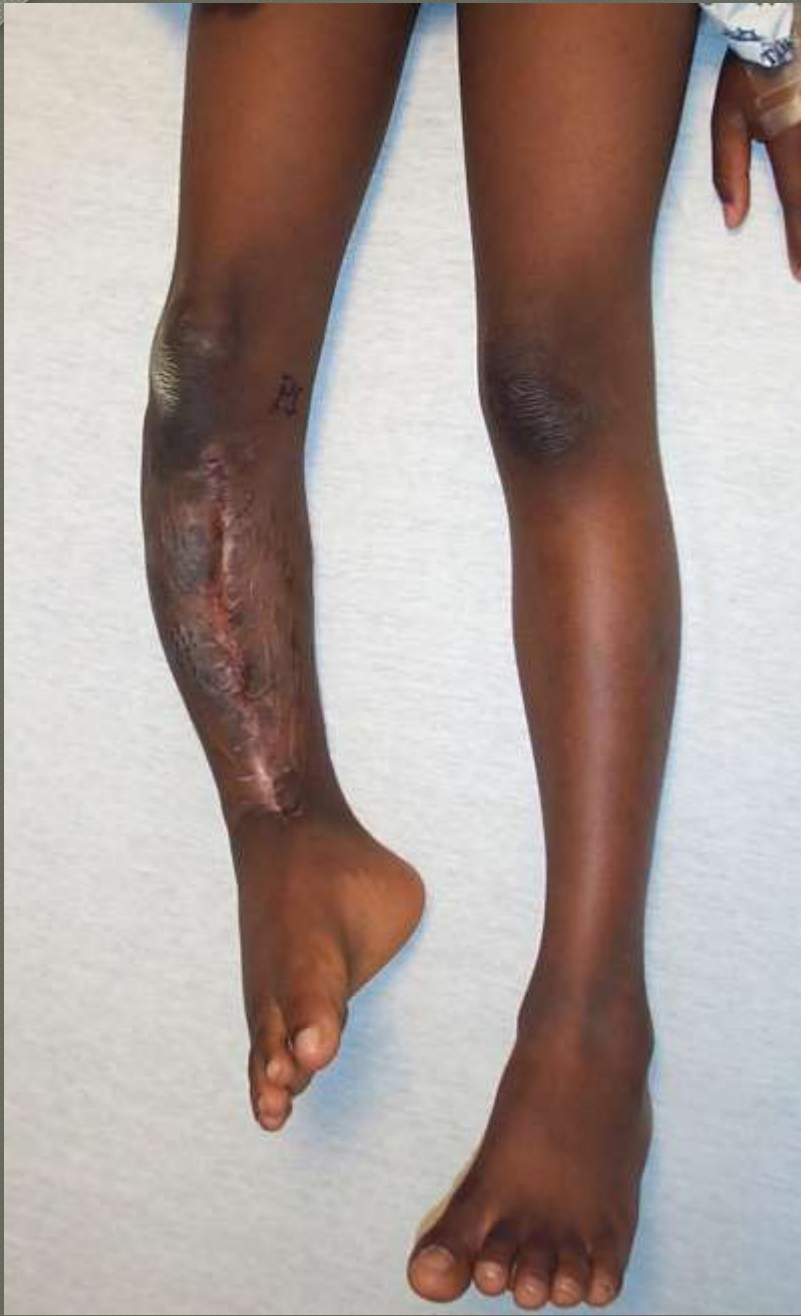
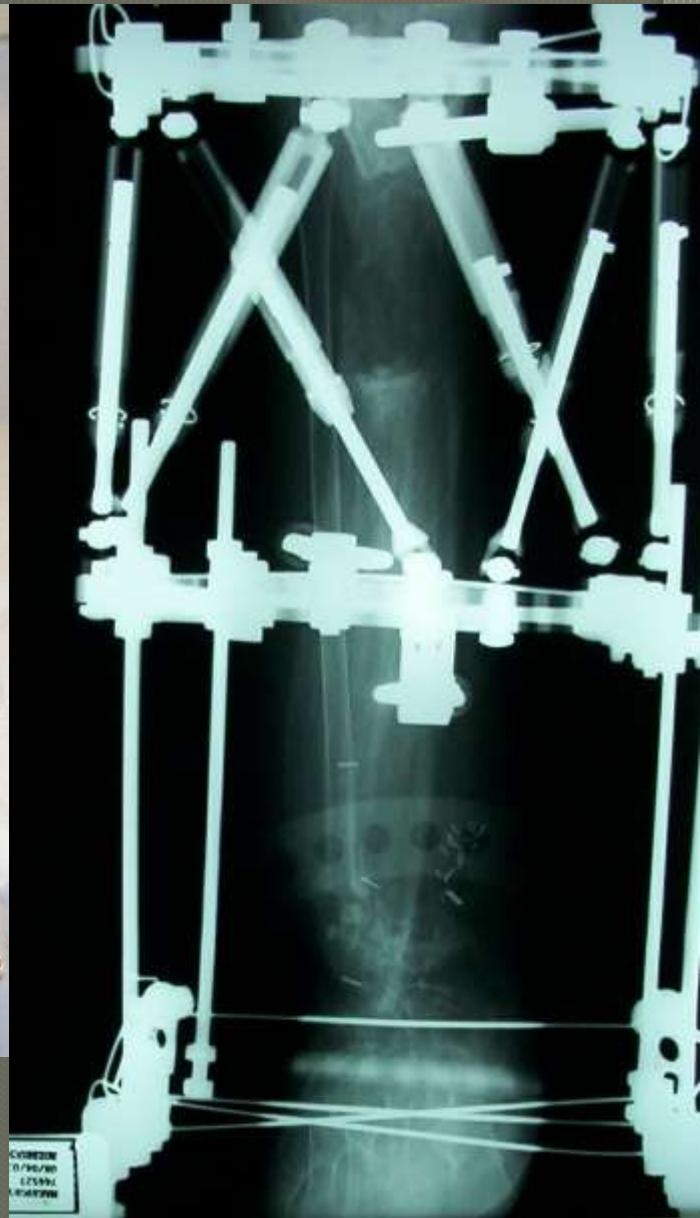
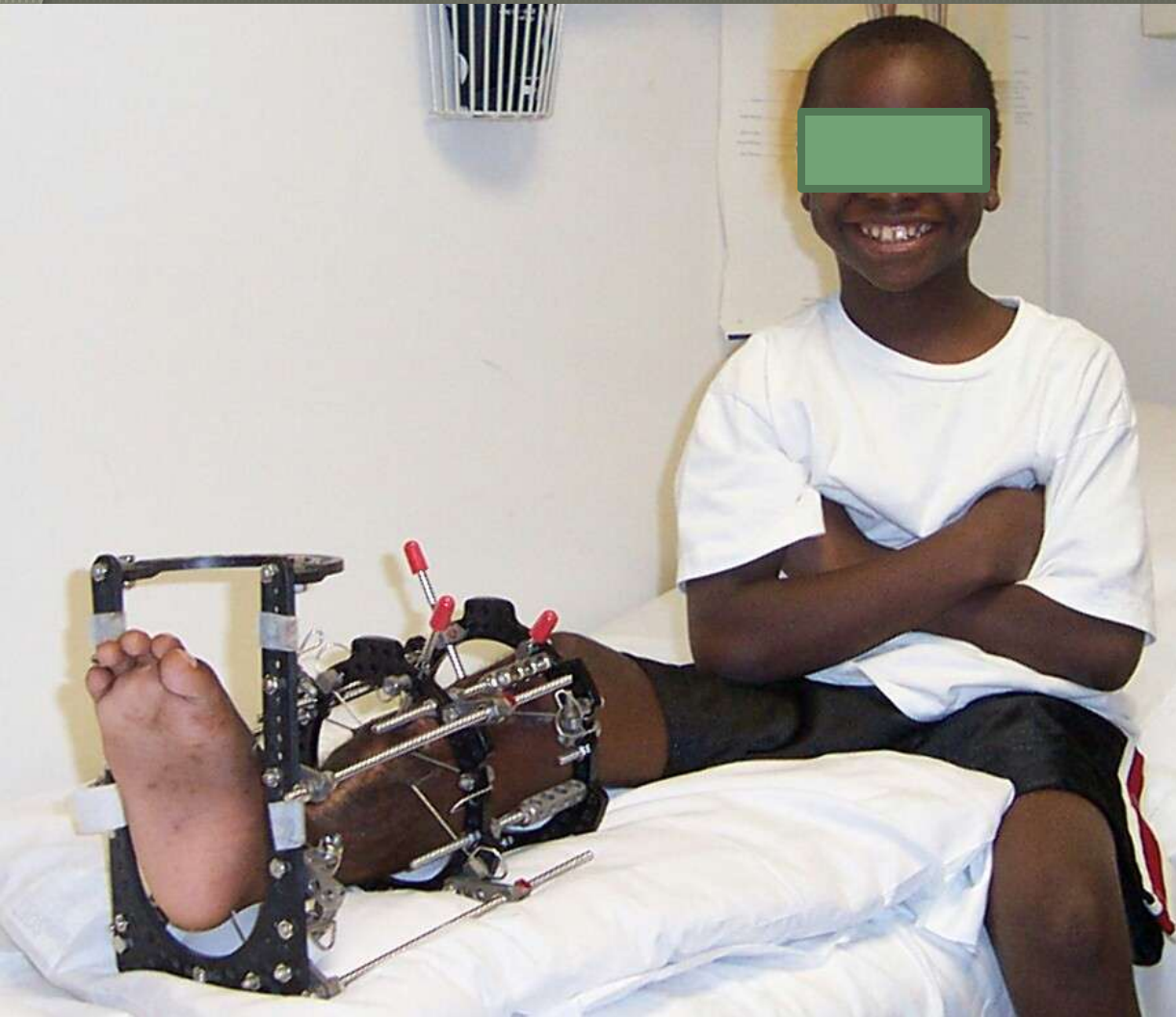




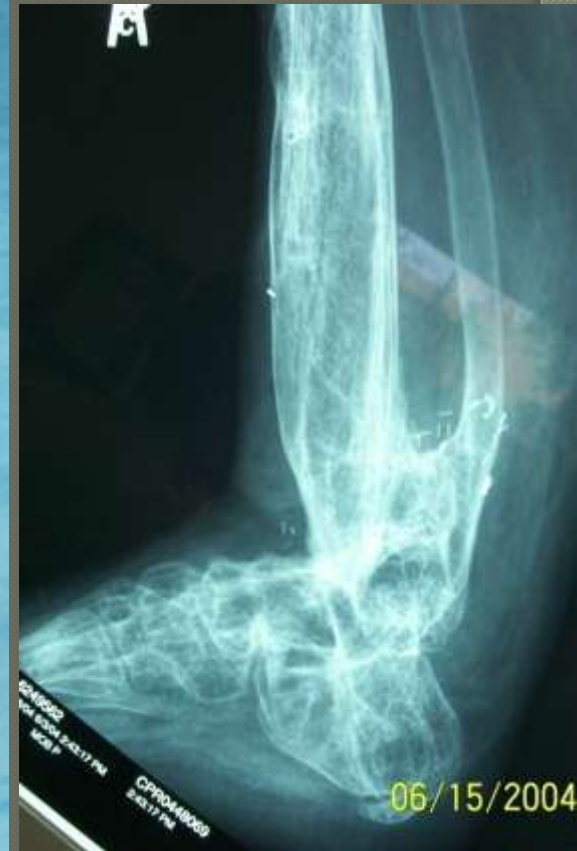
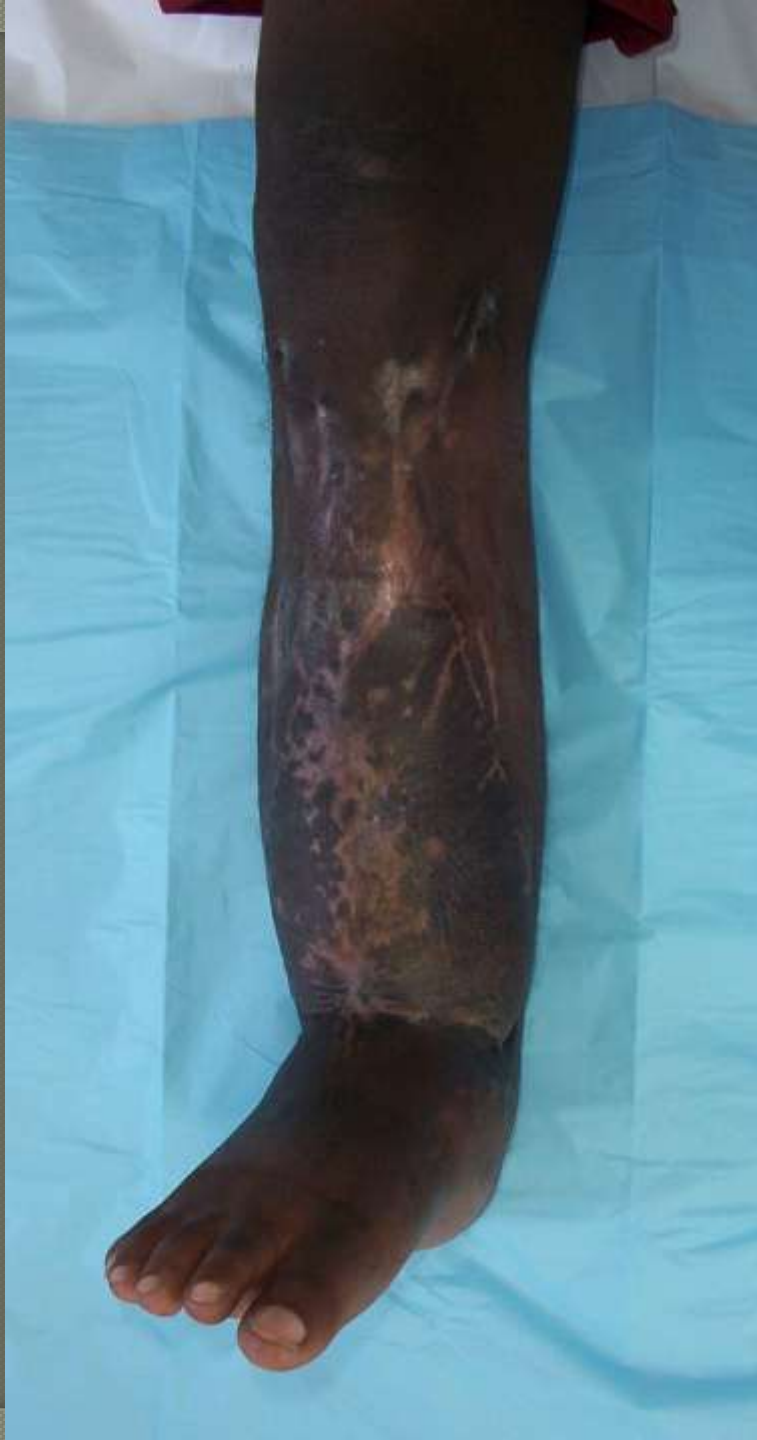
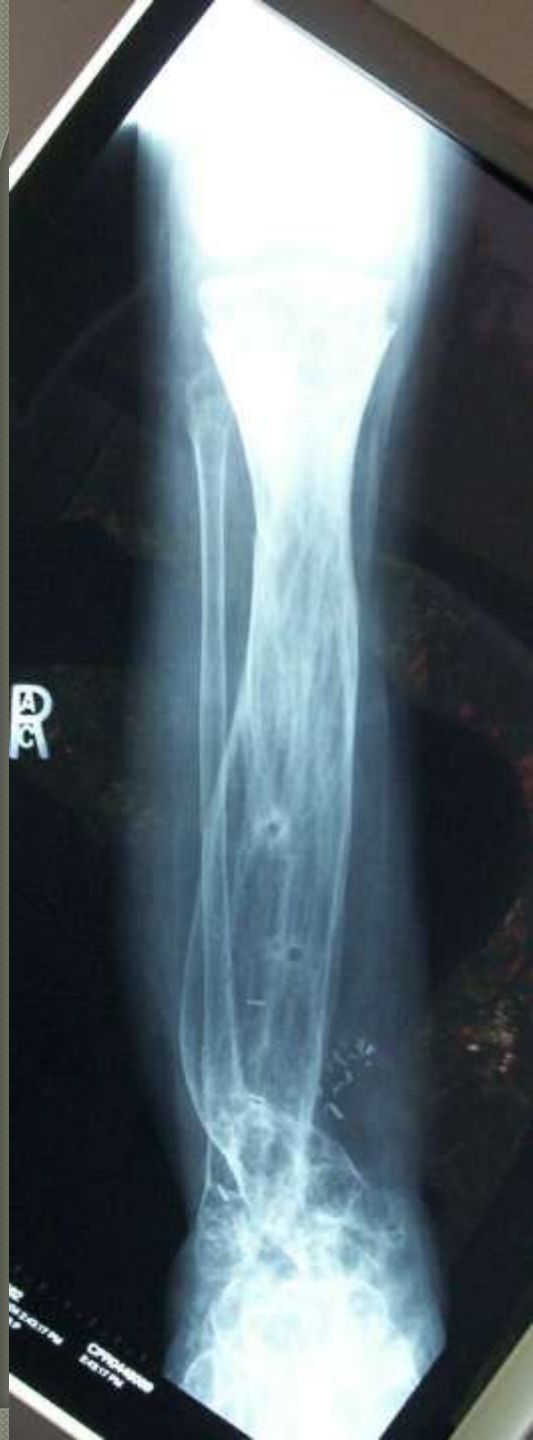

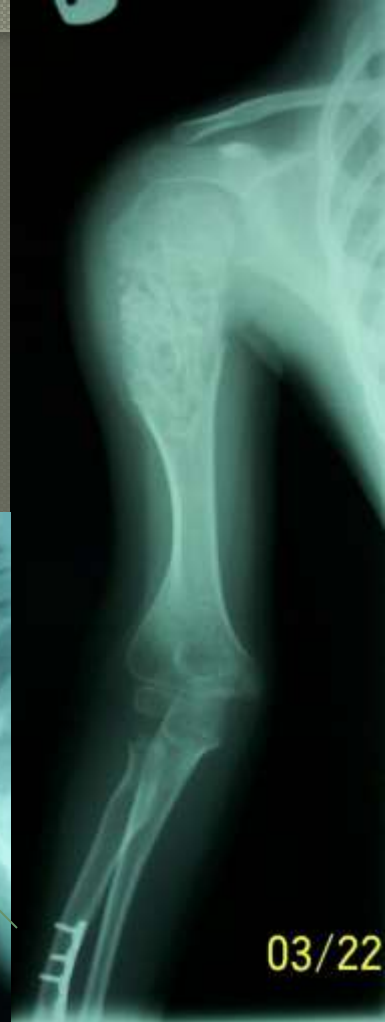





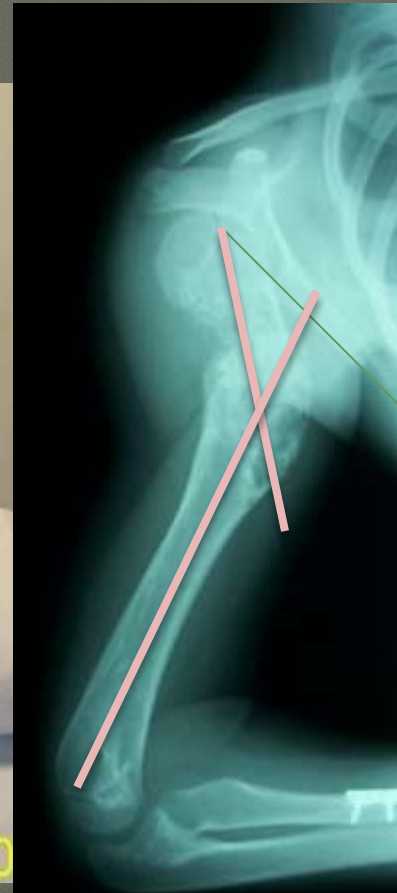
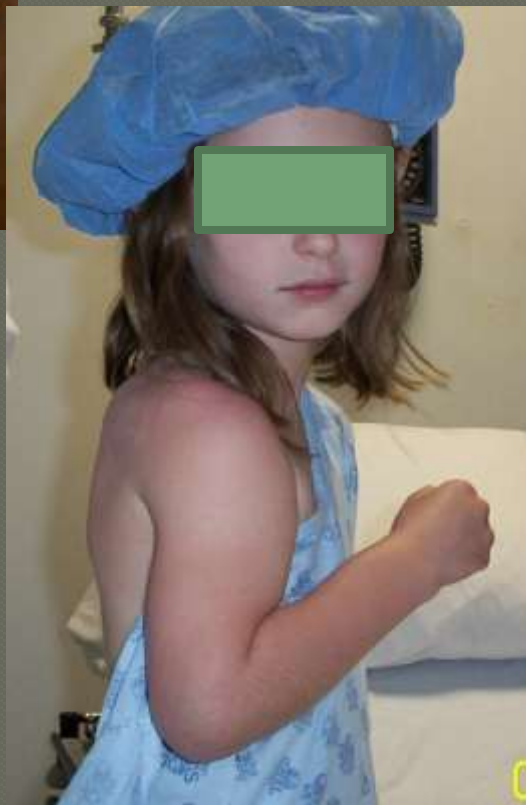


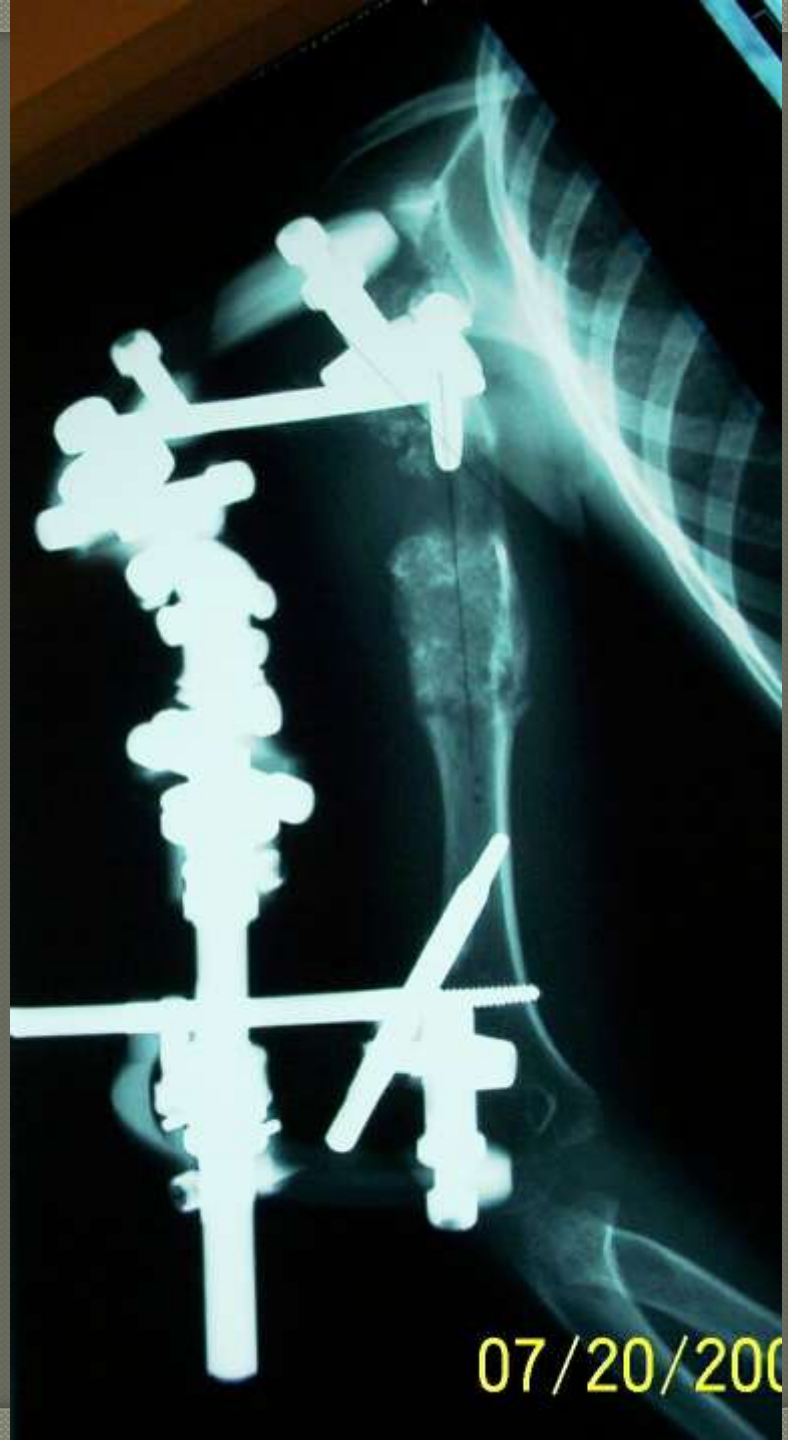


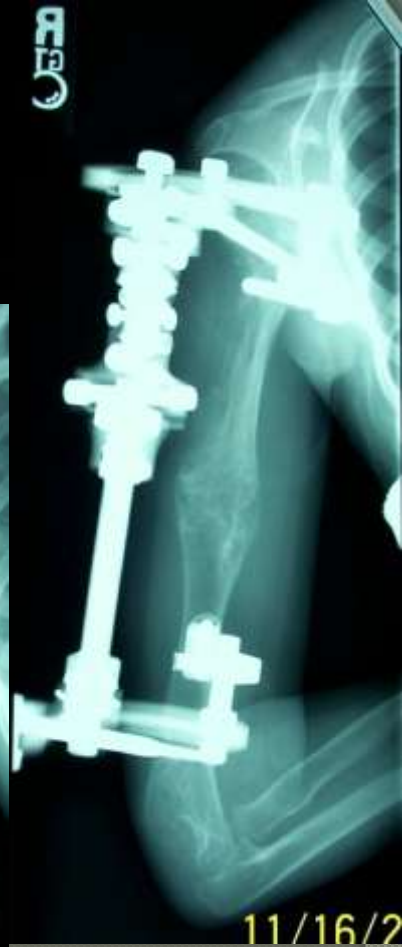
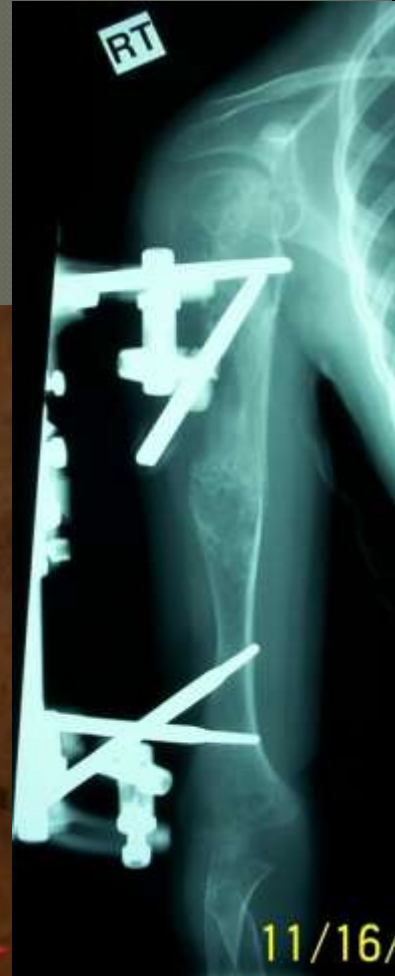
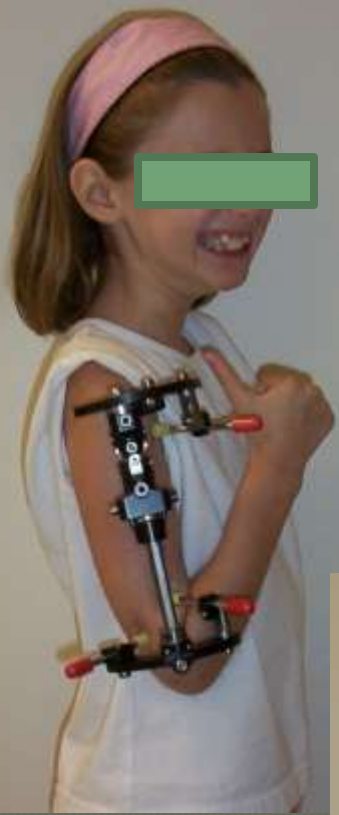
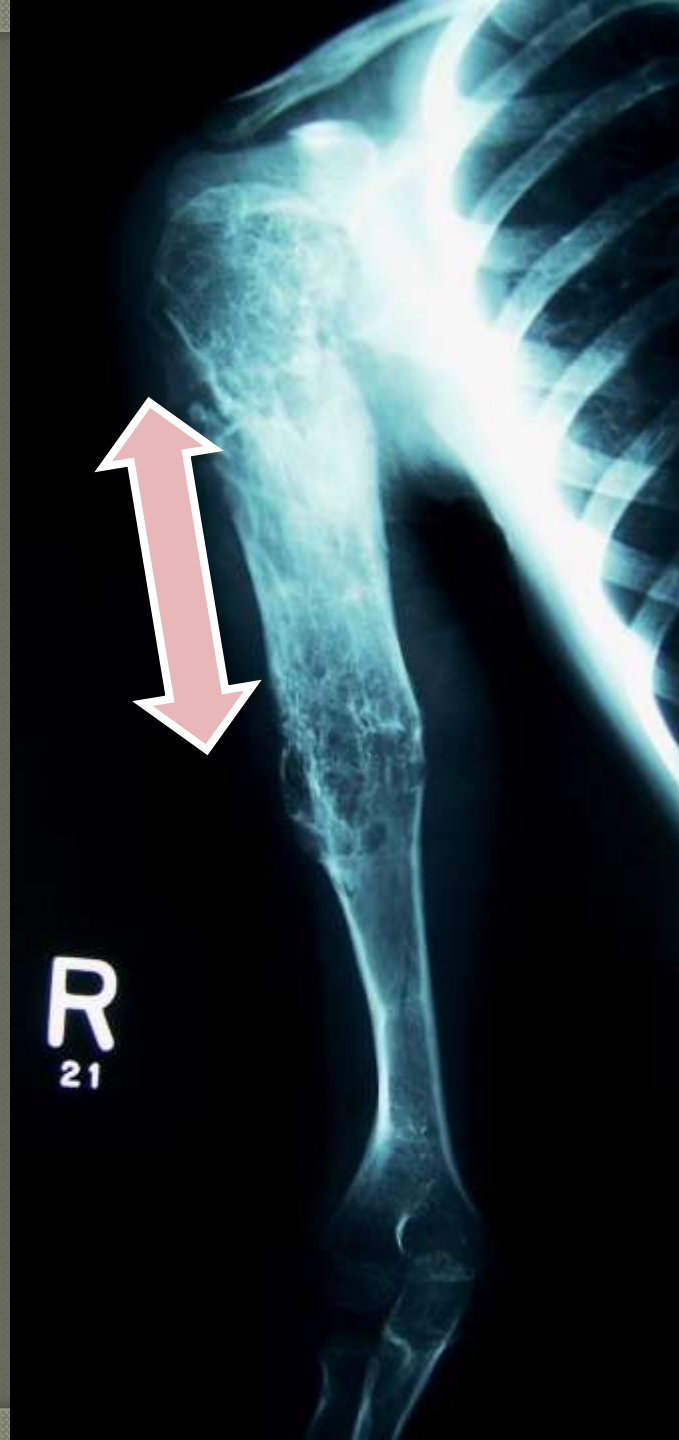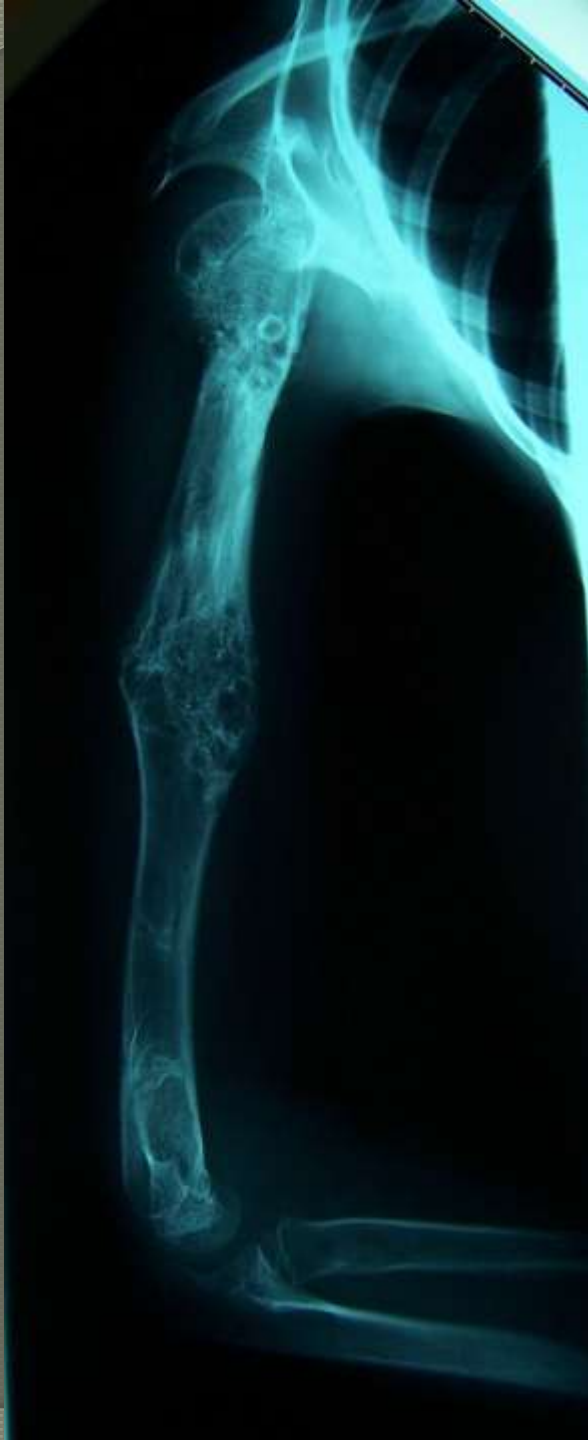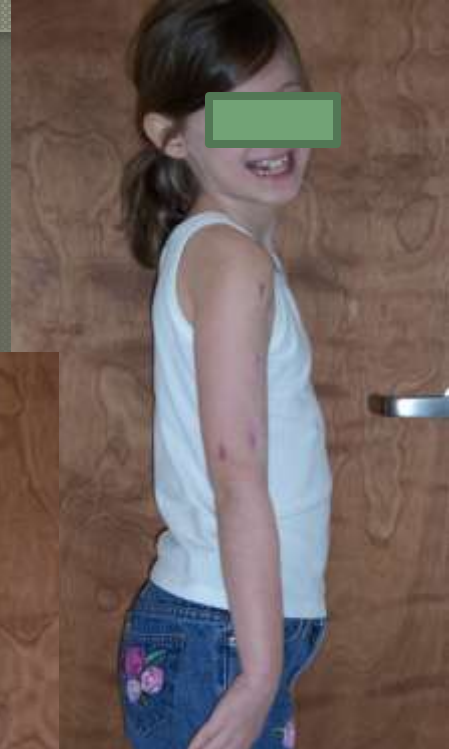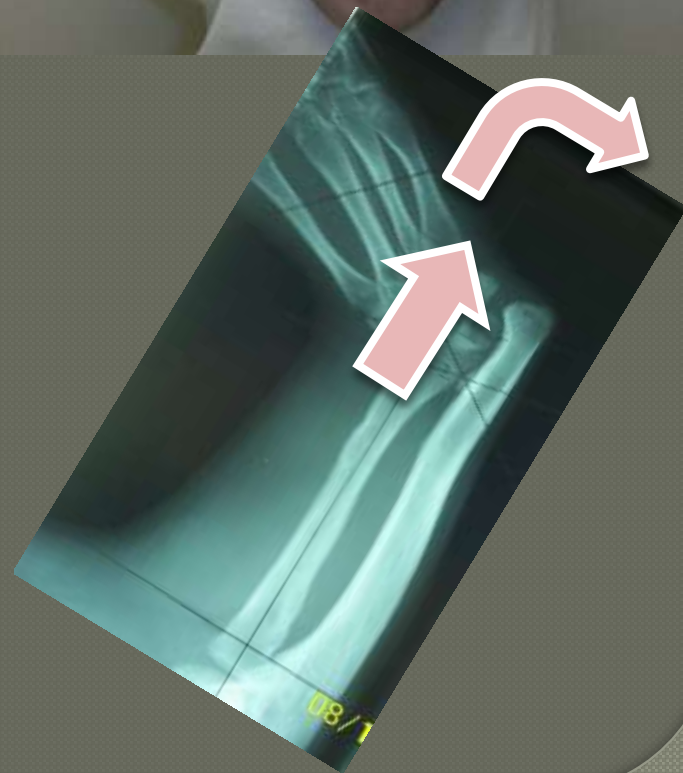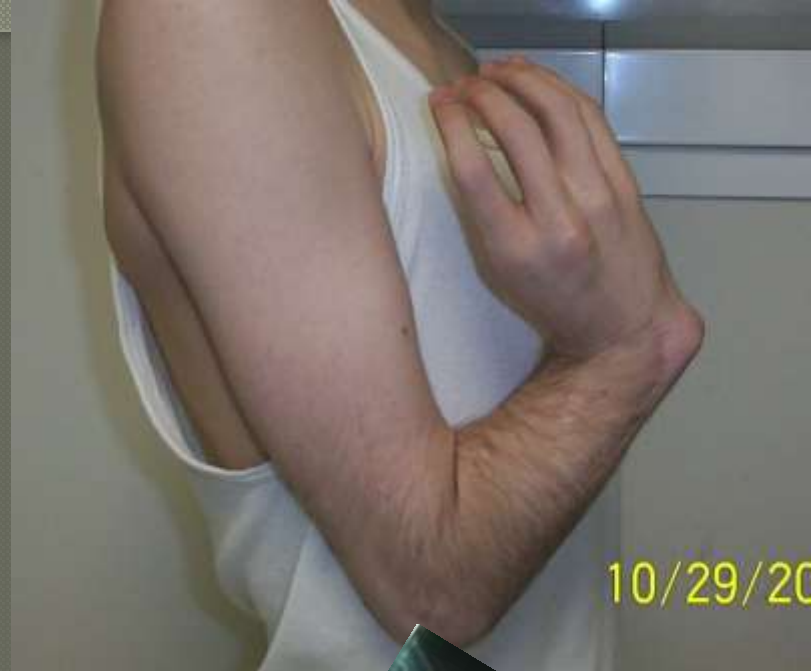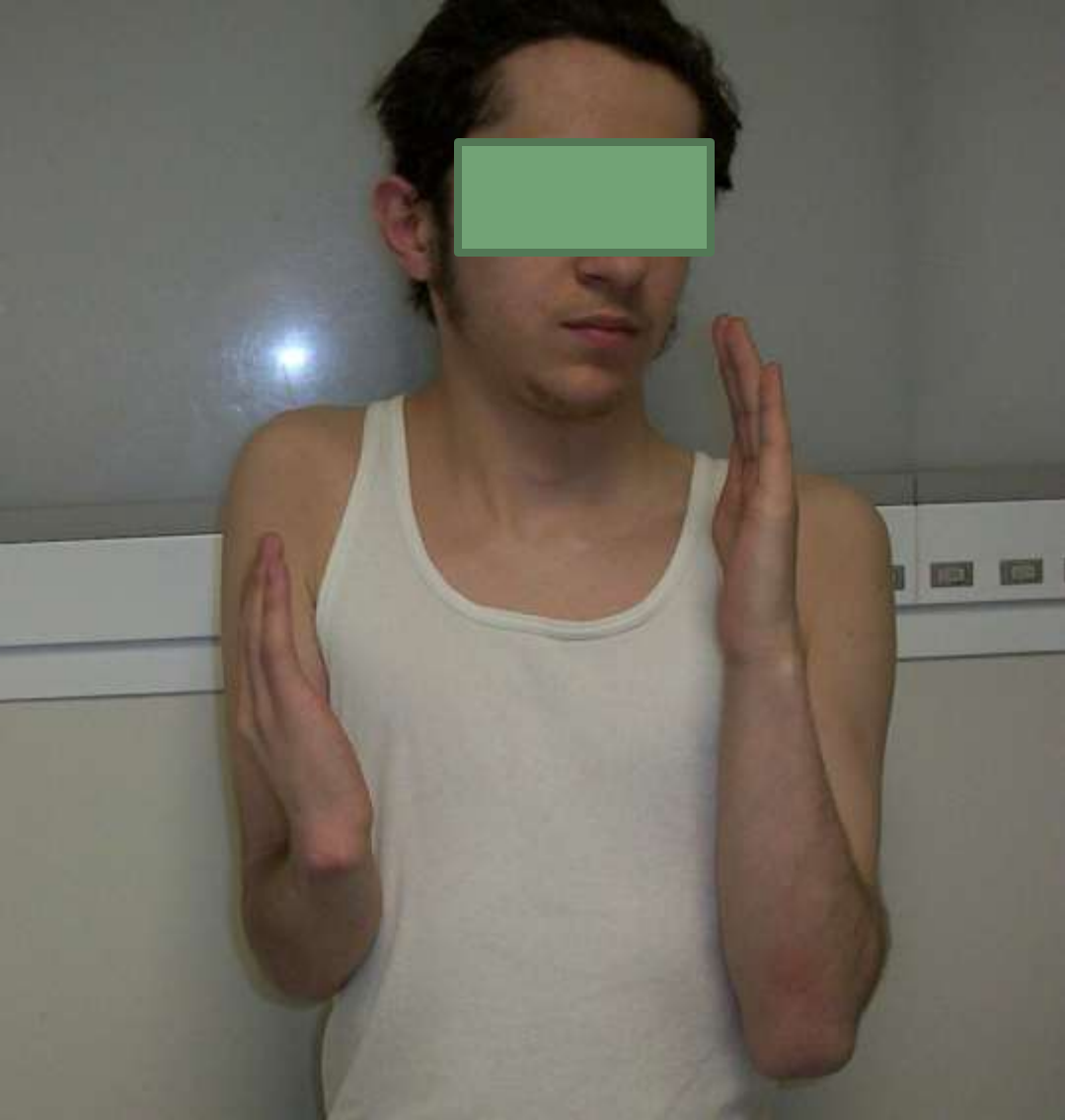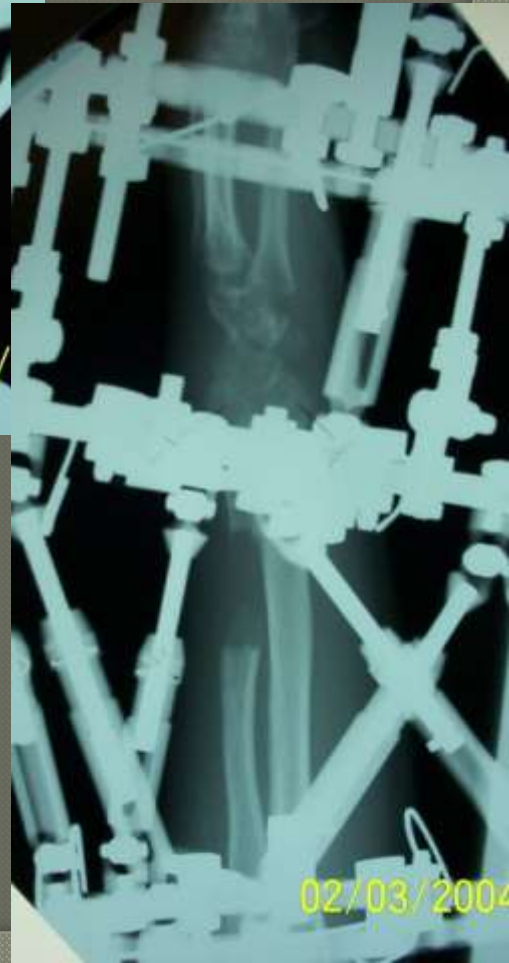
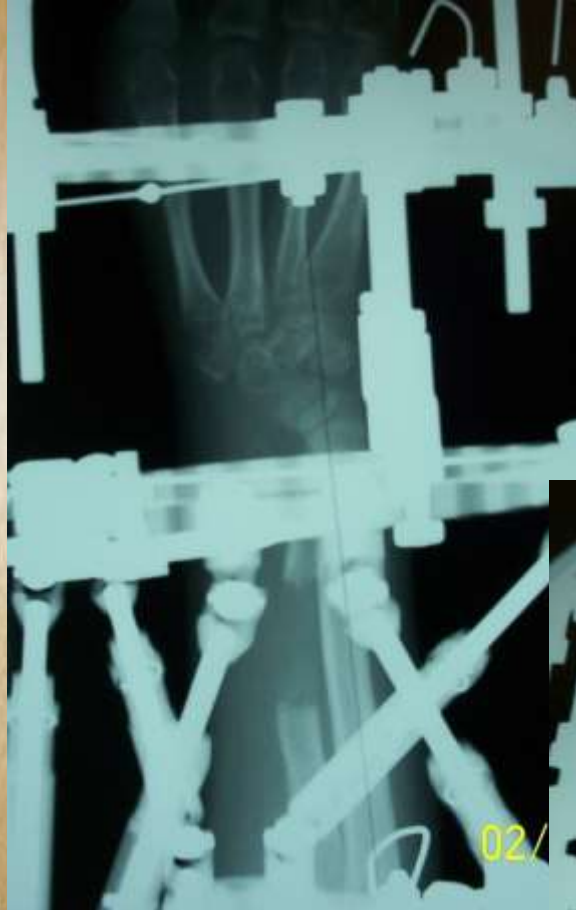
















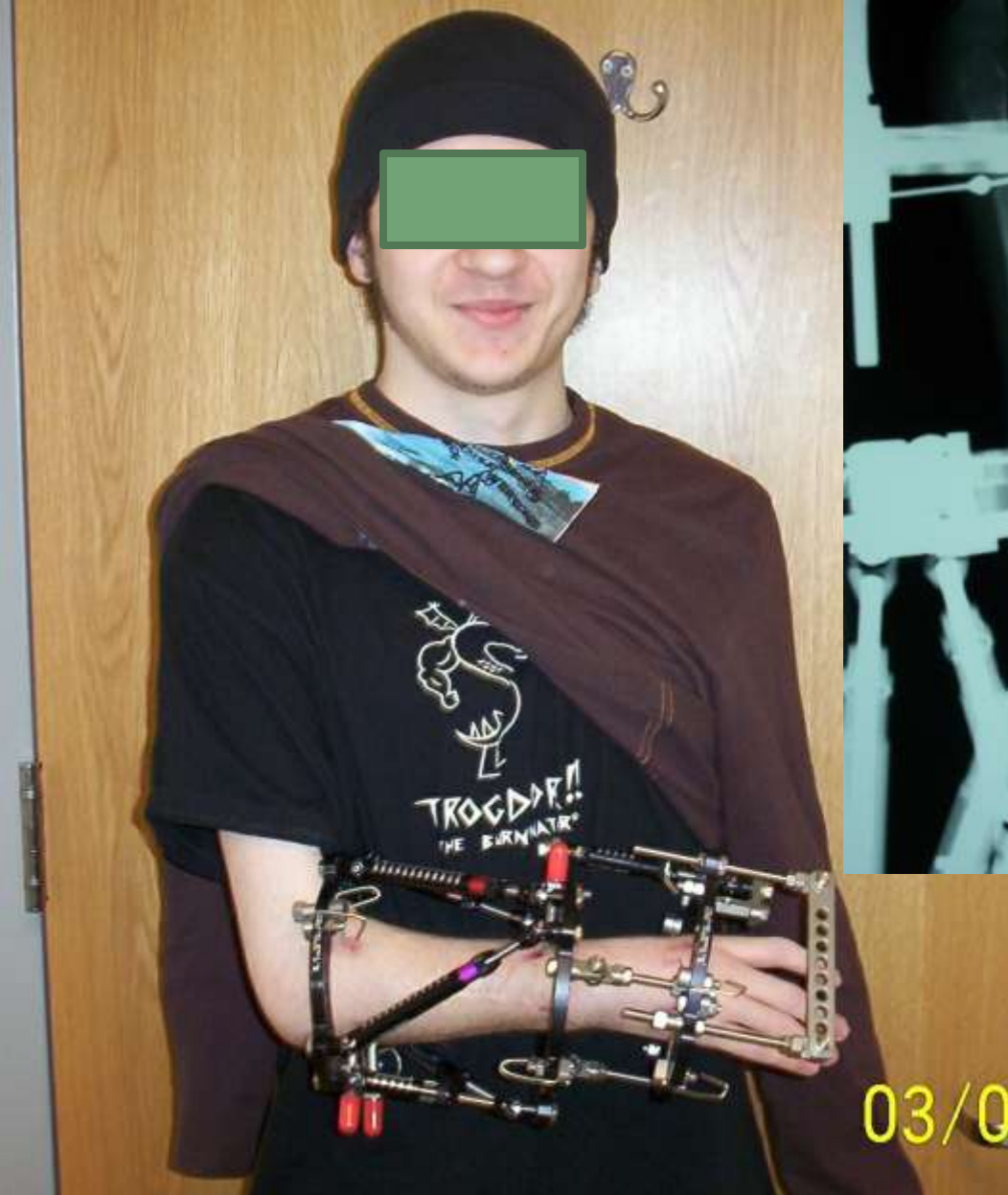

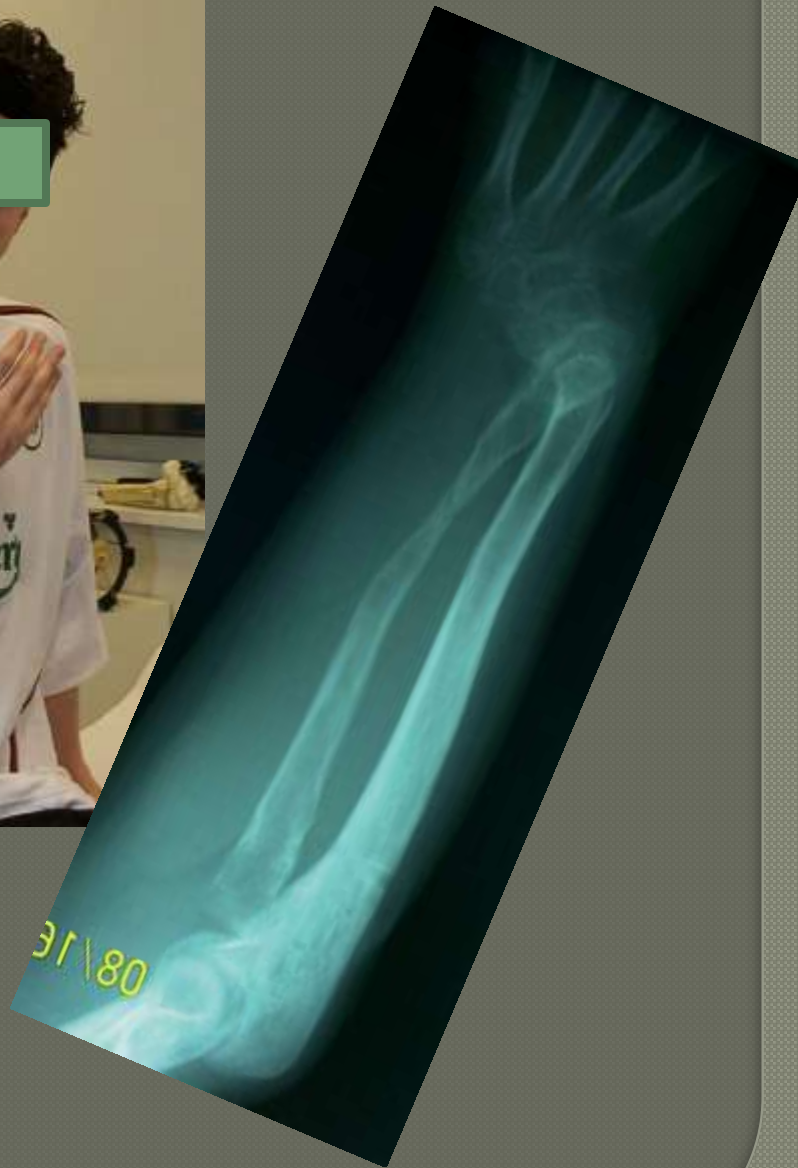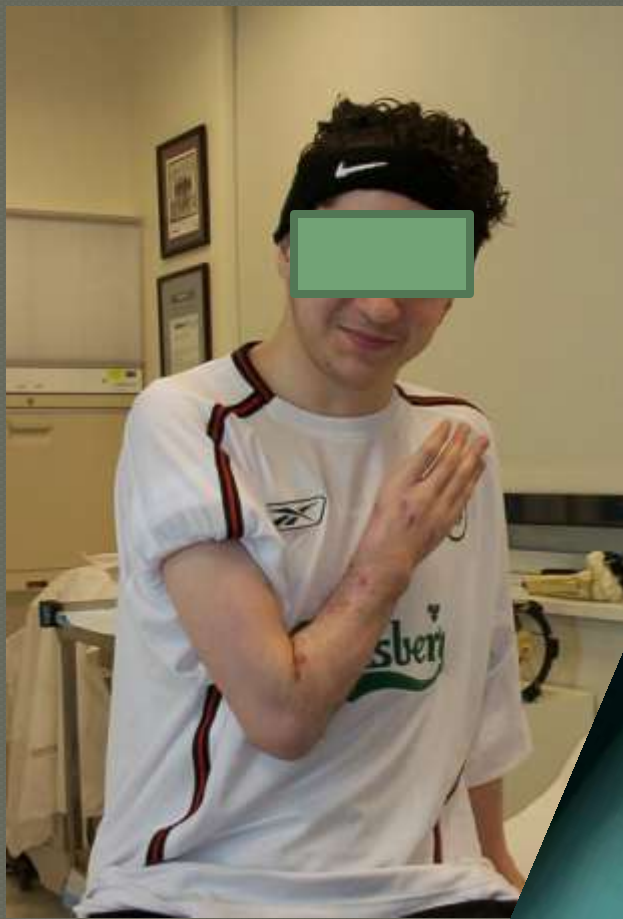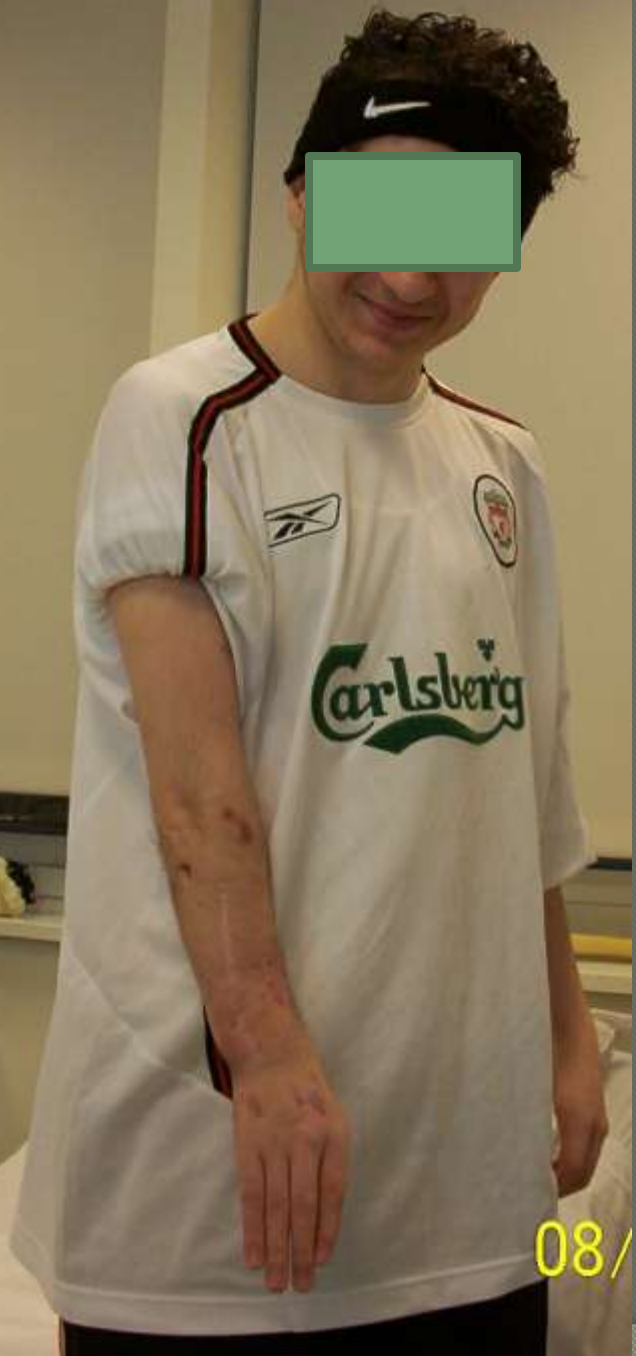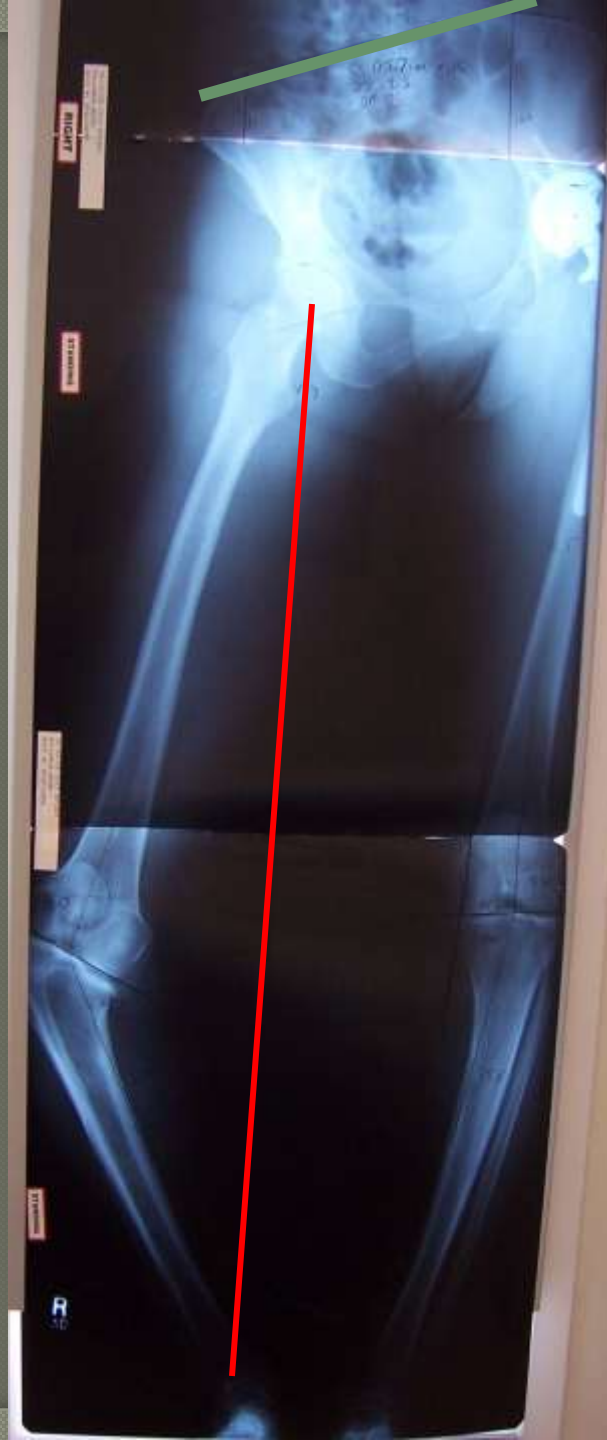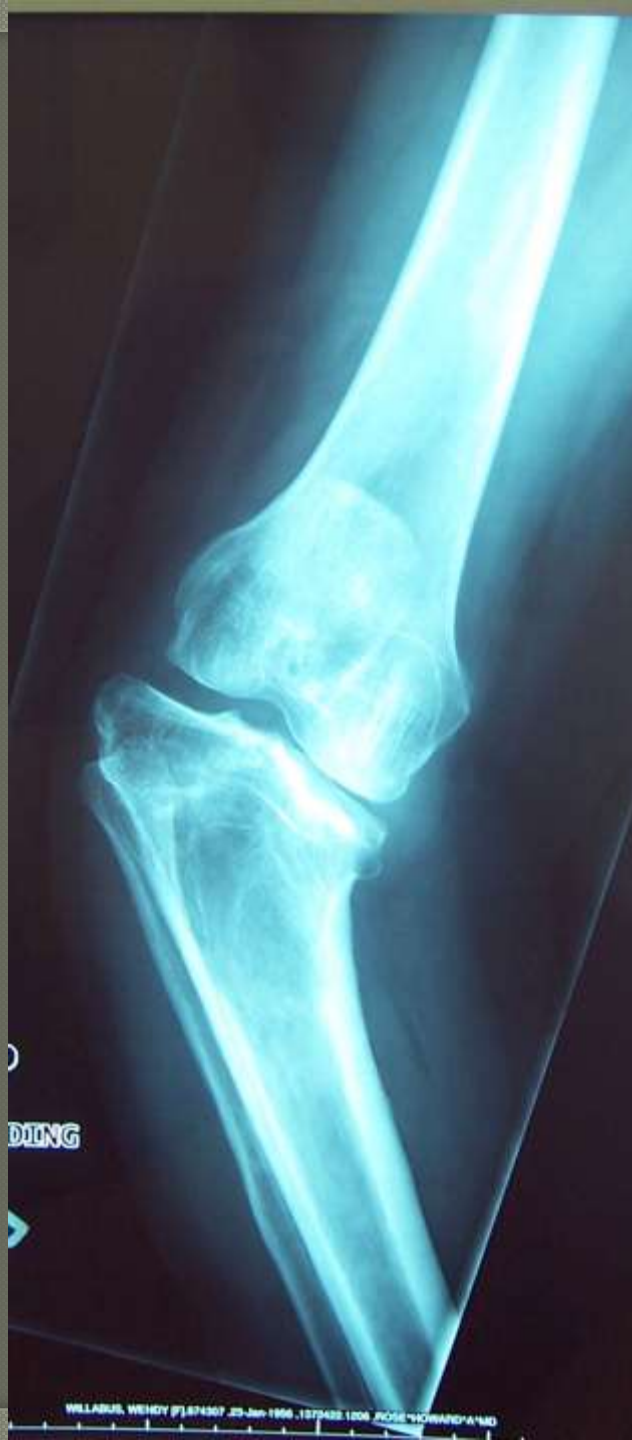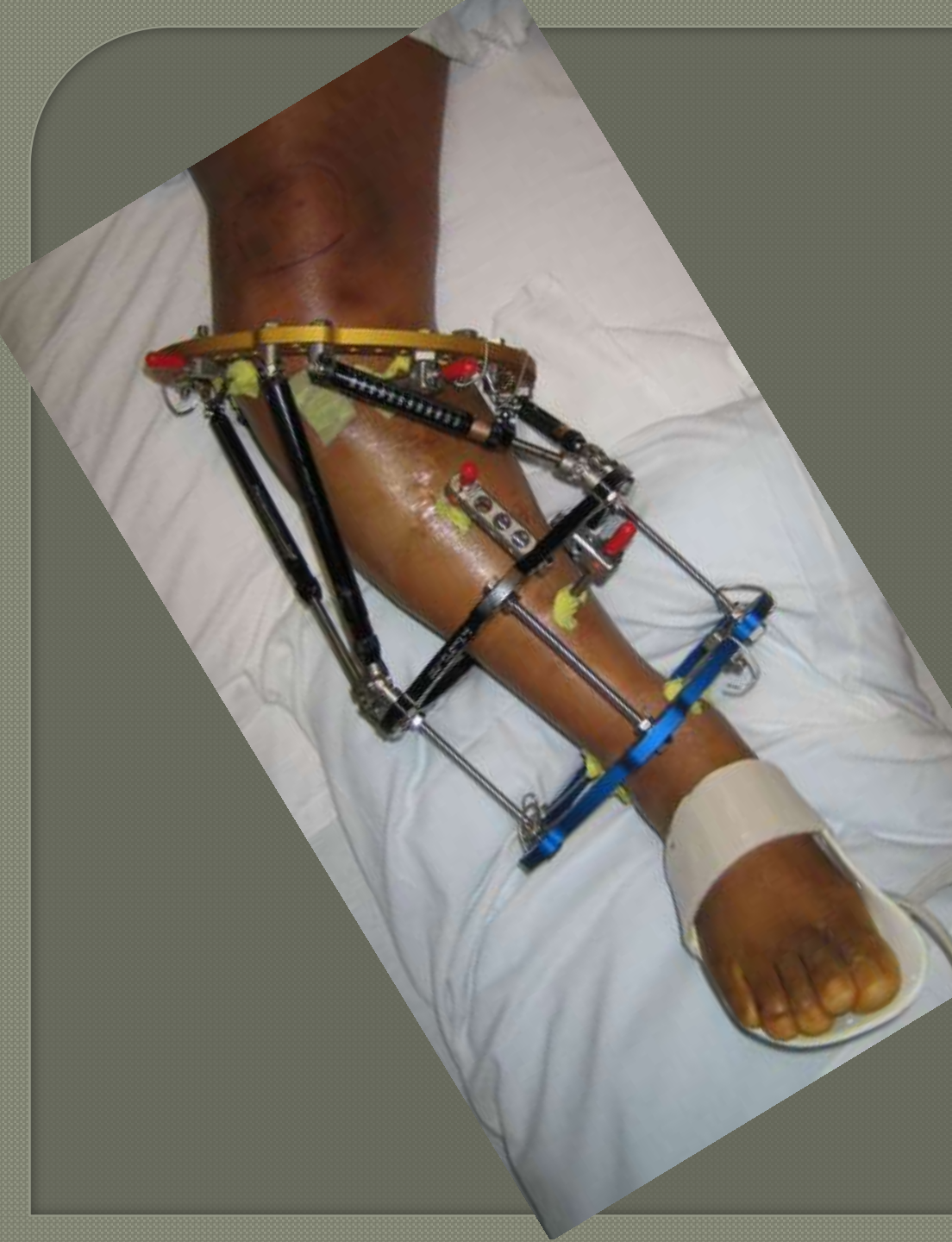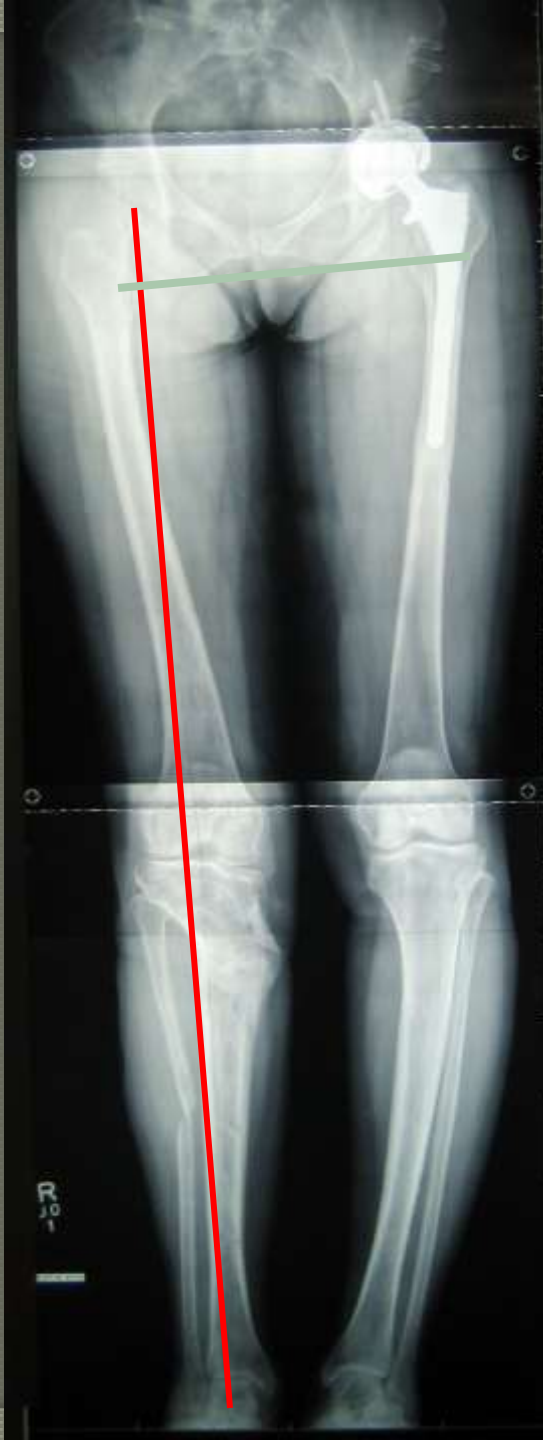Blount's Disease







Thank You



LIMB .COM

www.hss.edu/limblengthening