



**Limb Deformity Case Study #3:** Patient is a 10 ½ year old male who initially presented at three months of age with a history significant for osteomyelitis of the right femur & tibia, and septic knee with resultant growth arrest and varus angular deformity.

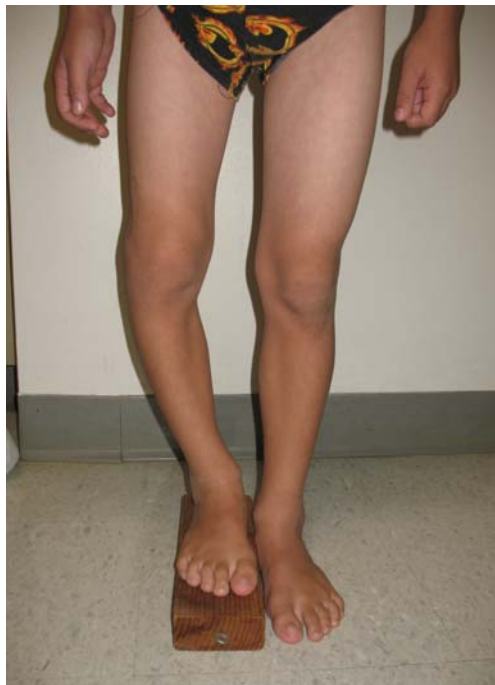Due to complex nature and significant resultant limb discrepancy that was predicted, a staged surgical plan was formulated to address the problems.

Stage 1: At five years of age, a four centimeter femoral lengthening was performed utilizing a Taylor Spatial Frame.

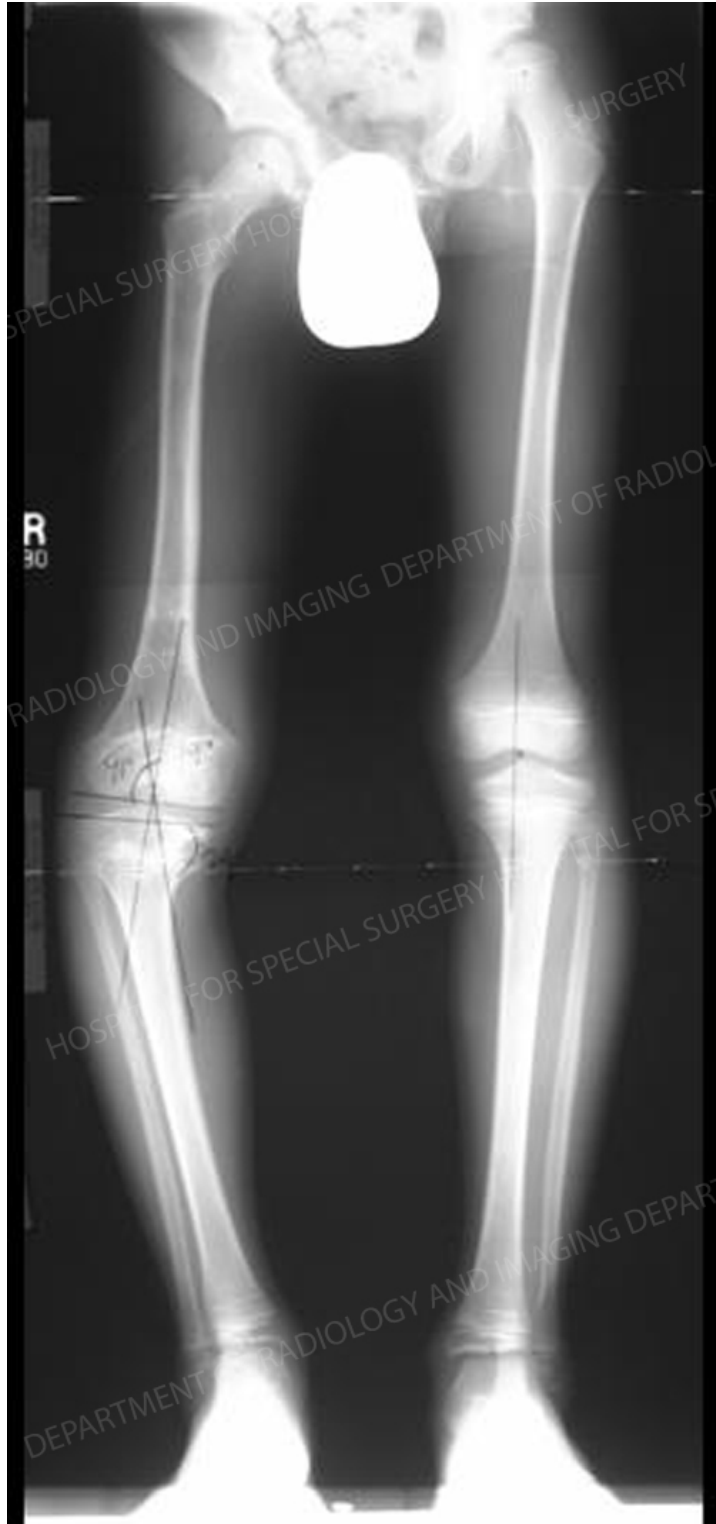Stage 2: At 8 ½ years of age, a 3/12 combined tibial/femoral lengthening was performed in conjunction with angular correction of the proximal tibia, utilizing an EBI monolateral fixator for the femur and a Taylor Spatial Frame for the tibia.

Stage 3: The plan is to perform a third lengthening procedure on the right and epiphysiodesis of the left distal femur at approximately 13 years of age.

Figures 1A and 1B: The image and x-ray demonstrate the patient's standing alignment and limb length discrepancy before the second stage of this treatment process.

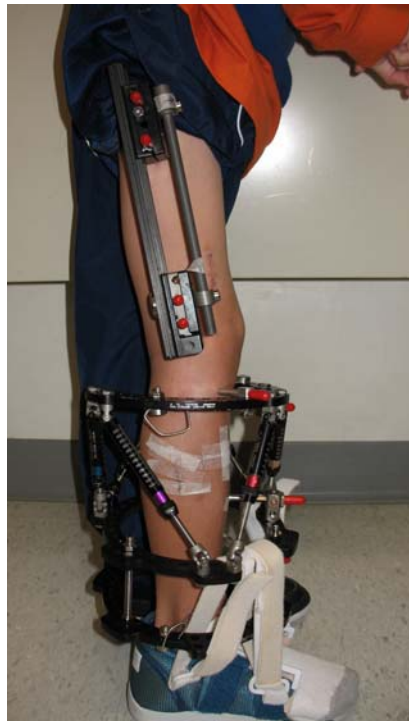
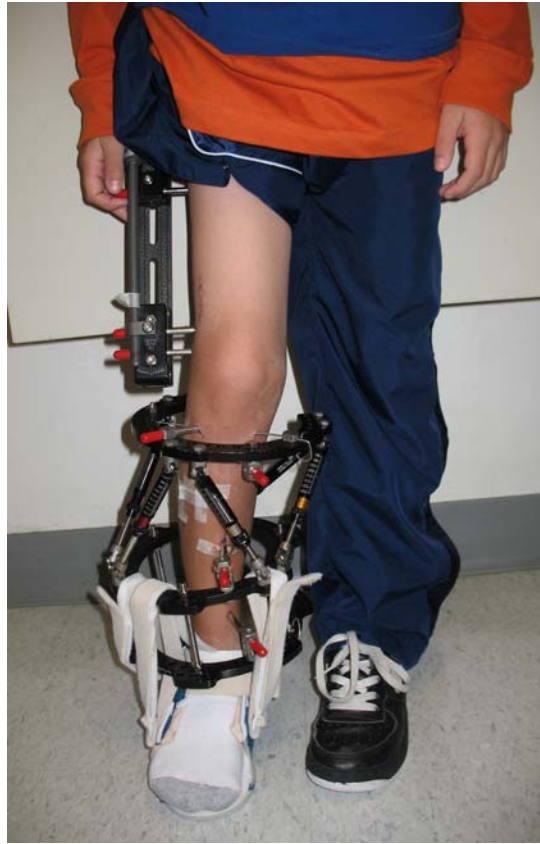

Cont'd next page...



Cont'd next page...

Figure 2: EBI monolateral femur frame and Taylor Spatial Tibial Frame utilized for the stage 2 procedure.



Cont'd next page...

