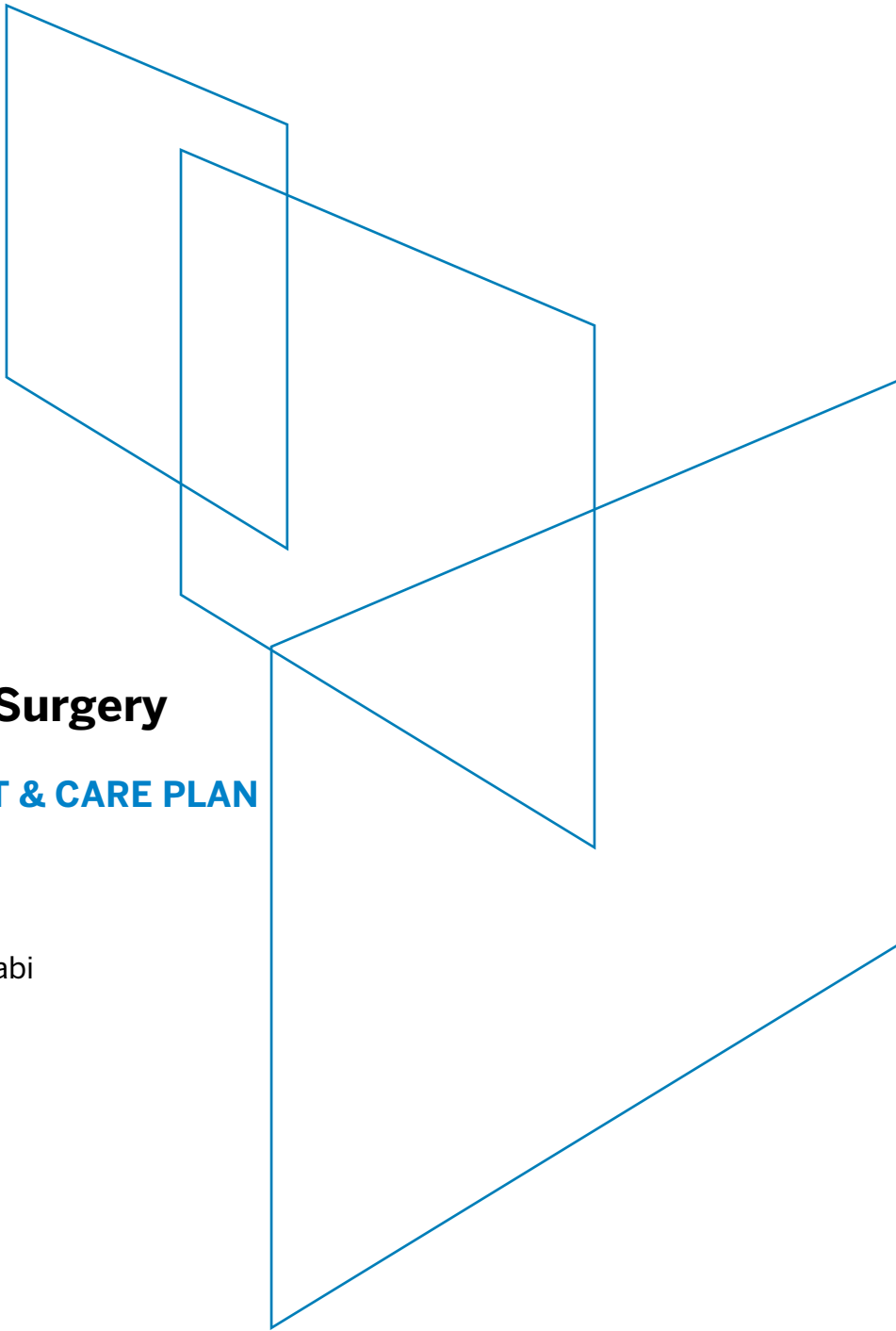



Hospital for Special Surgery

COMPREHENSIVE REPORT & CARE PLAN

HSS REMOTE 2nd Opinion

Rick Hannan | Dr. Danyal H. Nawabi
Prepared on 08/11/2020

Dr. Danyal H. Nawabi



About Dr. Nawabi

Dr. Danyal H. Nawabi is an orthopedic surgeon in the Sports Medicine Institute. He is a specialist in the fields of knee, shoulder, and hip surgery, performing both arthroscopic surgery and joint replacement.

Dr. Nawabi completed his medical training at Oxford University in England and residency in orthopedic surgery on the prestigious Percivall Pott Rotation in London, training at the Royal National Orthopaedic and the Royal London Hospitals. He was awarded the Sir Walter Mercer Gold Medal as the top graduating resident in the UK and served as the British Orthopaedic Association Young Ambassador in 2010. Following residency, he completed three years of advanced fellowship training in total joint replacement, sports medicine, and hip preservation at HSS, where he was a double recipient of the Philip D. Wilson Award for Excellence in Orthopaedic Surgery.

Dr. Nawabi has special expertise in ACL reconstruction, sports knee

and shoulder injuries, hip arthroscopy and robotic-assisted joint replacement in young and active patients. His expertise in sports knee and shoulder surgery was developed in London after completing a dedicated one year fellowship under the supervision of the internationally renowned sports surgeon, Dr. Andy Williams. During this fellowship he gained experience treating elite soccer athletes from Chelsea Football Club and other English Premier League clubs. He has served as an assistant team physician to the New York Red Bulls MLS franchise.

Dr. Nawabi's expertise in hip surgery was developed at HSS during a one year fellowship under the supervision of Dr. Bryan Kelly, who trained him to perform hip arthroscopy. During this year, Dr. Nawabi also spent time with Dr. Michael Leunig in Switzerland and Dr. Stefan Kreuzer in Texas gaining advanced training in performing computer-navigated direct anterior hip replacement. He has also been trained to perform hip resurfacing by his mentors in the UK and Dr. Edwin Su at HSS.

A strong research background in knee, hip, and shoulder surgery, Dr. Nawabi has authored over fifty peer-reviewed publications and delivered over 100 presentations at national and international conferences. He has been recognized with multiple awards by HSS and international societies for his academic accomplishments.

Dr. Nawabi believes in offering compassionate care and state-of-the-art solutions to his patients with sports injuries and arthritic conditions of the knee, shoulder, and hip joints.

Clinical Expertise

Knee:

ACL reconstruction (pediatric, adolescent, and adult)

PCL, MCL, posterolateral corner reconstruction

Revision ACL reconstruction

Meniscus and cartilage repair
Patella dislocation and MPFL reconstruction
Robotic-assisted partial knee replacement (MAKOplasty)
Total knee replacement

Shoulder/Elbow:

Shoulder arthroscopy
Rotator cuff repair
Superior capsule reconstruction
Shoulder stabilization for dislocation (arthroscopic and open)
Shoulder labrum repair
AC joint separation and reconstruction
Proximal biceps tenodesis and repair
Distal biceps repair
Pectoralis major repair

Hip:

Hip arthroscopy
Hip labrum repair and reconstruction
Proximal hamstring repair (open and endoscopic)
Abductor repair (open and endoscopic)
Surgical hip dislocation
Hip resurfacing
Robotic-assisted total hip replacement (MAKOplasty)
Direct anterior hip replacement

Education

MD, University of Oxford Medical Sciences Division
Fellowship, 2014, Hospital for Special Surgery, Hip Preservation Service
Fellowship, 2013, Hospital for Special Surgery, Sports Medicine Service
Fellowship, 2012, Hospital for Special Surgery, Adult Hip and Knee
Replacement (ARJR)

Awards

International Society of Hip Arthroscopy Basic Science Award, 2015, AAOS/OREF/ORS Clinician Scholar Career Development Program, 2014, American Orthopaedic Association (AOA) Emerging Leaders Program, 2014, Philip D. Wilson Award, 2014, ORS/OREF Award in Orthopaedic Research Translation, 2014, Lance Peters Memorial Biomechanics Award, 2013, Philip D. Wilson Award, 2012, Adult Reconstruction and Joint Replacement Fellowship Excellence Award, 2012, HCA International Foundation Scholarship, 2011, Charnley Latta Award, British Hip Society, 2011, Norman Capener Award, Royal College of Surgeons of England, 2010, British Orthopaedic Association Young Ambassador, 2010, Sir Walter Mercer Gold Medal, 2009

Your Expert Opinion

Patient Summary

79 yo male with an 8 month history of left hip pain. This was aggravated 3 months ago. Since then he has been limping, has constant pain, and is unable to go for walks. PMH is significant for CHD, hypertension, previous CABG and angioplasty.

Patient's Questions and Answers

1. Are there any additional diagnostic tests that you would recommend before determining next best steps?

No. There is enough information in the X-ray and MRI to recommend the next best steps.

2. Based upon the information provided, what is your opinion regarding the etiology of the patient's pain?

The etiology of the pain is osteoarthritis of the left hip. In this condition, loss of articular cartilage, inflammation of the synovium, subchondral cysts in the bone, and the associated labral tearing, all account for the pain.

3. Based on the information provided, what are the treatment options you would recommend and related pros/cons?

Since the pain and limited mobility is significantly affecting the patient's quality of life, my recommendation would be a total hip replacement.

PROS:

Immediate and reliable relief of pain.

Quick return to full mobility without walking aids (2-4 weeks after surgery).

Excellent post-operative function and mobility.

High satisfaction rate postoperatively according to almost all published scientific literature.

CONS:

There are potential complications associated with this surgery.

Fortunately the incidence is extremely low. These are as follows:

Infection = 0.4%

Dislocation = 1%

Fracture = 1%

Neurovascular Injury = 0.1%

Deep venous thrombosis = 1.5%

Leg length discrepancy = 1%

4. If THR is not the only choice at this point, do you believe that the pain could be addressed by arthroscopic surgery to repair the labrum? Please elaborate.

Arthroscopic surgery for advanced osteoarthritis (as this patient has), is doomed to fail. There are multiple studies in the scientific literature that have found that joint space narrowing <2 mm, subchondral cysts, and full-thickness cartilage loss, result in poor outcomes after hip arthroscopy performed for labral repair and correction of femoroacetabular impingement. Therefore, I feel there is absolutely no value in performing arthroscopic surgery in this case.

5. Are there non-surgical approaches to treatment that might delay the need for THR?

There are two non-surgical approaches that can be considered:

1. Physical therapy directed at increasing range of motion and strengthening and conditioning the muscles around the hip.
2. Hip injections consisting of either cortisone, viscosupplementation or platelet-rich plasma/stem cells.

Both these treatment modalities are likely to result in only temporary relief ranging from a few weeks to a few months.

6. Even if arthroscopic or non-surgical approaches are possible at this time, do you believe that the arthritis will ultimately progress to the point where THR is inevitable?

Yes.

7. What is the significance of the intraosseous cyst formation and surrounding bone marrow edema?

Both of these findings are common features of advanced hip arthritis and are directly responsible for the severe pain experienced by the patient.

8. What is the significance of the full thickness cartilage loss in the superolateral aspect of the hip?

This is another reason for the severe pain experienced by the patient.

9. What is the significance of the high grade tear in the ligamentum teres?

Once again, this is a feature of advanced arthritis of the hip, and also responsible for the pain and instability experienced by the patient.

10. If THR is a consideration, what is your opinion about anterior versus posterior approach?

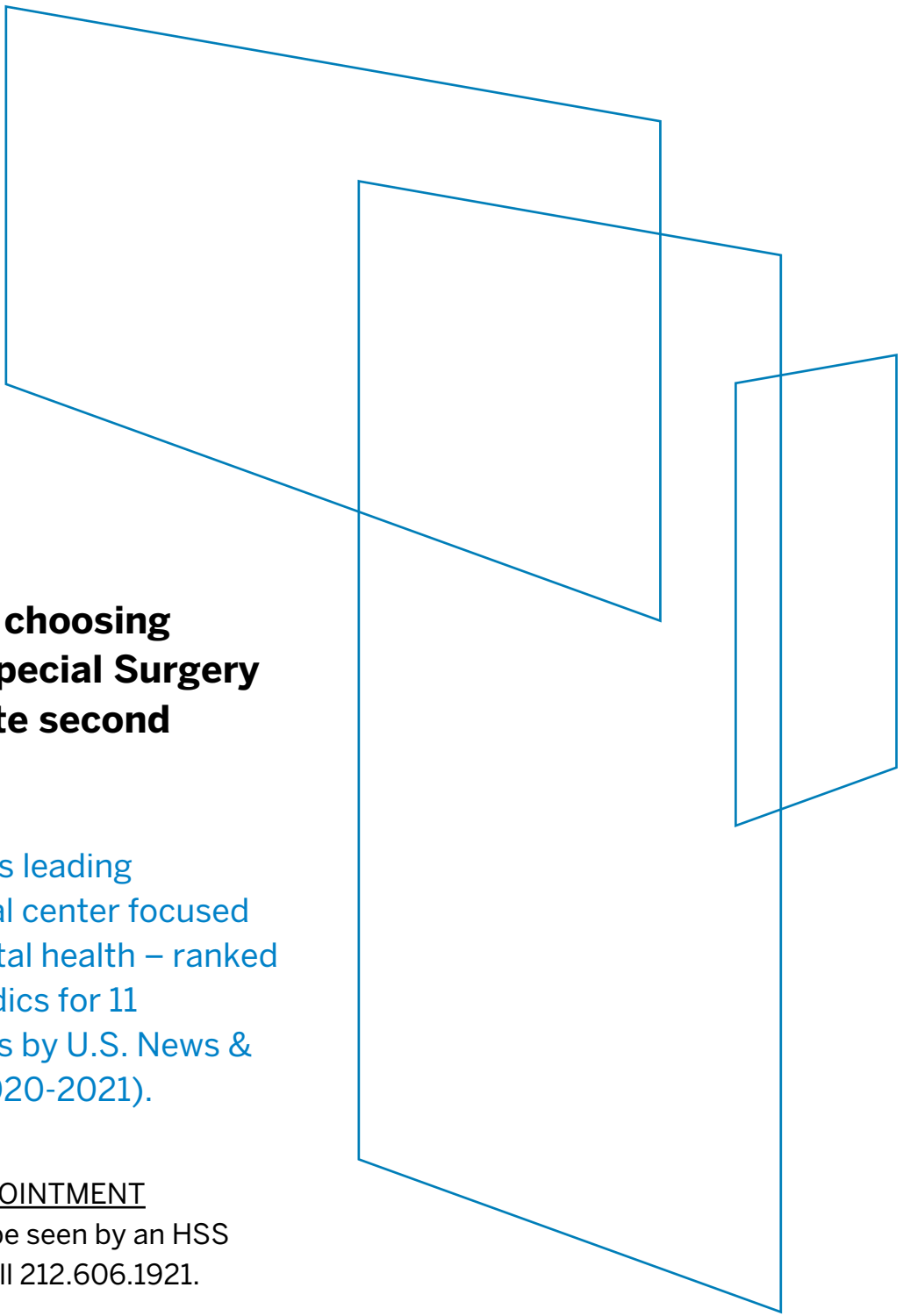
They are both excellent approaches and I perform both of them in my patients. The indications for an anterior approach are quite specific and therefore I make a determination of the candidacy of the patient for the anterior approach when I see them in clinic. On the whole, if I can safely do the anterior approach for the patient, I do it, based on the fact that it is muscle sparing and potentially less painful in the first 6 weeks after surgery.

11. What are the expected steps and timeline to recovery (hospitalization, ambulation, rehab etc) from THR if all goes as expected with the surgery?

1. Inpatient stay 2 nights.
2. Crutches 2 weeks.
3. Outpatient PT for 3 months.
4. Return to full unrestricted activity after 3 months.

12. If arthroscopic surgery is a consideration (and not aTHR), what are the expected steps and timeline to recovery (hospitalization, ambulation, rehab etc) if all goes as expected?

Not applicable in this case.



**Thank you for choosing
Hospital for Special Surgery
for your remote second
opinion.**

HSS is the world’s leading academic medical center focused on musculoskeletal health – ranked no. 1 for orthopedics for 11 consecutive years by U.S. News & World Report (2020-2021).

SCHEDULE AN APPOINTMENT

If you would like to be seen by an HSS physician, please call 212.606.1921.

*The second opinion is not intended for use in any legal dispute including but not limited to litigation, arbitration, claim for disability benefits, claim for worker’s compensation and/or malpractice claims without the prior written consent of HSS.