

A Comparison of Femoral Lengthening Methods Favors the Magnetic Internal Lengthening Nail When Compared with Lengthening Over a Nail

**Austin T. Fragomen, Anton M. Kurtz,
Jonathan R. Barclay, Joseph Nguyen &
S. Robert Rozbruch**

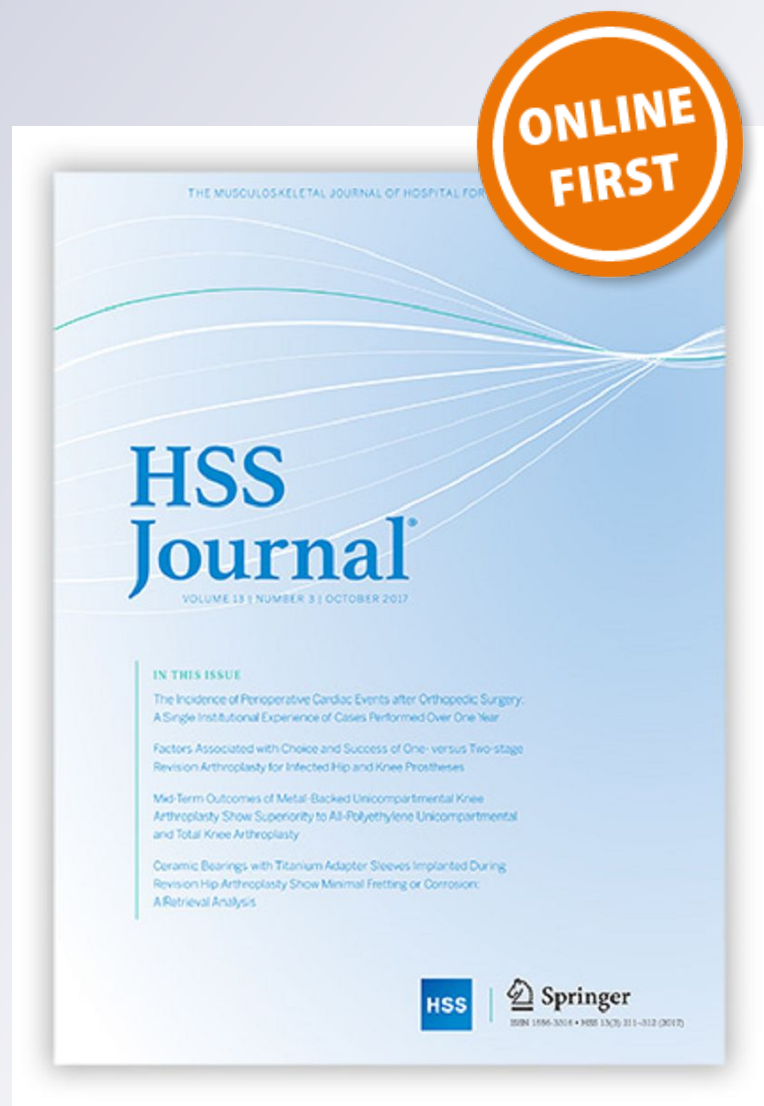HSS Journal®

The Musculoskeletal Journal of Hospital
for Special Surgery

ISSN 1556-3316

HSS Jnl

DOI 10.1007/s11420-017-9596-y



Your article is protected by copyright and all rights are held exclusively by Hospital for Special Surgery. This e-offprint is for personal use only and shall not be self-archived in electronic repositories. If you wish to self-archive your article, please use the accepted manuscript version for posting on your own website. You may further deposit the accepted manuscript version in any repository, provided it is only made publicly available 12 months after official publication or later and provided acknowledgement is given to the original source of publication and a link is inserted to the published article on Springer's website. The link must be accompanied by the following text: "The final publication is available at link.springer.com".

A Comparison of Femoral Lengthening Methods Favors the Magnetic Internal Lengthening Nail When Compared with Lengthening Over a Nail

Austin T. Fragomen, MD · Anton M. Kurtz, MD · Jonathan R. Barclay, BS · Joseph Nguyen, MPH · S. Robert Rozbruch, MD

Received: 2 August 2017/Accepted: 16 November 2017
© Hospital for Special Surgery 2018

Abstract *Background:* Bone lengthening with an internal lengthening nail (ILN) avoids the need for external fixation and requires one less surgical procedure than lengthening over a nail (LON). However, LON has been shown to be superior to femoral internal lengthening using a mechanical nail. The magnetic ILN, a remote-controlled and magnet-driven device, may have overcome the weaknesses of earlier internal lengthening technology and may be superior to LON. *Questions/Purposes:* (1) Is the magnetic ILN more accurate than LON for femoral lengthening? (2) Does the magnetic ILN demonstrate more precise distraction rate control than LON? (3) Does the magnetic ILN result in faster regenerate site healing, with more robust callus, than LON? (4) Does the magnetic ILN result in fewer complications, including impediments to knee motion, than LON? *Methods:* We conducted a retrospective comparison of the records and radiographs of 21 consecutive patients with 22 femoral lengthenings using LONs and 35 consecutive

patients with 40 femoral lengthenings using remote-controlled magnetic ILNs. Primary outcomes measured included accuracy, distraction rate precision, time to bony union, final knee range of motion, regenerate quality, and complications. The minimum follow-up times for the LON and ILN cohorts were 13 and 21 months, respectively. *Results:* Patients treated with ILN had a lower post-treatment residual limb-length discrepancy (0.3 mm) than those treated with LON (3.6 mm). The rate of distraction was closer to the goal of 1 mm/day and more tightly controlled for the ILN cohort (1 mm/day) than that for the LON group (0.8 mm/day; SD, 0.2). Regenerate quality was not significantly different between the cohorts. Bone healing index for ILN was not statistically significant. Time to union was shorter in the ILN group (3.3 months) than that in the LON group (4.5 months). A lower percentage of patients experienced a complication in the ILN group (18%) than in the LON group (45%). Knee flexion at the end of distraction was greater for ILN patients (105°) than that for LON patients (88.8°), but this difference was no longer observed after 1 year. *Conclusions:* Femoral lengthening with magnetic ILN was more accurate than with LON. The magnetic ILN comports the additional advantage of greater precision with distraction rate control and fewer complications. Both techniques afford reliable healing and do not significantly affect knee motion at the final follow-up. The magnetic ILN method showed no superiority in regenerate quality and healing rate.

Level of Evidence: Therapeutic Study: Level III

Investigation performed at the Hospital for Special Surgery, New York, NY

Electronic supplementary material The online version of this article (<https://doi.org/10.1007/s11420-017-9596-y>) contains supplementary material, which is available to authorized users.

A. T. Fragomen, MD (✉) · J. Nguyen, MPH · S. R. Rozbruch, MD
Hospital for Special Surgery,
Weill Medical College of Cornell University,
535 East 70th Street,
New York, NY 10021, USA
e-mail: FragomenA@HSS.edu

A. M. Kurtz, MD
Maine Orthopedics,
Portland, ME, USA

J. R. Barclay, BS
Weill Cornell Medical College,
New York, NY 10065, USA

Keywords internal lengthening nail · PRECICE · lengthening over a nail · limb lengthening

Introduction

External fixation has provided the stability and adjustability needed for successful femoral bone lengthening [5, 14, 26]. However, reliable, external fixation has been marred by patient dissatisfaction with pin site pain (and need for extended opioid use), infection (and antibiotic-related complications) [6, 8, 15], knee stiffness [2, 12, 16, 21], and the

need for clothing modification [22]. The lengthening over a nail (LON) technique [29] was introduced to reduce the time patients needed to wear the external fixator by combining the simultaneous use of internal and external fixation, a concept called “integrated fixation” [1]. LON requires a two-stage surgical approach; the first surgery entails intramedullary (IM) nail insertion and external fixator (frame) application with pin insertion outside of the path of the nail. This is followed by a second surgery, at the completion of lengthening, to insert locking screws into the nail and remove the frame. The benefit is that the frame is no longer needed during the consolidation period (while the lengthened bone unites), reducing the external fixation index (EFI) (time in the frame). Integrated fixation has been shown to be safe and effective, despite the risk of deep infection from contaminated external fixation pins that are in close proximity to the internal implant [1, 4, 10, 13, 18, 20, 32].

The advantages of a fully implantable lengthening device are numerous [3, 11], but previous designs available in the USA were unreliable [23, 25, 34], making LON the preferred technique for femoral lengthening. The innovation of a magnetic internal lengthening nail (ILN) that utilizes an electromagnetic field (PRECICE[®], NuVasive, Inc., Irvine, CA, USA) to accurately lengthen the femur has delivered such outstanding clinical results [6, 7, 19, 31, 33] that it merits further study and, specifically, a comparison with LON.

In this study, we asked the following questions: (1) Is the magnetic ILN method more accurate than the LON method in achieving the desired limb length? (2) Does the ILN demonstrate more precise distraction rate control compared with LON? (3) Does the regenerate site heal faster and with more robust callus when using the ILN? (4) Does the ILN result in fewer complications including impediments to knee motion when compared with LON?

Methods

We conducted a retrospective cohort study with institutional review board approval and in accordance with the Strengthening the Reporting of Observational studies in Epidemiology (STROBE) guidelines. We reviewed the records and radiographs of a consecutive series of patients who underwent femoral LON between 2005 and 2009 and another consecutive series of those who underwent femoral lengthening using a magnetic remote-controlled ILN between 2012 and 2014. All procedures were performed by two fellowship-trained limb-lengthening and deformity surgeons at the same academic institution.

Two groups were identified using our patient registry. The indications for surgery were the same for both techniques and included shortening of the femur or lower extremity as a result of a posttraumatic incident or congenital, metabolic, or constitutional short stature (Table 1). Contraindications to surgery were active infection or irregular bone diameter or deformity that would prevent insertion of an intramedullary device.

The preoperative evaluation was similar for both groups. Patients underwent a standard history and physical examination. Rotational deformity was identified with a prone examination and gait analysis. Standing anteroposterior (AP) lower extremity radiographs were obtained on 51-in. cassettes and measured in the picture archiving and communication system (PACS) with a calibration ball [17] (Fig. 1). AP and lateral radiographs were obtained of the affected femur and were measured in the same manner.

The LON technique used was an antegrade nailing method similar to that described in previous studies [4, 18, 20, 25, 29]. The Schanz screws were 6-mm hydroxyapatite-coated tapered pins placed posteriorly to the nail in the lesser trochanter and in the distal femoral condyle (Fig. 2). The osteotomy was percutaneous using multiple drill holes followed by an osteotome. For children with open physes, a trochanteric entry point was used for the nail. The nail was locked proximally only. The frame used was a monolateral rail system (Biomet, Warsaw, IN, USA) (Fig. 3). The iliotibial band (ITB) was not released in these patients.

For the magnetic ILN cohort, a well-described surgical technique, including both antegrade and retrograde nailing, was used [6, 7, 9, 19, 27, 28, 31, 33]. Steinmann pins or Schanz screws were placed posteriorly to the path of the ILN to mark rotational alignment. The osteotomy site was predrilled percutaneously. The canal was over-reamed 2 mm greater than the diameter of the nail and the reamings were noticed to extrude out through the drill holes. The corticotomy was completed with an osteotome. The PRECICE magnetic ILN was used. A separate, longitudinal incision was made along the lateral thigh 5 cm proximal to the superior pole of the patella. The ITB was cut across its fibers and the fractional lengthening extended along the anterior vastus fascia. The release was also extended posteriorly to include the lateral intramuscular septum. The decision to release the ITB in the ILN cohort but not in the LON patients was a change in practice decision. As the LON patients were all operated on prior to the invention of the ILN, we were not performing routine ITB release in lengthening patients. At the time the practice changed to use ILN, it also changed to include routine ITB release, with the reasoning that it would reduce pain, knee stiffness, and lengthening-induced deformity.

Postoperatively, patients received 23 h of IV antibiotics. Unless contraindicated, enoxaparin 40 mg daily was started on postoperative day (POD) two and continued for 14 days, at which point, aspirin 325 mg daily was used for another two weeks for venous thromboembolic prophylaxis. Physical

Table 1 Indication for surgery

Etiology of femoral shortening	ILN (<i>n</i>)	LON (<i>n</i>)
Traumatic shortening (malunion)	12	11
Growth arrest	2	2
Metabolic	4	2
Congenital (unilateral)	11	3
Stature lengthening	5	1

ILN internal lengthening nail, LON lengthening over nail

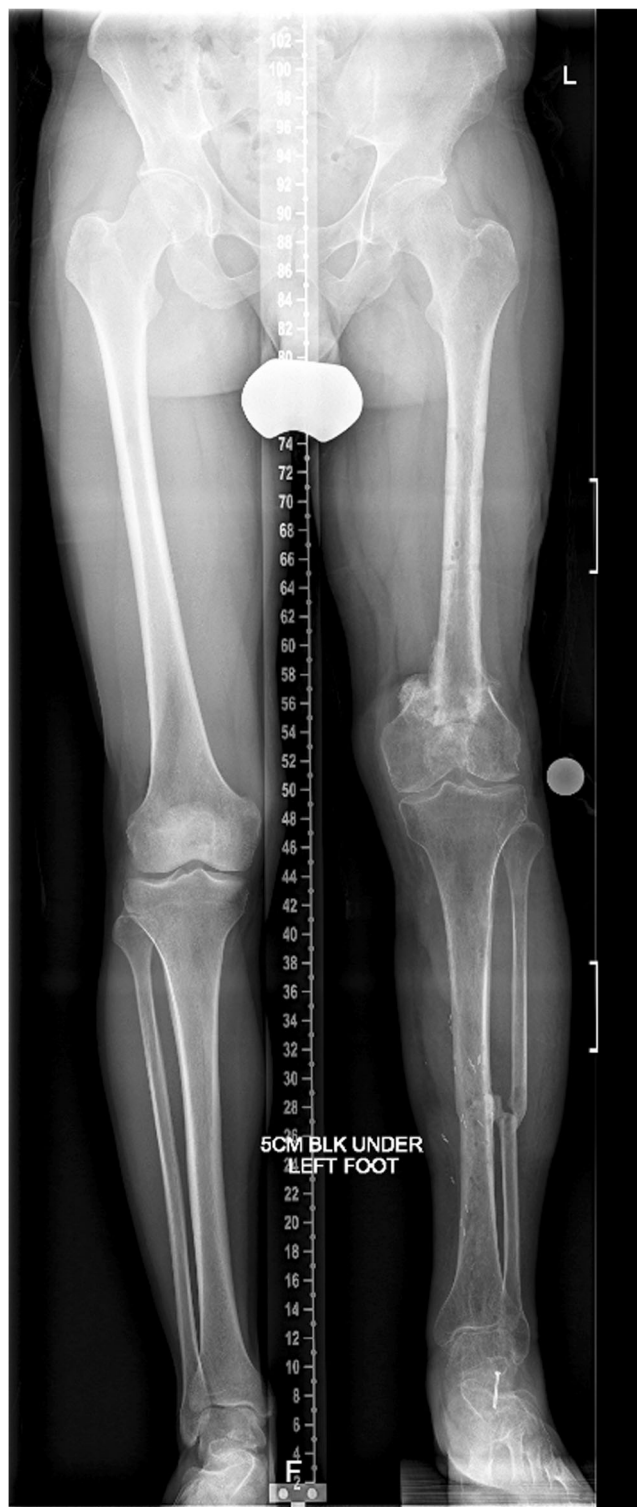

Fig. 1. A 51-in. cassette shows both lower extremities including hip and ankle joints with an appropriate block under the short limb allowing for the accurate measurement of limb length.

therapy was ordered and focused on ambulation with weight-bearing restrictions. For LON patients, weight bearing as tolerated was allowed. For ILN patients, the weight bearing was dependent on the nail diameter (30, 50, or 70 lbs for 8.5-, 10.7-, and 12.5-mm nail diameters, respectively).

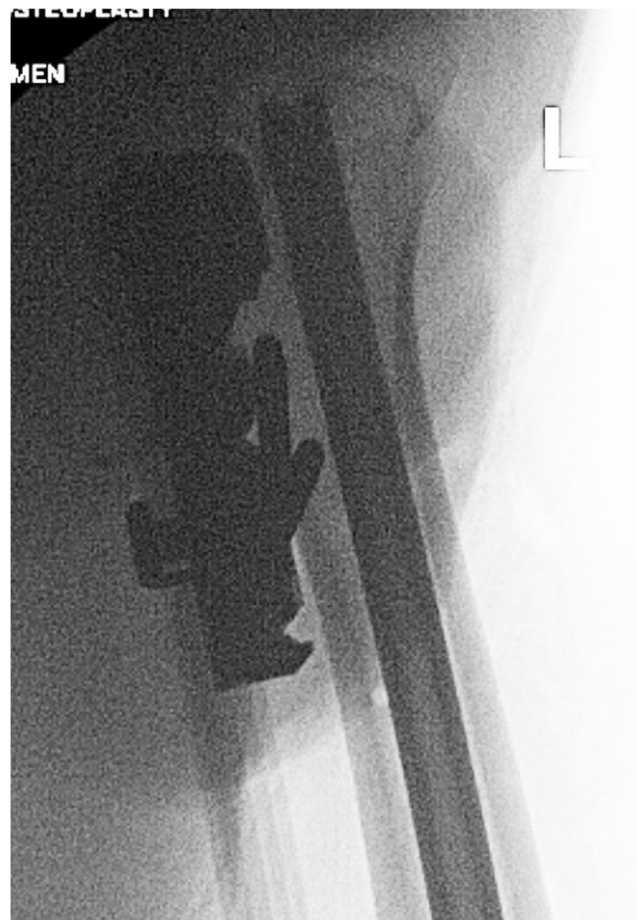

Fig. 2. An intraoperative lateral fluoroscopy shot of the proximal femur shows two Schanz pins placed posterior to the intramedullary nail.

Therapy included knee range of motion, emphasizing maintaining terminal extension. For LON patients, the frame was distracted at 1 mm/day starting on POD 5. For ILN patients, the lengthening started on POD 4 and proceeded at 1.32 mm/day (0.33 mm, 4 times/day) for 4 days, then slowed to 0.99 mm/day (0.33 mm, 3 times/day) thereafter.

Patients returned for an office visit every two weeks until the desired lengthening had been achieved. AP and lateral calibrated X-ray views of the femur were obtained at each visit. For the LON group, the distraction gap between bone ends (bony gap) was measured in millimeters, and the numbers of millimeters the patient distracted the frame were documented (Fig. 4). For the ILN group, the bony distraction gap was measured on both views and compared with the nail distraction gap (Fig. 5a, b). The quality of the regenerate was also assessed to confirm the best rate of distraction. Once the desired length was obtained, another standing 51-in. bilateral lower extremity film was taken to measure limb lengths and calculate residual limb-length discrepancy (LLD). In both groups, the IM nails were removed one year after surgery. In the ILN patients, the implanted magnet should be removed as per industry protocol. In the LON patients, concern about potential late infection due to some contamination of the internal implant by the half pins inspired universal IM nail removal.

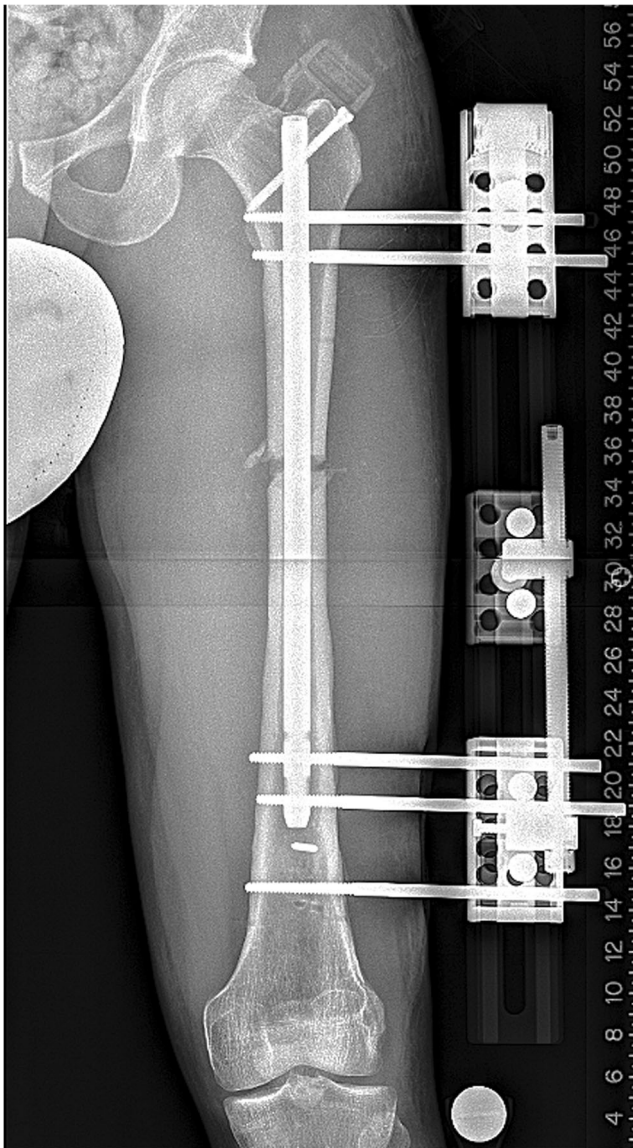

Fig. 3. This AP radiograph shows a typical LON setup with the monolateral frame mounted parallel to the intramedullary nail and as close to the skin as safely possible.

Chart review was used to record patient's gender, age at time of surgery, etiology of shortening, and lengthening technique utilized (Table 2). Charted measurements of knee flexion and extension were collected at preoperative, end of distraction, and final follow-up time points. (The surgeon obtained these measurements in the office with a goniometer.) Union was defined as the time at which there was bridging bone on three of four cortices on the AP and lateral femur radiographs (Fig. 6a, b). From the radiographic record, the pre- and postoperative LLD and final length distracted were measured. The quality of the regenerate was measured by a single author on the radiographs obtained at eight weeks after surgery using a simplified modification of the method described by Li et al. [24, 25]. The regenerate types were graded as homogenous (A), heterogeneous (B), or sparse (C) based on their radiographic appearance at the

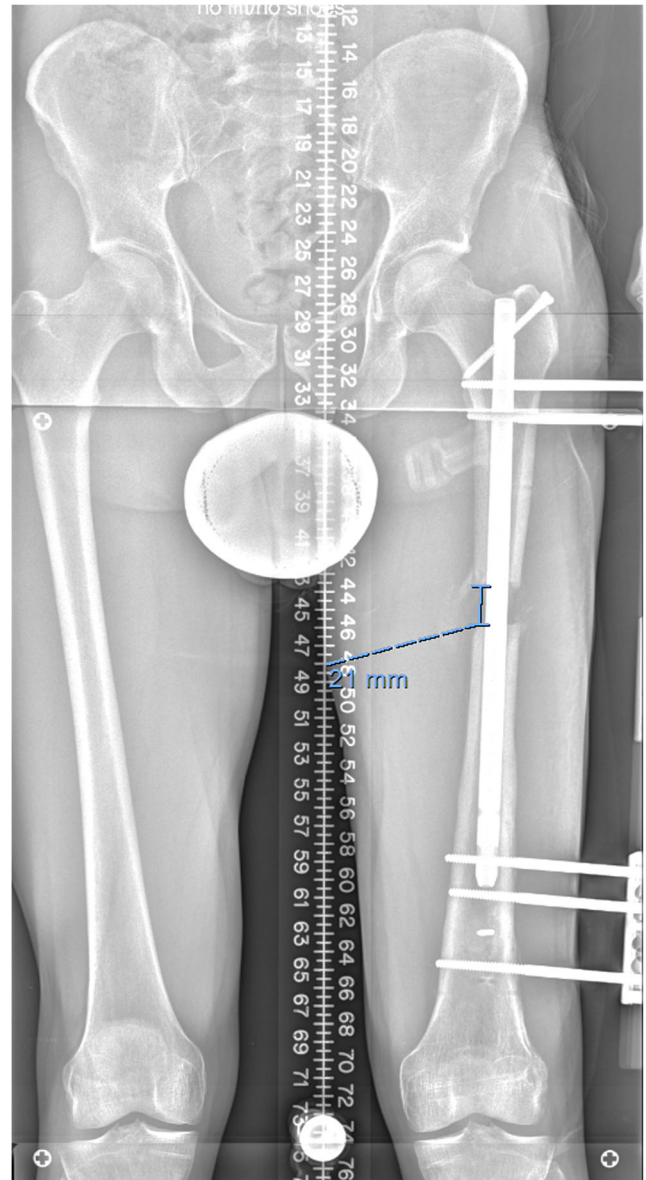


Fig. 4. The same patient is seen after 21 mm of distraction. The bony gap measured on the radiograph and then compared with the number of millimeters the patient recorded turning the frame distractor.

eight-week postdistraction mark. The bone healing index, a measure of the rate at which bone heals after lengthening surgery, was also calculated. It is a simple calculation of time from osteotomy to full consolidation in months divided by the number of centimeters of length achieved. This currency can be used to compare techniques with that producing the lowest bone healing index being heralded as the best method. Complications encountered during treatment were recorded, including premature or delayed union, hardware failure, unintended angular deformity, knee contracture, leg-length discrepancy, unplanned surgery, or any other difficulties.

Twenty-one patients with 22 femoral LON procedures and 35 patients with 40 femoral magnetic ILN lengthenings were identified. Two of the 21 patients in the LON group

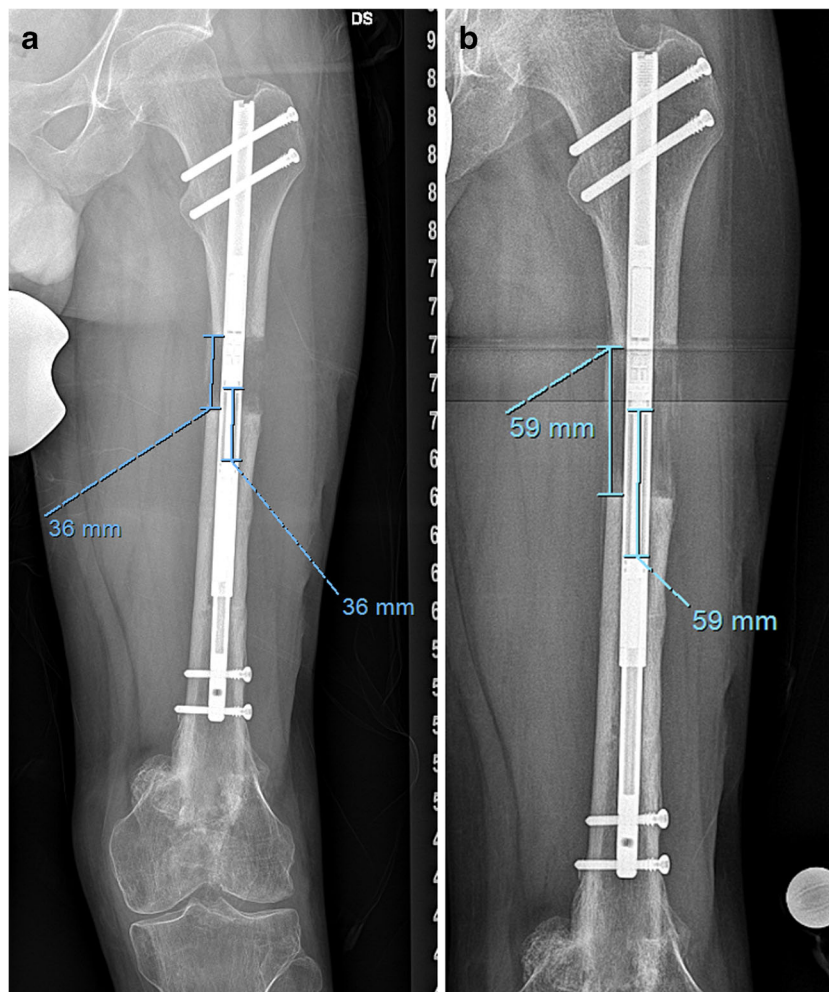


Fig. 5. **a** The patient from Fig. 1 is seen at an interim follow-up visit after ILN lengthening. The amount of nail distraction is compared with the amount of bony gap. **b** The same patient at a later visit has the same comparison performed.

Table 2 Patient demographics

Characteristic	ILN		LON		<i>p</i> value
	Mean or <i>N</i>	SD or %	Mean or <i>N</i>	SD or %	
Age (years)	29.7	13.6	32.4	14.2	0.487
Gender					
M	31	78%	18	90%	0.307
F	9	23%	2	10%	
Side treated					
R	20	50%	8	40%	0.464
L	20	50%	12	60%	
Alcohol?					
N	31	78%	12	60%	0.156
Y	9	23%	8	40%	
Smoking (tobacco/e-cigarette)?					
N	37	93%	20	100%	0.544
Y	3	8%	0	0%	
Preop limb-length discrepancy (mm)	26.8	23.5	43.3	20.4	0.007

ILN internal lengthening nail, LON lengthening over nail

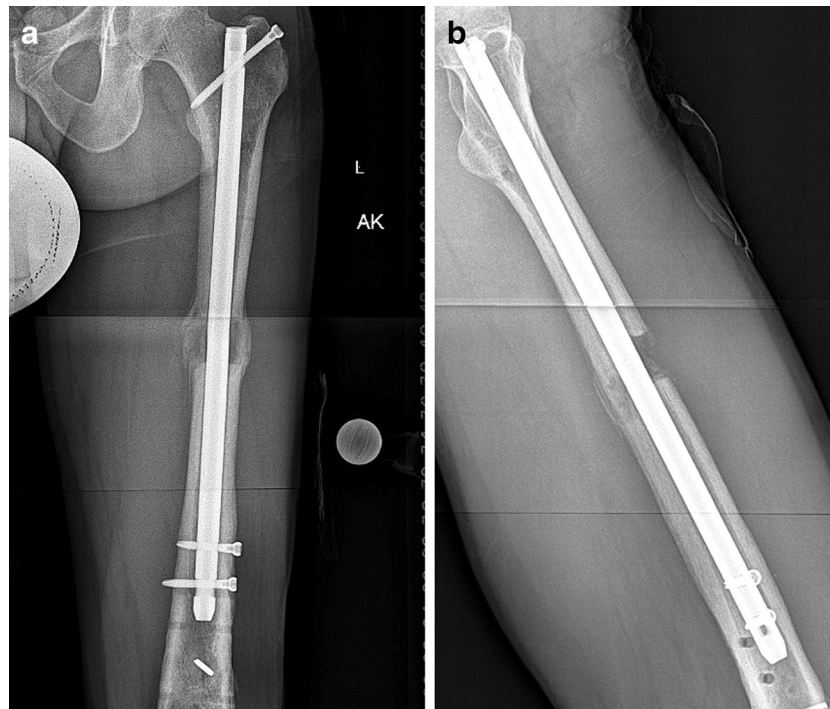


Fig. 6. **a** This AP radiograph of the same case as Figs. 2, 3, and 4, post-distal nail locking and frame removal, shows two cortices of bridging callus. **b** The lateral X-ray of the same patient shows bridging callus posteriorly but not anteriorly. With bony bridging on the posterior, medial, and lateral cortices, this patient is considered united.

were lost to follow-up at three and four months post-frame removal, leaving 19 patients (20 femurs) in the group. One of the 35 patients in the ILN group was lost to follow-up after the first postoperative visit, leaving 34 patients (39 femurs). The minimum follow-up was 13 months (average, 27 months; range, 13–38 months) for the LON group and 21 months (average, 31 months; range, 21–43 months) for the ILN group.

Statistical Analysis, Study Size

Patient and surgical characteristics between the LON and magnetic ILN groups were evaluated using independent

samples *t* tests for continuous variables and χ -square/Fisher's exact tests for discrete factors. Continuous variables are reported as mean and standard deviation (SD), while discrete variables are reported as frequencies and percentages. To control for the differences in the distraction osteogenesis in patients, an additional stratified analysis was performed for patients who had a distraction rate of 1 mm or greater per day and those who had a distraction rate of less than 1 mm per day. Longitudinal analysis used generalized linear models to analyze range of motion outcomes of knee flexion and extension. Full factorial models were used to analyze the effect of time and study group. This modeling technique was used to maximize all observations from all patients, regardless of

Table 3 Clinical characteristics

Characteristic	ILN		LON		<i>p</i> value
	Mean or <i>N</i>	SD or %	Mean or <i>N</i>	SD or %	
Length distracted (mm)	38.0	16.8	40.5	22.9	0.666
Accuracy: mean residual limb-length discrepancy (mm)	0.3	1.6	3.6	7.0	0.007
Precision of distraction (mm)	1.0	0.0	0.8	0.2	< 0.001
Modified Li score					
A (homogenous)	35	88%	14	70%	0.082
B (heterogeneous)	5	12%	4	20%	0.565
C (sparse)	0	0%	2	10%	0.188
Bone healing index (months/cm)	1.0	0.5	1.4	0.8	0.101
Time to union (months)	3.3	1.0	4.5	1.7	0.001
Nail diameter (mm)	10.7	1.1	10.0	1.2	0.041

ILN internal lengthening nail, LON lengthening over nail

Table 4 Complications

	ILN	LON
Delayed union	1	
Limb-length discrepancy	1	1
Varus deformity of regenerate	2	1
ILN fracture	1	
Premature consolidation	2	2
Unplanned surgeries	5	4
Skin dehiscence		1
Excessive pain		3
Knee contracture		1

Patients with more than one complication were counted multiple times to illustrate the types of complications. Therefore, these numbers are not additive. Total number of complications in the ILN group was 7/39 limbs and in the LON group was 9/20 limbs
ILN internal lengthening nail, *LON* lengthening over nail

inconsistent data collection at follow-up. Parameter estimates were measured using maximum likelihood estimates. Statistical significance was defined as a *p* value that achieved 0.05 or below. All statistical analyses were performed using SPSS version 22.0 (IBM Corp., Armonk, NY, USA).

Results

In all cases, the goal was to lengthen the femur to the desired amount as determined preoperatively. The average preoperative LLD was 26.8 mm in the magnetic ILN group and 43.3 mm in the LON group (*p* = 0.007) (Table 2). (These numbers *do not* include stature-lengthening patients.) The femur was distracted 38.0 mm in the ILN group and 40.5 mm in the LON group (*p* = 0.666). (These statistics *do* include stature-lengthening patients.) The postoperative LLD (difference between desired length and final length) was 0.3 mm in the ILN group, and 3.6 mm in the LON cohort (*p* = 0.007) (Table 3).

Table 5 Knee range of motion

Range of motion characteristic	ILN		LON		<i>p</i> value (between)
	Mean	SD	Mean	SD	
Knee extension					
Preoperative	0.4	2.8	-0.5	3.6	0.385
Distraction	1.8	5.4	2.7	4.4	0.481
Postoperative	0.5	1.6	0.9	5.7	0.739
<i>p</i> value (within)	0.239		0.070		
Knee flexion					
Preoperative	125.9	9.5	122.2	8.9	0.426
Distraction	103.3	25.2	88.8	20.0	0.006
Postoperative	122.6	14.9	119.2	11.5	0.464
<i>p</i> value (within)	0.000		0.000		
Knee arc of motion					
Preoperative	125.5	9.5	116.3	29.9	0.145
Distraction	101.5	26.9	80.0	30.7	0.002
Postoperative	122.0	16.0	111.9	30.8	0.112
<i>p</i> value (within)	0.000		0.000		

ILN internal lengthening nail, *LON* lengthening over nail

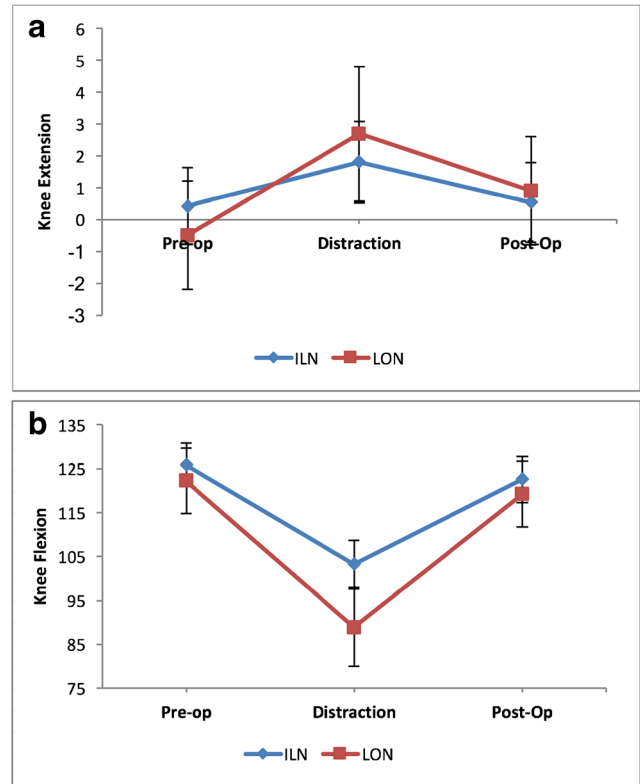


Fig. 7. **a** This graphic representation of knee extension before, during, and after treatment shows more consistency in the magnetic ILN group. **b** This graphic representation of knee flexion before, during, and after treatment shows less variability in knee motion in the magnetic ILN group throughout treatment.

The precision of distraction rate control was calculated. For the LON group, the actual length distracted as measured between the bone ends (bony gap) was divided by the amount distracted on the external fixator (in millimeters). The calculated distraction ratio was 0.8 (SD, 0.2) in the LON group. For the ILN group, the actual length distracted as measured between the bone ends (bony gap) was divided by the amount the nail distracted. For the magnetic ILN group, the distraction ratio was 1 (SD, 0.2; *p* < 0.001). An additional stratified analysis was performed for patients who had a distraction rate of greater than and less than 1 mm/day which verified no skewness in distraction ratio within each group.

Our modified Li scores [24, 25] were homogenous (A), heterogeneous (B), or sparse (C). The scores were A in 88% and B in 12% of the magnetic ILN patients. In the LON group, the modified Li score was A in 70%, B in 20%, and C in 10% of patients. Although the ILN patients scored higher, the difference between these scores was not statistically significant (*p* = 0.082). The bone healing index was 1 in the magnetic ILN group versus 1.4 in the LON cohort (*p* = 0.101). Time to union was 3.3 months for the ILN cohort and 4.5 months in the LON group (*p* = 0.001). In all ILN cases, a minimum of 51 mm of the thick portion of the nail remained in the opposite fragment (mean, 96.3 mm; range, 51–160 mm), which is felt to be important for controlling the bone ends and preventing new deformities.

Table 6 Review of studies using the PRECICE nail

Study	Type of study	Number of limbs	Accuracy of lengthening	Mean amount lengthened	Complications (number of events)
Paley et al. [30]	Retrospective	65 total 54 femoral 2 fibula 8 tibial 1 humerus	88.2% ^a	44.1 mm	26 total 3 nail breakages 1 premature consolidation 2 operator errors 4 dense regenerate 2 prominent hardwares 1 periprosthetic fracture 2 deep infection 3 failed regenerate 1 hematoma evacuation 3 soft tissue contractures 1 superficial infection 1 deep vein thrombosis 2 joint subluxations
Shabtai et al. [35]	Prospective	21 total 16 femoral 5 tibial	100% ^a	44 mm	7 total 4 delayed bone healing 1 hip contracture 1 hip subluxation 1 knee subluxation
Kirane et al. [19]	Retrospective	25 total 17 femoral 8 tibial	96% ^b	35 mm	7 total 1 implant failure 1 premature consolidation 2 delayed bone healing 2 delayed equinus contractures 1 toe clawing
Schiedel et al. [34]	Prospective	26 total 20 femoral 6 tibial	97% ^a	37 mm	4 total 2 nail breakages 1 nail failed to function 1 premature consolidation

^a Accuracy measured after total lengthening; accuracy = lengthening achieved/desired lengthening

^b Measured accuracy of distraction at each postoperative visit; accuracy = 100—absolute % error of distraction

Complications occurred in 45% of patients in the LON group and 18% of patients in the ILN cohort ($p = 0.027$) (Table 4). Preoperative knee flexion was 122° in LON patients and 126° in ILN patients ($p = 0.426$) after removing two outliers in the LON cohort with knee extension contractures (one with a knee arthrodesis). Final postoperative knee flexion was 120° in LON patients (without outliers) and 123° in ILN patients ($p = 0.464$). When interim knee flexion at the end of distraction was analyzed, flexion was significantly greater for ILN patients (103°) than that for LON patients (89° without the same outliers) ($p = 0.006$) (Table 5; Fig. 7a, b).

Discussion

Since implementing the ILN, we had observed that the magnetic ILN was quite accurate, exhibited excellent distraction rate control, produced a regenerate site with rapid healing and robust callus, and resulted in few complications. In this study, we sought to compare the magnetic ILN technique with a well-known and trusted method for distraction osteogenesis: the LON technique.

This study had a number of limitations. The study was performed in a retrospective, comparative manner with the two cohorts treated sequentially. There were more stature-lengthening patients and patients with congenital femoral shortening in the ILN cohort, resulting in suboptimal

matching. Technical experience gained with the LON femoral-lengthening technique may have carried forward to greater facilitate the ILN method. Time to union was defined when three of four cortices were noted to be bridged on X-ray, which depends on the time of the office visit. This limitation affects both cohorts equally, though, and should not bias one group more than the other. Time to union is independent of lengthening distance, making bone healing index (time to union/length of regenerate bone) a more relevant parameter. Post-hoc power analysis determined that the sample size available for the study was adequately powered to find a statistically significant difference in time to union between the two study groups and a trend toward a difference in bone healing index. The quality of regenerate assessment and scoring was performed by only one observer. It would have been better to use two observers with multiple time points to calculate intra- and interobserver reliability. The ILN cohort had ITB releases while the LON cohort did not, making comparison of knee motion less reliable.

Our study showed the magnetic ILN to be highly accurate, allowing the desired length to be achieved with reliability. This accuracy corroborates the results reported in several other studies (Table 6). Lengthening with ILN was more accurate than lengthening using the LON technique.

The importance of lengthening with the proper rate and rhythm is well established. The unpredictable distraction rates of the intramedullary skeletal kinetic distractor were

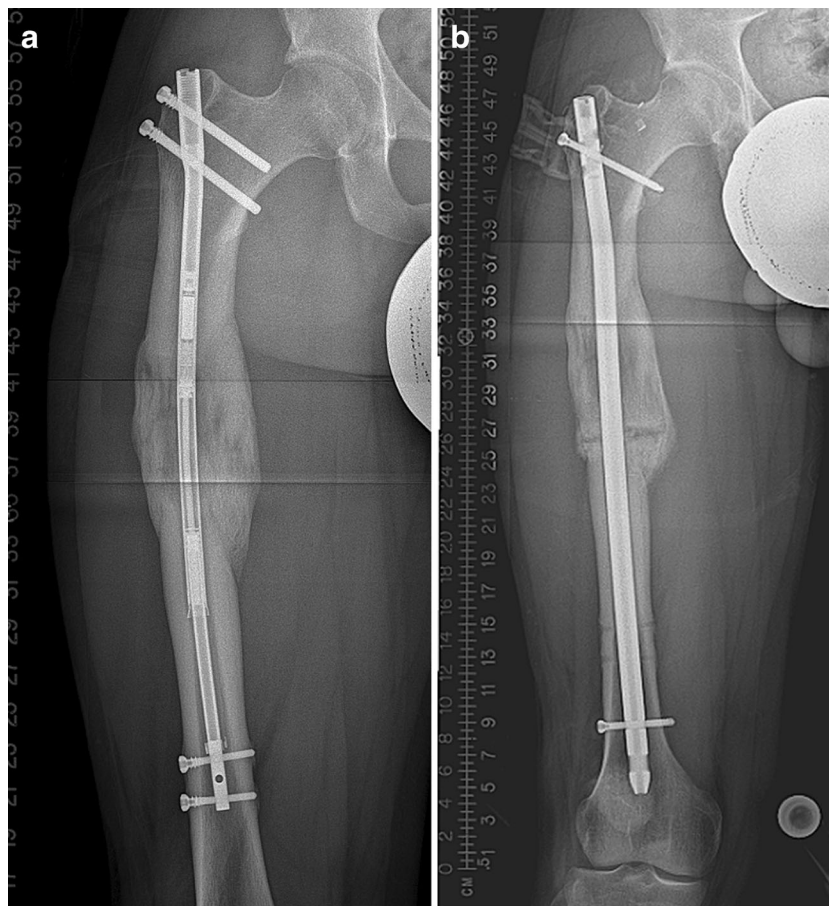


Fig. 8. **a** This patient had a trochanteric entry 8.5-mm ILN that bent into varus. **b** This was remedied with a novel osteotomy and exchange nailing.

among the reasons the authors reverted to LON and may have contributed to problems with regenerate quality in some of those patients. Femoral lengthening with the magnetic ILN more precisely controlled the distraction rate than lengthening using the LON method. This is a distinct advantage of the ILN and is likely a result of elimination of cantilever inefficiencies inherent in the monolateral frames.

The difference in modified Li scores was not significant between cohorts. The technique of the osteotomy, the intramedullary canal reaming, and the presence of an IM rod were all constant across both methods.

The percentage of patients who experienced a complication did differ significantly between cohorts, and the types of complications encountered varied. Both groups had premature consolidations. The LON group had one case of skin breakdown around a pin site, two cases of premature consolidation (one with a varus deformity), and one case of knee flexion contracture. The ILN group had no wound-related complications, one case of delayed union, two cases of varus deformity, one case of over-lengthening, and one case of nail breakage. It is important to be vigilant for varus deformity, which occurs in both femoral-lengthening techniques. Overreaming may allow either bone fragment to fall into varus. Trochanteric entry may facilitate varus nail insertion. The 8.5-mm-diameter ILN may bend slightly through the

unsupported region to cause this deformity, as was the case with one of the above-reported complications (Fig. 8a, b). The case of over-lengthening was treated by reversing the motor for four days with no ill effect on healing or final limb length. The broken nail was likely a problem of the first generation of this nail, which had a seam between two portions of the upper part of the nail. This has been changed with the current generation of the nail, and we have not found any further incidents of this failure mode, albeit in the context of modest lengthenings. The finding that the ILN group had greater knee range of motion at the end of distraction was statistically significant; however, ITB release was performed routinely at the index surgery. This finding may be a marker for overall improved comfort during treatment with this method when compared with LON as observed by Landge et al. [22]. The IT band releases were performed on the ILN patients but not on the LON patients are a confounding variable. Furthermore, the total bone lengthening and therefore soft tissue tension was greater in the LON cohort, making knee motion at completion of distraction an unfair comparison. Although not technically a complication, the additional operation to lock the nail and remove the fixator at the end of the lengthening phase in patients treated with LON adds additional expense and general risk. The elimination of this operative intervention is a

benefit of the ILN technique. Both groups had all nails removed eventually. While this additional surgery was a necessary part of both techniques, it had no effect on the imbalance in the total number of surgeries for each technique.

In conclusion, femoral lengthening with the magnetic ILN offers the limb-lengthening surgeon great accuracy in achieving lengthening goals and was more accurate than the LON technique. The ILN has more precise distraction rate control and fewer complications. The regenerate was not more robust and did not consolidate faster with ILN based on our sample size. Both techniques afford reliable healing and do not significantly affect knee motion at final follow-up. The ILN method maintains an acceptable risk of complications and obviates the need for the additional surgery requisite with LON. In our practice, these benefits have allowed us to replace LON with the magnetic ILN for nearly all cases requiring femoral lengthening.

Acknowledgements We thank our research coordinator Eugene Borst for his help in managing the clinical data collection.

Compliance with Ethical Standards

Conflict of Interest: Anton M. Kurtz, MD, Jonathan R. Barclay, BS, and Joseph Nguyen, MPH, declare that they have no conflicts of interest. Austin T. Fragomen, MD, reports receiving personal fees from NuVasive, Smith and Nephew, and Synthes, outside the submitted work. S. Robert Rozbruch, MD, reports receiving personal fees from NuVasive, Smith and Nephew, and Stryker, outside the submitted work.

Human/Animal Rights: All procedures followed were in accordance with the ethical standards of the responsible committee on human experimentation (institutional and national) and with the Helsinki Declaration of 1975, as revised in 2013.

Informed Consent: Informed consent was waived from all patients for being included in this study.

Required Author Forms Disclosure forms provided by the authors are available with the online version of this article.

References

- Bernstein M, Fragomen AT, Sabharwal S, Barclay J, Rozbruch SR. Does integrated fixation provide benefit in the reconstruction of posttraumatic tibial bone defects? *Clin Orthop Relat Res.* 2015;473(10):3143–3153.
- Bhave A, Shabtai L, Woelber E, Aplyan A, Paley D, Herzenberg JE. Muscle strength and knee range of motion after femoral lengthening. *Acta Orthop.* 2016;28:1–6.
- Black SR, Kwon MS, Cherkashin AM, Samchukov ML, Birch JG, Jo CH. Lengthening in congenital femoral deficiency: a comparison of circular external fixation and a motorized intramedullary nail. *J Bone Joint Surg Am.* 2015;97(17):1432–1440.
- Fernandes HP, Barronovo DG, Rodrigues FL, Hono M. Femur lengthening with monoplanar external fixator associated with locked intramedullary nail *Rev Bras Ortop.* 2016;52(1):82–86.
- Fragomen AT, Rozbruch SR. The mechanics of external fixation. *HSS J.* 2007;3(1):13–29.
- Fragomen AT, Rozbruch SR. Lengthening of the femur with a remote controlled magnetic intramedullary nail: retrograde technique. *JBJS Essent Surg Tech.* 2016;6(2): e20.
- Fragomen AT, Rozbruch SR. Lengthening and deformity correction about the knee using a magnetic internal lengthening nail. *SICOT J.* 2017;3(25):1–10.
- Fragomen AT, Miller AO, Brause BD, Goldman V, Rozbruch SR. Prophylactic post operative antibiotics may not reduce pin site infections after external fixation. *HSS J.* 2017;13(2):165–170.
- Hammouda AI, Jauregui JJ, Gesheff MG, Standard SC, Conway JD, Herzenberg JE. Treatment of post traumatic femoral discrepancy with PRECICE magnetic powered intramedullary lengthening nails *J Orthop Trauma.* 2017;31(7): 369–374.
- Harbacheuski R, Fragomen AT, Rozbruch SR. Does lengthening and plating shorten duration of external fixation? *Clin Orthop Relat Res.* 2012;470(6):1771–1781.
- Horn J, Grimsrud Ø, Dagsgard AH, Huhnstock S, Steen H. Femoral lengthening with a motorized intramedullary nail. *Acta Orthop.* 2015;86:248–256.
- Hosalkar HS, Jones S, Chowdhury M, Hartley J, Hill RA. Quadricepsplasty for knee stiffness after femoral lengthening in congenital short femur. *J Bone Joint Surg Br.* 2003;85(2):261–264.
- Iobst CA, Dahl MT. Limb lengthening with submuscular plate stabilization: a case series and description of the technique. *J Pediatr Orthop.* 2007;27(5):504–509.
- Kawoosa AA, Wani IH, Dar FA, Sultan A, Qazi M, Halwai MA. Deformity correction about knee with Ilizarov technique: accuracy of correction and effectiveness of gradual distraction after conventional straight cut osteotomy. *Ortop Traumatol Rehabil.* 2015;17(6):587–592.
- Kazmers NH, Fragomen AT, Rozbruch SR. Prevention of pin site infection in external fixation: a review of the literature. *Strat Trauma Limb Recon* 2016;11:75–85.
- Khakharia S, Fragomen AT, Rozbruch SR. Limited quadsplasty for contracture during femoral lengthening. *Clin Orthop Rel Res.* 2009;467(11):2911–2917.
- Khakharia S, Bigman D, Fragomen AT, Pavlov H, Rozbruch SR. Comparison of PACS and hard-copy 51-inch radiographs for measuring leg length and deformity. *Clin Orthop Relat Res.* 2011;469:244–250.
- Kim HJ, Fragomen AT, Reinhardt K, Hutson JJ, Rozbruch SR. Lengthening of the femur over an existing IM nail. *J Orthop Trauma.* 2011;25:681–684.
- Kirane YM, Fragomen AT, Rozbruch SR. Precision of the PRECICE internal bone lengthening nail. *Clin Orthop Relat Res.* 2014;472:3869–3878.
- Kocaoglu M, Eralp L, Bilen FE, Balci HI. Fixator-assisted acute femoral deformity correction and consecutive lengthening over an intramedullary nail. *J Bone Joint Surg Am.* 2009;91(1):152–159.
- Koczewski P, Shadi M. Repair of the knee extension apparatus in the treatment of knee extension contracture after femoral lengthening. *Chir Narzadow Ruchu Ortop Pol.* 2005;70(2):91–96.
- Landge V, Shabtai L, Gesheff M, Specht SC, Herzenberg JE. Patient Satisfaction After Limb Lengthening with Internal and External Devices. *J Surg Orthop Adv.* 2015;24(3):174–179.
- Lee DH, Ryu KJ, Song HR, Han SH. Complications of the Intramedullary Skeletal Kinetic Distractor (ISKD) in distraction osteogenesis *Clin Orthop Relat Res.* 2014;472(12):3852–3859.
- Li R, Saleh M, Yang L, Coulton L. Radiographic classification of osteogenesis during bone distraction. *J Orthop Res.* 2006;24:339–347.
- Mahboubian S, Seah M, Fragomen AT, Rozbruch SR. Femoral lengthening with lengthening over a nail has fewer complications than intramedullary skeletal kinetic distraction. *Clin Orthop Relat Res.* 2012;470:1221–1231.
- McCarthy JJ, Ranade A, Davidson RS. Pediatric deformity correction using a multiaxial correction fixator. *Clin Orthop Relat Res.* 2008;466(12):3011–3017.
- Muthusamy S, Rozbruch SR, Fragomen AT. The use of blocking screws with internal lengthening nail and reverse rule of thumbs for

- blocking screws in limb lengthening and deformity correction surgery. *Strategies Trauma Limb Reconstruct*. 2016;11(3):199–205
28. Paley D. PRECICE intramedullary limb lengthening system *Expert Rev Med Devices*. 2015;12(3):231–249.
 29. Paley D, Herzenberg JE, Paremain G, Bhave A. Femoral lengthening over an intramedullary nail. A matched-case comparison with Ilizarov femoral lengthening *J Bone Joint Surg Am*. 1997;79(10):1464–1480.
 30. Paley D, Harris M, Debiparshad K, Prince D. Limb lengthening by implantable limb lengthening devices. *Tech Orthop*. 2014;29(2):72–85
 31. Rozbruch SR, Fragomen AT. Lengthening of the femur with a remote-controlled magnetic intramedullary nail: antegrade technique. *JBJS Essential Surgical Techniques*. 2016;6:e2–e2.
 32. Rozbruch SR, Kleinman D, Fragomen A, Ilizarov S. Limb lengthening and then insertion of an intramedullary nail. A case matched comparison. *Clin Orthop*. 2008;466(12):2923–2932.
 33. Rozbruch SR, Birch JG, Dahl MT, Herzenberg JE. Motorized intramedullary nail for management of limb-length discrepancy and deformity. *J Am Acad Orthop Surg*. 2014;22:403–409.
 34. Schiedel FM, Vogt B, Tretow HL, Schuhknecht B, Gosheger G, Horter MJ, Rödl R. How precise is the PRECICE compared to the ISKD in intramedullary limb lengthening? Reliability and safety in 26 procedures. *Acta Orthop*. 2014;85:293–298.
 35. Shabtai L, Specht SC, Standard SC, Herzenberg JE. Internal lengthening device for congenital femoral deficiency and fibular hemimelia. *Clin Orthop Relat Res*. 2014;472(12):3860–3868.