

## A Magnetically Controlled Lengthening Nail: A Prospective Study of 31 Individuals (The PRECICE™ Intramedullary Nail Study)

### Abstract

**Purpose:** We studied 31 individuals whose femur or tibia was elongated with the PRECICE™ intramedullary lengthening nail in a protocol-controlled, multicentric, prospective series. Only skeletally mature individuals were included in the study. **Materials and Methods:** The protocol entailed 2-year follow-up after consolidation of the regenerate new bone in the distraction gap. Since the external remote controller (that powers the nail's internal rotating magnet) must be within a predetermined distance from the implant, body weight limitations applied to the individuals. Similarly, a history of active or prior bone infection in the involved limb segment, an offset medullary canal that could not be successfully reamed for the implant, an angular deformity that precluded insertion of a straight device, and any potential limitation on regenerate new bone formation (such as metabolic bone disease or vascular compromise) were causes for exclusion. The mean age  $\pm$  standard deviation was  $24.3 \pm 15.0$ , and the median age was 18 years. There were 20 males and 11 females in the series, with 21 Caucasians, 5 Hispanics, and 5 African-American individuals. The mean body mass index was  $24.2 \pm 4.7$ . Twentythree (74.2%) cases involved the femur and 8 (25.8%) involved the tibia. **Results:** One participant died of medical causes during the study period, and one participant was lost to follow-up, but 29 of 29 participants followed at least to consolidation achieved union (100%) although one of these participants was treated with a supplementary cancellous bone graft and another participant was converted to trauma nail before consolidation, to permit full weight-bearing as a stimulus to regenerate consolidation. On an average, participants achieved  $96.3\% \pm 23.2\%$  of the preoperative target lengthening (3.5 cm; range 1.8–6.0 cm) over an average of  $48.5 \pm 15.6$  days. The average time to full weightbearing (permitted when the regenerate was consolidated on three sides) was  $141.1 \pm 80.7$  days. The knee joint, at consolidation, lost an average of  $6.5^\circ$  of flexion and  $0.3^\circ$  of extension. The ankle lost an average of  $1.4^\circ$  of dorsiflexion and  $5.4^\circ$  of plantar flexion. The hip joint lost, on average,  $2^\circ$  of flexion, and gained  $1.6^\circ$  of extension. There was one deep infection involving the implant, successfully treated with intravenous antibiotics and superficial debridement. Nearly 25.8% of the participants had pain issues during lengthening, often over prominent hardware. In one participant, the nail failed to elongate during lengthening at home and had to be exchanged. One interlock screw broke. The internal components separated during implant extraction in the one subject had his nail exchanged by a trauma nail. Only 17 participants exited the protocol by presenting to clinic for evaluation 2 years after consolidation. None experienced significant deterioration of outcome. **Conclusion:** The PRECICE™ IM nail is a well-tolerated, reliable, fully implantable limb lengthening device that will accurately elongate the femur or tibia in a variety of causes of limb length inequality, with a low implant failure rate, and few complications.

**Keywords:** Leg lengthening, lengthening intramedullary nail, limb lengthening, magnetical

### Introduction

The PRECICE™ lengthening nail is a fully implantable, telescoping interlocking intramedullary (IM) nail that distracts along a spindle connected through a gearbox to an incorporated cylindrical magnet. This internal magnet rotates on its axis in response to an external magnetic field generated by two rotating

solid-state magnets placed on the external surface of the limb, the external remote controller (ERC), within a predetermined distance from the implant.

Anatomical considerations have resulted in several implant configurations, including PRECICE™ femoral nails designed for piriformis or trochanteric entry from the antegrade direction, as well as a retrograde femoral nail for insertion into the femur

This is an open access journal, and articles are distributed under the terms of the Creative Commons Attribution-NonCommercial-ShareAlike 4.0 License, which allows others to remix, tweak, and build upon the work non-commercially, as long as appropriate credit is given and the new creations are licensed under the identical terms.

For reprints contact: [reprints@medknow.com](mailto:reprints@medknow.com)

**How to cite this article:** Green SA, Fragomen AT, Herzenberg JE, Iobst C, McCarthy JJ, Nelson SC, et al. A magnetically controlled lengthening nail: A prospective study of 31 individuals (The PRECICE™ intramedullary nail study). *J Limb Lengthen Reconstr* 2018;4:67-75.

Stuart A Green,  
Austin T  
Fragomen<sup>1</sup>,  
John E  
Herzenberg<sup>2</sup>,  
Christopher Iobst<sup>3</sup>,  
James J McCarthy<sup>4</sup>,  
Scott C Nelson<sup>5</sup>,  
Dror Paley<sup>6</sup>,  
S Robert  
Rozbruch<sup>1</sup>,  
Shawn C Standard<sup>2</sup>

*Department of Orthopaedic Surgery, University of California, Irvine, Orange,*  
*<sup>3</sup>Department of Orthopedic Surgery, Loma Linda University, Loma Linda, CA, <sup>2</sup>International Center for Limb Lengthening, Rubin Institute for Advanced Orthopedics, Baltimore, MD,*  
*<sup>3</sup>Department of Orthopedic Surgery, Nationwide Children's Hospital, Columbus, <sup>4</sup>Cincinnati Children's Hospital Medical Center, Cincinnati, OH,*  
*<sup>6</sup>Paley Orthopedic and Spine Institute, West Palm Beach, FL,*  
*<sup>1</sup>Department of Limb Lengthening and Reconstruction, Hospital for Special Surgery, NY, USA*

**Address for correspondence:**  
Dr. Stuart A Green,  
University of California,  
Irvine, Orange, CA, USA.  
E-mail: [sgreen@uci.edu](mailto:sgreen@uci.edu)

### Access this article online

**Website:**  
[www.jlimblengthrecon.org](http://www.jlimblengthrecon.org)

**DOI:** 10.4103/jllr.jllr\_20\_18

### Quick Response Code:



through the intercondylar notch. The PRECICE™ nail for tibial use has a typical bend in the proximal part of the nail. Appropriate jigs for each configuration allow easy insertion of the proximal interlocking screws. The distal interlocking screws are inserted through the freehand method. At the time of the study, the nail was manufactured in three different diameters, namely 8.5 mm, 10.7 mm, and 12.5 mm.

The implant was originally approved by regulatory agencies around the world for lengthening of the femur and tibia (after transverse osteotomy) although additional indications have been gradually added and approved for the device, including compression osteosynthesis of long-bone nonunions, bone transport for segmental defects, and humeral applications.

In 2014, shortly after the Food and Drug Administration clearance of the device in the United States, we commenced a multicenter, prospective, observational, protocol-controlled series called the PRECICE™ Intramedullary Nail Study, with a minimum 2-year follow-up after full consolidation of the lengthened bone, to better understand the risks and benefits associated with this novel technology.

## Materials and Methods

Altogether, six sites were selected for the series, each obtaining Institutional Review Board (IRB) approval in accordance with the facilities' own standards.

Inclusion criteria included a leg length discrepancy involving either the femur or tibia of between 1.5 and 6.5 cm. Only skeletal mature individuals were included in the series. Their body weight had to be  $\leq 114$  kg if a 10.7 mm or 12.5 mm diameter nail was employed and  $\leq 57$  kg if the 8.5 mm diameter nail was used.

Each participant in the series had to have a patent IM canal without an offset, and the tibia or femur had to have a sufficient cortical thickness to be completely contained in the implant after reaming.

Each participant had to have sufficient cognitive awareness to comply with the protocols, procedures, and schedules since the lengthening is done at home with the ERC.

IRB-approved informed consent was necessary to permit the use of personal health data in this study. When appropriate, personal data were deidentified utilizing participants' code numbers only.

Because of the nature of the implant, there were numerous exclusion criteria. A potential participant was excluded if they had an active infection or a previous history of a deep infection in the involved bone. Individuals with metal allergies or sensitivities to the components, principally titanium, of the implant were excluded.

Body mass was an important issue because an individual was excluded if the ERC could not be placed within 38 mm for the 8.5 mm PRECICE™ nail, 51 mm for the PRECICE™ 10.7 nail, or 76 mm for the PRECICE™ 12.5 nail. Because

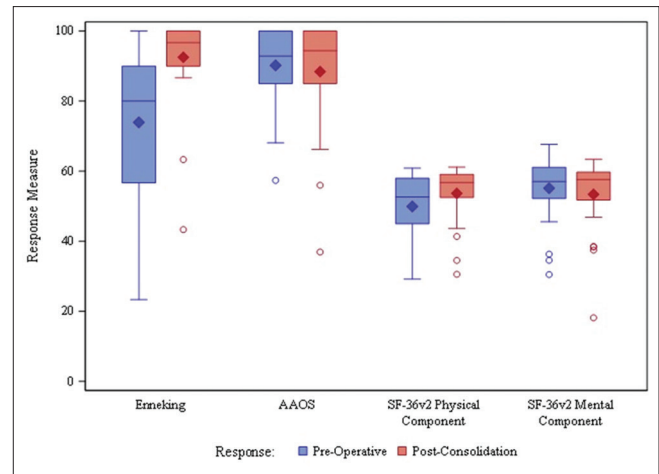


Figure 1: Patient questionnaire response outcomes

there is a magnet within the nail and two magnets in the ERC, individuals with pacemakers or implanted cardiac defibrillators or other electronic implants that could conceivably be sensitive to magnetic fields were excluded. Similarly, any individual who might require a magnetic resonance imaging while the device is *in situ* was excluded.

Participants with a nonunion of the involved bone were excluded as were those who had an impassable or obstructed IM canal. Similarly, if there was a significant angular deformity of the involved bone that prevented device placement, or the participant could not bear weight on the contralateral limb, exclusion was mandatory. We also excluded participants who had a significant preexisting reduced range of motion of a joint adjacent to the lengthening bone.

Furthermore, we excluded individuals in whom the transverse osteotomy for lengthening could not be done at an appropriate level or any individual who had a deformity that required correction at the time the implant was inserted.

Likewise, individuals with a systemic bone disease were eliminated from consideration, as were pregnant or nursing women, as well as individuals with inadequate vascularity or any evidence of vascular disease or peripheral neuropathy. We excluded individuals with malignancies or tumors in the involved bones, participants who were drug abusers, or those that had open wounds or ulcers anywhere in the body that could compromise treatment and lead to a possible implant infection.

For each participant, we recorded the date of birth, gender, height, weight, and calculated body mass index (BMI) (weight in kilograms divided by height in meters squared). We recorded the race as well as the cause of the discrepancy and the current use of an ambulatory support [Table 1].

We also measured, for the limb to be treated, the range of knee flexion and extension, ankle dorsiflexion and plantar flexion, as well as hip flexion and extension.

The investigators obtained a complete medical history and review of systems. They also conducted a complete physical examination noting any abnormalities in the head and neck, eyes and ears, nose and throat, chest, lungs, heart, abdomen, extremities and joints, as well as lymph nodes, skin, and any neurologic deficit.

Utilizing standardized radiologic technique (with appropriate identification for image magnification), we obtained the limb length discrepancy of the involved bone compared to the contralateral limb and recorded the target amount for lengthening. We recorded the canal diameter as well as the starting length of each bone to be lengthened. We also measured the skin circumference of the bone to be treated at the midline of the bone because, as mentioned earlier, the ERC must be within a certain distance of the internal magnet to make it turn on its axis.

Utilizing the full-length X-ray views (anteroposterior [AP] projection), we placed the subject on an appropriately sized lift under the short leg, and then measured, for both the treated and contralateral limb, the length from the top of the film to the top of the femoral head, the distance from the top of the femoral head to the lowest point on the femoral condyles, from the tibial plateau to the tibial plafond, and computed the leg length discrepancy by subtracting the length of the short side from the length of the long side and adding the height of the lift.

From the full-length films obtained in both the AP and lateral projections, we made numerous angular measurements and recorded them for both sides. These included the femoral neck shaft angle, the mechanical lateral proximal femoral angle, the anatomic medial proximal femoral angle, the mechanical lateral distal femoral angle, the anatomic lateral distal femoral angle, the joint line convergence angle of the knee, the mechanical medial proximal tibial angle, the mechanical lateral distal tibial angle, and from the lateral projection, the anatomic posterior distal femoral angle, the anatomic posterior proximal tibial angle, and the anatomic anterior distal tibial angle. We also measured the mechanical axis deviation at the knee from its proper location to its actual location.

We administered the Enneking Functional Status evaluation preoperatively, 6 months after consolidation, 12 months after consolidation, and 24 months after consolidation. This metric assesses pain, functional activity, emotional status, use of ambulatory supports, walking capacity, and gait pattern. Likewise, we used the short form (SF) 36 questionnaire during the same time intervals and also administered the American Academy of Orthopedic Surgeons (AAOS) Lower Limb Outcomes Questionnaire, at the same time interval (preoperatively, 6 months, 12 months, and 24 months postconsolidation).

Regarding the surgical technique, we recorded the bone lengthened and the side, as well as the insertion direction, whether antegrade or retrograde. We noted the starting

**Table 1: Subject characteristics**

Baseline characteristic (n=31)	Mean±SD, median/n (%)
Age	24.3±15.0, 18
Sex	
Male	20 (64.5)
Female	11 (35.5)
Race	
Caucasian	21 (67.7)
Black	5 (16.1)
Hispanic	5 (16.1)
BMI	24.2±4.7, 24.2
Treated limb	
Femur	23 (74.2)
Tibia	8 (25.8)
Limb discrepancy	
Traumatic	12 (38.7)
Congenital	10 (32.3)
Developmental	6 (19.4)
Current support	
Lift	18 (58.1)
None	11 (35.5)

Other limb discrepancy: Ollier's disease (1), unknown (2), Other support: Walker (1), cane (1). SD: Standard deviation, BMI: Body mass index

**Table 2: Summary of lengthening**

Parameter	Statistics (n=31)
Lengthening achieved (cm)	
n	30
Mean±SD	3.35±1.09
Median (minimum-maximum)	3.4 (1.3-5.6)
95% CI	2.94-3.76
Total distraction amount (cm)	
n	30
Mean±SD	3.40±0.90
Median (minimum-maximum)	3.4 (1.9-5.2)
95% CI	3.06-3.73
Percentage accuracy <sup>a</sup>	
n	29
Mean±SD	96.67±20.56
Median (minimum-maximum)	100.0 (60.9-140.0)
95% CI	88.85-104.49

<sup>a</sup>The percentage accuracy between lengthening achieved during treatment and the recorded amount of distraction of the implant. SD: Standard deviation, CI: Confidence interval

and ending time of each operation as well as the diameter of the first and last reamer used to prepare the medullary canal. We recorded the type of osteotomy, whether open or percutaneous, as well as the instruments used to perform that osteotomy (multiple drill holes, Gigli saw, osteotomy/chisel, or oscillating saw). We also recorded the direction of the osteotomy, whether transverse or oblique, and the contour of the osteotomy site, whether it was smooth, spiked, or comminuted. We noted the displacement of the distal fragment with respect to the proximal fragment

as well as any angulation in multiple planes. We also recorded any axial rotation if it occurred or was needed for correction [Figure 1].

We recorded whether there was hardware from a preexisting surgery and whether it was removed or not. We noted any other operations performed at the same time as the implantation of the lengthening nail. We kept track of the specific PRECICE™ nail used, as well as the proximal and distal blocking screws.

Any adverse events or complications during the surgery were recorded. We noted the estimated blood loss and measured the distance from the nail insertion site to the level of the osteotomy in millimeters, based on measurements taken on immediate postoperative X-ray studies.

Postoperative visits were generally conducted weekly while the bone was being lengthened, and then approximately monthly thereafter until consolidation, judged by full corticalization on three sides, as seen on two orthogonal X-ray views.

For each visit, we recorded the participant's ambulatory capacity and the use of any ambulatory aids in this regard. We noted whether full weight-bearing was permitted and tolerated. We measure the range of motion on the

treated limb including knee flexion and extension, ankle dorsiflexion and plantar flexion, and hip flexion and extension.

We made radiographic evaluations of the regenerate in the widening distraction gap, recording whether there were cortex deficiencies in the anterior, posterior, medial, or lateral projections and also noted the quality of the regenerate, if it was assessable.

We noted any adverse events or complications that occurred since the last follow-up visit, and if any existed, we recorded the event on a case report form (CRF) form. Likewise, we noted any change in the participant's medication requirements.

During the distraction phase (i.e. while the implant was lengthening), we recorded the skin circumference at the middle of the treated bone and noted both the targeted and actual distraction achieved since the last visit. We also measured the actual total distraction since implant insertion. Finally, we noted the target distraction rate in millimeters per day until the next scheduled visit.

The key question during the consolidation phase visits was whether or not consolidation had occurred based on radiographic verification of consolidation of the regenerate on three sides.

Once consolidation was achieved, the intervals between the visits were naturally lengthened. Typically, there was to have been a 6-month, 12-month, 18-month, and 24-month postconsolidation visit. We also recorded any unscheduled visits.

Once again, as with other visits, we recorded the type of ambulatory support, the nature of weight-bearing, and the range of motion of the hip, knee, and ankle in the sagittal plane. We recorded the maturation of the regenerate as evident on X-ray studies.

At the end of treatment, with a minimum of 2 years of follow-up, we once again took full-length films (with a shoe lift if necessary to level the pelvis) and made

**Table 3: Performance of implant**

Performance outcome	Mean±SD, median/n (%)	95% CI
Lengthening		
Percentage of preoperative target	96.3±23.2, 94.9	87.7-105.0
Percentage of total distraction	96.7±20.6, 100.0	88.9-104.5
Time to complete (days)	48.5±15.6, 50	42.7-54.3
Bone union*		
Achieved	29/29 (100.0)	88.1-100.0
Achieved without intervention	27/29 (93.1)	77.2-99.2
Time to complete (days)	142.0±70.5, 115	115.2-168.9
Time to full weight-bearing	141.1±80.7, 116	110.9-171.2

\*Bone union: lost to follow-up (1) and death (1) before consolidation not included in calculations. SD: Standard deviation, CI: Confidence interval

**Table 4: Range of motion**

Range of motion Parameter change from baseline	Mean±SD, median (n)		
	All individuals <sup>a</sup>	Completed individuals <sup>b</sup>	
	At consolidation	At consolidation	At 24 months
Knee			
Flexion	-6.5±16.5, -5 (27)	-4.1±14.8, -5 (11)	-10.9±30.9, -5 (11)
Extension	-0.3±4.8, 0 (26)	0.0±3.2, 0 (11)	0.7±3.3, 0 (11)
Ankle			
Dorsiflexion	-1.4±11.4, -2 (26)	-1.3±10, 0 (9)	2.6±8.9, 0 (9)
Plantar flexion	-5.4±19.1, 0 (26)	-2.0±17.0, 0 (10)	-3.0±17.0, 3 (10)
Hip			
Flexion	-2.0±29.7, 0 (24)	-4.1±19.3, 0 (9)	0.6±15.5, 0 (9)
Extension	1.6±30.6, 0 (25)	5.3±20.9, 0 (9)	3.7±7.4, 0 (9)

<sup>a</sup>Based on available data for all individuals, <sup>b</sup>Based on data for individuals with results at baseline, consolidation, and 24 months. SD: Standard deviation

**Table 5: Patient reported outcomes**

Patient-reported outcome change from baseline	Mean±SD, median/n (%)	95% CI
Enneking functional status	18.3±19.9, 13	10.0-26.5
SF-36v2 health survey: Physical	2.92±7.11, 1.8	-0.08-5.92
SF-36v2 health survey: Mental	-2.70±10.43, -0.6	-7.10-1.71
AAOS lower limb outcomes	-2.1±13.4, 0	-7.9-3.7

SD: Standard deviation, CI: Confidence interval, AAOS: American academy of orthopaedic surgeons, SF: Short form.

**Table 6: Adverse events**

Adverse events (n=31)	Number of events	Number of individuals (%)
Any adverse event	34	16 (51.6)
Pain	10	8 (25.8)
Medical issue	7	3 (9.7)
Tardy bone union	4	2 (6.5)
Trauma	4	2 (6.5)
Alignment issue	2	2 (6.5)
Hardware issue	2	2 (6.5)
Infection (superficial)	2	2 (6.5)
Contracture	2	1 (3.2)
Infection (deep)	1	1 (3.2)
Possibly or probably related to study device and/or procedure	16	12 (38.7)
Serious	11	5 (16.1)

the same measurements as we did preoperatively, described above. Likewise, as mentioned above, we administered the patient-reported outcome (PRO) studies at the appropriate intervals.

Study data were collected on CRF and entered into Excel worksheets. All study data were imported into SAS datasets and analyzed using SAS Version 9.4 software (SAS Institute, Cary, NC, USA). All statistical analyses were independently quality checked. Continuous measurements and endpoints were reported using the mean, standard deviation (SD), median, and range. Categorical measurements and endpoints were reported as the number and percent of participants with each characteristic. Summaries of the study outcome endpoints also included 95% confidence intervals (CIs).

## Results

### Subject demographics

A total of 31 individuals were initially enrolled in the study. There were 20 males (65%) and the 11 females (35%), with an average age of 24, ranging from 13 to 69 years old. Nearly 68% of the participants were Caucasians and 16% were Black and Hispanics, respectively. The mean BMI was 24.2 kg/m<sup>2</sup>, with a range of 16.2–34.3.

Twenty-three (74%) femora were treated and eight (25.8%) tibia were involved in the study. The cause of the discrepancy was a traumatic injury in 12 (39%) participants, congenital discrepancy in 10 (32%)

participants, developmental cause in 6 (19%) participants, and Ollier's disease in 1 (3%) participant. The cause of discrepancy was unknown for one participant and was not recorded for one participant.

Before surgery, for ambulation, 18 (58%) participants used a shoe lift and 11 (36%) participants used no means of limb equalization. One (3%) participant used the walker and one (3%) participant used a cane.

Only 17 of the 31 (55%) participants completed the study. Ten (32%) participants failed to show up for their final (2-year postconsolidation) visit but were fully consolidated when last evaluated. Two (6%) participants withdrew before final evaluation but were fully consolidated at the last visit. Moreover, one (3%) participant was lost to follow-up shortly after completing lengthening. There was one death, which occurred prior to consolidation.

### Lengthening

The target amount of limb lengthening planned averaged 3.5 cm, with a range of 1.8–6.0 cm. The lengthening actually achieved averaged 3.35 cm, range 2.94–3.76 cm.

Of the thirty participants with lengthening measurements, when comparing the achieved length to the preoperative targeted length, the results revealed that the final obtained length averaged 96.3% of the targeted length (95% CI 87.7%–105.0%), meaning that, on an average, the resulting elongation of a limb was short of the planned elongation of that limb by 3.7%. The range overall was 46.7%–157.1%.

The lengthening accuracy was a mean of 96.67%, range 60.9%–140.0%, and 95% CI 88.85%–104.49%.

For the thirty participants with lengthening measurements, the time to complete the lengthening part of the procedure from the date of surgery averaged 48.5 days, with a range of 25–80 days. The target lengthening was similar for each bone (femur: mean 3.55 cm and tibia: mean 3.56 cm), but lengthening achieved was greater for tibia (3.76 cm) versus femur (3.23 cm) [Table 2].

### Implant precision

The implant's performance proved quite precise, matching its name, as noted in the chart above. On an average, the limb's lengthening was within 96.67% of the implant's recorded elongation (SD 20.56%) while the median accuracy was 100.0% (max/min: 60.9/140.0).

The femur was lengthened for fewer days (mean = 46.4 days and SD 16.3 days) than was the tibia (mean = 54.3 days and SD 12.4 days) [Table 3].

### Time to full weight-bearing

For statistical purposes, we calculated the length of time in days between surgical implantation procedure and the 1<sup>st</sup> day that full weight-bearing was recorded during a clinic

visit. The mean for thirty participants followed to full weight-bearing was 141.1 days (SD  $\pm$  80.7), with a median of 116 days (min/max 32/360; 95% CI 110.9, 171.2).

### Bone union

Of the 31 participants, 29/29 participants achieved bone union. One participant was lost to follow-up before consolidation and 1 died prior to consolidation. 27/29 participants achieved bone union without intervention. Two participants required additional intervention, of which 1 had bone graft and 1 had trauma nail.

The participant who had a bone graft demonstrated tardy consolidation of the regenerate and received an autogenous cancellous iliac crest bone graft, which resulted in consolidation of the lengthened zone. The other participant with a tardy bone union was subjected to an exchange nailing with a trauma nail to permit increased weight-bearing. This resulted in consolidation of the regenerate without the need for additional grafting. The one participant that died during the final months in the study had already consolidated his regenerate new bone in the distraction gap.

We defined bone union (consolidation) as the date when X-ray studies first revealed full corticalization of the newly formed regenerate bone on three sides. The healing index, defined as the time from surgical implantation to bone union (days)/the total length achieved since surgery (cm), was 44.5 with a SD of 22.8.

It took an average of 142 days (median 115, range 42–360) from surgery to consolidation for all participants who completed the study at least to consolidation. This time interval was slightly shorter for the femur (mean 141 days, median = 105 days) than the tibia (mean = 144 days, median 142 days).

### Range of motion

Comparing range of motion from preoperative baseline to the point of consolidation of the lengthened regenerate zone, the knee joint lost an average of 6.5° of flexion and 0.3° of extension. The ankle lost an average of 1.4° of dorsiflexion and 5.4° of plantar flexion. The hip joint lost, on average, 2° of flexion, and gained 1.6° of extension.

At 24-month follow-up evaluation, it appears that the average range of knee flexion deteriorated an additional 4° from the results obtained at consolidation. Other ranges of motion changed lesser amounts, with some improving 1° or 2°. However, since fewer participants were available for the final 24-month postconsolidation evaluation, it appears that the participants with substantial residual loss of motion were more likely to return for final examination, skewing the results, whereas those participants who had a near normal range of motion at consolidation evaluation apparently did not feel a need to return for re-examination 2 years later and were thus lost to follow-up. This is

reflected in the observation that while the mean range of knee motion deteriorated, the median range of knee motion did not deteriorate after consolidation, nor did the median range of motion for any other joint [Table 4].

### Subject-reported outcome studies

The SF-36 v2 Health Survey, AAOS Lower Limb Outcomes Questionnaire, and Enneking Functional Status Assessment were administered preoperatively and at postconsolidation visits. The latest available assessment at or after consolidation was used in comparisons with the preoperative assessment. The results of SF-36 and AAOS Lower Limb Outcomes Questionnaire demonstrated virtually no change from preoperative to final postoperative scores. The postoperative Enneking Functional Status Assessment improved 18% over the preoperative assessment (95% CI 10.0% to 26.5%) [Table 5].

### Adverse events

#### Summary of adverse events

Adverse events were grouped into similar reporting categories. Over the course of the study, 34 events occurred in 16 participants (52%). The most common event reported was pain (26%). Of these events, 16 were judged to be possibly or probably related to the study device and/or procedure. Five participants (16%) experienced a total of 11 serious adverse events, most of which were judged not related to the study device and/or procedure.

Two events were classified as hardware issues. One nail failed to elongate while the participant was lengthening the device at home. It was necessary to remove this nail and replace it with one that functioned properly. One interlocking screw broke. It passed through a proximal hole in the nail and was used as a syndesmotom screw between the upper tibia and the head of the fibula. The screw broke at the time of lengthening nail removal. The broken fragment could not be retrieved without great difficulty and was thus left *in situ* between the upper tibia and fibula head.

The internal components of the PRECICE™ lengthening nail separated during removal in the implant for exchange nailing in the participant noted above required a trauma nail to increase weight-bearing activity. The components had to be fished out of the IM canal with a Pituitary Rongeur.

There was only one serious medical issue in this series: a participant developed a ruptured colonic diverticulum 1 month after completing lengthening, during the consolidation phase, his femur having been lengthened 1.5 cm. An exploratory laparotomy was followed by a *Clostridium difficile* bowel infection, bilateral pleural effusions, and a fatal outcome. The death was deemed unrelated to the lengthening procedure.

One participant, a femoral lengthening, developed a deep *Staph aureus* infection involving the implant, at the

osteotomy site. It was successfully treated with debridement and IV antibiotics.

One participant developed a superficial infection at the site of implant removal, treated successfully with 2 weeks of oral antibiotics. Another participant developed a superficial skin infection at the site of removal of a syndesmotic screw above the ankle; it resolved after 10 days on oral antibiotics.

Eight participants (25.8%) had pain issues during limb lengthening. In some cases, this could be traced to hardware. For example, there was one participant who had a trochanteric bursitis relieved by removal of the implant. Another participant, whose regenerate had fully ossified, experienced pain after running one mile; the symptoms were relieved by removal of the implant.

One participant had pain over a distal of locking screw on the medial aspect of the knee. The symptoms disappeared after removal of that screw.

One participant developed hypoesthesia in the saphenous nerve distribution following a femoral lengthening through the retrograde approach. It was still present at the final follow-up.

One participant, at the final follow-up, reported an injury while playing a basketball several days earlier. He was found to have sustained an anterior cruciate ligament (ACL) injury, likely requiring surgery. It is not known whether the lengthening procedure contributed to this problem. (The footprint of the ACL on the tibia abuts, and may overlap slightly, the entry point of a tibial nail) [Table 6].

### Status at the end of study

Seventeen participants completed the protocol and exited the study at the appropriate time, with at least 2-year follow-up after consolidation. Two participants withdrew before final evaluation but were fully consolidated at the last visit. One participant was lost to follow-up prior to consolidation, and one participant was lost to follow-up after consolidation. There was one death. No participant withdrew from the study because of an adverse event, and no participant was terminated by an investigator.

### Discussion

For more than half a millennium, medical practitioners have tried to overcome limb length inequality, especially after a traumatic injury. At the beginning of the 20<sup>th</sup> century, surgeons began to combine rudimentary external skeletal fixators with step-cut osteotomies to lengthen bones of the lower extremities, with varying rates of success.<sup>[1-3]</sup>

A major step forward occurred in 1951 when Soviet surgeon G. A. Ilizarov unlocked from within bone a previous hidden capacity to form new osseous tissue in a widening distraction gap under appropriate conditions of delay prior to distraction; stable but axially-dynamic

external skeletal fixation; and a distraction rate of about 1 mm/day, fractionated into at least four steps.<sup>[4-6]</sup> An entire system of orthopedics evolved from this discovery, used with astonishing success to correct congenital, developmental, and acquired deformities, eliminate largest skeletal defects, treat all manners of fractures, both open and closed, and even regenerate soft tissues to a degree never before thought possible.

The principal drawback to the Ilizarov method has always been problems associated with the use of an external skeletal fixator to achieve the desired outcome. Aside from the wire-skin or pin-skin interface infections and the risk of acute and chronic implant site osteomyelitis, the transcutaneous/transosseous wires must, by their very function, cut through the skin through a process of compression necrosis along with the implant's pathway.

Under the circumstances, it is no surprise that progressive surgeons tried to develop entirely internal lengthening devices that could be used in accordance with Ilizarov methodology but without the transcutaneous implants associated with external fixation. The first such devices consisted of a telescopic IM nail that could be elongated with an internal ratchet mechanism.<sup>[7-9]</sup> While some of these implants are still available and used in certain locations around the world, they all suffer from a lack of precision control of the elongation process and the inability to reverse the nail if necessary.

Baumgart of Germany invented a telescopic nail containing an internal electric motor that elongates the device. It receives its power through a subcutaneous induction coil that is intermittently mated to a similar coil outside the skin.<sup>[10]</sup> Since the device does not elongate unless the external coil is applied to the limb, fear of excess or runaway elongation is thereby eliminated. However, as of yet, the lengthening nail cannot be used in compression mode.

The PRECICE™ IM lengthening nail was derived from the MAGEC™ spinal growing rod used to maintain alignment in surgically treated cases of early-onset scoliosis.<sup>[11]</sup> As mentioned earlier, an internal rotating magnet, connected through a gear reduction box to a rotating spindle, elongates the nail by pushing the telescopic portion outward. Since the internal magnet will only rotate on its axis in the presence of a magnetic field generated by rotating external magnets, uncontrolled elongation cannot occur. Likewise, and equally important, the PRECICE™ IM lengthening nail is the only one currently available that can be reversed, thereby eliminating tension on nerves or vascular structures if such a problem that develops during lengthening. Likewise, the nail can be used in the compression mode for osteosynthesis if needed.

The present study was undertaken to assess the reliability of the PRECICE™ nail and to reveal any flaws in the implant that called out for improvement. During the

course of the study, the manufacturer modified the basic design of the nail. Initially, the outer tube of the implant contained multiple welds, which were deemed a potential source of failure, although none occurred during this study. Subsequently, the outer tube was manufactured from a solid piece of titanium, thereby eliminating the welds.

The targeted lengthening amounts in this study were not large, averaging 3.5 cm, with a range of 1.8–6.0 cm.

It took 48.5 days, on an average, to achieve an average of 3.5 cm of lengthening. Given that distraction did not start until a week after surgery, on average, it took an average of 41.5 days to lengthen a limb on average, 35 mm, a rate of 0.84 mm/day. Full consolidation assessed by observing full corticalization on three sides of the regenerate required an average of 142 days, which averages out to 7.4 mm/month total treatment time.

Since several participants did not return for the final follow-up assessment after consolidation, first assesses the range of motion at consolidation rather than study exit to determine the average range of motion change. The knee joint in this series lost an average of 6.5° of flexion and 0.3° of extension. With the ankle, the loss was more of plantar flexion (5.4°) than of dorsiflexion (1.4°). The hip joint hardly changed at all. We anticipated that the range of motion would approach the preoperative values if we had been able to follow all participants to study exit, 2 years after consolidation. We noted, however, that the knee range of motion appeared to deteriorate slightly at the final follow-up, an unlikely occurrence since activity typically increases range of motion over time following consolidation. Instead, we concluded that the participants with less than optimal range of motion at consolidation were more likely to return for 24-month postconsolidation assessment, skewing the data.

We found the PRO surveys were not useful in this study. The pre- and posttreatment results were so varied as to be meaningless. This observation corresponds to a similar finding reported earlier wherein the results of typical PRO surveys are not helpful in deformity correction and limb-lengthening assessment.<sup>[12]</sup> This is because most participants are functioning quite well with respect to activities of daily living in spite of the limb length discrepancy. In the aforementioned study, we found that a modified version of the Scoliosis Research Society's (SRS) outcome instrument (limb deformity-SRS), which assesses such things as physical appearance and social embarrassment, proved a far better discriminator of pre- and posttreatment considerations than any of the standard PRO instruments.

In a study comparing 20 femoral nailing cases to 13 limb reconstruction system monorail external fixator system, Laubscher *et al.* at Britain's Royal National Orthopaedic Hospital<sup>[13]</sup> found that IM lengthening resulted in earlier

weight-bearing, few complications, and greater patient satisfaction than obtain with the external fixation system. Likewise, the group at Baltimore's Sinai Hospital came to the same conclusion when they compared the PRECICE™ nail to a monolateral fixator to treat proximal femoral focal deficiency.<sup>[14]</sup>

The Sinai group also reported on a unique series of participants had previously experienced limb lengthening with an external skeletal fixator but were now having another limb segment lengthened with the PRECICE™ IM nail.<sup>[15]</sup> Thus, each participant served as his or her own control, when asked which lengthening technique they preferred. As one would expect, the greater patient comfort associated with the elimination of transcutaneous implants greatly enhanced the patient experience with the IM device.

The limb lengthening group from New York's Hospital for Special Surgery wanted to know how precise was the PRECICE™? They therefore compared the read-out values on the ERC to actual measured length of the distraction zone in 24 individuals undergoing either femoral or tibial lengthening with the implant. They found an accuracy of 96% and a precision of 86% comparing the measured elongation at each visit with the elongation recorded on the External Remote Controller.<sup>[16]</sup> Our results demonstrated the same amount of precision (96.67%).

Birkholtz and de Lange from Pretoria, South Africa,<sup>[17]</sup> described their initial experience with the PRECICE™ nail in nine participants, with results similar to ours: a targeted lengthening averaging 4.5 cm was achieved in all participants with an accuracy of 103%. All regenerate zones consolidated. There were two complications: a nail failed to elongate and was replaced with one that functioned properly; and a nail protruded through the cortex of a lengthening femur through a region that had previously been elongated with external fixator techniques (and was thus softer than a normal cortex). The surgeon, as in our case of tardy regenerate ossification, replaced the lengthening nail with a trauma nail, with uneventful consolidation thereafter.

## Conclusion

The PRECICE™ IM nail is a well-tolerated, reliable, fully implantable limb lengthening device that will accurately elongate the femur or tibia in a variety of causes of limb length inequality, with a low implant failure rate, and few complications. Persistent pain, when present, often occurred over prominent hardware and responds favorably to removal of the implant when the regenerate new bone in the distraction gap had fully consolidated.

## Financial support and sponsorship

The project was sponsored by NuVasive Specialized Orthopedics, Aliso Viejo, CA, USA.



## Conflicts of interest

All authors have either consulting and/or royalty agreements with the manufacturer of the PRECICE Nail.

## References

1. Abbott LC, Saunders JB. The operative lengthening of the tibia and fibula: A preliminary report on the further development of the principles and technic. *Ann Surg* 1939;110:961-91.
2. Codivilla A. On the means of lengthening, in the lower limbs, the muscles and tissues which are shortened through deformity. *Am Surg* 1905;2:353-69.
3. Putti V. Operative lengthening of the femur. *Surg Gynecol Obstet* 1934;58:318-24.
4. Ilizarov GA. A Method of Uniting Bones in Fractures and an Apparatus to Implement This Method. USSR Authorship Certificate, 98471; 1952.
5. Ilizarov GA. The tension-stress effect on the genesis and growth of tissues. Part I. The influence of stability of fixation and soft-tissue preservation. *Clin Orthop Relat Res* 1989;239:249-81.
6. Ilizarov GA. The tension-stress effect on the genesis and growth of tissues: Part II. The influence of the rate and frequency of distraction. *Clin Orthop Relat Res* 1989;240:263-85.
7. Bliskunov AI. Intramedullary distraction of the femur (preliminary report). *Ortop Travmatol Protez* 1983;10:59-62.
8. Cole JD, Justin D, Kasparis T, DeVlugt D, Knobloch C. The intramedullary skeletal kinetic distractor (ISKD): First clinical results of a new intramedullary nail for lengthening of the femur and tibia. *Injury* 2001;32 Suppl 4:SD129-39.
9. Guichet JM. Leg lengthening and correction of deformity using the femoral Albizzia nail. *Orthopade* 1999;28:1066-77.
10. Baumgart R, Zeiler C, Kettler M, Weiss S, Schweiberer L. Fully implantable intramedullary distraction nail in shortening deformity and bone defects. Spectrum of indications. *Orthopade* 1999;28:1058-65.
11. Pool S, Green SA, Roschak E. Inventors; Variable Length Device and Method. USA: Ellipse Technologies, Assignee; 2012.
12. Fabricant PD, Borst EW, Green SA, Marx RG, Fragomen AT, Rozbruch SR, *et al.* Validation of a modified scoliosis research society instrument for patients with limb deformity: The limb deformity-Scoliosis Research Society (LD-SRS) score. *J Limb Lengthen Reconstr* 2016;2:86-97.
13. Laubscher M, Mitchell C, Timms A, Goodier D, Calder P. Outcomes following femoral lengthening: An initial comparison of the precice intramedullary lengthening nail and the LRS external fixator monorail system. *Bone Joint J* 2016;98-B: 1382-8.
14. Szymczuk VL, Hammouda AI, Gesheff MG, Standard SC, Herzenberg JE. Lengthening with monolateral external fixation versus magnetically motorized intramedullary nail in congenital femoral deficiency. *J Pediatr Orthop* 2017. doi: 10.1097/BPO.0000000000001047.
15. Landge V, Shabtai L, Gesheff M, Specht SC, Herzenberg JE. Patient satisfaction after limb lengthening with internal and external devices. *J Surg Orthop Adv* 2015;24:174-9.
16. Kirane YM, Fragomen AT, Rozbruch SR. Precision of the PRECICE internal bone lengthening nail. *Clin Orthop Relat Res* 2014;472:3869-78.
17. Birkholtz FF, de Lange P. Evaluation of the first experience of intramedullary nail lengthening using PRECICE® in a South African limb lengthening and reconstruction unit. *S A Orthop J* 2015;15:67-71.

